

DEVELOPMENT AND STRUCTURE OF THE VILLOUS
HAEMOCHORIAL PLACENTA OF THE NINE-BANDED
ARMADILLO (*DASYPUS NOVEMCINCTUS*)

BY ALLEN C. ENDERS

Department of Biology, Rice Institute, Houston, Texas

INTRODUCTION

Chapman (1901) described the afterbirth of *Euphractus sexcinctus*, and Fernandez (1914) described implantation in *Dasypus hybridus* in some detail. Considerable attention was paid by the early workers to the form of the placenta regarding arrangement of the villi. Newman & Patterson (1910), in their paper on polyembryony, summarized the earlier studies concerning the structure of the placenta of *D. novemcinctus*, listed a number of different patterns of distribution of villi during the course of gestation, and suggested that these were modifications of a discoidal implantation. The most comprehensive description of placentation in the nine-banded armadillo is that of Patterson (1913). He described the early attachment of the blastocyst in the fundic tip of the uterus, yolk-sac inversion, germinal inversion, and the formation of the Träger. Both Fernandez (1909) and Patterson (1913) compared the early development of the armadillo placenta with the development of the rodent, referring specifically to the work of Melissinos (1907). Strahl (1913) pictured the villi as lying in part under the endometrium, but stated that the intervillous space was formed by erosion. In the work predating publication of Grosser's (1927) full development of his system of classification of placentas, little attention was paid to the relationship of the foetal vessels to the maternal blood vascular system. In their reviews of placental structure, both Mossman (1937) and Amoroso (1952) listed the placenta of *D. novemcinctus* as in the villous haemochorial class of Grosser. Mossman (1937), in summarizing the known information concerning the armadillo placenta, states that implantation is fundic, orientation fundic, amniogenesis by cavitation, shape modified discoidal, yolk-sac completely inverted, and that there is no decidua capsularis. Enders, Buchanan & Talmage (1958), in their study of the endometrium of pregnancy of the armadillo, reported that the cell columns and vascular villi invade the maternal blood sinuses which subsequently constitute the intervillous space.

The work reported here was initiated as a part of a comprehensive study of implantation in the armadillo (Buchanan, Enders & Talmage, 1956; Enders *et al.* 1958; Enders & Buchanan, 1959 *a, b*). It was felt that the additional material available makes a study of placentation in the armadillo in the light of modern interpretations of placental function highly desirable.

MATERIALS AND METHODS

During the course of our research studies concerning implantation of the blastocyst, several hundred female armadillos have been examined. The majority of these animals were purchased from suppliers who caught them within 100-mile radius of Houston, Texas. Approximately half of the females examined were in some stage of pregnancy, predominantly the period of delay of implantation.

Histological preparations were made from the placental tissues of forty-seven females in all stages from the period of early implantation to parturition. Routinely, portions of the placentas were fixed in Zenker's and Carnoy's fluids and in buffered formalin. When better cytological preservation was desired, Flemming's fluid or Elftman's osmichrome fixation was employed. The fixed material was stained by haematoxylin and eosin or by a variant of Masson's trichrome mixture. Glycogen was demonstrated by the PAS method using diastase extraction as a control. Lipid was demonstrated by the use of Sudan Black B on formalin-fixed frozen sections. Where it was desired to demonstrate cytoplasmic basophilia, Zenker's or Carnoy's fixed tissues were stained in eosin and methylene blue at a pH of 5.6.

Most of the tissue was obtained from animals from the feral population. Estimation of the age of the conceptus had, therefore, to be made on the basis of the extent of development and size of the embryos. A number of specimens were obtained from animals in which implantation had been induced by bilateral ovariectomy (Buchanan *et al.* 1956). Implantation in these animals does not differ from normal implantation (Enders *et al.* 1958).

DESCRIPTION

The continuous series of morphological changes in the formation and growth of the armadillo placenta can be divided for convenience of description into three stages. The first of these stages constitutes the period of placental establishment, beginning with the attachment of the blastocyst to the endometrium and ending with the formation of the cell columns. The second stage is that of placental enlargement, starting with the formation of the vascular villi and ending with the disappearance of the cytotrophoblast. The final stage, extending from the disappearance of the cytotrophoblast until parturition, is the period of the mature placenta.

Period of establishment of the placenta

Observations on the few previllous stages we have correspond well to Patterson's (1913) description of early implantation. The salient features in initial implantation which have been described by Patterson will be summarized in order to provide the necessary background for the interpretation of later stages. The initial attachment of the blastocyst is afforded by the cells of the trophoblast overlying the embryonic cell mass (Raubert's layer). After attachment has been initiated, the abembryonic trophoblast degenerates. At this time, the endoderm has extended only slightly beyond the margins of the embryonic cell mass. Consequently, an inverted yolk-sac placenta is formed without there being a bilaminar omphalopleure stage. The extraembryonic space forms initially between the embryonic cell mass and the overlying trophoblast. The mesenchyme therefore arises from trophoblastic

cells. As implantation progresses, the trophoblast becomes thickened marginally and reduced over the initial site of implantation. These changes, reported by Patterson (1913), constitute the initial implantation. They are probably completed within the first 2 or 3 days of implantation, as judged by the rarity of these stages in our collection and by estimation of the date of implantation from the animals in which early implantation was produced by bilateral ovariectomy.

The avillous placenta, consisting of the inverted yolk-sac placenta and the trophoblast, is formed by the developments summarized above. The placenta persists in this form during the budding of the ectodermal plate and subsequent division into four individuals of the intraembryonic portion of the conceptus. An example of this stage from our specimens is illustrated in Pl. 1, fig. 1. At the periphery of the implantation site the trophoblast forms a thick ring. The endoderm of the yolk-sac is continuous with the luminal margin of this ring. Extending radially into the endometrium are tongues of trophoblastic tissue. This trophoblast appears to be partially syncytial and is vacuolated in paraffin preparations. It is only here in the peripheral region that the trophoblast is interdigitated with maternal tissues. A few slips of this invasive trophoblast may occasionally be found more centrally. The inner aspect of the peripheral ring of trophoblast consists of a mass of relatively cuboidal cells in which mitotic figures are numerous. Extending centrally over the implantation site and separated from the newly formed amnion by the developing exocoelom is a layer of syncytial trophoblast with altogether different characteristics than those of the invasive peripheral syncytium. This central syncytium resembles the epithelium which later clothes the vascular villi.

The inverted yolk-sac placenta consists of a layer of endodermal cells and a single layer of squamous mesenchymal cells. It forms a continuous sheet over the undivided ectodermal plate and separates the rest of the conceptus from the uterine lumen. At this stage the intraembryonic portions of the endoderm do not differ histologically from the cells of the extraembryonic portion.

The maternal tissues underlying the central trophoblast show evidence of deterioration. Even in the two earliest specimens which we have examined, the maternal blood sinuses have been tapped. (The blood sinuses lie particularly close to the surface in the fundic region where the blastocyst implants (Enders *et al.* 1958). More peripherally, where the tongues of trophoblast extend into the maternal tissues, the endometrium is less disorganized.

Period of placental expansion

(1) *Initial formation of villi*

The embryos from the specimens which we obtained in this stage constitute a series from primitive streak formation to early somite development. In the earliest specimens only scant evidence of incipient haemopoiesis is seen in the splanchnopleure. In the later specimens, numerous normoblasts fill the lumina of the well-developed vessels of the splanchnopleure. The diameter of the implantation site and the extent of erosion of maternal tissues varies considerably. In all our specimens, however, the maternal sinuses have been interrupted but not invaded.

The peripheral trophoblast displays essentially the same characteristics as in the previous stage (Pl. 1, figs. 2, 3). The central trophoblast, however, is quite different.

It is much more extensive than previously and exhibits, in addition to the syncytial epithelium, masses of cellular trophoblast extending from the surface (Pl. 1, fig. 2; Pl. 2, figs. 7, 8). When first seen, the cell columns (Träger's knots) are in isolated patches of only a few cells (Pl. 2, fig. 7). Each cluster of cells is covered by an especially thin layer of syncytium which is continuous with that of the underlying central trophoblast. In specimens in which cell columns are more numerous, areas may be found in which some of the cell columns are so close together that on first examination they appear to form a continuous multilayered portion of the trophoblast.

As the cell columns enlarge, they protrude from the surface to a greater extent (Pl. 2, fig. 8). In the late stages of cell-column formation the appearance is one of knobs of cells covered by a thin layer of syncytium located on the surface of a membrane consisting of syncytial trophoblast and several layers of mesenchymal cells. This latter membrane, which has been derived from the central trophoblast, is the chorionic plate. Evidence of blood-vessel formation is seen in the associated mesenchyme. The chorionic plate at this stage may be applied fairly closely to the maternal tissues, but more frequently it forms pockets containing extravasated maternal blood.

(2) *Formation of vascular villi and invasion of sinuses*

The first sign of the development of the vascular villi is the protrusion from the surface of the chorionic plate of small folds of tissue having the same morphological make-up as the chorion itself but capped by a cell column. These vascular villi are simple projections covered by syncytial trophoblast with a mass of cytotrophoblast at the distal extreme. Initially the exocoelom may extend partially into the villi. With continued development the villi become highly branched and the exocoelom is excluded from these structures.

In the early stages of their development the vascular villi are situated in a pool formed by extravasation of blood from the interruption of the endometrial blood sinuses. By the late limb bud stage, the villi have invaded the endometrial sinuses peripheral to the initial implantation site (Pl. 1, fig. 4). The villi subsequently invade the entire anastomotic system of basal endometrial sinuses. Progressive stages exhibit both extension of villi toward the cervix and the enlargement of the sinuses. Maximum expansion of the maternal blood sinuses is usually observed by the time the foetuses have reached a length of 5 cm.

The endothelium of the maternal sinuses remains intact except in the area of initial penetration (Pl. 3, fig. 13). Enlargement of the intervillous space is by passive stretching of the endometrium by the growing villi. It should be emphasized that in no instance has evidence been observed that the cell columns or vascular villi are erosive or actively invasive of the endometrial tissues *per se*.

Although the villi develop first in the centre of the implantation area, later the chorion covering the fundic tip of the uterus becomes relatively avillous. Four major villous areas develop corresponding to the quadrants of the uterus. The foetal vessels enter these areas near their fundic margin. The villi within these continuous areas exhibit extensive arborization, anastomosis and short non-anastomotic terminal projections. In younger placentas the terminal portions of the villi are

plate- or frond-like expansions (Pl. 2, fig. 11). Foetal capillaries form a radiating series of loops within the vascular portions of each projection, while the distal margin is formed by a crescentic cell column. In later placentas those terminal portions of the villi which do not anastomose are simple finger-like projections (Pl. 2, fig. 12).

When the body stalks of the embryos are formed, the epithelium of the inverted yolk-sac is separated from the endoderm of the embryos, except for a transient yolk stalk. The inverted yolk-sac constitutes the outer covering of the embryonic vesicle. In other words, the four developing embryos with their amnions are contained in an exocoelom, the splanchnopleure of which is covered by the endoderm of the yolk-sac. In specimens from early in the period of placental expansion, the inverted yolk-sac placenta is highly vascularized (Pl. 1, fig. 4). The epithelial cells are tall columnar and frequently exhibit both vacuolation and granulation in the distal cytoplasm (Pl. 1, fig. 5). However, prior to the disappearance of the cell columns, the nature of the epithelium of the yolk-sac alters. The cells become more cuboidal and, in places, stratified, and the underlying connective tissue becomes less vascular and more dense. The yolk-sac placenta of foetuses of around 3.5 cm. is relatively avascular.

The peripheral ring of trophoblast remains as the area of junction between the endometrium and the placenta. Relatively little evidence of invasion or proliferation can be seen here in the later aspects of this stage. At the junction between the yolk-sac and the trophoblast, a roll of luminal epithelial cells is frequently seen (Pl. 1, fig. 4). By the end of the period of expansion fusion of the overlying placental tissues with the luminal surface of the endometrium has been initiated and the peripheral ring is no longer distinguishable as such.

Mature placenta

By the time the foetuses have reached a crown rump length of 6 or 7 cm. the mature placenta has been formed. This stage persists until parturition (neonatal length 12 cm). Cell columns are absent, and it is doubtful that the placenta is increasing in size. The definitive position of the placenta in the uterus has been reached. The portion of the chorion overlying the fundus is relatively devoid of villi, but they are numerous in the sinuses of the body of the uterus (Pl. 2, fig. 6). The villi are highly branched, anastomotic structures, forming a meshwork composed of looping, branching chords of a relatively uniform diameter. The villi are massed in the four quarters of the uterus, while the four foetuses lie dorsal, ventral, left and right.

As previously stated, the umbilical vessels to each quarter of the continuous placenta are situated at the fundic end of the more villous portion. In addition, the vessels enter and leave relatively close to the overlying endometrial tissue. In other words, few villi are present on the side of the vessels directly underlying the endometrial arcades but numerous villi extend towards the muscularis. The blood flows via the umbilical arteries into a capillary bed extending in a highly tortuous fashion toward the inner muscular layer of the endometrium, and then back towards the luminal surface before confluence into a number of veins leading toward the umbilical vein at the fundic end of the placenta. It should be noted that maternal blood flow

is still in the opposite direction; that is, maternal blood enters the luminal side of the sinuses from vessels in the arcades of endometrium. The return flow is through the spongework created by the villi and into the numerous smaller sinuses in the inner layer of the myometrium.

In the mature placenta the endometrium is highly stretched, glands are few and poorly organized. The major change that occurs during this period is the fusion of the extraembryonic membranes overlying the endometrial arches with the now reduced endometrial tissue. By the time the foetuses have reached a c.r. length of 8 cm. fusion has occurred as far as the cervix.

Histology and histochemistry of the villi

The trophoblastic cell columns consist of aggregates of similar cells, the cytoplasm of which is slightly basophilic. Throughout most of their existence, the columns are characterized by the presence of numerous mitotic figures. Small lipid droplets are a conspicuous feature of many of the cells in the cell column (Pl. 3, fig. 20). Glycogen is only rarely present. Surrounding the cell columns is found a thin layer of syncytial trophoblast (Pl. 3, figs. 13, 18). This trophoblast has a more uniform free surface than has the epithelium of the vascular villi with which it is continuous. In most instances the cell columns appear to be completely surrounded by syncytium, but it is occasionally too thin to be readily discernible with the light microscope. No basement membrane was observed between the cells of the cell column and the syncytium. There are numerous intercellular spaces within the columns. A PAS positive material which resists diastase extraction is present in most of these spaces (Pl. 3, fig. 18). This material is granular, and only mildly acidophilic.

The vascular villi change appreciably in morphology during the course of gestation. In all stages, however, they are characterized by the presence of a single layer of syncytial epithelium and the complete absence of any cytotrophoblast. The surface of the syncytium is very irregular, exhibiting a brush border in some areas and a relatively smooth surface in other areas (Pl. 3, figs. 15-17). Frequently small vacuoles are found within the syncytium; occasionally large vacuoles are seen. Areas of the syncytium that exhibit protruding masses of cytoplasm are common. These cytoplasmic protrusions have a seemingly tenuous connexion with the syncytium (Pl. 3, fig. 17). At no stage of gestation does the syncytium contain appreciable amounts of demonstrable lipid. Cytoplasmic basophilia is characteristic of the mid-zone of the syncytium; that is, especially around the nuclei. The syncytium covering the vascular villi is underlain by a basement membrane of variable thickness (Pl. 3, fig. 16). This membrane is quite thin during the early expansion period of the placenta, but grows progressively thicker. The membrane is PAS positive, diastase resistant and acidophilic. The mesodermal core of these villi consists of the foetal capillaries and numerous fibroblasts derived from the mesenchymal cells. Throughout the period of expansion of the placenta the connective tissue is relatively loose (Pl. 2, fig. 9). The foetal capillaries are situated more or less randomly, although there is some tendency toward a peripheral location. Lipid is present in the perivascular cells (Pl. 3, fig. 20). Glycogen is occasionally present, especially in cross-sections of the larger villi (presumably nearer to the chorionic plate) (Pl. 3, fig. 19).

In late pregnancy after the disappearance of the cell columns, the structure of

the villi is somewhat different. The syncytium is generally thinner, although its surface exhibits almost as much variability as at earlier stages (Pl. 3, fig. 14). There are fewer nuclei per unit area. The syncytium is thickest at the bulges where the nuclei are located. The juxtannuclear area of the syncytium remains slightly basophilic. The basement membrane underlying the syncytium is thick, and contains numerous collagen fibres as well as PAS positive material. The stroma of the villi is more fibrous than previously. The foetal capillaries lie close to the syncytium, but do not indent it (Pl. 2, fig. 10). The fibroblasts in striking contrast to the previous stage have become rounded, gland-like cells (Pl. 3, fig. 14). They exhibit pronounced basophilia in the cytoplasm which surrounds the Golgi zone.

In addition to the healthy tissue, degenerating villi are common in late pregnancy. Both fibrin and fibrinoid, as judged by the criteria of Wislocki & Bennet (1943), are found in these areas. Fibrinoid is especially common.

DISCUSSION

The invasion of the maternal blood sinuses and the enlargement of these sinuses by the villi to form the intervillous space is a unique feature of placentation in the armadillo. The significance of this method of development is readily apparent. Since the maternal vascular system is uninterrupted except in the fundic area, the blood flow is unidirectional (Enders *et al.* 1958). The maternal blood enters the sinuses under the arches of endometrial tissue. The flow is then toward the inner muscularis. This pattern of blood flow should result in fewer areas of relative mixing of oxygenated and deoxygenated blood than are found in the intervillous spaces of the human and monkey placentas, in which the blood both enters and leaves from the basal plate (Boyd, 1956; Ramsey, 1959). The foetal blood vessels also enter the intervillous space near to the luminal border of the placenta. Thus the venous return flows from the muscularis side of the placenta to the luminal side. In consequence, there is in all probability a rough countercurrent with the more oxygenated blood in the foetal vessels being near the luminal surface. There would not, however, be a direct countercurrent since the highly branched and anastomotic villi form a rather complete spongework in the maternal sinuses. In any given capillary therefore, the direction of foetal blood flow could bear any relationship to the direction of maternal blood flow. Although the means of formation of the intervillous space is quite different, the pattern of maternal blood flow in these spaces is similar to that of the villous haemochorial placenta of the hyena (*Crocuta crocuta*) as described by Amoroso (1959). The disappearance of villi from the fundic region results in the superficial alteration of the placenta from a discoidal one to a relatively zonary type. More important, it means that the villi disappear in the one area where the maternal blood vessels are not preserved because of their destruction during the initial penetration of the trophoblast.

The yolk-sac epithelium alters in character about the middle of the period of expansion of the placenta. Since, at this time, it constitutes the separation between the uterus and the splanchnopleure of the exocoelom, it is likely that this is the placental membrane which fuses with the surface of the endometrium in later stages. An examination of the mature placenta, however, reveals very little epithelium covering the connective tissue that is fused with the endometrium. Furthermore,

what little epithelium is present has a somewhat different character from that of the earlier yolk-sac epithelium. An alternative method of development would be the outgrowth of the chorion from the junctional zone to fuse with the endometrium and isolate the yolk-sac. Further studies will be necessary to clarify the morphology of the yolk-sac in the later stages of pregnancy.

The early villi have frond-like terminal projections. The villous trees observed in later pregnancy are composed of anastomotic cylindrical chords and terminal projections. There are, however, discontinuities in the early projections. The fusion and perforation of the syncytial trophoblast might be the means by which the plate-like initial terminations are converted to a series of anastomosing cylinders. An additional modification which would contribute to the change in form of the villi is the break-up of the trophoblastic cell columns capping the projections into smaller masses of cells (cell islands).

During the period of establishment of the placenta the peripheral ring of trophoblast apparently acts as the proliferative area. Mitotic figures are numerous there. The few cells which penetrate into the endometrium become highly modified and seem to degenerate. The more centrally located trophoblast appears to be formed by additions from the peripheral area. Consequently, the peripheral ring serves as a source of the trophoblast in general, a source of invasive tissue, the region of attachment to the uterus, and the junction point of the yolk-sac and the trophoblast. The area in which the trophoblast is actually invading the endometrium is the only true 'junctional zone'. Although this area of close relationship between the endometrium and the placenta persists into the period of placental expansion, active destruction of the endometrium occurs only in the early stages of the period of placental establishment.

In the armadillo placenta the only cytotrophoblast present after formation of the vascular villi is that of the cell columns. The absence of Langhans cells, of anchoring villi, and of basal plate simplifies the interpretation of the function of the cytotrophoblast in this species. From a structural point of view, the role of the cytotrophoblast is apparently to act as a source of proliferation of syncytial trophoblast. Both the restriction of mitotic figures to the cell columns and the position of these columns indicate that these structures constitute the proliferating tips of the growing villi. It is also possible that the cytotrophoblast may have a glandular function, as evidenced by the presence of intercellular, PAS positive material. Before a glandular function can be ascertained with certainty, however, evidence for liberation of the intercellular material must be accumulated. It is interesting to note that the staining qualities of this intercellular substance are those which would be expected of a gonadotropin.

Discussion of the functional activity of the armadillo placenta is premature at this time. However, a few inferences may be drawn from the observations to date. The strictly limited active invasion of the endometrium by the trophoblast suggests that the products of histolysis are of relatively little importance to the developing conceptus. The early degeneration of the abembryonic trophoderm produces an inverted yolk-sac placenta that is admirably situated to receive the products of glandular secretion. Penetration of the maternal sinuses also occurs very early, when the embryos would probably have a relatively limited capacity for synthesis.

On the other hand, the formation of the intervillous spaces by invasion of a pre-existing system not only leaves these spaces with a directional blood flow, but also causes relatively little interference with the vascular supply to the overlying endometrial glands. Consequently the products of the glands, probably garnered by the yolk-sac, would appear to have greater importance to the developing conceptus of the armadillo than to other species with a placenta of the villous haemochorial type. However, Boyd (1959) recently pointed out that the products of glandular secretion (histopoietic histotrophe) are probably more important to the early human embryo than has been generally recognized.

SUMMARY

Placentation in the armadillo was studied with special attention to the formation, development, and structure of the villi. Placental development can be divided into three stages: the period of establishment of the placenta, the period of placental enlargement, and the period of the mature placenta. Initial attachment, formation of the inverted yolk-sac, and the formation of the avillous placenta occur during the first period. Formation of cell columns and vascular villi, and the invasion of the maternal blood sinuses, occur during the second period. By the time the third period is reached, the blood sinuses have been invaded throughout the body of the uterus. There are no cell columns present in mature placentas, and no evidence that growth takes place during this period. The definitive form of the placenta is a spongework consisting of anastomotic and highly branched villi situated within the maternal blood sinuses.

The cytotrophoblast is composed of the cell columns (and islands) forming the distal ends of the villi. Neither Langhans cells nor anchoring cell columns are present, nor is there a basal plate at any stage. The cell columns are composed of aggregates of cells, many of which exhibit mitotic figures. Small lipid droplets are present in many of these cells and a proteinaceous, PAS positive substance is present in the intercellular spaces. The cell columns are invested by a thin layer of syncytium. The vascular villi in the early stages are frond- or plate-like extensions from the villous stem. The syncytial trophoblast covering the vascular villi has numerous and varied modifications of its free surface, and is underlain by a basement membrane. Numerous capillaries are seen in the stroma of the villi. In later stages the villi are composed of anastomotic strands with a relatively uniform diameter. The syncytium is thinner than at early stages and there is a great deal of collagen in the stroma. The foetal capillaries lie close to the syncytium but do not indent it. There are numerous highly modified fibroblasts with markedly basophilic cytoplasm within the villi.

The structure of the villi, position of the cell columns, and restriction of mitotic figures to the cell columns lead to the conclusion that these structures constitute the source of the syncytial trophoblast throughout the period of growth of the villi.

It is suggested that the products of the uterine glands are probably a more important source of nutrients to the developing conceptus in this species than in others with a villous haemochorial placenta.

This study was supported by a grant by the United States National Science Foundation.

REFERENCES

- AMOROSO, E. C. (1952). Placentation. Chapter 15 in *Marshall's Physiology of Reproduction* (ed. A. S. Parkes), pp. 127–311. New York: Longmans, Green and Co.
- AMOROSO, E. C. (1959). Comparative anatomy of the placenta. Part VIII in *The Uterus*. *Ann. N.Y. Acad. Sci.* 75, 855–872.
- BOYD, J. D. (1956). Morphology and physiology of the uteroplacental circulation. In *Gestation* (ed. G. A. Villee), pp. 182–193. *Trans. 2nd Conf.* New York: Josiah Macy, Jr. Foundation.
- BOYD, J. D. (1959). Glycogen in early human implantation sites. In *Memoirs Soc. Endocrin.* no. 6. *Implantation of Ova* (ed. P. Eckstein), pp. 26–34. Cambridge University Press.
- BUCHANAN, G. D., ENDERS, A. C. & TALMAGE, R. V. (1956). Implantation in armadillos ovariectomized during the period of delayed implantation. *J. Endocrin.* 14, 121–128.
- CHAPMAN, H. C. (1901). Observations upon the placenta and foetus of *Dasypus seacinctus*. *Proc. Acad. nat. Sci. Philad.* 53, 366–370.
- ENDERS, A. C., BUCHANAN, G. D. & TALMAGE, R. V. (1958). Histological and histochemical observations on the armadillo uterus during the delayed and post-implantation periods. *Anat. Rec.* 130, 639–658.
- ENDERS, A. C. & BUCHANAN, G. D. (1959a). The reproductive tract of the female nine-banded armadillo. *Texas Reports on Biology and Medicine*, 17, 323–340.
- ENDERS, A. C. & BUCHANAN, G. D. (1959b). Some effects of ovariectomy and injection of ovarian hormones in the armadillo. *J. Endocrin.* 19, 444–452.
- FERNANDEZ, M. (1909). Beiträge zur Embryologie der Gürteltiere, zur Keimblätterinversion und spezifischen Polyembryonie der *Mulita (Tatusia hybride Desm.)*. *Morph. Jb.* 39, 302–333.
- FERNANDEZ, M. (1914). Zur Anordnung der Embryonen und Form der Placenta bei *Tatusia novemcincta*. *Anat. Anz.* 46, 253–258.
- GROSSER, O. (1927). *Fruhentwicklung, Eihautbildung und Placentation des Menschen und der Säugetiere*. München: Bergmann.
- MELISSINOS, K. (1907). Die Entwicklung des Eies der Mäuse. *Arch. mikr. Anat. Ent.* 70, 577–628.
- MOSSMAN, H. W. (1937). Comparative morphogenesis of the fetal membranes and accessory uterine structures. *Contr. Embryol. Carneg. Instn.* 26, 129–246.
- NEWMAN, H. H. & PATTERSON, J. T. (1910). The development of the nine-banded armadillo from primitive streak to birth, with special reference to the question of specific polyembryology. *J. Morph.* 21, 359–423.
- PATTERSON, J. T. (1913). Polyembryonic development in *Tatusia novemcinctus*. *J. Morph.* 24, 559–684.
- RAMSEY, E. M. (1959). Vascular adaptations of the uterus to pregnancy. Part v in *The Uterus*. *Ann. N.Y. Acad. Sci.* 75, 726–745.
- STRAHL, H. (1913). Über den Bau der Plazenta von *D. novemcinctus*. *Anat. Anz.* 44, 440–447.
- WISLOCKI, G. B. & BENNER, H. S. (1943). The histology and cytology of the human and monkey placenta, with special reference to the trophoblast. *Amer. J. Anat.* 73, 335–449.

EXPLANATION OF PLATES

PLATE 1

- Fig. 1. Early implantation. Although the ectodermal plate is elongate, there is as yet no separation into separate embryos. The yolk-sac (uppermost membrane in picture) is already inverted. The amnion has been formed but is not yet distended with fluid. The exocoelom separates the amnion from the trophoblast in the central region. Note the masses of trophoblast at the margin of the implantation site. Tetrachrome stain. $\times 110$.
- Fig. 2. Implantation site from the avillous stage. Parts of three of the four embryos are visible in the picture. The fundic tip of the uterus was everted prior to fixation, and the blood has been washed out of the maternal blood sinuses at the base of the endometrium. Note the extensive central trophoblast. H. and E. $\times 28$.
- Fig. 3. Marginal region of the implantation site from the section in fig. 2. At the top of the picture is the inverted yolk-sac placenta. It fuses with the trophoblast in the middle of the picture. The trophoblast extends into the endometrium at the bottom of the picture. Note that the

luminal epithelium of the endometrium is folded where the trophoblast penetrates the endometrial tissues. H. and E. $\times 110$.

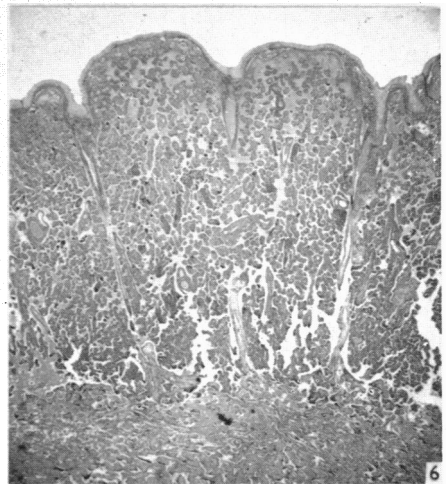
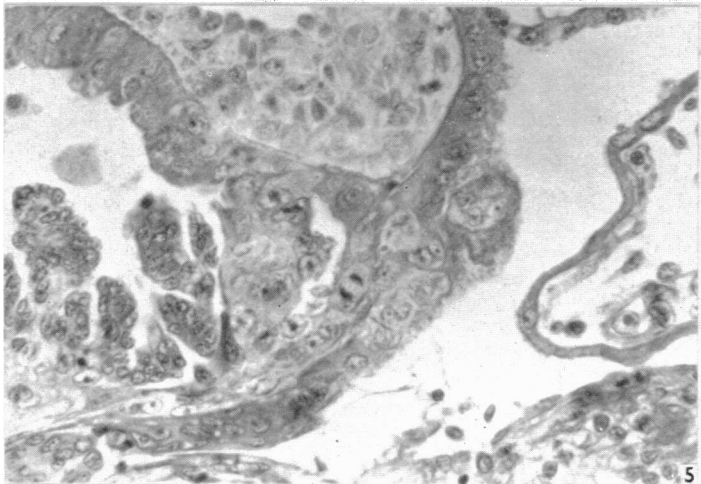
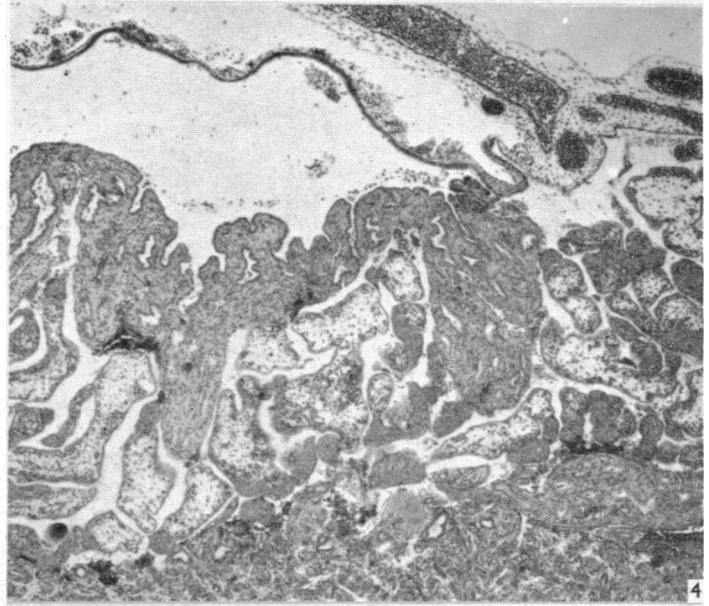
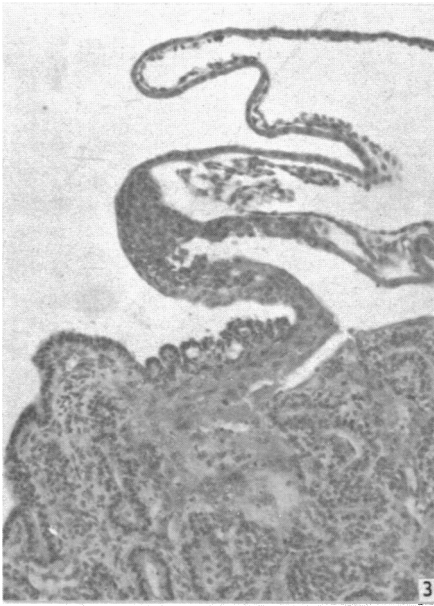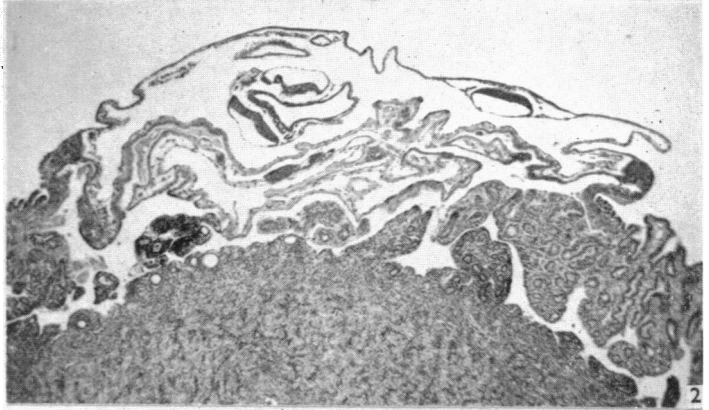
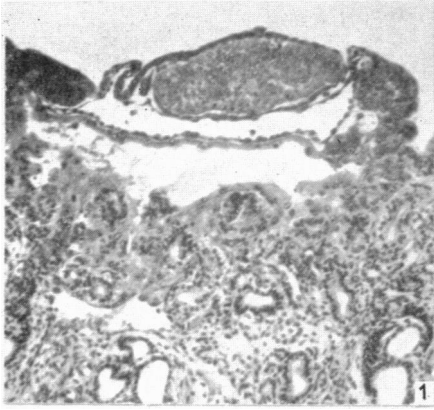
- Fig. 4. Margin of an implantation site from early in the period of expansion of the placenta. At the top of the picture the well-vascularized inverted yolk-sac lies in the uterine lumen. Note that the cell columns and vascular villi have extended into the endometrial sinuses in the centre and left of the picture. Tetrachrome stain. $\times 43$.
- Fig. 5. A junctional zone from the same stage as fig. 4. In the upper left of the picture is the inverted yolk-sac epithelium. In the upper right is syncytial trophoblast. Note the tongue of trophoblast extending into the endometrium in the lower left corner and the luminal epithelial cells in the centre of the picture. Tetrachrome stain. $\times 200$.
- Fig. 6. A portion of the placenta from late pregnancy. The maternal sinuses have been greatly expanded. The endometrium consists of thin arcades over the sinuses and is fused with the overlying placental membranes. The endometrial blood vessels are seen in the radiating septa. Note the dilation of the luminal portion of such a vessel in the upper centre of the picture. H. and E. $\times 11$.

PLATE 2

- Fig. 7. Section from the same specimen as Pl. 1, fig. 2. The two embryos seen in the upper right of the picture are as yet incompletely separated. A portion of the yolk-sac placenta appears in the upper left corner. Note the masses of cells occurring in the lower centre and right of the picture. These masses constitute the earliest stage in the formation of cell columns. H. and E. $\times 110$.
- Fig. 8. Development of the cell columns is more advanced than seen in fig. 7. The cell columns in the lower portion of the figure are more highly developed than those in the upper portion of the picture. In the right centre, a vascular villous is seen in the early stages of formation. H. and E. $\times 110$.
- Fig. 9. Typical cross-section of the cell columns and vascular villi during the period of expansion of the placenta. Note the uterine glands at the margins of the picture. H. and E. $\times 110$.
- Fig. 10. Villi from the period of the mature placenta. Note the relative density of the mesodermal core and the peripheral position of the capillaries. There is a fibrotic area in the endometrium overlying these villi. H. and E. $\times 140$.
- Fig. 11. A formalin-fixed, unstained, terminal frond, dissected from a villous stem early in the period of placental expansion. The light margin of the projection is formed by the cell columns. At the upper right an anastomosis with another frond was broken. A particularly flat frond was selected for photography. $\times 43$.
- Fig. 12. A portion of a villous stem from a mature placenta. The treatment and magnification are the same as in fig. 11. Note that the terminal projects are relatively uniform in diameter although knobby. Several anastomotic branches between this and other terminal arborizations had to be broken during the dissection. The vascular pattern is particularly clear in this specimen. $\times 43$.

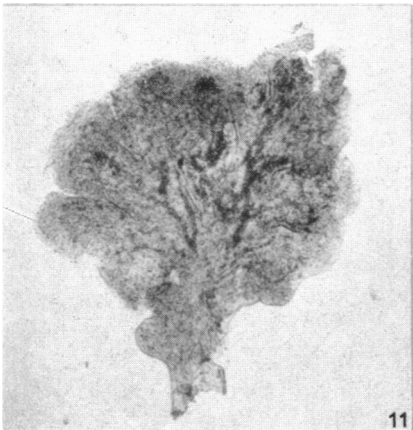
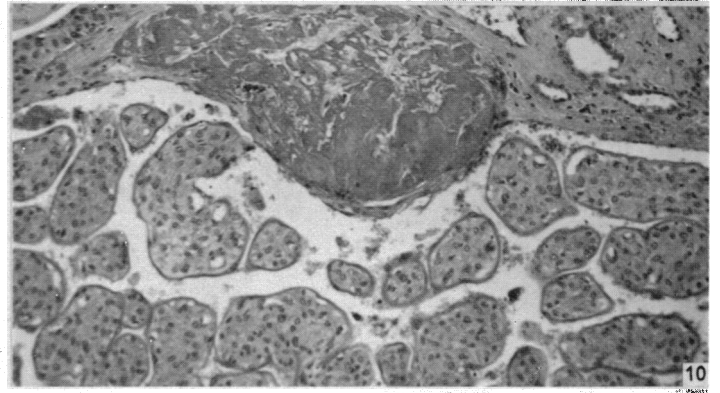
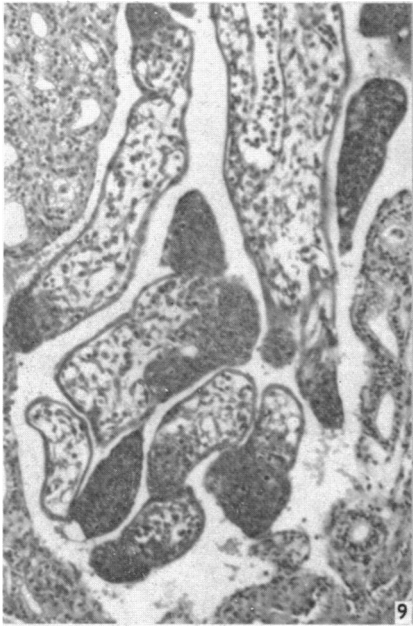
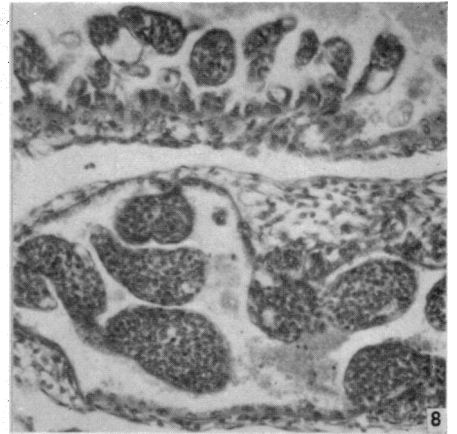
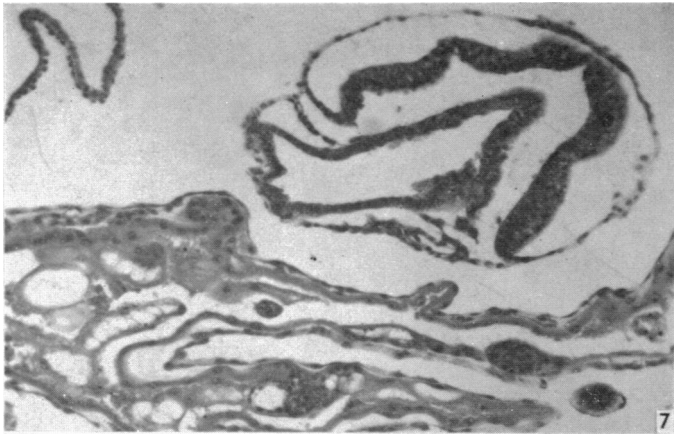PLATE 3

- Fig. 13. Period of placental expansion. A cell column is seen in the centre of the picture. To the lower right and left are endometrial glands. Note that the endothelium of the maternal sinus is still present, and that the syncytium surrounding the cell column is continuous with that of the vascular villi above it. Tetrachrome stain. $\times 435$.
- Fig. 14. A portion of a villus from a mature placenta. Note the Golgi zone underlying the nucleus of the fibroblast in the lower centre of the picture, and that the fibroblasts in general are glandular in appearance. The areas of cytoplasm which appear light in this picture exhibit basophilia in other types of preparation. Note also the irregularity of the surface of the syncytium. Champy's fixed, post-osmified, phase contrast. $\times 790$.
- Fig. 15. A tangential section of the syncytium illustrating the presence of numerous small vacuoles and the irregularity of the free surface. Osmichrome fixation, PAS, haematoxylin. $\times 435$.
- Fig. 16. Portions of two villi. Note the presence of a large vacuole in the syncytium at the centre of the picture and the variable thickness of the basement membrane. Period of placental expansion. Osmichrome fixation, PAS, haematoxylin. $\times 1000$.
- Fig. 17. Syncytium of vascular villi from expansion period. Note the presence of a brush border and of protoplasmic projections. Phase contrast, osmium tetroxide fixed, methacrylate embedded section. $\times 790$.

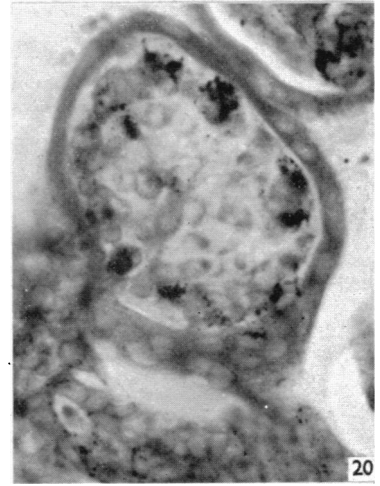
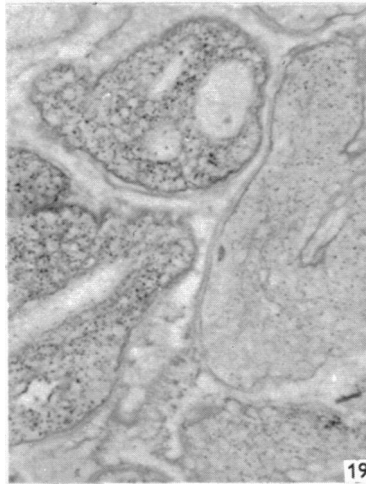
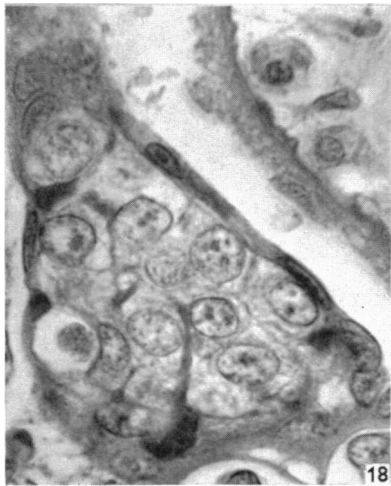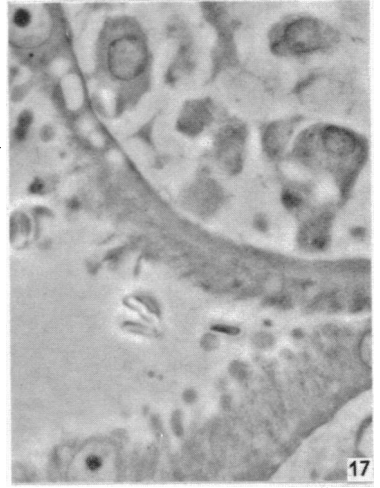
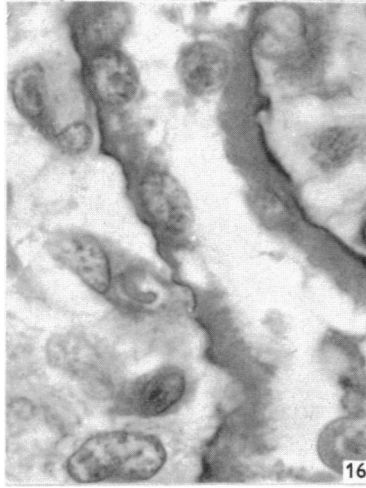
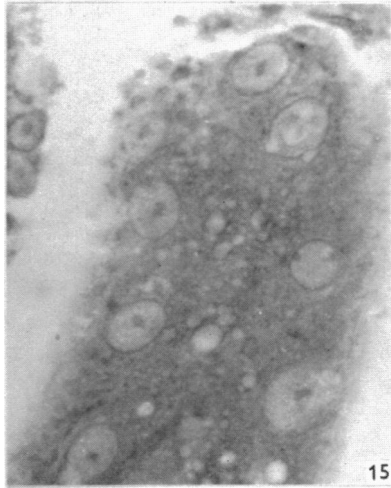
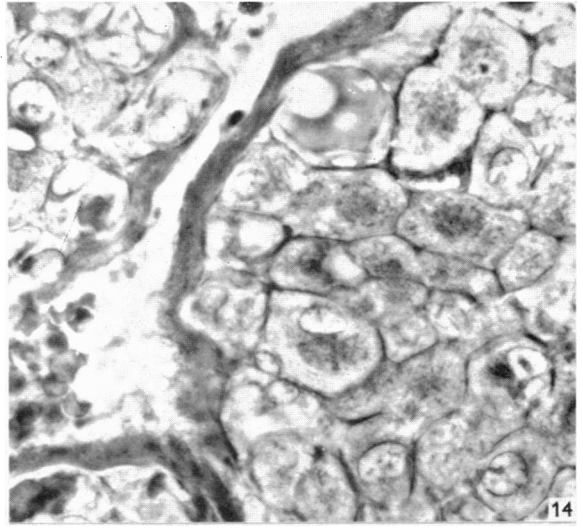
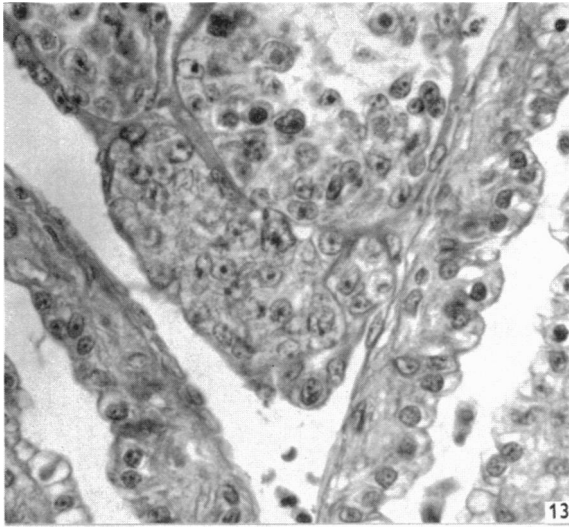


ENDERS—DEVELOPMENT AND STRUCTURE OF THE VILLOUS HAEMOCHORIAL PLACENTA OF THE NINE-BANDED ARMADILLO (*DASYPUS NOVEMCINCTUS*)

(Facing p. 44)



ENDERS—DEVELOPMENT AND STRUCTURE OF THE VILLOUS HAEMOCHORIAL PLACENTA OF THE NINE-BANDED ARMADILLO (*DASYPUS NOVEMCINCTUS*)



ENDERS—DEVELOPMENT AND STRUCTURE OF THE VILLOUS HAEMOCHORIAL PLACENTA OF THE NINE-BANDED ARMADILLO (*DASYPUS NOVMCINCTUS*)

- Fig. 18.** Cell column. Note the syncytium surrounding the cell column and the presence of a dark substance between the cells within the column. This intercellular substance is PAS positive in other types of preparation. Osmichrome fixation, iron haematoxylin, aniline blue. $\times 1000$.
- Fig. 19.** Glycogen in the vascular villi. Note that there is appreciably more glycogen in the villi containing the larger blood vessels. Carnoy's fixed, PAS. $\times 110$.
- Fig. 20.** Frozen section demonstrating lipid in a cell column and vascular villus. Note that the lipid droplets in the cell column are small and that there are numerous large droplets associated with the blood vessels of the vascular villus. Formalin fixation, Sudan Black B. $\times 435$.