THE EFFECT OF AGE ON THE ARRANGEMENT OF FIBRES IN THE BONE MATRIX OF THE FEMUR OF THE DOMESTIC FOWL

By C. W. M. PRATT

Department of Anatomy, University of Cambridge

INTRODUCTION

In previous papers (Pratt, 1957, 1959) accounts were given of the fibre structure of the various kinds of bone present in the prenatal and postnatal femur of the rat. The present paper extends these studies to the domestic fowl, and again special attention has been given to the situation of the various kinds of bone in relation to the growth of the bone as a whole. The arrangement of collagen fibre bundles in the matrix of avian bone was described by von Ebner (1875) and later by Weidenreich (1923), but both of these accounts were concerned with the classification of bony tissue according to its fibrous structure and did not consider the bone as a whole. There is also the description of avian bone by Maj (1938), as seen with polarized light, but he did not describe the fibre pattern in any detail. There do not appear to be any previous accounts of the structural changes associated with the maturation of avian long bones apart from that of Fell (1925) which covers the embryonic period, and the brief account of Policard (1941) which does not extend beyond the third month of postnatal life. It was considered, therefore, a necessary preliminary to include a brief account of the maturation of the fowl's femur.

MATERIALS AND METHOD

The material used included embryos of 9, 11, 13 and 17 days, postnatal cockerels aged 1, 8, 15, 22, 29, 43, 57, 71, 85, 120, 155, 190, 246 and 379 days, and two laying hens, all of which were from the same Rhode Island Red stock.

The embryos were fixed in Bouin's fluid and the hind limb was removed subsequently on each side. In the case of the postnatal birds the femur was dissected out on each side immediately after death and fixed in 5 % formal saline. The bones were decalcified with the disodium salt of ethylene-diamine-tetracetic acid, and in each case the specimen from one side was cut longitudinally and that from the other side was cut transversely. Sections thus obtained at 4 μ were stained with haematoxylin and eosin, iron haematoxylin, by a modification of Long's silver impregnation which showed both reticular and collagenous fibres, and with Weigert's elastin stain.

OBSERVATIONS

Text-fig. 1 outlines the main features of the development and maturation of the fowl's femur, and it will be seen that there are several differences when these are compared with the better known patterns of development and maturation of mammalian long bones. In the earliest stage examined (Text-fig. 1A), the arrangement of the constituent cells of the cartilage model allows one to distinguish between the central diaphysial cartilage and the two peripheral epiphysial cartilages. The central portion of the diaphysial cartilage has undergone hypertrophic changes and is surrounded by a sleeve of perichondrial bone. This cartilage is then rapidly invaded by subperiosteal tissues, and a primary medullary cavity is formed. Meanwhile a shaft of periosteal bone has been laid down around the diaphysial cartilage (Text-fig. 1B), and by the time of hatching the shaft consists solely of periosteal bone. This is closed at both extremities by the remains of the diaphysial cartilage, each of which now forms a growth cartilage consisting of the juxta-medullary hypertrophic zone and the juxta-epiphysial proliferative zone (Text-fig. 1C). Trabeculae of endochondral bone appear for the first time in the metaphysis of the postnatal bone. The walls of the latter, now and in all later stages, are formed largely of periosteal bone (Text-fig. 1D, E, F). This bone is separated at first by perichondrial bone from the underlying endochondral bone. Later, if external metaphysial remodelling occurs, the periosteal bone is separated by a cement line from the underlying endochondral bone and endosteal bone. The structure of the avian growth and epiphysial cartilages has been described by Haines (1942) and Wolbach & Hegsted (1952). The medullary aspect of the growth cartilage (the hypertrophic zone) is continuously, but unevenly, invaded by marrow tissues, which gives a serrated appearance to the cartilage. The epiphysial cartilage does not undergo endochondral ossification in the way it does in mammals, but persists for a considerable time as a wide basophilic hyaline zone and a narrow outer eosinophilic articular zone (Text-fig. 1D, E). The cells of the growth cartilage become exhausted with maturity and this structure has disappeared at both extremities by 155 days (Text-fig. 1E). The invading marrow tissues then enter the hyaline zone of the epiphysial cartilage, where individual groups of chondrocytes have hypertrophed and in this way endochondral osteogenesis slowly spreads through the hyaline zone, so that by 190 days only the articular zone persists, whose structure at this stage is described by Whiston (1940). At this point a terminal plate of bone is formed which lines the deep surface of the articular cartilage (Text-fig. 1F). Though not illustrated in the text-figure, there is an extensive deposition of endosteal bone throughout, and almost completely filling, the medullary cavity of the long bones of female birds during the egg-laying cycle. The process has been described in the domestic fowl by Bloom, Domm, Nalbandov & Bloom (1958).

(i) *Perichondrial bone*

The perichondrial bone (the 'primary diaphysial lamella' of Johnston, 1958) is laid down under the perichondrium and directly upon the surface of the diaphysial cartilage. This bone appears to be devoid of lacunae and is about 10 μ in thickness. Its fibrous structure is distinctive and consists of short fine fibres, which are directed radially and densely packed (Pl. 2, fig. 4). In the 9-day-old embryo this bone forms a continuous thin sleeve, which is co-extensive with the zone of hypertrophic cartilage. Further perichondrial bone is being formed at the junction of the hypertrophic and proliferative zones, about which point the extremities of the diaphysial cartilage are increasing in diameter as well as elongating, and as a result the perichondrial bone has an hour-glass shape. An erosion of the central portion of the

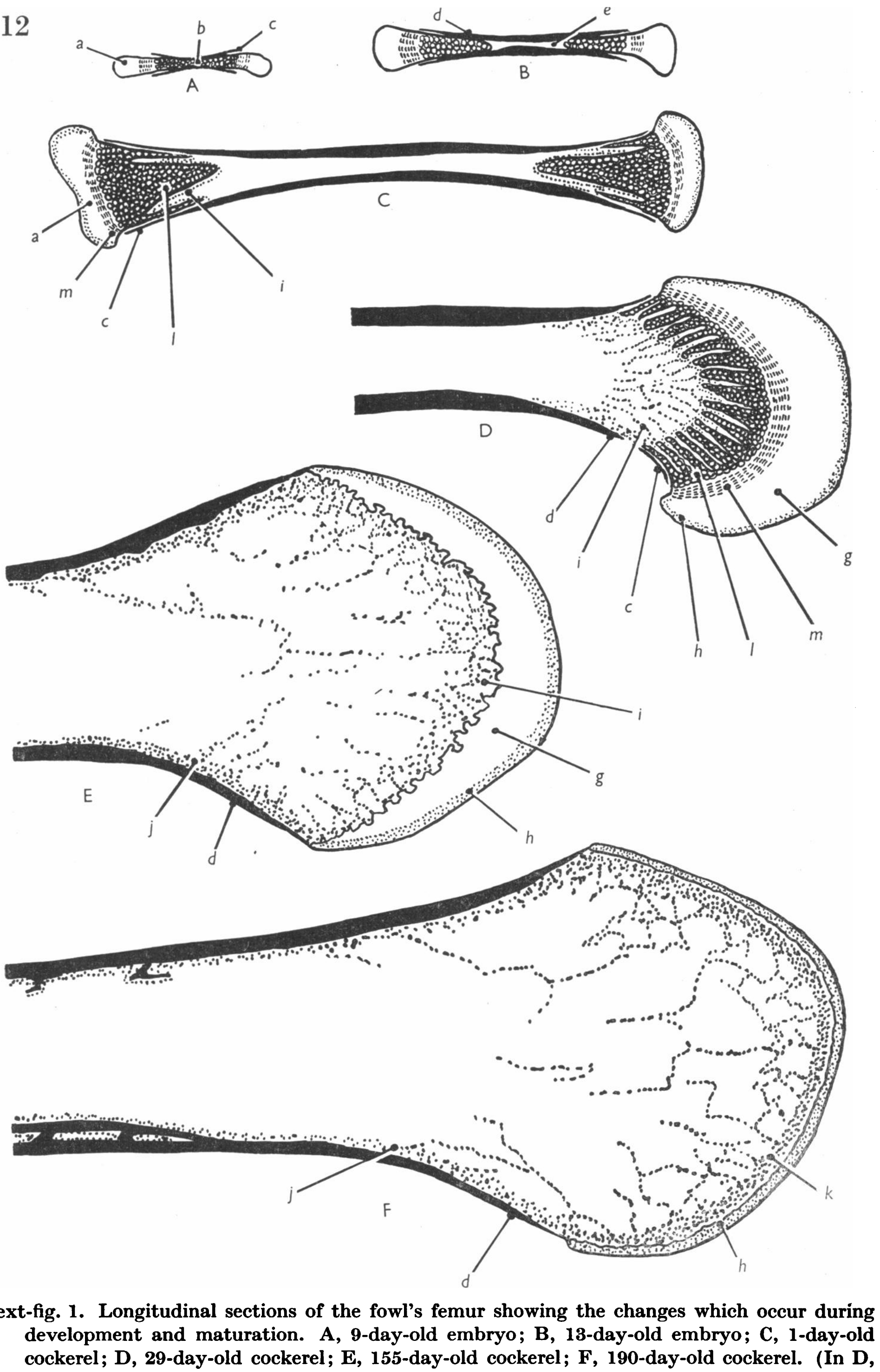

Text-fig. 1. Longitudinal sections of the fowl's femur showing the changes which occur during development and maturation. A, 9-day-old embryo; B, 13-day-old embryo; C, 1-day-old cockerel; D, 29-day-old cockerel; E, 155-day-old cockerel; F, 190-day-old cockerel. (In D, E and F the distal extremity is shown.) ×4. *a*, epiphysial cartilage; *b*, diaphysial cartilage; *c*, perichondrial bone; *d*, periosteal bone; *e*, primary medullary cavity; *g*, hyaline zone (of epiphysial cartilage); *h*, articular zone (of epiphysial cartilage); *i*, endochondral bone; *j*, endosteal bone; *k*, terminal plate of bone; *l*, hypertrophic zone (of growth cartilage); *m*, proliferative zone (of growth cartilage).

perichondrial bone has occurred by the 13th day of embryonic life, when, at the same time the central part of the diaphysial cartilage is completely replaced by a marrow cavity. With subsequent medullary erosion the perichondrial bone comes to line the marrow cavity, but in the later embryonic stages a narrow band of cartilage remains unabsorbed, and lies immediately adjacent to the perichondrial bone. By 17 days the perichondrial bone is confined to the metaphysis.

Perichondrial bone formation continues in postnatal bones, where it occurs between the perichondrium and the hypertrophic zone of the growth cartilage. With subsequent growth this bone forms part of the wall of the metaphysis unless there is external remodelling of the latter when the perichondrial bone forms a rather ill defined 'perichondrial ring of the ossification groove' (Text-fig. 1D) which is co-extensive with the hypertrophic zone of the growth cartilage. The fibres of the postnatal perichondrial bone are irregularly arranged and it is difficult to distinguish between this bone and the periosteal bone which becomes deposited on its outer surface.

(ii) *The periosteal bone*

The fibrous perichondrium surrounding the bones of the early embryo is, by convention, referred to as the periosteum in the later embryos, as perichondrial bone has appeared, and any further bone that may be deposited beneath this fibrous sheath is called periosteal bone.

(A) *Embryonic woven bone.* This bone exists in two forms, which will be referred to as early and late periosteal bone. The early periosteal bone lies about the middle of the shaft and consists of irregular trabeculae, containing numerous large round closely packed lacunae. The fibres of its matrix are finely bundled and form an irregular network which blends both with the fibres of the periosteum and with the fibres of the perichondrial bone (Pl. 2, fig. 4). On the other hand, the late periosteal bone (*Fasenknochen* of Weidenreich, 1923), which first is confined to the extremities of the shaft, consists of elongated needle-like trabeculae, these being longitudinally directed and giving an imbricated appearance. The matrix of this bone contains coarse longitudinally directed fibre bundles (Pl. 2, fig. 5) which form the 'core' of the trabeculae where they lie in a fine network of fibres similar to that found in the early periosteal bone.

(B) *Neonatal sheath.* This matrix appears to have escaped recognition in the past. It is not apparent in haematoxylin and eosin preparations, but in silver-stained sections it appears as a densely fibred band. It forms at the time of hatching, when a layer (about 5 μ in thickness) of densely packed longitudinally running fibre bundles is deposited about the whole of the circumference of the bone. The appearances at 8 days confirm the fact that it forms a compete sheath to the bone, though by this time further deposition of woven bone has occurred and the neonatal sheath no longer lies on the external surface of the bone (Pl. 1, fig. 1; Pl. 2, fig. 5). The progressive enlargement of the medullary cavity results in the disappearances of the sheath by 29 days. The persistence of the neonatal sheath within the shaft during the first 4 weeks of postnatal life makes it possible to use the sheath as a marker for indicating growth in width during this period (Text-fig. 2). It will be seen that during this period periosteal deposition and medullary remodelling are eccentric, and a considerable portion of the bone is unchanged for at least the first 3 weeks.

(C) *Postnatal woven bone.* The bone matrix formed after the appearance of the neonatal sheath is similar to the late embryonic periosteal bone, but in the former the incorporation of extra-osseous fibres plays an increasingly important part. The postnatal fibrous periosteum contains fine reticular fibres, wavy collagen fibres and linear elastic fibres, all of which are tightly packed and run longitudinally. Immediately adjacent to the deep surface of the fibrous periosteum lie osteoblasts, in varying stages of differentiation, and situated within a dense network of fibres. Some of these latter fibres are collected into linear bundles of wavy fibres, which at one extremity appear to be continuous with the fibrous periosteum and at the other extremity pass into the bone where they can often be traced to the medullary surface. These osseous fibre bundles, which were observed by Gegenbaur (1867), increase in number with age and run parallel to each other in either half of the bone, always being directed outwards towards the nearest extremity, which means that at either extremity they will be running almost longitudinally but will be radially directed about the middle of the bone. These osseous fibre bundles appear to act as a scaffolding for the formation of the trabeculae of more finely fibred bone. This latter bone matrix is finely and irregularly fibred similar to the early embryonic periosteal bone, and contains numerous spherical lacunae (Pl. 2, fig. 5). Vascular canals form by the bridging of adjacent trabeculae (Pl. 1, fig. 2), and these channels become further reduced in diameter by the deposition within them of bone whose matrix is characterized by the more orderly arrangement of the fine fibre bundles which run, closely packed, in the long axis of the vascular channel, as described by von Ebner (1875) (Pl. 1, fig. 2; Pl. 2, fig. 10). These perivascular structures correspond to the primary osteones described in reptiles by Gross (1934).

There is an incorporation of tendon fibres into the bone in certain situations. These fibres are similar to the osseous fibre bundles but are thicker (Pl. 3, fig. 14). In some instances the tendon fibres may cross the osseous fibre bundles and the former are often to be seen transversing vascular spaces and then re-entering bone substance.

The vascular spaces found in the wall of the shaft, whose formation has already been described, in some instances acquire a lining which appears to be devoid of fibres (Pl. 3, fig. 11). This hyaline lining, which does not appear to have been described in the past, varies from 2 to 7 μ in thickness and contains lacunae occupied by elongated cells. These structures appear to be confined to relatively 'old' parts of the bone. For example, such linings are found even in early stages in bone adjacent to a periosteal surface which has been static for a time due to an eccentric mode of growth. After 85 days, when there is little medullary erosion of the shaft,

Text-fig. 2. Transverse sections of the diaphysis of the femur from cockerels aged 1–246 days. Sites of endosteal ossification are shown with crosses; it should be noted that this process occurs in the first instance upon the intramedullary trabeculae, and only later occurs throughout the medullary cavity. The bone formed during embryonic life is identified by the presence of the neonatal sheath, which limits this bone, which is shown as solid in the first four stages illustrated. The lictor-bundle bone, which also contains elastic fibres, which is laid down after 85 days, is shown by stippling. Secondary osteones are shown as solid circles (× 5½).

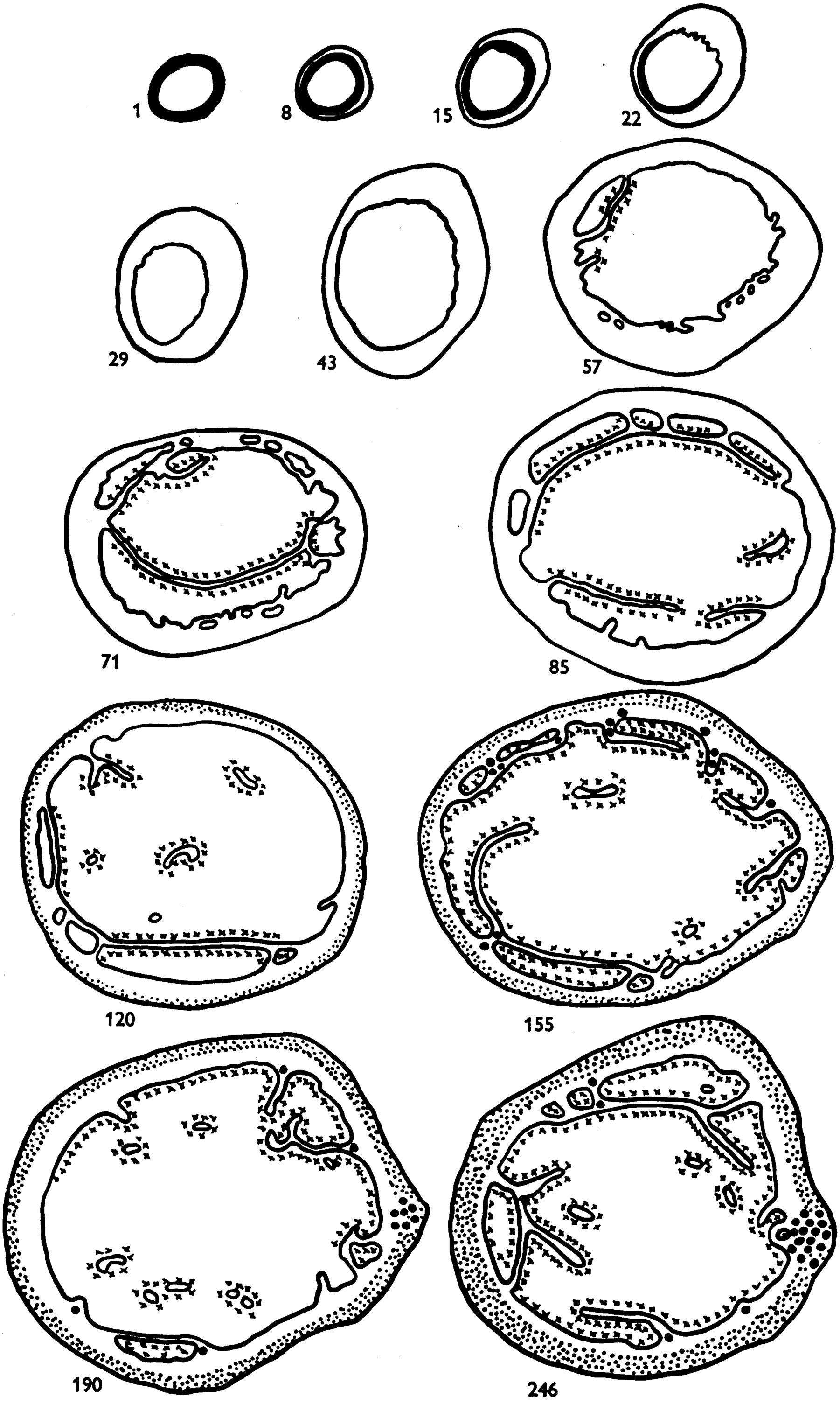

Text-fig. 2. For legend see foot of facing page.

the remaining woven cancellous bone persists indefinitely, and consequently most of vascular spaces within this bone have hyaline linings (Pl. 1, fig. 3).

(D) *Lictor-bundle bone.* At 120 days and in all later stages (Text-fig. 2) the newly formed matrix of the periosteal bone has a homogeneous appearance (Pl. 1, fig. 3), as it consists almost entirely of longitudinally arranged and densely packed fibre bundles (Pl. 2, figs. 6, 7). These fibre bundles have a similar diameter to the perivascular fibre bundles seen in the earlier stages. Their wavy appearance and their linear arrangement was observed by Weidenreich (1930), who called this type of bone lictor-bundle bone. Though usually forming fine fibre bundles they do collect into coarser bundles in some situations. The lacunae are elongated and fewer than in the woven bone. Occasional circumferential bundles of fibres are to be seen, which result in a type of lamellar bone.

It would seem that this late periosteal bone results in part from an incorporation of the deeper layers of the fibrous periosteum. Elastic fibres are found within the matrix of the periosteal bone in all the specimens examined at 120 days and later. These fibres are not seen in the bone matrix in earlier stages but are present in the fibrous periosteum. When in the bone matrix they appear as incomplete concentric sheaths of longitudinally running fibres (Pl. 2, figs. 8, 9). Elastic fibres have been described previously in avian bone (Weidenreich, 1930), but the significance of their incorporation into bone has not been commented upon.

(E) *Secondary osteones.* Secondary osteones, which are perivascular deposits of bone separated from the surrounding bone by reversal lines, are occasionally found within the cancellous woven bone which persists in the diaphysis of older birds (Text-fig. 2; Pl. 1, fig. 3). The presence of these structures suggests that earlier there has been localized resorption of bone, followed by repair. It should be emphasized that secondary osteones are rare and are easily overlooked. Two varieties exist, which are distinguishable structurally, namely those found in areas where tendon fibres pass into the diaphysis, and those found in that part of the diaphysis which is adjacent to the medullary cavity.

In those areas where coarse bundles of tendon fibres pass into the bone, and form a large proportion of the fibrous matrix, secondary osteones are frequently seen after the age of 190 days in both sexes. The lacunae of these osteones are irregularly shaped and have no apparent pattern of distribution. The tightly packed fibre bundles have a diameter similar to that of the bundles of lictor-bundle bone, and run in the same plane as the long axis of the osteone (Pl. 3, fig. 14).

The other type of secondary osteone is seen at 155 days and in older stages in situations adjacent to the medullary surface of the shaft. In these, the lacunae are elongated and arranged circumferentially in a regular manner. The fibres are finely bundled and usually a lamellar arrangement is present, though this may not always be well defined (Pl. 3, fig. 13).

(iii) *Intramedullary bone*

(A) *Embryonic endochondral woven bone.* There is no evidence of intramedullary bone formation until immediately before hatching, when the hypertrophic cartilage, as a consequence of peripheral erosion, forms a large central core (Text-fig. 1C), and the endochondral bone present forms a discontinuous layer on the surface of this core. It has already been pointed out that a layer of hypertrophic cartilage persists on the internal surface of the perichondrial bone, and endochondral bone is also deposited on the medullary surface of this cartilage. Thus a layer of cartilage comes to be between perichondrial bone on the outside and endochondral bone internally. The fibrous structure of the endochondral bone closely resembles that of the early periosteal bone and consists of an irregular network of fine fibre bundles.

(B) *Postnatal endochondral and endosteal metaphysial woven bone.* Endochondral bone formation continues until both the growth cartilage and the hyaline zone of the epiphysial cartilage are completely exhausted, which has occurred at 190 days (Text-fig. 1). This bone differs from the bone formed in similar situations in the embryo in that it is more extensive and contains numerous rounded osteocytes (Pl. 3, fig. 12). This bone is confined to the metaphysis, due, presumably, to the extensive intramedullary resorption of bone in the region of the junction of the diaphysis and metaphysis, where there are large numbers of osteoclasts. Osteoclasts are also found in large numbers under certain parts of the metaphysial periosteum, as described by Koelliker (1873) when the peripheral trabeculae of endochondral bone are removed during the process of external remodelling of the metaphysis. Elsewhere osteogenesis continues especially amongst those remaining peripheral trabeculae which form the wall of the metaphysis. Subsequently, periosteal bone is deposited on these and a cement line intervenes. This 'endosteal' activity results in the consolidation of the trabeculae of endochondral bone. Cement lines are often also present in this metaphysial spongiosa and serve to distinguish the endosteal from the endochondral bone as the fibrous structure of the two types of bone is identical at this stage.

(C) *Endosteal lictor-bundle and lamellar bone.* The osteoclastic erosion of the internal surface of the diaphysial wall associated with expansion of the marrow cavity occurs at first at all points, later (at 57 days) this process becomes confined to certain situations where, once having penetrated the wall of the shaft, the invading tissues extend circumferentially. This has the effect, by 71 days, of isolating extensive sheets of bone which were originally formed under the periosteum but now lie within and extend throughout the medullary cavity (Text-fig. 2). These trabeculae may subsequently be remodelled to some extent, but are always to be seen in the later postnatal stages. Lictor-bundle bone is deposited on these early intermedullary trabeculae. This bone has sparse and elongated lacunae and is separated from the underlying woven bone by a continuous cement line. The osteoblastic activity associated with the endosteal osteogenesis of the shaft appears to be continuous with the endosteal bone formation occurring in the metaphysis where, by this time, lictor-bundle bone is being formed and woven bone has ceased to be formed.

The endosteal bone, which is formed after 71 days, has a lamellar fibrous structure (Pl. 3, fig. 15) and after 120 days is found lining the whole of the medullary cavity (Text-fig. 2). In the shaft it forms a wide almost avascular layer separated by a smooth cement (resting) line from the bone of periosteal origin (Pl. 1, fig. 3).

(D) *Endosteal bone, associated with egg laying.* In the two hens examined, one of which was in lay and the other was out of lay and moulting, a type of bone, somewhat similar to the early embryonic woven bone, is found forming trabeculae throughout the medullary cavity. Elsewhere this bone is superimposed upon the endosteal lamellar bone, where the junctions of the two types of bone are sharply demarcated although there are no cement lines, which suggests that there is a continuity of the osteogenic processes. The matrix of this bone is more deeply basophilic than the matrix from any other part of the bone. This bone, associated with egg laying, is irregularly and finely fibred (Pl. 3, fig. 16), and furthermore the fibre density is variable so that some areas appear almost hyaline. It contains numerous irregularly shaped lacunae.

DISCUSSION

Periosteal osteogenesis in relation to growth in length

Experimental data on the growth in length of avian long bones does not seem to be available. There is, however, indirect evidence based on the measurements of large numbers of bones obtained from birds of known ages. Latimer (1927) showed that the femur in White Leghorn cockerels grew in length at an even rate until about 145 days when the rate decreased, so that by about 182 days growth in length had ceased. Buckner, Insko, Harns, Wachs & Wachs (1950), who used New Hampshire cockerels, showed that the femur reached its maximum length by about 119 days. The evidence obtained from the present material is in close agreement with these earlier results, for the disappearance of the growth cartilage by 155 days must mean that rapid elongation will have ceased between 120 and 155 days, but the persistence of the hyaline part of the epiphysial cartilage until 190 days may allow for slight further elongation.

The cessation in the formation of woven bone, and the appearance of lictor-bundle bone, occurs between 85 and 120 days. This period is probably somewhat before the actual cessation of elongation, but a slowing of growth will almost certainly have occurred. It would seem that lictor-bundle bone formation only occurs in any amount when growth in length is very slow or has ceased, and furthermore this bone continues to be laid down for a considerable time after elongation has ceased, which means that the structure of the shaft continues to change after the apparent maturation of the bone. It will be recalled that the elastic fibres are found in the bone amongst the fibres of the lictor-bundle bone, and it is suggested that their presence indicates that there is an incorporation of the fibrous periosteum into the bone as the bone ceases to elongate.

Rapid elongation of the bone would appear to be necessary for the incorporation of the extra-osseous fibres, into its matrix, as is suggested by the normal growth pattern and by the fact that during prolonged starvation, when growth is severely retarded, there are no extra-osseous fibres incorporated into the bone and the fibres found in this bone differ from those in the bones of adults (Pratt & McCance, 1960). These effects upon the fibrous structure of the periosteal bone by the slowing down of the rate of elongation may well explain the formation of the neonatal sheath, when for a short period of time the incorporation of extra-osseous fibres is disturbed.

Perivascular bone

The vascular spaces within the walls of the embryonic diaphysis have no distinct fibrous lining. However, after hatching these and similar vascular spaces become reduced in their diameter by the deposition within them of longitudinally running and densely packed fibre bundles. The further reduction in the diameter of some of these primary osteones, especially the older ones, by a lining of hyaline matrix, is difficult to understand, and does not seem to have been observed in bone before. It is unlikely that they represent a preosseous zone as they are not found in areas where primary osteones are forming. It is likely, on the other hand, that they are in the nature of a wide resting line similar to those seen in severely dwarfed bones (Pratt & McCance, 1960).

Secondary osteones, which are perivascular bony structures separated from the surrounding bone matrix by a narrow crenated cement line, indicating that they have formed as a result of localized resorption of perivascular bone which has been followed by repair, are rarely seen in the material examined. The two types of fibrous structure seen within these secondary osteones require comment. Those osteones with a lamellar structure, which have also been described by Amprino & Godina (1947) in the phalanx of the ostrich, represent a continuation of endosteal osteogenesis along the perivascular spaces leading from the marrow into the cortex. While those osteones with dense coarse fibres, which appear to be similar to the osteones described by Amprino & Godina (1947) in the metatarsal of the stork, and by Amprino (1948) in the ossifying tendon of a bird, represent a continuation of the periosteal osteogenic process. Thus it would seem that the appearances of secondary osteones depends whether they are repaired by subperiosteal or medullary osteoblasts.

The perivascular structures seen in severely undernourished immature cockerels (Pratt & McCance, 1960) are not secondary osteones, even though they are limited by a cement line. These cement lines are smooth, very wide and are not sharply demarcated, that is they are resting lines, which indicate the cessation of deposition followed by the recommencement of perivascular osteogenesis.

A more extensive development of secondary osteones can occur as shown by Bloom *et al.* (1958) who described cortical erosions, resulting from the enlargement of the vascular channels, in calcium-deficient laying pullets. With their recovery there was a subsequent deposition of bone within the erosions resulting in extensive secondary osteone formation. Similar cortical erosions and their subsequent repair have been described in ducks and waders by Meister (1951), who ascribed these changes to moulting, and recently Zahnd (1954) described similar findings in moulting cocks and hens. However, Urist & Deutsch (1960), when examining fowl bones, found cortical erosion only in hens, and then only after prolonged egg production, and noted further erosion occurred with moulting; but these workers claimed that there was never any repair of these erosions. Though the repair of cortical erosions may fail, this was not the case in the birds examined here. Possibly erosions may have different causes or perhaps capacity for repair can be lost. While secondary osteones are found in the fowl long bone, they are not usually very much in evidence, and it is difficult to assess the significance of their more extensive occurrence in the bones of other birds as described by Foote (1916), Demeter & Mátyás (1928), Maj (1938), Amprino (1952), Amprino & Godina (1944) and Enlow & Brown (1957). Amprino & Godina (1947) pointed out that secondary osteones in birds were found in much greater numbers in the distal limb bones than in the femur.

SUMMARY

1. A brief account of the development and maturation of the fowl's femur is given.

2. The arrangement of fibre bundles in the bone matrix is described as seen following silver impregnation. Several distinctive types of bone are present.

3. Perichondrial bone contains short radially directed fibres in embryonic stages, but is more irregularly fibred in later stages.

4. Finely fibred woven bone is formed under the periosteum in embryonic and early postnatal stages.

5. Extra-osseous fibres are incorporated into bone and result in the imbricated appearance of the trabeculae.

6. A transient neonatal sheath is formed and consists of densely packed longitudinal fibres.

7. The reduction in the diameters of the vascular spaces occurs by means of the deposition of parallel and densely fibred bone. After some time these spaces are further reduced in diameter by a lining of fibreless matrix.

8. The late periosteal bone contains closely packed, longitudinally running lictor bundles, and after 120 days contains large numbers of elastic fibres.

9. Occasional secondary osteones are found in mature individuals, and are of two sorts, one of which is finely fibred and the other more coarsely fibred.

10. Endochondral osteogenesis continues for some distance into the metaphysis and thus consolidates the trabeculae.

11. As growth in length slows down, there is a deposition of endosteal lictor-bundle (and later lamellar) bone, which occurs throughout the medullary cavity.

12. The endosteal bone formed during the egg-laying cycle is irregularly woven.

13. The relation of periosteal osteogenesis to linear growth, and the significance of perivascular osteogenesis are discussed.

The encouragement of Prof. J. D. Boyd and Prof. R. A. McCance is gratefully acknowledged. The postnatal material was kindly provided by Prof. R. A. McCance and the support of the Medical Research Council is acknowledged. Mr and Mrs R. A. Parker provided technical assistance, and the photography was undertaken by Mr T. M. Crane.

REFERENCES

Amprino, R. (1948). A contribution to the functional meaning of the substitution of primary by secondary bone tissue. *Acta anat.* **5**, 291–300.

Amprino, R. (1952). Rapporti fra processi di ricostruztione e distribuzione dei minerali nelle ossei. *Z. Zellforsch.* **37**, 144–183, 240–273.

Amprino, R. & Godina, G. (1944). Observazioni sui processi di rimaneggiamento strutturale della sostanza compatta delle ossa lunghe di Uccelli corridori. *Anat. Anz.* **95**, 191–214.

Amprino, R. & Godina, G. (1947). La struttura delle ossa nei vertebrati. *Comment. pontif. Acad. Sci.* **11**, 329–462.

Bloom, M. A., Domm, L. V., Nalbandov, A. V. & Bloom, W. (1958). Medullary bone of laying chickens. *Amer. J. Anat.* **102**, 411–453.

Buckner, G. D., Insko, W. M., Harns, A., Wachs, H. F. & Wachs, E. F. (1950). The comparative rates of growth and calcification of the femur, tibia and metatarsus bones of the male and female New Hampshire chicken having straight keel. *Poult. Sci.* **29**, 332–335.

DEMETER, G. & MÁTYÁS, J. (1928). Mikroskopisch vergleichend-anatomische Studien an Röhrenknochen mit besonderer Rucksicht auf die Unterscheidung menschlicher und tierischer Knochen. *Z. ges. Anat.* 1. *Z. Anat. EntwGesch* **87**, 45–99.

EBNER, V. VON (1875). Über den feineren Bau der knochensubstanz. *S.B. Akad. Wiss. Wien*, **72** (*Abt.* 3), 49–138.

ENLOW, D. E. & BROWN, S. O. (1957). A comparative histological study of fossil and recent bone tissues. Part II. *Texas J. Sci.* **9**, 166–214.

FELL, H. B. (1925). The histogenesis of cartilage and bone in the longbones of the embryonic fowl. *J. Morph.* **40**, 417–459.

FOOTE, J. S. (1916). A contribution to the comparative histology of the femur. *Smithson. Contr. Knowl.* **35** (3), 1–242.

GEGENBAUR, C. (1867). Über die Bildung des Knochengewebes. II. mittelung. Jena. *Z. Naturf.* **3**, 206–246.

GROSS, W. (1934). Die typen des mikroskopischen Knochenbaues bie fossilen Stegocephalen und Reptilien. *Z. ges. Anat.* 1. *Z. Anat. EntwGesch*, **103**, 731–764.

HAINES, R. W. (1942). The evolution of epiphyses and of endochondral bone. *Biol. Rev.* **17**, 267–292.

JOHNSTON, P. M. (1958). Autoradiographic studies of the utilization of Ca^{45} by the chick embryo. *J. biophys. biochem. Cytol.* **4**, 163–168.

KOELLIKER, A. (1873). *Die normale Resorption des Knochengewebes und ihre Bedeutung für die Entstehung der typischen Knochenformen.* Leipzig: F. C. W. Vogel.

LATIMER, H. B. (1927). Postnatal growth of the chicken skeleton. *Amer. J. Anat.* **40**, 1–57.

MAJ, O. (1938). Singolare struttura de tessuto osseo in Gallus gallus adulto e vecchio. *Monit. zool. ital.* **48** (suppl.), 140–147.

MEISTER, W. (1951). Changes in histological structure of the long bones of birds during the moult. *Anat. Rec.* **111**, 1–21.

POLICARD, A. (1941). Sur les typis d'ossification au cours du développement des os longs chez les Oiseaux. *C.R. Soc. Biol., Paris*, **135**, 963–965.

PRATT, C. W. M. (1957). Observations on osteogenesis in the femur of the foetal rat. *J. Anat., Lond.*, **91**, 533–544.

PRATT, C. W. M. (1959). Postnatal changes in the shaft of the rat's femur. *J. Anat., Lond.*, **93**, 309–322.

PRATT, C. W. M. & MCCANCE, R. A. (1960). Severe undernutrition in growing and adult animals. 2. Changes in the long bones of growing cockerels held at fixed weights by undernutrition, *Brit. J. Nutr.* **14**, 75–84.

URIST, M. R. & DEUTSCH, N. M. (1960). Osteoporosis in the laying hen. *Endocrinology*, **66**, 377–391.

WEIDENREICH, F. (1923). Knochenstudien. *Z. ges. Anat.* 1. *Z. Anat. EntwGesch.* **69**, 382–466, 558–597.

WEIDENREICH, F. (1930). Das knochengewebe. In *Handbuch der mikroskopishen Anatomie des Menschen* (ed. W. van Mollendorff), Teil 2. Berlin: Julius Springer.

WHISTON, G. C. (1940). A histological study of the growing avian femur (*Gallus domesticus*) following experimental dislocation of the hip. *Anat. Rec.* **76**, 499–521.

WOLBACH, J. B. & HEGSTED, D. M. (1952). Endochondral bone growth in the chick. *Arch. Path.* (*Lab. Med.*), **54**, 1–12.

ZAHND, J. P. (1954). Sur les modifications histologiques du squelette des oiseaux pendant la mue. *C.R. Soc. Biol., Paris*, **148**, 1491–1493.

EXPLANATION OF PLATES

PLATE 1

Fig. 1. Transverse section of a portion of the diaphysis of the femur from a 15-day-old cockere showing the vascular spaces in the bone, and the neonatal sheath separating the inner bone formed during embryonic life from the outer bone formed after hatching. Long's method. (×120.)

Fig. 2. Transverse section of a portion of the diaphysis of the femur from a cockerel aged 29 days. Note the trabeculae of bone forming under the periosteum and the conversion of these into

perivascular structures. The neonatal sheath has disappeared by this stage. Long's method (× 81.)

Fig. 3. Transverse section of a portion of the diaphysis of the femur from a cockerel aged 246 days. Showing from the internal surface outwards, the lamellar endosteal bone separated by a cement line from the woven bone containing numerous primary osteones and a single secondary osteone, and the outer densely fibred lictor-bundle bone. Long's method. (× 125.)

PLATE 2

Fig. 4. Longitudinal section of the diaphysis of the femur from a 17-day-old embryonic fowl. Showing the perichondrial bone immediately adjacent to the hypertrophic cartilage of the diaphysis. The finely fibred early embryonic woven bone is seen to be continuous with the perichondrial bone. Long's method. (× 780.)

Fig. 5. Longitudinal section of the diaphysis of the femur from a cockerel aged 15 days (compare with fig. 1). Note the appearance of the neonatal sheath and the obliquely running fibre bundles whose courses are interrupted by the sheath. Long's method. (× 270.)

Fig. 6. Longitudinal section of the peripheral portion of the diaphysis of the femur from a cockerel aged 155 days, showing the lictor-bundle bone. Long's method. (× 780.)

Fig. 7. Transverse section of the peripheral portion diaphysis of the femur from a cockerel aged 379 days (compare with fig. 6) showing the lictor-bundle bone. Long's method. (× 330.)

Fig. 8. Longitudinal sections of the diaphysis of the femur from a cockerel aged 246 days, showing the elastic fibres present on the outer part of the cortex. Weigert's elastin stain. (× 180.)

Fig. 9. Transverse section of the diaphysis of the femur from an adult hen showing the elastic fibres. Compare with figs. 3 and 8. Weigert's elastin stain. (× 180.)

Fig. 10. Transverse sections of the diaphysis of the femur from a cockerel aged 29 days, showing the perivascular arrangement of fibres. Compare with fig. 2, which shows the more rapidly growing surface. Long's method. (× 330).

PLATE 3

Fig. 11. As fig. 10 at greater magnification showing the hyaline lining to the vascular spaces. Long's method. (× 1692.)

Fig. 12. Longitudinal section of the metaphysis of the femur from a cockerel aged 29 days, showing the endochondral bone which contains numerous osteocytes and surrounds islands of unresorbed hypertrophic cartilage. Long's method. (× 780.)

Fig. 13. Transverse section of the diaphysis of the femur from a cockerel aged 379 days, showing a large secondary osteone with a lamellar fibrous structure. Long's method. (× 330.)

Fig. 14. Transverse section of the diaphysis of the femur from a cockerel aged 249 days, showing a secondary osteone containing coarse fibre bundles running in the longitudinal axis of the osteone. Note the numerous coarse tendon fibre bundles in the surrounding woven bone. Long's method. (× 360.)

Fig. 15. Transverse section of the diaphysis of the femur from a cockerel aged 249 days, showing the lamellar fibrous structure of the endosteal bone. Long's method. (× 780.)

Fig. 16. Transverse section of the diaphysis of the femur from an adult hen, showing the fibrous structure of the intramedullary trabeculae of 'egg-laying' bone. Long's method. (× 330.)

Key to lettering

c = cement line; *e* = endosteal bone; *el* = elastic fibres; *h* = hypertrophic cartilage; *hl* = hyaline lining; *l* = lictor-bundle bone; *la* = lacuna; *m* = marrow cavity; *n* = neonatal sheath; *p* = fibrous periosteum; *pb* = perichondrial bone; *po* = primary osteone; *so* = secondary osteone; *t* = subperiosteal trabecula; *v* = vascular space; *w* = woven bone.

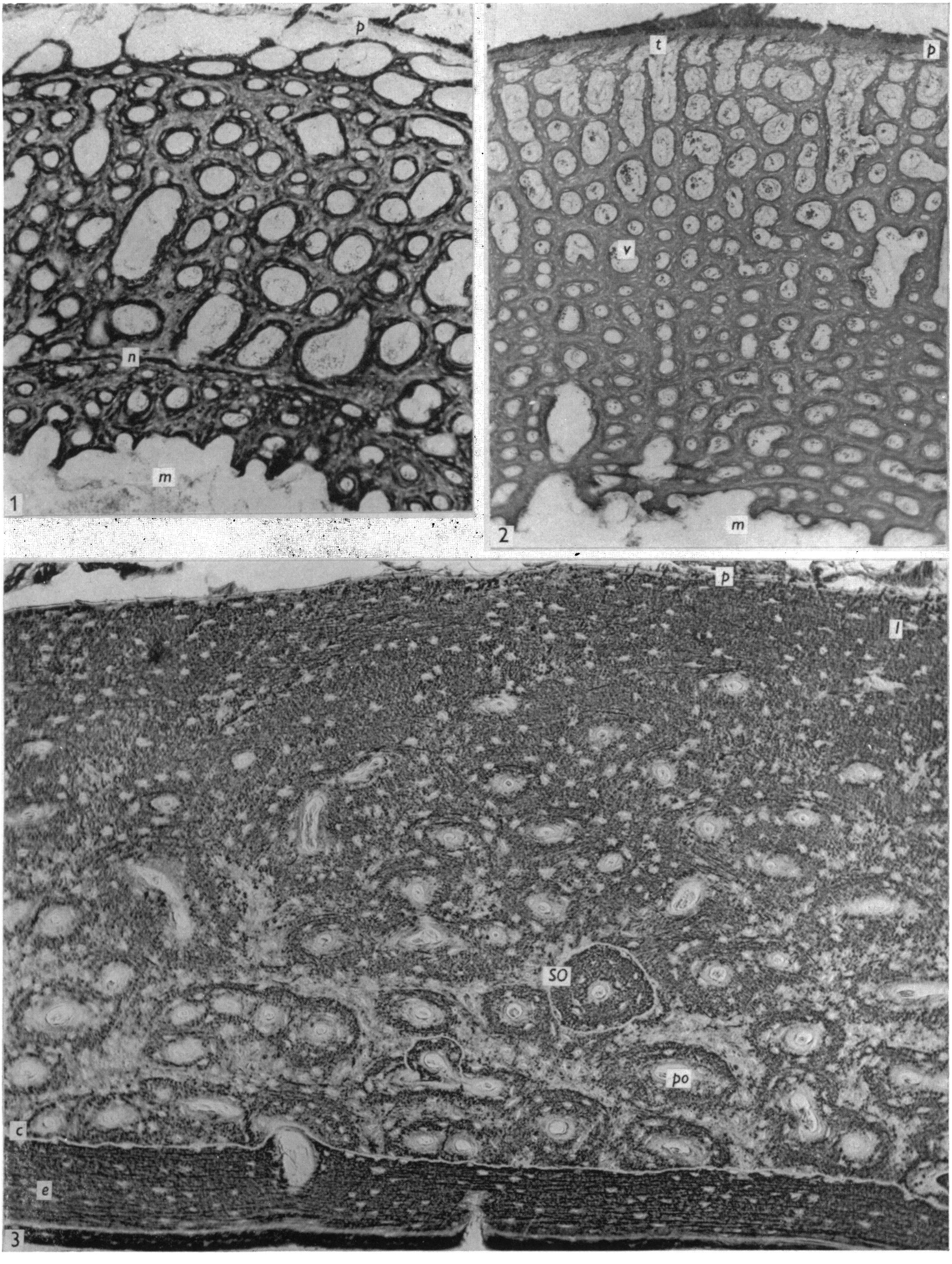

PRATT—Effect of age on the arrangement of fibres

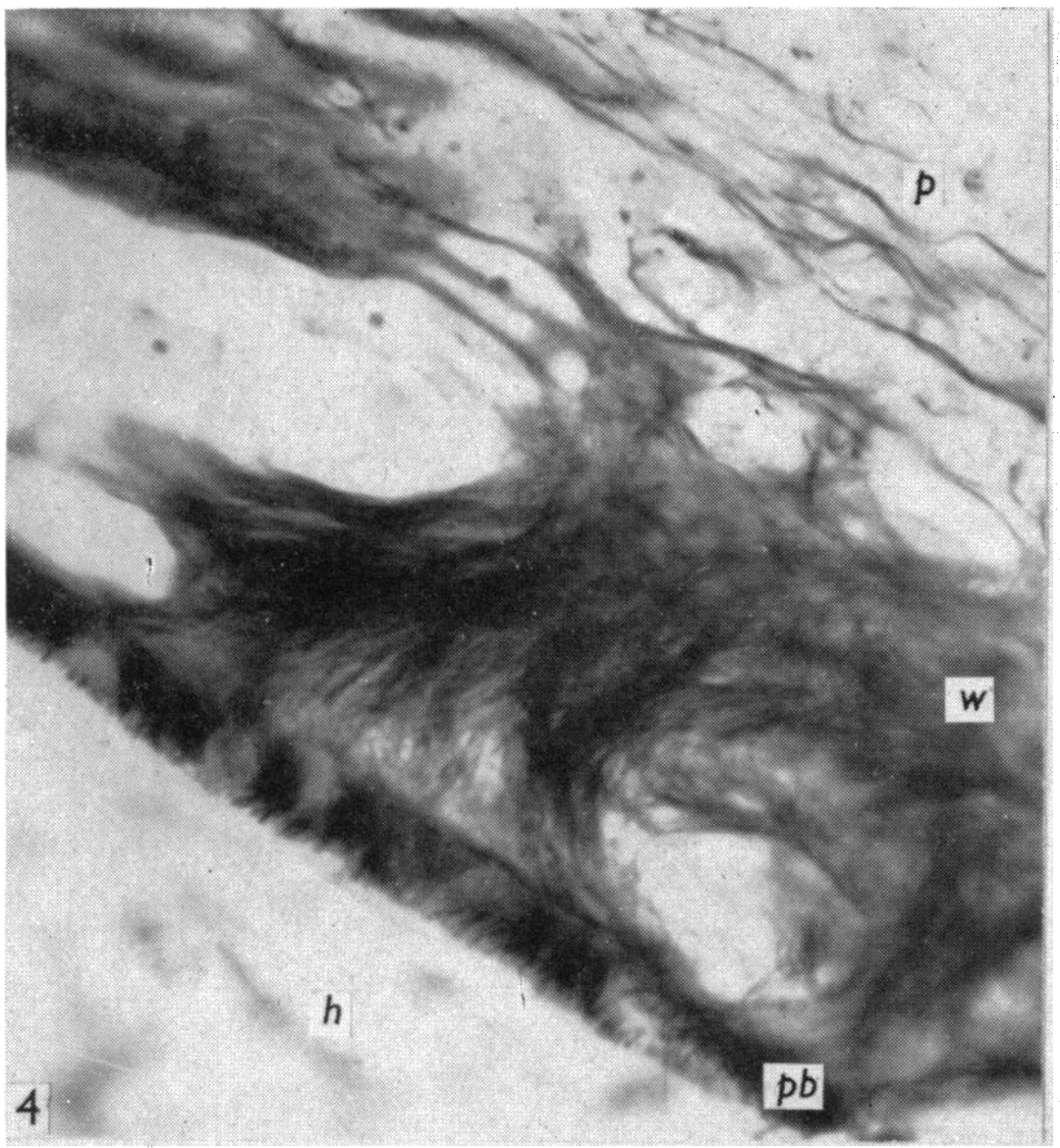

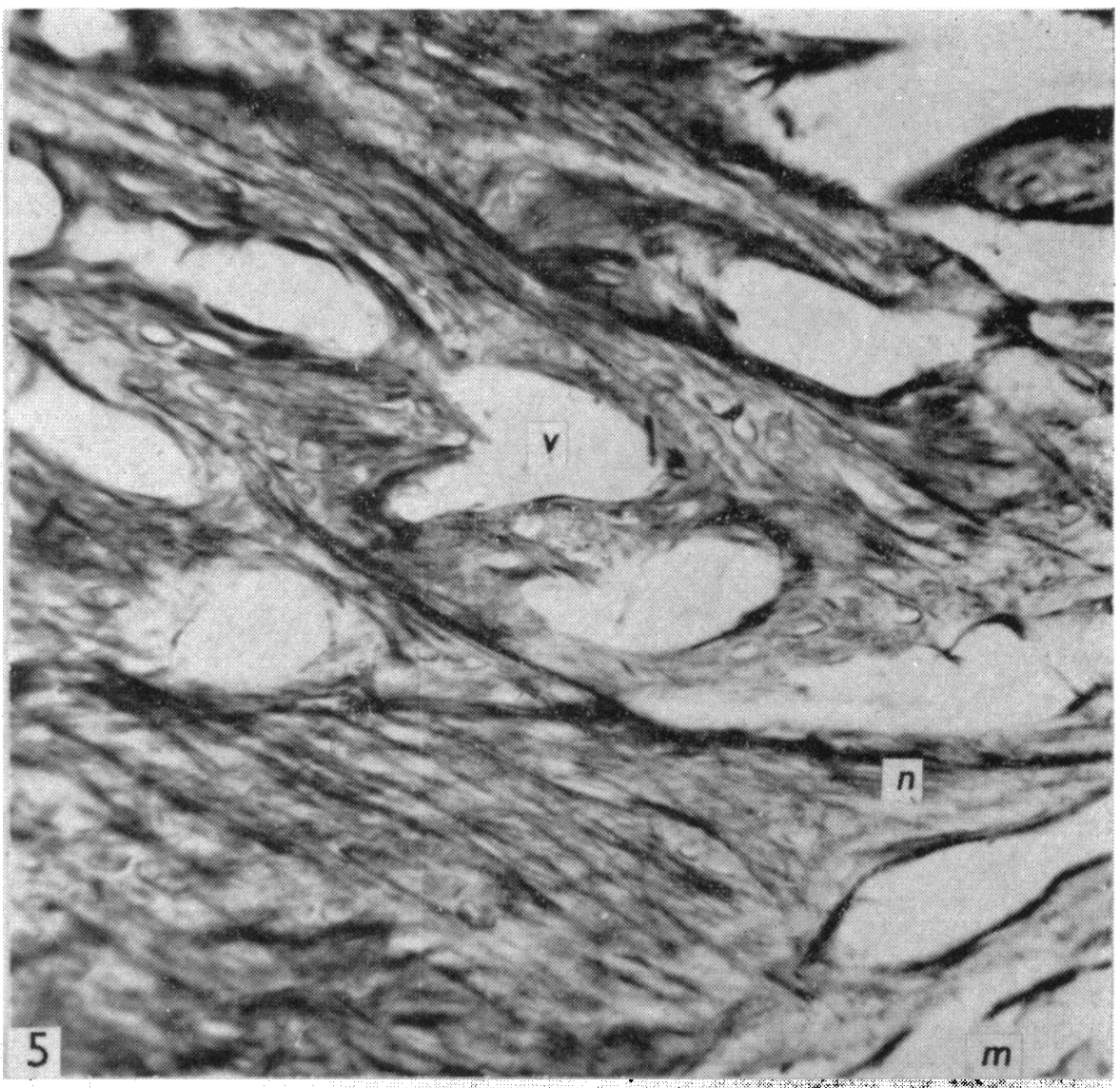

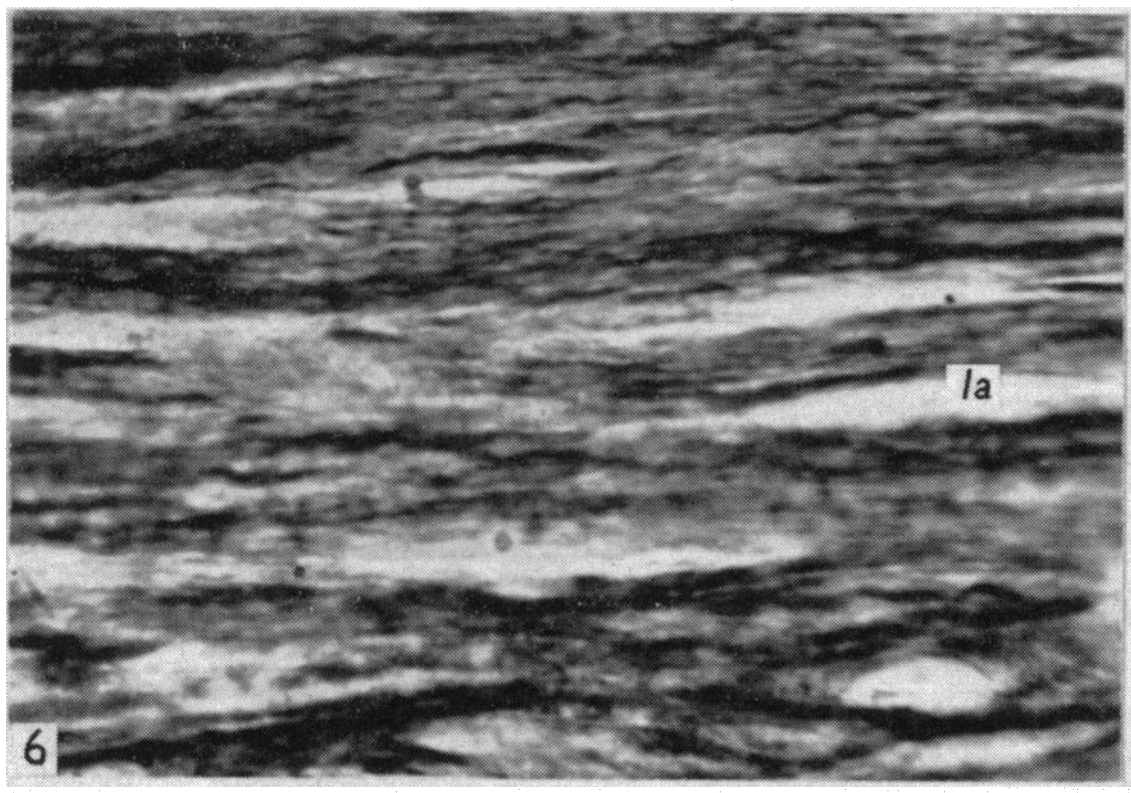

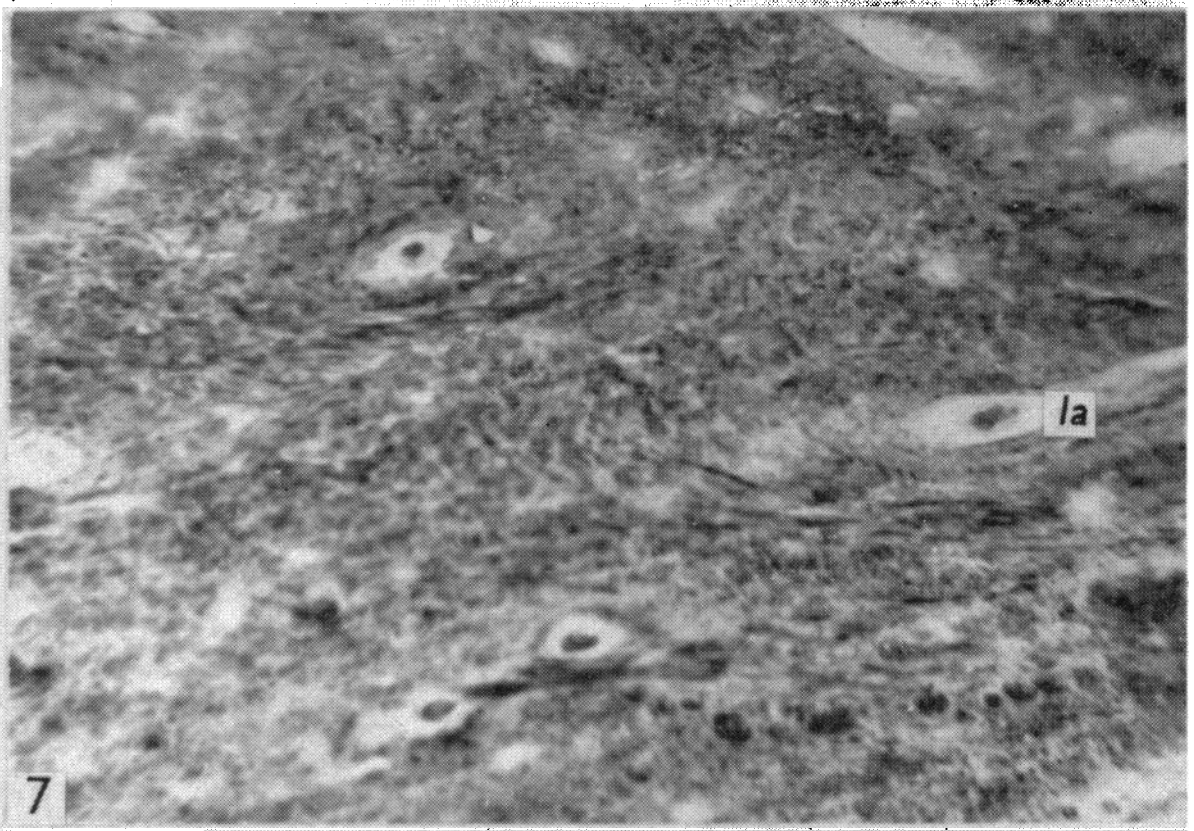

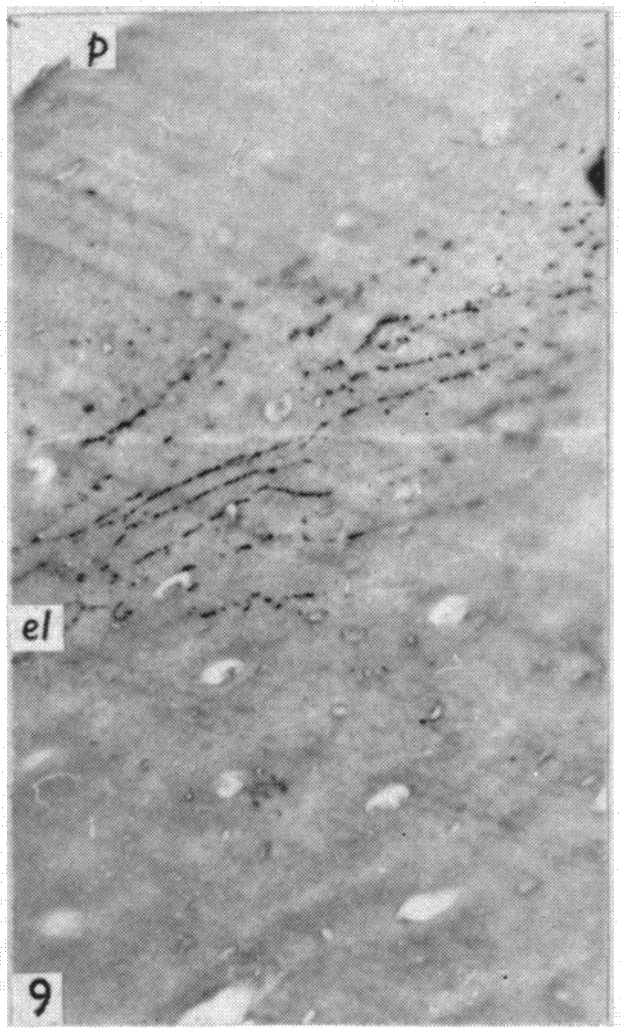

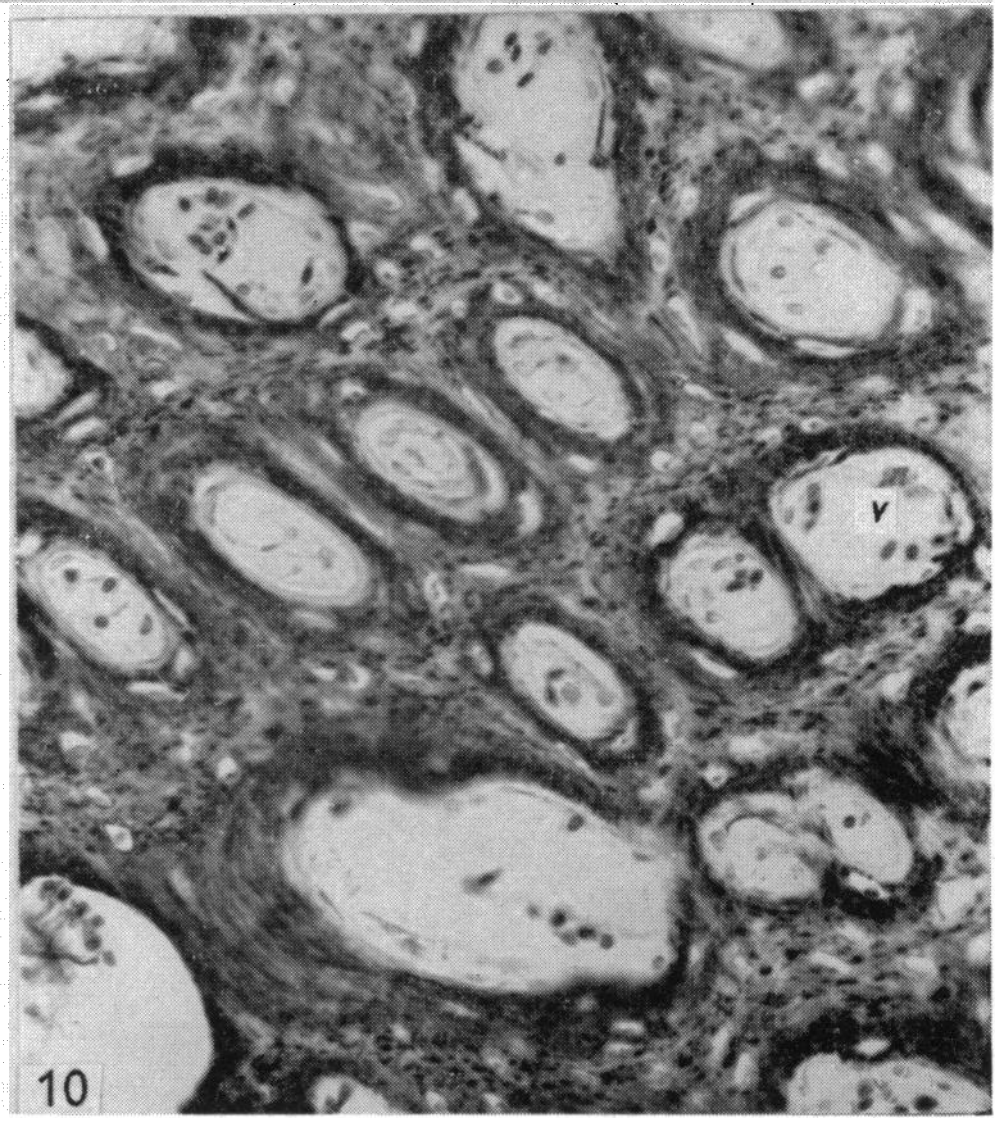

PRATT—EFFECT OF AGE ON THE ARRANGEMENT OF FIBRES

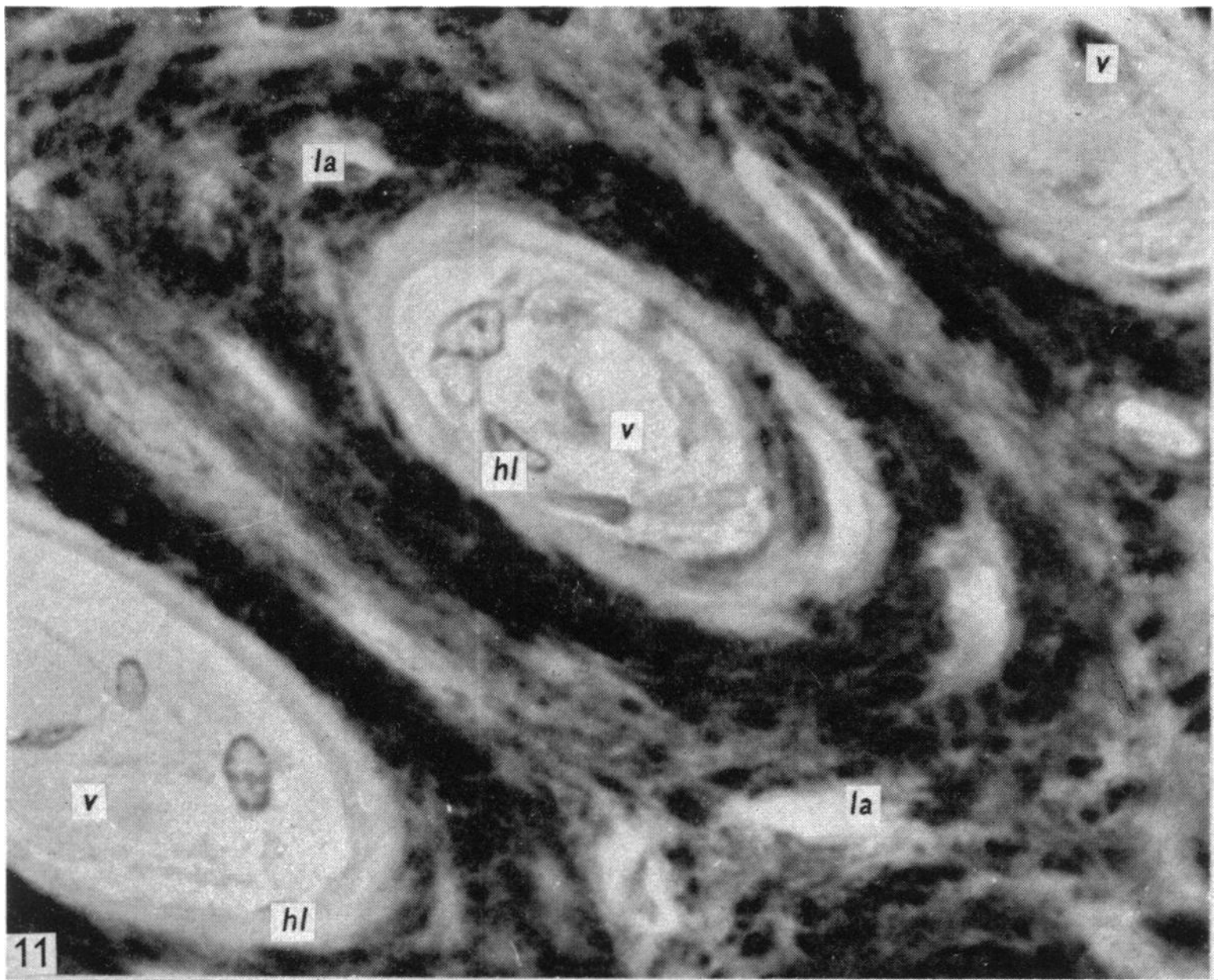

11

12

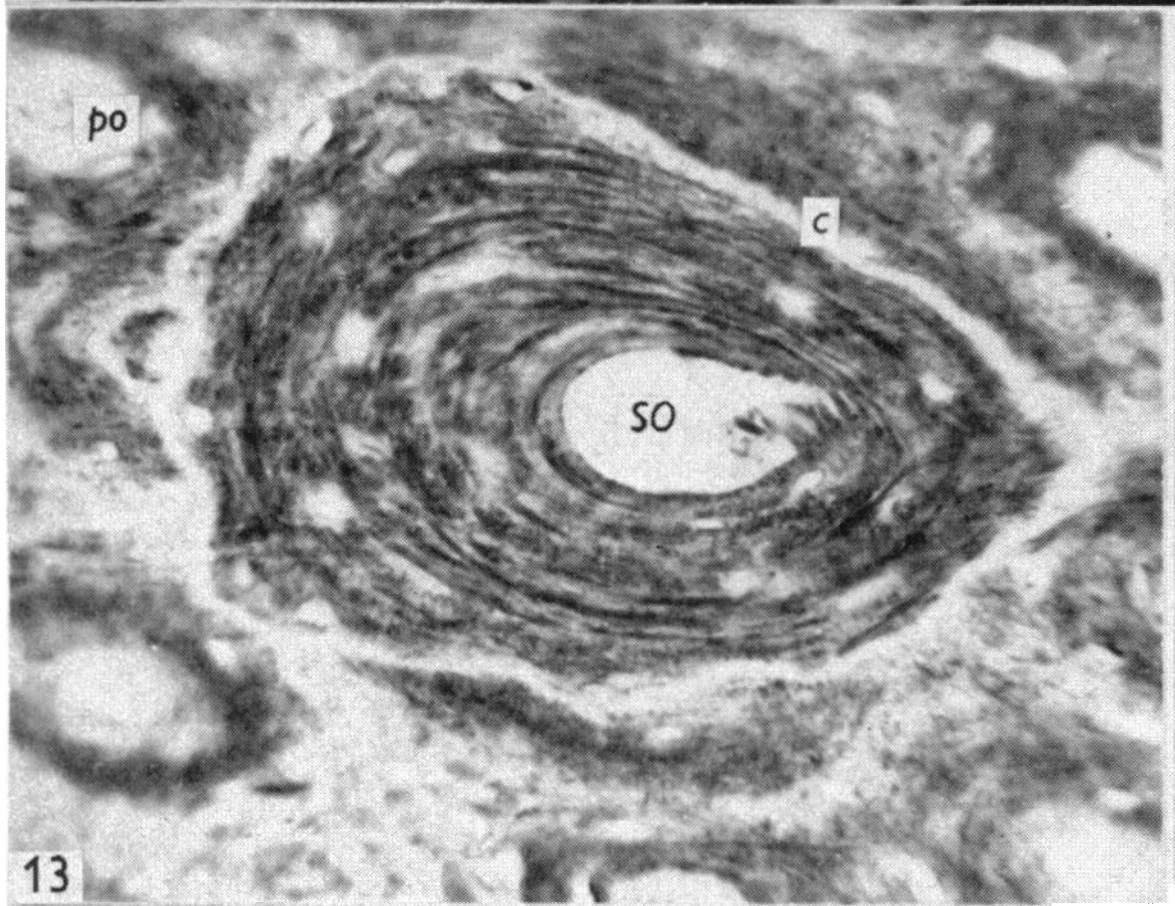

13

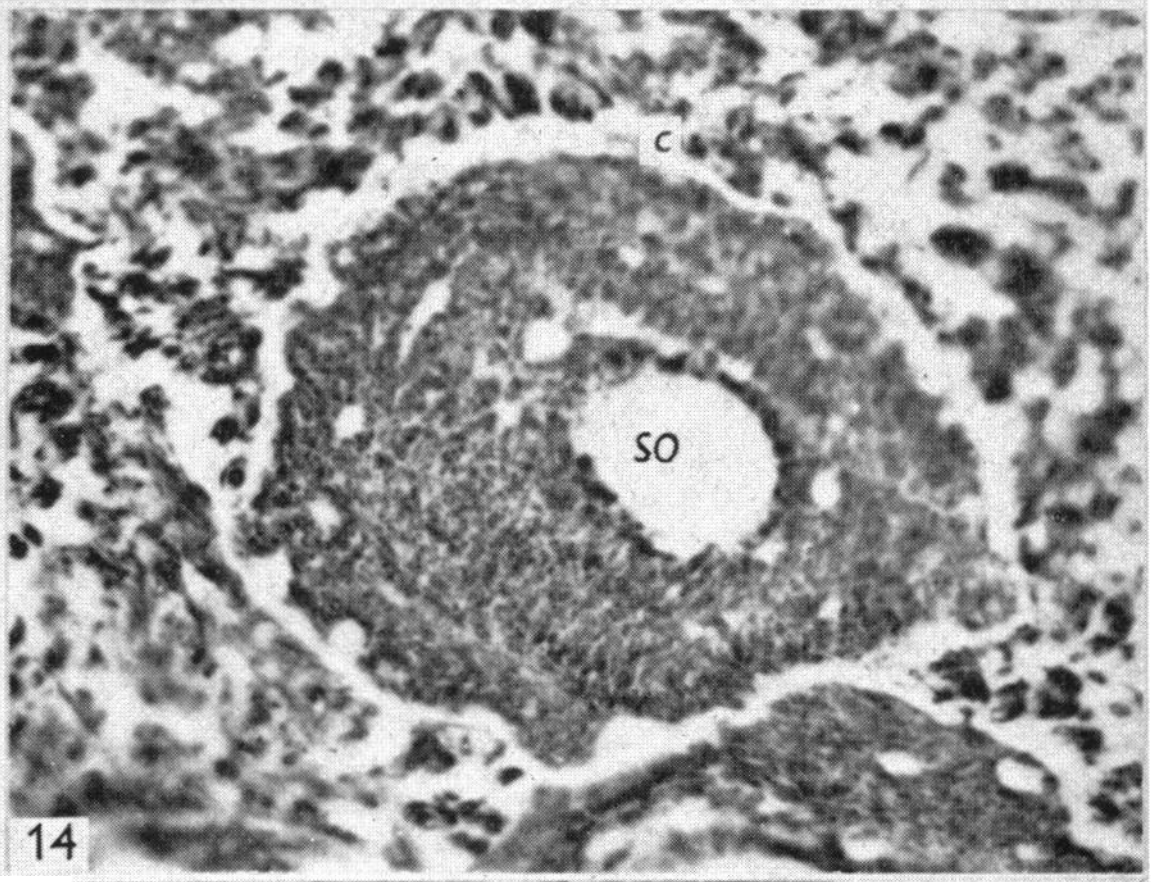

14

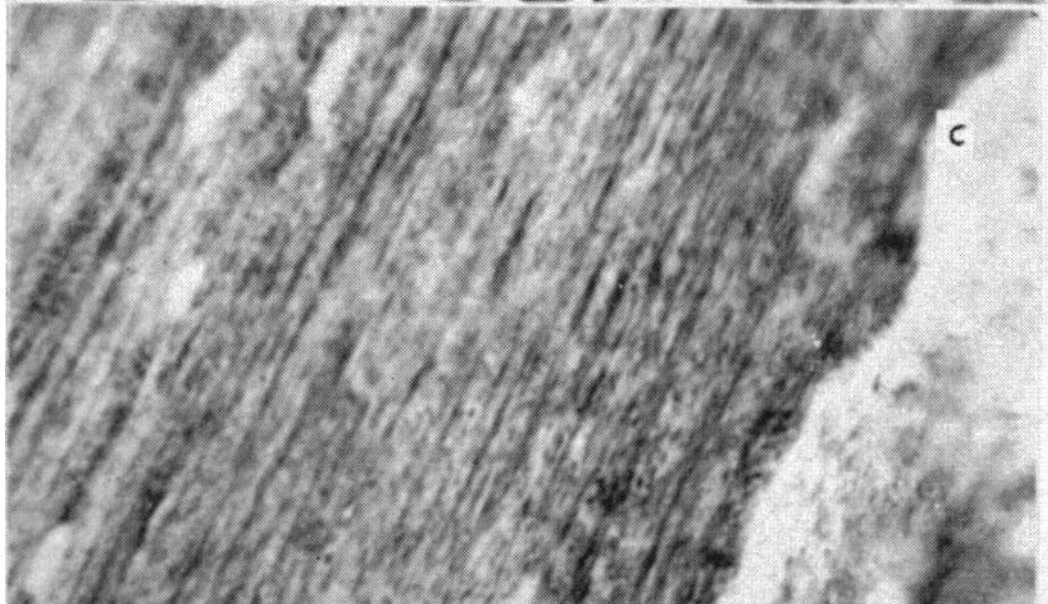

15

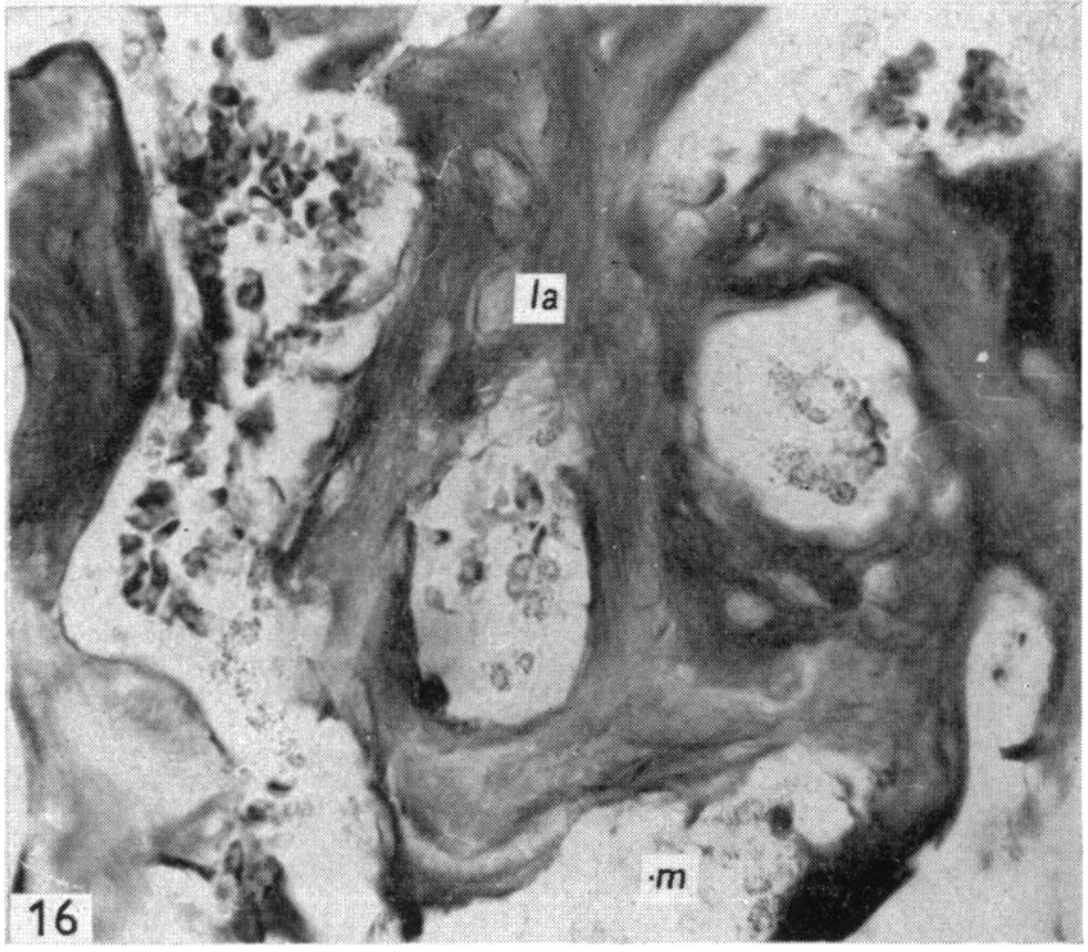

16

PRATT—EFFECT OF AGE ON THE ARRANGEMENT OF FIBRES