

QUANTITATIVE ANALYSIS OF CELL TYPES IN MAMMALIAN NEO-CORTEX*

By N. L. MITRA†

Department of Anatomy, University College, London

INTRODUCTION

The classification of neurons into various morphological types has played an important part in the investigation of the structural organization of the cerebral cortex. Such classifications have mainly been based on various modifications of the Nissl and Golgi methods of staining. Using the Nissl method, which stains the cell body and the proximal parts of the larger dendrites of a neuron only, the cortical neurons have been classified, usually into pyramidal, granular and fusiform types, by a number of investigators; to mention only a few of the more recent, Economo & Koskinas (1925), Ngowyang (1937) and Walker (1940). A classification by this method cannot be regarded as satisfactory since only the shapes of the cell bodies are considered while the dendritic and axonal organization is ignored.

Using his own method of staining and on the basis of the axonal ramification, Golgi classified the neurons into two primary groups, type I and type II cells; he further subdivided each group into pyramidal, fusiform and polygonal or stellate types depending on the mode of origin and ramification of the dendrites from the perikaryon. This plan was elaborated by subsequent workers, and at least sixty different types of neurons have been recognized in the cortex of mouse (Lorente de Nó, 1922). Although the value of such qualitative descriptions cannot be denied, adequate information on the relative proportions of the cell types and their precise mode of distribution in the cortex is lacking. For example, the structure of the human visual cortex is apparently fundamentally the same as that of the mouse with regard to the diversity of the cell types (Lorente de Nó, 1934), but a quantitative analysis may, nevertheless, reveal striking differences. Such a quantitative method is clearly valuable for comparing not only the organization of different cortical zones of the same species of animals but also of similar areas in animals of different habits.

The present paper gives estimates of the proportions of cells with various shapes that appear in different parts of the cortex. In Golgi-Cox preparations three different groups of neurons with distinctive types of dendritic organization can be recognized. In one group (the pyramidal cells) each neuron possesses a long apical dendrite and several basal ones, in the second group (stellate cells) the dendrites originate from all parts of the surface of the perikaryon while the third, forming

* This work was the subject of a dissertation approved for the degree of Ph.D. in the University of London and was aided by grants from the Rockefeller Foundation and the State of Bihar, India. The thesis contains the full statistical data which form the basis of the present paper.

† Present address: Department of Anatomy, Medical College, Darbhanga, Bihar, India.

a small minority, consists of fusiform neurons with a dendrite originating from each pole of the cell body. These cell types are not arranged at random but show patterns of distribution varying in different zones of the cortex.

MATERIAL AND METHOD

Animals and functional areas

Three cats, four rabbits and one monkey (*Macaca mulatta*) were used for observations on adult animals. A limited investigation was also made on the visual area of two young rabbits, 10 and 17 days old, on one kitten 6 weeks old and on the prefrontal cortex of a human subject taken at lobotomy. Of the twenty-six sets of observations, six were on the visual, four on the motor and two on the somato-sensory areas of cats, eight on the visual area of rabbits, two each on the visual and motor areas of monkey (*Macaca*) and one each on the parastriate area of monkey and the prefrontal cortex of man.

Although the histological localization of most of the functional areas on which the present observations were made is fairly easy and accurate, the visual area of rabbits and the somato-sensory area of cats provided some difficulty. The cyto-architectural maps compiled by various authors show considerable differences in the localization of these two areas. Hence, the results of stimulation, ablation and other electro-physiological experiments were also considered when the areas for the present investigation were identified. Only that region within a functional area of the cortex was selected for observation over which the results obtained by the different methods, histological and physiological were in accord.

Block staining by a modification of the Golgi-Cox method was adopted (Sholl, 1953).

Criteria for classification of neurons

The neurons have been classified into pyramidal, stellate and fusiform or spindle-shaped types, depending on the shape of the cell bodies and on the mode of origin and course of the dendrites. This classification does not in any way take into account the axons of the neurons. Consequently, all the three types of neurons include both Golgi type I and Golgi type II cells.

A typical pyramidal cell is defined as a neuron possessing a conical perikaryon with apical and basal dendrites. The apical dendrite is directed towards the pial surface; it may or may not reach the molecular layer but usually extends for a greater distance than the basal dendrites and is also generally thicker at its origin. The basal dendrites originate from the basal angles and the basal surface of the perikaryon and extend horizontally or obliquely upwards and downwards. The lateral surfaces of the perikaryon, extending between the apical and the basal angles, are devoid of dendrites and this criterion together, with the presence of an apical dendrite, forms a very important distinguishing characteristic of a pyramidal cell. In some cases the perikaryon of a pyramidal cell, instead of being conical, is of ovoid shape and hence does not possess a lateral angle. In such cases, the basal dendrites originate from the basal surface and the lower half of the lateral surface of the cell body, leaving the upper half or more free of dendrites.

Besides these typical cells, certain variations are met with. Thus the large pyramidal cells, such as the Betz cells and the solitary pyramidal cells of Meynert, sometimes possess a few dendrites that originate from the lateral surfaces of conical perikarya, but the configuration of such neurons as a whole leaves no doubt of their pyramidal nature. Another type of pyramidal cell possesses a relatively fine and short apical dendrite, but the cell body is conical and the absence of dendrites on its lateral surfaces renders the classification easy. Sometimes a pyramidal cell is orientated in an inverted manner, that is to say, the 'apical' dendrite is directed towards the white matter of the cortex and the basal surface with its dendrites is directed towards the pial surface of the cortex.

Stellate cells possess spherical, ellipsoidal or polygonal perikarya. The dendrites originate from all parts of the surfaces of the cell body and ramify uniformly around it. Usually all the dendrites are of uniform size at their origin and their lengths are almost the same. In exceptional cases, however, the dendrite directed towards the pial surface of the cortex runs for a longer distance and is appreciably thicker than the rest of the dendrites.

The fusiform cells are situated with their long axes usually parallel but occasionally vertical to the pial surface. They are bipolar and one dendrite originates from each pole of the cell body.

As the results will show, it is possible in this way to classify nearly but not quite all the cells of the cortex; a few are more complex and do not come under any of the three categories. Certain technical limitations also render some of the cells unclassifiable; in the course of sectioning, a few of the cells lose their processes in such a way as to make classification difficult and sometimes the neurons are partially superimposed on each other. In other cases the ramifications of the dendrites of a neuron obscures the details of an adjacent one. About 15–20 % of the neurons in some of the samples had to be left unclassified, but it must be emphasized that neurons possessing shapes other than the three main types formed only a small fraction of these cases.

Method of observation

On the basis of these criteria the neurons within a strip of cortex belonging to any one of the cortical areas studied were typed and their vertical distances from the pial surface measured. The positions of all the unclassified neurons were noted in order to determine whether they were distributed at any particular depth of the cortex. Owing to the selectivity of the staining method the number of neurons stained per unit volume of cortex varies in different animals and results expressed in terms of the absolute numbers of the various cell types would obviously be misleading. The purpose of the present analysis was, therefore, to determine the mode of distribution of the various cell types and their relative proportions only; consequently, no attempt was made to maintain a constancy in the width of the various strips within which the counts were made. A sample of about 300–350 neurons was considered adequate for each set of observations. In the motor area of the various animals and in the visual area of young animals, however, the cell density in the stained preparations is always rather poor and a sample of 300 cells could not be

taken without the risk of a part of it being obtained from a different functional area. In such cases, each sample had to be reduced to about 200 cells.

The portions of cortex for examination were restricted to those having a relatively plane pial surface, since the measurement of the vertical distances of the neurons below the pial surface over a wide zone of the cortex possessing a sharp curvature cannot be made without considerable error and the shapes of the neurons at highly curved regions of the cortex are altered as a result of mechanical factors.

The vertical distance of a neuron from the pial surface was measured between the deeper surface of the pia mater and the upper edge of the perikaryon of the neuron. The constriction usually present at the beginning of a dendrite was accepted as the limit of the perikaryon. In some cases, however, no such constrictions are present and the cell body tapers gradually to be continued into a dendrite. In such cases, the decision had to be arbitrary.

It was found that the unclassified cells have no special zones of concentration in the cortex. The fusiform cells are very few in number. The pyramids and the stellates form the two main cell types (according to this mode of classification) and constitute the main features of interest. Their patterns of distribution have been examined by the construction of superimposed histograms representing the frequency of each cell type in 100 μ depth strips below the pial surface of the cortex; the relative proportion of each variety of neurons has been expressed as a percentage of the total number of classified neurons.

Statistical considerations

The Golgi-Cox method of staining is highly selective, and the selectivity is known to vary from animal to animal as evidenced by the number of cells stained per unit volume of the cortex. Moreover, this variation may not be uniform over the whole depth of the cortex. A preference for a particular cell type in some localized regions might lead to an apparent change in the patterns of distribution and the relative proportions of the various cell types. The need for a statistical method for testing the consistency of the results becomes obvious.

The distribution of the cells in 100 μ depth strips below the pial surface in various samples from the same functional area of animals belonging to the same species was tested for consistency by the χ^2 method. The samples from the same animal proved to be always consistent, but those from different animals were slightly but significantly different. However, examination of the actual frequency distributions of the pyramidal and stellate cells and the contributions made by the different groups to the total value of χ^2 show that the differences are not due to any general changes in the form of the distributions but rather to slight differences at one or two depths only. The relative proportions of the two cell types differ only slightly in different animals of the same species (Table 1). There is thus reason to think that in this series variations in the selectivity of the staining do not cause any serious differences either in the manner of distribution or in the relative proportions of the pyramidal and stellate cells in a particular functional area of animals within the same species.

RESULTS

The visual area of Macaca

The distribution of the various cell types were examined in strips 100 μ wide taken throughout the depth of the cortex in two samples from the same animal. The unclassified cells form about 16–20% of the total number of the neurons counted. They are, however, randomly distributed throughout the depth of the cortex, and

Table 1. *Relative proportions of the cell types in certain cortical areas of different mammals*

Animal and area		Cell types expressed as percentages of the total number of classified neurons		
		Pyramidal	Stellate	Fusiform
Monkey visual	4a	54	44	2
	4b	51	47	2
Cat visual	190a	62	34	5
	190b	63	34	3
	190c	57	37	6
	236	63	33	5
	307	61	37	2
	244 (6 weeks)	66	31	3
Rabbit visual	2366a (adult)	66	32	2
	2366b (adult)	69	28	3
	2357a (adult)	65	32	3
	2357b (adult)	64	32	4
	2436 (adult)	69	29	2
	2487 (adult)	65	30	6
	2303 (17 days)	74	23	3
	2557 (10 days)	85	13	2
Cat somatosensory	307a	64	35	1
	307b	62	36	2
Monkey motor	4a	75	21	4
	4b	73	23	4
Cat motor	273a	84	10	6
	273b	86	8	6
	265a	86	8	5
	265b	84	12	5
Human prefrontal	—	72	26	2

their proportion varies with the density of neurons at each depth strip. The fusiform cells, on the other hand, form an insignificant proportion accounting for only 2% of the total number of classified neurons. The pyramids and the stellates therefore form the main cell types and, as the two samples were found to be statistically consistent, the distributions have been added together and superimposed histograms constructed (Tables 1 and 2, and Fig. 1).

The pyramids are mainly distributed in the upper and the lower thirds of the cortex, whereas the stellate cells are mainly concentrated in its middle one-third; within a zone of about 700 μ (600 μ –1300 μ below pial surface) they are more numerous than the pyramidal cells. For convenience of assessment of the relative proportions of these two cell types at different levels, the cortex of areas showing such a specific distribution of stellate cells has been arbitrarily divided into three zones, a 'stellate zone' where there are more of these cells than pyramids, a 'supra-

stellate zone' lying above and an 'infra-stellate zone' lying deep to the stellate zone, both of which contain more pyramids than stellates. There are very few stellate cells in the supra- and infra-stellate regions of the visual cortex of the monkey and they form only 9 and 8 % respectively of the total number of these two cell types in these regions. Moreover, the peak of the stellate cell distribution reaches a higher level than that of the pyramids, and stellate cells form an average of about 45 % of the total number of classified neurons (Table 2).

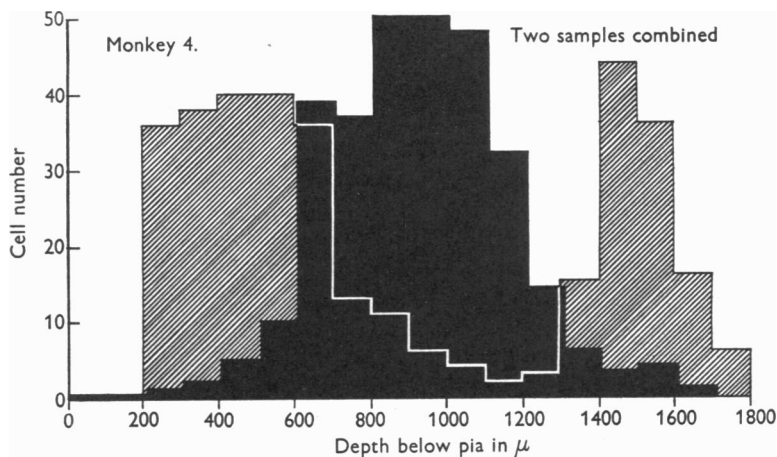


Fig. 1. Distribution of pyramidal and stellate cells in the visual cortex of *Macaca*. Shaded area: distribution of pyramidal cells. Black area: distribution of stellate cells.

Table 2. *Relative percentages of the cell types in various cortical areas of different mammals*

Animal and area	Cell types expressed as percentages of total number of classified neurons		
	Pyramidal	Stellate	Fusiform
Rabbit visual (adult)	66.0	31.0	3.0
Cat visual (adult)	60.0	35.0	5.0
Monkey visual (adult)	52.0	45.0	3.0
Cat somatosensory (adult)	63.0	35.0	2.0
Monkey motor (adult)	74.0	22.0	4.0
Monkey parastriate (adult)	66.0	29.0	5.0
Cat motor (adult)	85.0	9.0	6.0
Human prefrontal (adult)	72.0	26.0	2.0
Kitten visual (6 weeks)	66.0	31.0	3.0
Rabbit visual (17 days)	74.0	23.0	3.0
Rabbit visual (10 days)	85.0	13.0	2.0

The visual area of the cat

The proportion of unclassified cells varied from 3 to 13 %, distributed without any preference for any particular depth of the cortex. The samples from the different adult animals show only minor variations in the distribution of the cell types, mainly owing to thickness differences in the depth of cortex and slight variations in the zone of the stellate cell concentration. The histograms in Fig. 2 show that the patterns of stellate and pyramidal cell distributions are similar in the three adult

cats. χ^2 tests showed the presence of significant differences but these are not of great magnitude (Table 1).

The stellate cells are concentrated in the middle of the cortex over a zone of 400–500 μ thick and slightly narrower than that found in the monkey (700 μ in the latter). This concentration is attained more gradually and the stellate cells form on the average, about 15 % of the total number of cells in the 'suprastellate' zone. The peak of the stellate cell distribution does not generally exceed that of the pyramids but both are nearly of the same height. The stellate cells form an average of 85 % (Table 2), this is significantly less than in the case of the monkey (45 %).

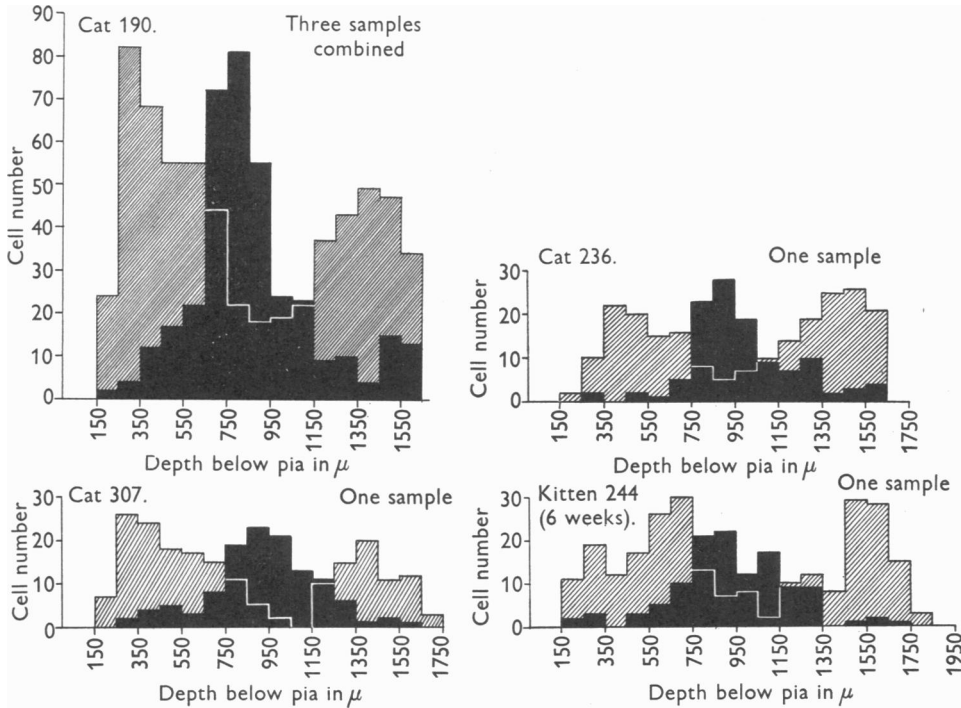


Fig. 2. Distribution of pyramidal and stellate cells in the visual cortex of the cat. Cat 190: three samples combined. Cat 236: one sample. Cat 307: one sample. Kitten 244 (6 weeks): one sample. Shaded area: distribution of pyramidal cells. Black area: distribution of stellate cells.

In the 6-week-old kitten, the distribution patterns of the stellates and pyramids are similar to the adults, but there are fewer stellate cells (81 %) (Table 2), and the peak of the stellate cell distribution is at a lower level than that of the pyramids.

The visual area of the rabbit

The unclassified and the fusiform cells form about 9–18 and 4 % of the samples respectively, and the former are again found to be distributed in a random manner at all depths of the cortex. The difference between the pair of samples from each of the two adult rabbits was found to be statistically insignificant, but comparisons

between the samples from the different adult animals were significantly different. The causes giving rise to such differences have been discussed earlier (p. 469), and no consistent pattern could be detected in the distribution of these differences.

The patterns of distribution of the pyramidal and stellate cells are represented in a series of histograms in Fig. 3, each of which represents the distribution in one animal. In spite of possible differences suggested by the χ^2 test, these patterns appear to be very similar in the adult animals. The zone of stellate cell concentration

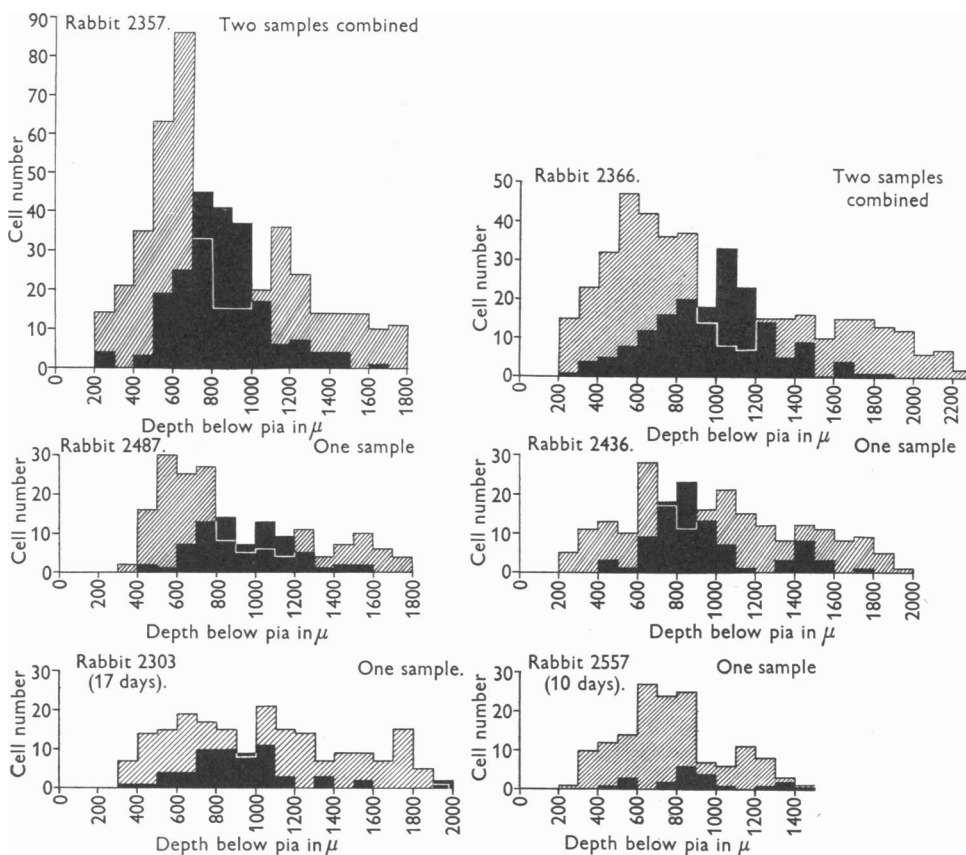


Fig. 3. Distribution of pyramidal and stellate cells in the visual cortex of the rabbit. Rabbit 2357: two samples combined. Rabbit 2366: two samples combined. Rabbit 2487: one sample. Rabbit 2436: one sample. Rabbit 2303 (17 days): one sample. Rabbit 2557 (10 days): one sample. Shaded area: distribution of pyramidal cells. Black area: distribution of stellate cells.

is narrower in this species than in the monkey or cat and occupies only a zone 300–400 μ thick compared with 700 μ in the monkey and 400–500 μ in the cat visual area. Beyond this zone the number of stellate cells diminishes more gradually than in the latter two species of animals and becomes 19% of the total number of pyramids and stellates in the 'suprastellate zone'. The peak of the stellate cell distribution is at a significantly lower level than that of the pyramidal cells, showing that their concentration is relatively less in rabbits than in cats and

monkeys. The percentage of the stellate cells varies between 28 and 32 % with an average of approximately 31 % (Table 2).

Examination of the stellate cell distributions in young animals (Fig. 3) leaves no doubt that they are very different from the adults. The stellate cells are concentrated in a region of the cortex where in the adults they outnumber the pyramids but they form only approximately 23 % of the classified neurons in the 17-day-old animal and 13 % in the 10-day-old rabbit in comparison with 31 % in the adults; moreover, at these early ages, there are more pyramids than stellates at all depths of the cortex.

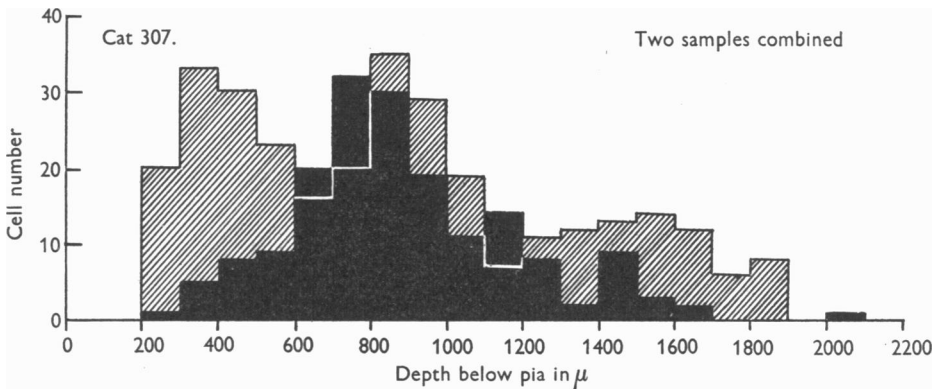


Fig. 4. Distribution of pyramidal and stellate cells in the somatosensory cortex of the cat. Cat 307: two samples combined. Shaded area: distribution of pyramidal cells. Black area: distribution of stellate cells.

The somatosensory area of the cat

Two sets of observations were made in one animal and the cell distributions in the two samples were found to be statistically consistent. They have been added together and are represented in Fig. 4. The stellate cells are seen to be distributed in a way similar to those of the visual area of the other species of animals examined and their zone of predominance is almost the same as that of the visual cortex of cat. This predominance however, is less well marked as can be seen from a comparison of the histograms in Figs. 4 and 2. The concentration is attained more gradually, the stellate cells form about 18 % of the neuron population in the suprastellate region as compared with about 15 % in the visual area of cats, but the relative proportion of these cells in the whole depth of the cortex is the same in both areas.

The parastriate area of Macaca

Fifty-two cells out of a total of 357 could not be classified, forming about 15 % of the total sample and only fourteen cells could be classified as belonging to the fusiform group. The superimposed histograms in Fig. 5 show that the stellate cells are distributed more uniformly throughout the whole depth of the parastriate than of the striate cortex, with a slight preference for the more superficial regions. The selective mode of distribution of the two main cell types seen in the primary receptive areas is totally lacking. Another striking difference is that at every depth

of the cortex below the pial surface the stellates are fewer in number than the pyramids; they form only about 29 % (Table 2) of the classified cells, as compared with 45 % in the visual area of the same animal.

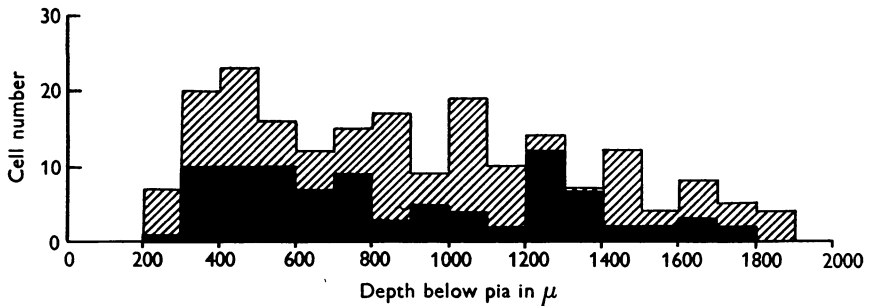


Fig. 5. Distribution of pyramidal and stellate cells in the parastriate cortex of the monkey. Monkey 4: one sample. Shaded area: distribution of pyramidal cells. Black area: distribution of stellate cells.

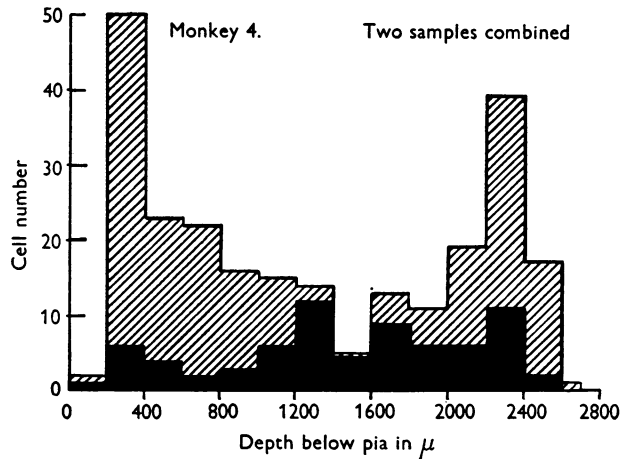


Fig. 6. Distribution of pyramidal and stellate cells in the motor cortex of the monkey. Monkey 4: two samples combined. Shaded area: distribution of pyramidal cells. Black area: distribution of stellate cells.

The motor area of the monkey

Only 17 % of the neurons could not be classified and, unlike the other areas examined, these are slightly more frequent in the deeper parts of the cortex. This is explained by the fact that in the wall of a sulcus the corticopetal and corticofugal nerve fibres take a sharp bend as they enter or leave the grey matter and thus tend to modify the shapes of the neurons; the result of these mechanical factors makes their classification more difficult.

The pattern of distribution of the stellate cells is similar to that of the parastriate area of the same animal, in that they are distributed uniformly throughout the whole depth of the cortex and at every depth they are outnumbered by the pyramidal cells.

There is a slightly greater frequency of the stellate cells in the deeper parts of the cortex and their proportion is slightly less, forming about 22 % (Tables 1 and 2) of the total number of classified neurons compared with 29 % in the parastriate area.

The motor area of the cat

Three samples were taken from the caudal wall of the cruciate sulcus, two from one cat and one from another. All the distributions were found to be statistically consistent and hence these distributions have been added. Those of a fourth sample derived from the rostral wall have been considered separately on account of the

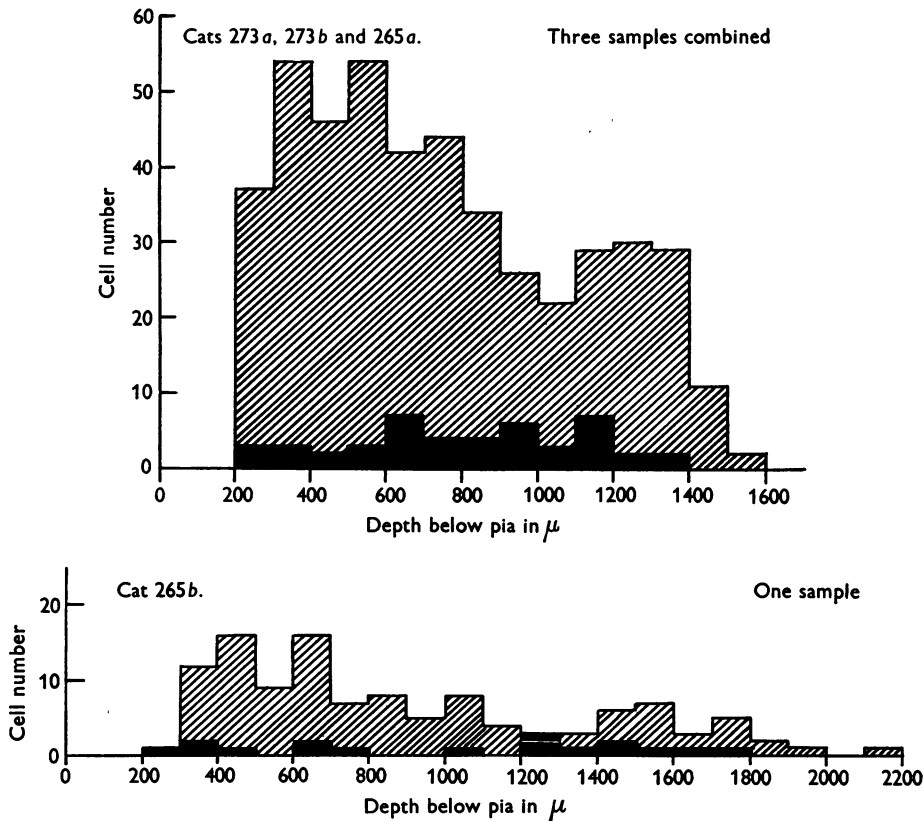


Fig. 7. Distribution of pyramidal and stellate cells in the motor cortex of the cat. Cats 273a, 273b and 275a: three samples combined. Cat 265b: one sample. Shaded area: distribution of pyramidal cells. Black area: distribution of stellate cells.

great differences in the thickness of the cortex of the rostral and caudal walls of the sulcus. The unclassified cells formed 15 % of the samples. The histograms in Fig. 7 show that the stellate cells, as in the case of the monkey, are distributed uniformly at all depths of the cortex, but only 9 % of the cells are stellate (Table 2).

The prefrontal cortex of man

The cell distribution in this area of the human cortex is very similar to that found in the parastriate area of monkey, and the relative proportions of the cell types are almost the same in both areas (Table 1 and Fig. 8). 16% of the cells were unclassified.

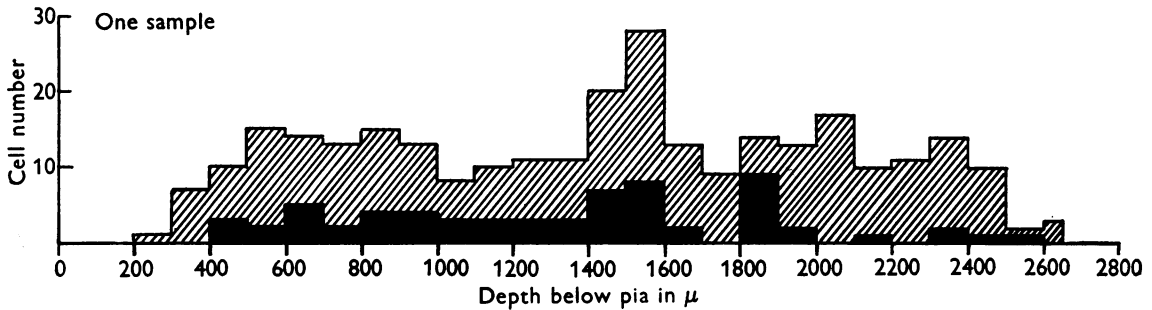


Fig. 8. Distribution of pyramidal and stellate cells in the prefrontal cortex of man. One sample. Shaded area: distribution of pyramidal cells. Black area: distribution of stellate cells.

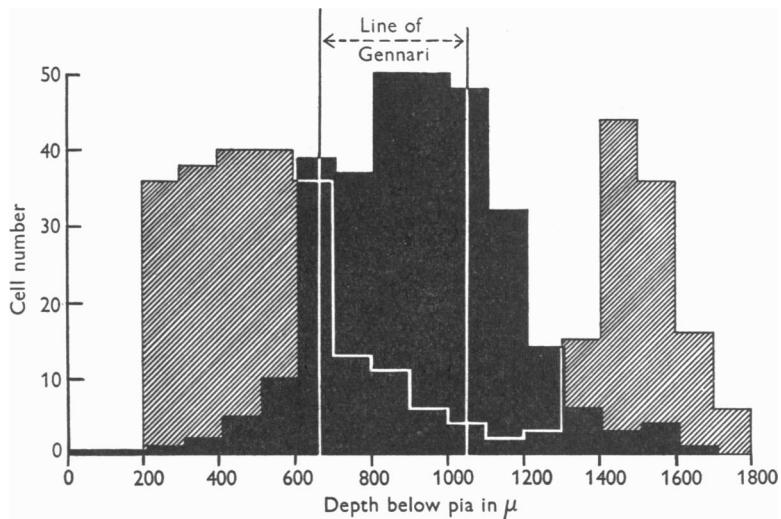


Fig. 9. Distribution of the stellate cells in relation to the line of Gennari in the visual cortex of the monkey.

Relationship of the specific afferent fibres with stellate cell distribution in the visual area of the monkey

The line of Gennari, where most of the specific afferent fibres from the lateral geniculate body ramify and terminate is very prominent in the monkey and can easily be identified on sections stained by Nissl or silver methods. In order to investigate the spatial relationship of the stellate cells to the specific visual afferents, the width of the line of Gennari and its depth below the pial surface of the cortex

were measured on sections stained with a silver (Bielschowsky) method. These measurements were made on the opposite (right) hemisphere of the same macaque whose left hemisphere had been used for cell typing. The relationship of these afferents to the area of stellate cells distribution is shown in Fig. 9, in which the two white lines represent the position and extent of the line of Gennari as measured on silver preparations.

It is clear from this figure that the line of Gennari corresponds closely to the area of distribution of the stellate cells. Although some of these stellate neurons are situated beyond the limits of Gennari's line, the majority are contained within them; in other words, within the zone of termination of the specific afferents.

DISCUSSION

Consistency of the Golgi-Cox method

The Golgi technique provides more information about the processes of neurons than any other method, but it has been little used for quantitative work. This has perhaps been due to fears that there may be wide variations in the proportions of cells that are stained. The present figures show that with the Golgi-Cox method used the proportions of pyramidal, stellate and fusiform cells do not differ greatly in different samples of one cortical area in the same animal, or between different individuals of the same species. Nevertheless, there are consistent differences between areas. This result does not of course show that the cells actually occur in the recorded proportions. It is impossible to prove that there are not systematic differences in the proportions of the various types that are stained. There is, however, no evidence of such selectivity in these figures and if it exists it must be relatively constant.

Horizontal cells and fusiform cells

Very few horizontal cells of Cajal have been observed either in the adults or in the young animals and the few that have been seen resemble the stellate cells more closely than the Cajal cells proper. It is to be noted that most of the investigations reporting the presence of horizontal cells have been carried out on embryonic cortex or in very young animals in which these cells have not differentiated to the full extent (Ramón y Cajal, 1891, 1893; Retzius, 1891, 1893, 1894; Veratti, 1897). Further evidence of the relative immaturity of these horizontal cells at the time of birth is provided by Ramón y Cajal himself (1900-6) who found that some of the processes of the horizontal cells undergo atrophy during postnatal maturation of the cortex. It is therefore probable that these cells represent a transitional phase and that later on they change their shapes through the atrophy of some of the processes and perhaps by the growth of fresh ones till there are very few, if any, horizontal cells left in the adult cortex.

In agreement with a number of previous observers, very few fusiform cells are found in regions of cortex possessing comparatively plane surfaces. They are most abundant on the crowns of the gyri and at the depths of the sulci, and are mostly confined to the deeper parts of the cortex. It seems probable that some of the pyramidal and a few of the stellate cells in these regions are compressed in a vertical or in a horizontal direction.

Afferent fibres as a determinant of stellate cell organization in the cortex

The intimate spatial relationship between the stellate cells and the termination of the specific afferent fibres in the visual cortex suggests a close correlation between the number of stellate cells and the density and distribution of the afferent plexus in the cortex.

In cortical areas that are not primarily sensory, for example in the parastriate area of the monkey and the frontal cortex of man, the stellate cells are distributed almost uniformly throughout the whole depth of the cortex and this may be associated with the fact that the afferent fibres in these regions do not form a localized plexus but terminate at all cortical levels (Lorente de N6, 1949).

In the series rabbit, cat and monkey there is a progressive increase in the proportion of the stellate cells in the visual area, together with their more restricted distribution to this area. This may be correlated with the facts that the termination of the specific afferents in the visual cortex of cat is less diffuse and more branched than in rabbits (O'Leary & Bishop, 1938), and that the line of Gennari is much wider and more prominent in monkeys than in cats. This may be correlated with the mode of organization of the afferent plexus in these animals.

Polyak (1932) showed that the afferent plexus in the somatosensory area of the monkey is more diffuse than in its visual area. If this is also true of cats, it may well explain the more diffuse distribution of the stellate cells in the somatosensory area of these animals.

There is therefore a strong suggestion that the density and the mode of distribution of the afferent fibres may be related to the relative proportion and the pattern of distribution of the stellate cells.

The comparative development of the cell types in the cortex

From a series of non-quantitative comparative studies on various mammals Mott (1907) advanced the theory that a more highly organized visual cortex is correlated with a more well-developed layer of supragranular pyramidal cells and in this he was supported by Watson (1907) and Ari6ns Kappers (1909). Although no statement of a positive nature was made, it seems that the statement 'the development of the supragranular pyramidal layer' implies not only a more complete segregation of the supragranular pyramidal cells from the granular cells but a progressive increase in the relative proportion of the pyramidal cells as well. The present quantitative findings on the visual area (Table 2) show that although there is a progressive increase of separation of the suprastellate pyramidal cells from the stellate cells in the series rabbit, cat, monkey, the relative proportion of the stellate cells, instead of decreasing, shows a definite increase in the same order. In other words, a progressive concentration of the stellate cells runs parallel with an increase of their proportion of the total cell content.

Progressive increase in the proportion of stellate cells with post-natal development

The progressive increase in the relative proportion of the stellate cells with post-natal development has not been reported earlier. This increase may be attributed to

several factors: (a) some of the stellate cells at birth may exist in the cortex as neuroblasts which are not stained by the Golgi-Cox method and may gradually develop into mature neurons, (b) some of the pyramidal cells may be transformed into stellate cells by the growth of secondary dendrites from the cell bodies and by the attenuation of the apical dendrites, and (c) the Golgi-Cox method of staining may be less selective towards the stellate cells in young animals, causing an apparent reduction in the proportion of the stellate cells stained. The possibility, however, of mitosis of neuroblasts in the cortex causing an increase in the relative proportion of the stellate cells must be borne in mind though no evidence of such mitosis has been found.

The hypothesis that the Golgi-Cox method stains a smaller proportion of the stellate cells in young animals is not impossible, but appears improbable in view of the fact that in adults it is found to be slightly more selective towards the stellate cells. The number of the cells stained by this method in young animals is much less than in the adults and progressively increases with the growth of the animal. This suggests, but does not prove, that a considerable proportion of the cortical neurons at birth exist in the neuroblast stage (and hence are unstained) and of these a larger proportion belongs to the stellate type. This suggestion is further strengthened by the consideration that the cortical neurons in very young animals appear to be much less developed than in the adults with respect both to dendritic and axonal proliferations. Postnatal growth of axon collaterals and dendrites has been reported by Ramón y Cajal (1900-6), Lorente de Nó (1922) and Conel (1939, 1941, 1947, 1951).

The possibility of some of the pyramidal cells changing into stellate type, remote as it may appear, cannot be disregarded. At the present time the whole question must remain open and await further investigation.

The possible role of stellate cells in the discrimination of visual patterns

The ability to discriminate between visual patterns is more highly developed in monkeys than in cats and rabbits, and this situation is closely correlated with the numbers of stellate cells in the striate cortex associated with the region of termination of the specific afferent fibres. Sholl & Uttley (1953) have suggested a possible analogy between this part of the cortex and a machine for pattern discrimination. A machine of this kind demands a number of identical units, the number of which increases with the complexity of the patterns to be discriminated. It would be hazardous to press this analogy too far at the present state of our knowledge, but the design of such a machine suggests that the stellate cells may have properties and connexions comparable with the basic units of these authors.

SUMMARY

1. Estimates were made of the proportions of pyramidal, stellate and fusiform cells in Golgi-Cox preparations of various areas of the cortex of rabbits, cat, monkey and man.

2. The proportions do not differ greatly in different samples from a given area in any one brain nor in different individuals of the same species. There are, however, consistent differences between different 'functional' areas and between each area in different mammals.

3. The proportion of fusiform neurons is very low and horizontal cells are almost or quite absent from the areas examined in adult animals.

4. The stellate cells are mainly concentrated in the middle third of the cortex of the primary sensory areas, whereas in the motor, parastriate and prefrontal cortex these cells are more uniformly distributed throughout the cortex. Their proportion is also greater in the primary sensory areas.

5. There is a progressive increase in the proportion of the stellate cells and the width of the zone of their predominance in the visual cortex of the series rabbit, cat and monkey. There is also a progressive decrease in the same series of the relative proportion of these cells in the cortical region superficial to the zone of predominance of the stellate cells.

6. The zone of termination of the specific visual afferents appears to be highly correlated with the zone of maximum concentration of stellate cells in the visual cortex of monkey.

7. The proportion of the stellate cells increases with the postnatal age in the rabbit.

It is a pleasure to record my indebtedness to Prof. J. Z. Young, F.R.S. for his continued encouragement and criticism throughout this work, and to Mr D. A. Sholl for his advice on the statistical problems involved in this work and on the last part of the paper. My thanks are also due to Miss E. R. Turlington for preparing the histograms and to Mr J. Armstrong, Mr G. Hyde and Miss R. Proudlock for technical assistance.

REFERENCES

- ARIËNS KAPPERS, C. U. (1909). The phylogenesis of the palaeo-cortex and archi-cortex compared with the evolution of the visual neo-cortex. *Arch. Neurol. Psychiat., Lond.*, 4, 161-173.
- CONEL, J. LEROY (1939, 1941, 1947, 1951). *Postnatal Development of the Human Cerebral Cortex*. Vols. 1-4. Cambridge, Mass.: Harvard University Press.
- ECONOMO, C. VON & KOSKINAS, G. N. (1925). *Die Cytoarchitektonik der Hirnrinde des erwachsenen Menschen*. Vienna: J. Springer.
- LORENTE DE NÓ, R. (1922). La corteza cerebral del ratón. *Trab. Lab. Invest. biol. Univ. Madr.* 20, 41-78.
- LORENTE DE NÓ, R. (1934). Studies on the structure of the cerebral cortex. 1. The area entorhinalis. *J. Psychol. Neurol., Lpz.*, 45, 381-438.
- LORENTE DE NÓ, R. (1949). Cerebral cortex: Architecture, intracortical connections, motor projections. In Fulton, J. F., *Physiology of the Nervous System*, 3rd ed. New York: Oxford University Press.
- MOTT, F. W. (1907). The progressive evolution of the structure and functions of the visual cortex in mammalia. *Arch. Neurol. Psychiat., Lond.*, 3, 1-48.
- NGOWYANG, G. (1937). Structural variations of the visual cortex in primates. *J. comp. Neurol.* 67, 89-107.
- O'LEARY, J. L. & BISHOP, G. H. (1938). The optically excitable cortex of the rabbit. *J. comp. Neurol.* 68, 423-478.
- POLYAK, S. (1932). The main afferent fibre systems of the cerebral cortex in primates. *Univ. Calif. Publ. Anat.* 2, 1-369.
- RAMÓN Y CAJAL, S. (1891). Sur la structure de l'écorce cérébrale de quelques mammifères. *Cellule*, 7, 125-176.
- RAMÓN Y CAJAL, S. (1893). Neue Darstellung von histologischen Bau des Centralnervensystem. *Arch. Anat. Physiol., Lpz. (Anat. Abt.)*, 1893, pp. 319-428.
- RAMÓN Y CAJAL, S. (1900-6). *Studien über die Hirnrinde des Menschen*. Leipzig: J. A. Barth.

- RETZIUS, G. (1891). Über den Bau der Oberflächenschicht der Grosshirnrinde beim Menschen und bei den Säugetieren. *Biol. Fören. Förh.* 3, 90–102.
- RETZIUS, G. (1893). Die Cajal'schen Zellen der Grosshirnrinde beim Menschen und bei Säugetieren. *Biol. Untersuch.*, N.F., 5, 1–8.
- RETZIUS, G. (1894). Weitere Beiträge zur Kenntniss der Cajal'schen Zellen der Grosshirnrinde des Menschen. *Biol. Untersuch.*, N.F., 6, 29–36.
- SHOLL, D. A. (1953). The dendritic organization of cortical neurons in the cerebral cortex of the cat. *J. Anat., Lond.*, 87, 387–406.
- SHOLL, D. A. & UTTLEY, A. M. (1953). Pattern discrimination and the visual cortex. *Nature, Lond.*, 171, 387–388.
- VERATTI, E. (1897). Über einige Struktureingetümlichkeiten der Hirnrinde bei den Säugetieren. *Anat. Anz.* 13, 377–389.
- WALKER, A. E. (1940). A cytoarchitectural study of the prefrontal area of the macaque monkey. *J. comp. Neurol.* 73, 59–86.
- WATSON, G. A. (1907). The mammalian cerebral cortex, with special reference to its comparative histology. I. Order Insectivora. *Arch. Neurol. Psychiat., Lond.*, 3, 49–117.