

DEVELOPMENT OF THE HUMAN LESSER SAC

By R. KANAGASUNTHERAM

Department of Anatomy, University of Ceylon

Our knowledge of the normal course of development of the lesser sac is in a confused state and is inadequate to account for some of the congenital anomalies met with in this region. This is perhaps to be attributed to the fact that since the pioneer work of Broman (1904) on the development of the omental bursa in man and in other vertebrates, no serious attempt has been made to reinvestigate the subject.

Müller (1830) considered that the omental bursa was formed as the result of a folding of the dorsal mesogastrium. This interpretation was accepted for the next fifty years till His (1880), Ravn (1889), Mall (1891, 1897, 1910) and Swaen (1896) found that the lesser sac was an independent formation commencing as a small recess on the right side of the foregut tube. Broman (1904), in his extensive monograph on the omental bursa, added details which were lacking in these earlier accounts. Later (1938) he came to the conclusion that the omental bursa of mammals was formed of hepato-enteric and pancreatico-enteric recesses. Vilkari (1950) made a detailed investigation of the infracardiac bursa in man and showed that the bursa persisted in a large proportion of full-term foetuses and might occasionally be found even during adult life.

According to the description in current text-books of embryology, the lesser sac begins its development as a shallow pocket appearing on the right surface of the dorsal mesogastrium. The recess burrows deeper into the thickness of the dorsal mesogastrium and grows in a cranial direction forming the pneumato-enteric recess. The pneumato-enteric recess is then divided by the developing diaphragm into a cranial portion, the infracardiac bursa (Broman, 1904), and a caudal part which becomes the superior recess of the lesser sac. An extension of the pneumato-enteric recess to the left, dorsal to the stomach, results in the formation of the omental bursa proper.

MATERIAL AND METHODS

Twenty-six serially sectioned human embryos ranging from 3 to 99 mm. (C.R.) and one *Hylobates mülleri* foetus 57 mm. (C.R.) were examined during the course of the present investigation. Some additional information was also obtained from the dissection of the lesser sac in a juvenile *H. hoolock*.

For purposes of convenience, the embryos are classified into five age-groups (see Table 1).

Group I: embryos in which the pneumato-enteric recess has not developed (no. examined, 1).

Group II: embryos of 3·8–5 mm. in which the pneumato-enteric recess appears as a longitudinal cleft and does not extend into the dorsal mesogastrium proper (no. examined, 4).

Group III: embryos of 6–12.25 mm. in which the pneumato-enteric recess has invaded the dorsal mesogastrum but the infracardiac bursal portion of the recess remains in continuity with the hepato-enteric part of the pneumato-enteric recess (no. examined, 8).

Group IV: embryos of 13–30 mm. in which the infracardiac bursa has become separate from the hepato-enteric portion of the pneumato-enteric recess. Embryos of this group show marked development of the omental bursa (no. examined, 9).

Group V: embryos of 37–99 mm. in which fusion of the dorsal mesogastrum to the posterior abdominal wall and to the transverse mesocolon is a prominent feature (no. examined, 4).

Table 1. *Embryos examined*

	Serial no.	length (mm.)	Thickness of sections (μ)
Group I	—	3	—
Group II	H. 86	3.8	10
	—	4	—
	—	5	8
Group III	Millard	5	8
	—	6	10
	Barnes	7–8	8
	H. 237	8.5	5
	H. 226 (J.T.W.)	9	10
	H. 116	9–10	10
	Thurkettle	9–10	8
	H. 67 (J. T. W.)	9.5–10	10
Group IV	H. 250	12.25	8
	H. 23	13	10
	H. 24	13.5	10
	H. 241	14	8
	H. 640	17	6
	H. 25	17	10
	H. 242	18	10
	H. 594	22	6
	H. 583	27	6
	H. 180	30	12
Group V	H. 549	37	10
	H. 653	46	7
	H. 183	60	10
	H. 80	99	15

All embryos with a serial number are in the Department of Anatomy, University of Cambridge. The 4, 5 mm. (Millard), 7–8 mm. (Barnes) and 9–10 mm. (Thurkettle) were made available by the Department of Anatomy, Charing Cross Hospital Medical School. Two embryos of 5 and 6 mm. were obtained from the Department of Anatomy and Embryology, University College, London, while the single 3 mm. embryo of the series belongs to the author. All the sections were cut in the transverse plane.

Terminology. In this communication, the terms ‘hepato-enteric recess’, ‘hepatic portion of the pneumato-enteric recess’ and ‘hepatic portion of the lesser sac’ are used synonymously to denote that part of the cavity of the lesser sac which is related to the caudate lobe of the liver. This cavity, in later development, forms the superior recess of the lesser sac. The term ‘omental bursa proper’ or ‘omental portion of the lesser sac’ refers to that part of the lesser sac which lies dorsal to the stomach and

is continued into the free caudal portion of the dorsal mesogastrium. The term 'pancreatico-enteric recess' is applied to a small portion of the lesser sac between the caudal part of the hepato-enteric recess and the cranial portion of the omental bursa proper. At times this junctional region is indistinct and in these cases the pancreatico-enteric recess appears as a part of the omental bursa proper. The 'pneumato-enteric recess' refers to the cavity of the lesser sac during its early development. It consists of a cranial infra-cardiac bursa and a caudal hepato-enteric recess, both of which remain in direct continuity until their separation occurs about the 13 mm. stage.

OBSERVATIONS

A 'type specimen' belonging to each of the groups II, III and IV is described in some detail with brief notes on the individual embryos of groups II and III. A general summary of the embryos of group IV and a few relevant facts with regard to embryos of group V are also included in the present observations.

Group I. 3 mm. embryo

The single embryo belonging to this group represents such an early stage of development that no anlage of the right pneumato-enteric recess is noticeable.

Group II. 3.8-5 mm. embryos (type specimen, 3.8 mm.)

The cranial end of the right pneumato-enteric recess lies between the ventral part of the oesophagus and the right lung bud. The ventral portion of the recess is very narrow and is lined by a single layer of epithelium. When traced in the caudal direction, the recess gradually extends dorsally and comes to lie lateral to the oesophagus. Between 20 and 100 μ from the cranial end, the recess is dilated in its dorsal half while the ventral half remains narrow as at the commencement (Pl. 1, fig. 1). Between 100 and 120 μ from the cranial end, the recess is dilated in its central portion while the dorsal and ventral extremities remain narrow. Further caudally, the dorsal part of the recess becomes dilated once again, and finally this dilated dorsal segment opens into the peritoneal cavity (Pl. 1, fig. 2). The total length of the right pneumato-enteric recess is 170 μ . The left pneumato-enteric recess is not present in this embryo.

The bar of mesoderm forming the lateral wall of the right pneumato-enteric recess blends cranially and ventrally with the mesodermal anlage of the right lung bud, while caudally it is split into dorsal and ventral lips by the opening of the recess into the general peritoneal cavity (Pl. 1, fig. 2). The ventral lip of mesoderm guarding the foramen blends caudally with the septum transversum while the dorsal lip merges with the dorsal mesogastrium.

The entodermal anlage of the stomach forms the dilated segment of the foregut. The right surface of the stomach is flattened and is directed slightly dorsally while its left surface is convex and faces ventrally. The dorsal mesogastrium forms a thick mid-line mesentery at this stage.

The ventral mesogastrium is very short and sagittally placed (Pl. 1, fig. 2). In the region of the duodenum, the mesoderm of the septum transversum containing the

liver is broadly in apposition with the lateral walls of the duodenal tube so that there is no ventral mesentery at this place (Pl. 1, fig. 3).

The pneumato-enteric recess is lined by a single layer of epithelium in its narrow cranial portion, while the lining becomes several layers deep in its caudal half. This increase in the layers of cells is particularly noticeable opposite the dilated segments of the recess.

4 mm. embryo. The cranial extremity of the right pneumato-enteric recess lies ventrolateral to the oesophagus and caudal to the entodermal anlage of the right lung bud. The recess soon passes dorsally to lie directly lateral to the oesophagus. Further caudally, the recess communicates with the general peritoneal cavity. The ventral lip of mesoderm guarding the foramen is thin and short, while the dorsal lip is thick and long. The cavity of the pneumato-enteric recess is of uniform width except caudally where the ventral part of the recess is dilated. The entodermal anlage of the stomach tube is flattened from side to side without any definite bulging of its left surface.

5 mm. embryo. The right pneumato-enteric recess is only 56μ in length and is placed between the entodermal anlage of the right lung bud and the oesophagus. The opening of the recess into the pleuroperitoneal coelom is guarded by a large ventral and a rudimentary dorsal lip of mesoderm. The entodermal anlage of the stomach in transverse section resembles that of the 4 mm. embryo.

5 mm. (Millard) embryo. There is a constriction of the central portion of the right pneumato-enteric recess in its cranial part so that sections passing through this region show a small dorsal and a larger ventral cavity (Pl. 1, fig. 4). Further caudally, the cavity of the recess extends dorsal to the stomach which in this region shows a flattened dorsal surface directed partly towards the right while its ventral surface is convex and faces slightly to the left.

The length of the recess is 304μ and the opening of the recess into the general peritoneal cavity is indefinite since the ventral lip guarding the orifice is now invaded by liver tissue and is in contact with the dorsal lip (Pl. 2, fig. 5).

The left pneumato-enteric recess is not present in any embryo of this group.

Group III. 6–12.25 mm. embryos (type-specimen, 8.5 mm.)

The right pneumato-enteric recess lies ventrolateral to the oesophagus and is separated from the anlage of the right lung bud by the cranial portion of the caval fold, the plica mediastino-pulmonalis. The infracardiac bursa which forms the cranial part of the pneumato-enteric recess is 270μ long. The caudal limit of the infracardiac bursa is arbitrarily chosen to correspond with the caudal end of the entodermal lung bud.

The infracardiac bursa passes without interruption into the hepato-enteric recess. The ventral part of this recess, which lies adjacent to the caudate lobe of the liver, is constricted while the dorsal portion of the hepato-enteric recess adjacent to the caval fold is dilated. The caval fold to a large degree remains free of liver tissue, although the caudate lobe of the liver is clearly recognizable. The inferior vena cava has not yet differentiated inside the caval fold.

The omental portion of the lesser sac begins about 670μ from the cranial extremity of the pneumato-enteric recess and appears as an extension from the dorsal portion

of the hepato-enteric recess. The hepatic and omental portions of the lesser sac are placed almost at right angles to each other and they communicate with the general peritoneal cavity by a common orifice, the foramen of Winslow. This opening is 22μ long in this embryo, and is directed towards the right mesonephros. The foramen is bounded ventrally by the liver, dorsally by the dorsal lip of the caval fold, cranially by the caudate lobe and caudally by a mesodermal fold extending from the proximal part of the duodenum to the dorsal body wall. This fold contains the hepatic artery and is therefore known as the *plica arteriae hepaticae* (Broman, 1904).

In transverse section, the anlage of the stomach appears as a flattened tube with dorsal and ventral surfaces. The dorsal mesogastrium is extremely thick and is attached along the mid-line of the dorsal abdominal wall. The most dilated portion of the cavity of the lesser sac is contained within the part of the dorsal mesogastrium lying caudal to the stomach.

The ventral mesogastrium is short and sagittally placed in its cranial part. It gradually becomes oblique and finally transverse when traced in a caudal direction. In the oblique and transverse portion, the ventral mesogastrium is extremely thick. The thick ventral mesentery of the proximal part of the duodenum and the corresponding part of the dorsal mesoduodenum are fused together and are connected with the dorsal surface of the liver.

6 mm. embryo. The cranial end of the right pneumato-enteric recess consists of a dilated ventral and a narrow dorsal portion (Pl. 2, fig. 6). The caval fold which forms the lateral wall of the recess is partly invaded by liver tissue so that the caudal part of the recess lies adjacent to the liver. The anlage of the omental bursa proper is beginning to differentiate inside the dorsal mesogastrium and is in direct communication with the hepatic portion of the pneumato-enteric recess. The hepatic and the omental portions of the lesser sac communicate with the general peritoneal cavity through a common opening, the foramen of Winslow which is 150μ long. The length of the infracardiac bursa is 72μ .

7-8 mm. (Barnes) embryo. This embryo closely resembles the type-specimen of this group. The infracardiac bursa measures 260μ in its cranio-caudal extent. The entodermal lining of the cranial part of the stomach is rectangular in section with dorsal and ventral mesogastria attached to the dorsal and ventral ends of the right surface of the stomach.

9 mm. embryo. The central portion of the hepato-enteric recess is completely occluded leaving a small ventral and a larger dorsal cavity (Pl. 2, fig. 7). The length of the infracardiac bursa is 200μ .

9-10 mm. embryo. The infracardiac bursa which is 360μ long continues caudally into the hepato-enteric recess without interruption. The caudal part of the hepato-enteric recess becomes subdivided by the *plica arteriae hepaticae* into a smaller right recess, the cavo-coeliac recess of Broman (1904), and a larger left recess which is prolonged caudally into the omental bursa proper. The cavo-coeliac recess is 80μ in length and its caudal part opens into the general peritoneal cavity. Consequently, there is no direct communication between the general peritoneal cavity and the lesser sac except through the cavo-coeliac recess. The cavo-coeliac recess has the *plica arteriae hepaticae* on its left, the caudate lobe on its right, the

ventral mesogastrium ventrally and the inferior vena cava dorsally (Pl. 4, fig. 13).

9–10 mm. (*Thurkettle*) embryo. In this embryo with situs inversus, both the right and the left pneumato-enteric recesses are present (Pl. 2, fig. 8). The right pneumato-enteric recess is 160μ long and opens caudally into the pleuro-peritoneal coelom.

The left pneumato-enteric recess is larger than the right, and when traced in a caudal direction, the central portion of the recess is occluded while very small cavities persist in the dorsal and ventral parts of the recess. In some sections no trace of the cavity is recognizable even in the dorsal or ventral part. The caudal part of the hepato-enteric recess leads into a poorly developed pancreatico-enteric recess. The omental bursa proper is developed as an independent cavity inside the caudal part of the dorsal mesogastrium (Pl. 3, figs. 10, 11). No portion of the lesser sac has any communication with the general peritoneal cavity. The stomach occupies the median plane and is flattened from side to side (Pl. 3, fig. 9).

12·25 mm. embryo. The cavity of the pneumato-enteric recess when traced in a caudal direction shows a narrowing of its lumen before becoming continuous with the cranial end of the hepato-enteric recess. But the infracardiac bursa is not completely separated off from the hepato-enteric recess.

Group IV. 13–30 mm. embryos (type-specimen, 14 mm. embryo)

The infracardiac bursa is not developed in this embryo. The cranial end of the hepato-enteric recess lies between the ventro-lateral aspect of the oesophagus and the caudate lobe of the liver. When traced in a caudal direction, the recess gradually extends dorsally towards the inferior vena cava which is now easily recognizable. Immediately caudal to the caudate lobe, the recess is dilated and further caudally it is subdivided by the *plica arteriae hepaticae* into a right cavo-coeliac recess and left portion which continues into the pancreatico-enteric recess. The cavo-coeliac recess, which is 160μ long, opens into the general peritoneal cavity caudal to the free margin of the ventral mesogastrium. The hepato-enteric recess has no direct access into the general peritoneal cavity except through the cavo-coeliac recess.

The junctional region between the hepato-enteric and the pancreatico-enteric recesses forms a narrow neck, caudal to which the pancreatico-enteric recess gradually extends towards the left to become continuous with the omental portion of the lesser sac. The narrow neck leading into the pancreatico-enteric recess is bounded cranially and on the left by the dorsal mesogastrium containing the left gastric artery, while the *plica arteriae hepaticae* forms the caudal and right boundary (Pl. 4, fig. 13).

The cranial portion of the dorsal mesogastrium is short and thick and is attached to the dorsal surface of the stomach close to the future lesser curvature. The attachment continues caudally till the cranial end of the pancreatico-enteric recess, beyond which the mesogastric attachment gradually passes towards the left border of the stomach adjoining the spleen. The attachment of the dorsal mesogastrium to the dorsal wall remains along the mid-line except where the mesogastrium contains the pancreas. At this region, the dorsal mesogastrium appears to arise from the root of the dorsal mesoduodenum.

The ventral mesogastrium is thin and obliquely placed in its cranial portion, while in its caudal parts the ventral mesogastrium assumes a transverse direction. The endodermal anlage of the stomach tube is triangular close to the cardiac orifice, quadrilateral in the cranial portion of the body, and cylindrical in the caudal part of the body of the stomach (Text-fig. 1).

Summary of the findings in other embryos of group IV. An infracardiac bursa is present in all embryos with the exception of the 22 and 30 mm. embryos in which a bursa is completely lacking. The length of the infracardiac bursa ranges from 696μ in the 27 mm. embryo to 150μ in the smallest (13 mm.) embryo of this group. However, there is no strict correlation between the length of the embryo and the length of the infracardiac bursa; for instance, the bursa is 210μ long in the 17 mm. embryo (H. 25), while its length is 250μ in the 13.5 mm. embryo.

The *plica mediastino-pulmonalis* extends between the anlage of the diaphragm ventrally and the mediastinum dorsally (Pl. 3, fig. 12). In the different embryos of this group, this plica shows considerable variation in thickness, in dorso-ventral length and in its relationship to the root of the right lung.

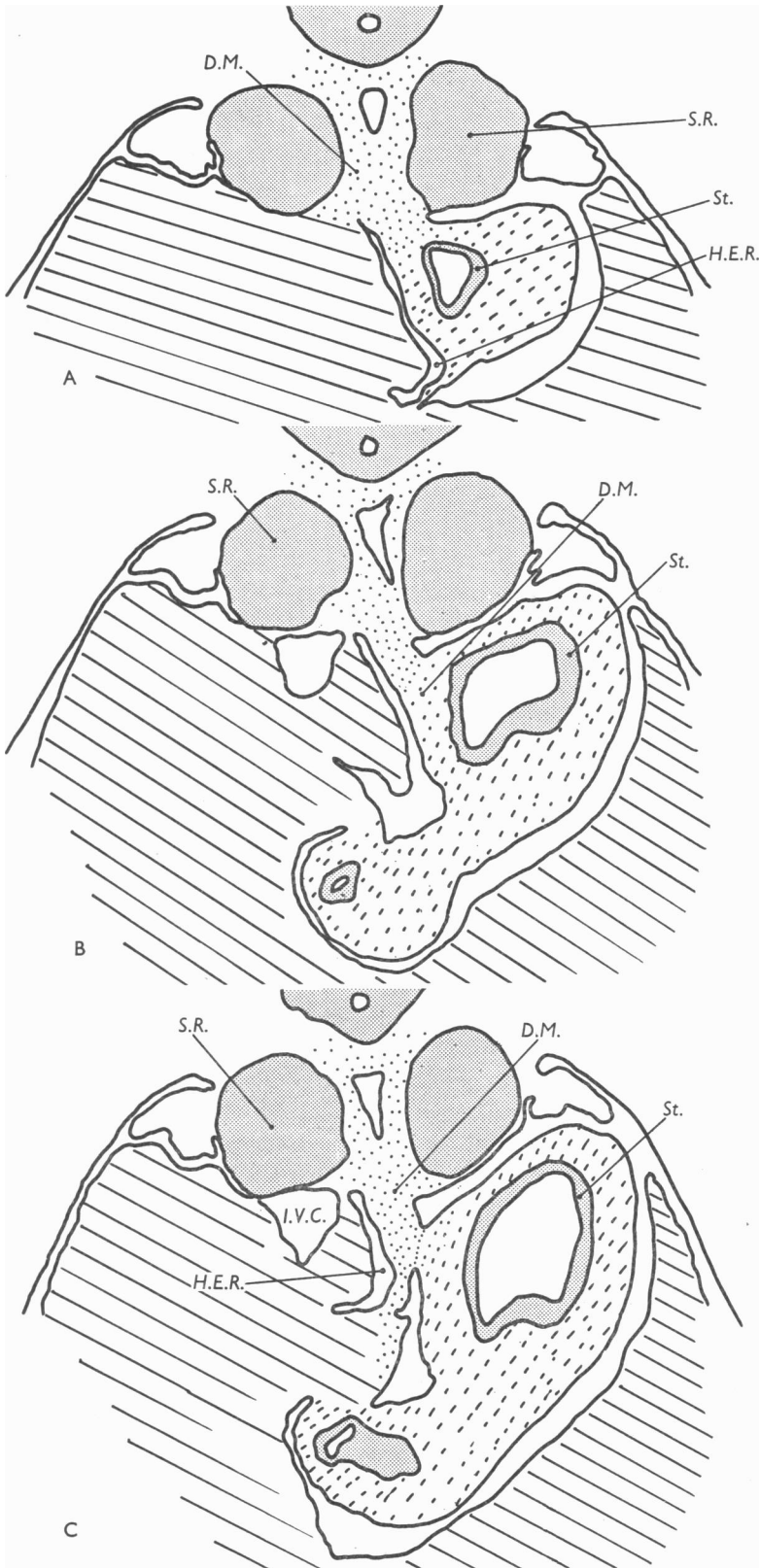
In the 13.5 mm. embryo, the dorsal two-thirds of the hepato-enteric recess is obliterated over a considerable distance with the cavity persisting only in the ventral part of the recess. In the 30 mm. embryo, the entire cranial portion of the hepato-enteric recess is undeveloped and there is mesodermal tissue connecting the caudate lobe not only with the stomach but also with the dorsal mesogastrium. The hepato-enteric recess in most embryos of this group communicates with the general peritoneal cavity by means of a cavo-coeliac recess; but, in the 13, 22 and 27 mm. embryos, there is a direct communication between the hepato-enteric recess and the general peritoneal cavity.

The junctional region between the hepato-enteric and the pancreatico-enteric recesses forms a narrow neck which usually lies between the left gastric and hepatic arteries. The pancreatico-enteric recess leads caudally into the omental bursa proper which in a majority of embryos of this group shows considerable increase in size by extension of the bursal cavity in a left and caudal direction. But in the 13.5 mm. embryo, and more particularly in the 30 mm. embryo, the cavity of the omental bursa is very narrow and in places completely occluded, with the result that considerable mesodermal connexions exist between the dorsal mesogastrium and the dorsal surface of the stomach (Pl. 4, fig. 16).

The cranial part of the dorsal mesogastrium is attached to the dorsal surface of the stomach and lies close to the ventral mesogastric attachment to the stomach, i.e. close to the future lesser curvature. When traced in a caudal direction, the dorsal mesogastric attachment is gradually shifted towards the left border of the stomach adjoining the spleen. But in the 18 mm. embryo, this shift of the mesogastric attachment from the dorsal surface of the stomach to its extreme left border

Explanation of Text-fig. 1

Camera lucida drawings ($\times 60$) of sections through a 14 mm. embryo (H. 241). A, most cranial level; B, intermediate level; C, most caudal level. The drawings indicate that the growth of the endodermal stomach is more marked on its left surface. Note that the dorsal and ventral mesogastria are attached to the dorsal and ventral extremities of the right surface.



Text-fig. 1

is very abrupt and is accomplished within a distance of 40–50 μ (Pl. 4, figs. 14, 15).

The root of the dorsal mesogastrium is attached along the median line of the body wall in all embryos of this group. The cranial part of the mesogastrium passing towards the spleen is thin and membranous, while the portion of the mesogastrium between the spleen and the stomach is thick and spongy. In the 17, 27 and 30 mm. embryos the caudal free portion of the mesogastrium is fused with that part of the midgut mesentery which suspends the transverse colon.

The ventral mesogastrium is thinner and longer than in embryos of group III, and the caudal part of the ventral mesogastrium forms the ventral boundary of the cavo-coeliac recess. The free margin of the ventral mesogastrium is directed caudally in all embryos of this group except the 13, 22 and 27 mm. embryos in which the free margin runs caudally and dorsally from the liver towards the proximal part of the duodenum.

Group V. 37–99 mm. embryos

The cavity of the infracardiac bursa is poorly developed in the 37 mm. embryo, although the bursa has a cranio-caudal length of 550 μ . In the 46 mm. embryo, the infracardiac bursa is very much larger than in the preceding embryo and has a total length of 988 μ . In both these embryos the infracardiac bursa is interposed between the ventro-lateral part of the oesophagus and the diaphragm and is practically unrelated to the right lung.

The hepato-enteric recess is well developed in all embryos with the exception of the 60 mm. embryo, in which only the dorsal portion of the recess adjacent to the inferior vena cava is present (Pl. 5, fig. 19). In the 37 and 46 mm. embryos the hepatic and omental portions of the lesser sac communicate with the general peritoneal cavity by a common orifice, the foramen of Winslow. In the 60 mm. embryo there is no communication at all between the greater and lesser peritoneal cavities, while in the 99 mm. embryo, the hepato-enteric recess opens into the general peritoneal cavity by means of a cavo-coeliac recess. The free margin of the ventral mesogastrium runs obliquely in a caudal and dorsal direction from the liver towards the proximal part of the duodenum in the 46 mm. and the 99 mm. embryos, but in the 37 mm. embryo the free margin is directed caudally and ventrally towards the duodenum.

The extreme cranial part of the dorsal mesogastrium remains in the median plane in all embryos of this group. The succeeding part of the mesogastrium stretching towards the spleen is partly fused with the dorsal body wall opposite the left suprarenal gland in the 37, 46 (Pl. 5, fig. 17) and 60 mm. embryos. In the 99 mm. embryo the fusion is almost complete except for a small pocket of peritoneal cavity close to the root of the dorsal mesogastrium.

The part of the dorsal mesogastrium containing the pancreas is partly fused with the dorsal abdominal wall in the 60 mm. embryo, and the fusion is complete in the 99 mm. embryo. The mode of fusion in this region is from the head of the pancreas towards its tail end.

The free portion of the dorsal mesogastrium forming the left wall of the omental bursa is thick and spongy, while the remaining portion of the mesogastrium is thin

and membranous. The transverse mesocolon, which is a part of the midgut mesentery, shows further progress in its fusion with the dorsal mesogastrum than what has been observed in embryos of group IV.

DISCUSSION

Mode of formation of the cavity of the lesser sac

Ravn (1889) believed that the pneumato-enteric recess (*recessus superior sacci omenti*) was formed from the medial portion of the pleuro-peritoneal coelom (*saccus parietalis dorsalis*) which was cut off from the remaining portion of the coelom by a mesodermal fold. This fold, according to Ravn's description and diagrams, appears to take origin from the septum transversum and pass dorsally towards the dorsal mesentery of the foregut. Ravn was also of the opinion that the fusion of the fold to the dorsal mesentery progressed in a cranial direction. This view of a progressive fusion of the fold in a cranial direction cannot be accepted since it would entail a communication between the cranial portion of the pneumato-enteric recess and the pleuro-peritoneal coelom at some stage of development. Such a communication never exists and, on the contrary, a communication is usually present between the caudal portion of the pneumato-enteric recess and the pleuro-peritoneal coelom.

According to the descriptions available in current text-books of embryology (Frazer, 1947; Hamilton, Boyd & Mossman, 1952; Arey, 1954) the pneumato-enteric recess starts as a small pocket on the right surface of the dorsal mesogastrum. This pocket proceeds to burrow deeper into the mesogastrum, and subsequently it grows in a cranial direction towards the root of the right lung bud, forming the pneumato-enteric recess. Growth of this recess towards the left and dorsal to the stomach results in the formation of the omental bursa proper. It is, however, difficult to understand why the lesser sac, which is a part of the general peritoneal cavity, should adopt this different and unique mode of development, while the remaining portion of the peritoneal coelom is formed by the fusion of small clefts appearing in the lateral sheet mesoderm. Further, the current text-book description does not explain how portions of the pneumato-enteric recess can be almost completely obliterated, while other portions of the recess remain dilated as in the 5 mm. (Millard) and 9 mm. embryos (Pl. 2, fig. 7). In the 30 and 60 mm. embryos a communication between the cavity of the lesser sac and the general peritoneal cavity is totally lacking. This finding provides further evidence against the current view, unless one postulates that the initial communication between the pneumato-enteric recess and the general coelom has subsequently become closed in the 30 and 60 mm. embryos. The text-book accounts are also inadequate for the explanation of some of the anomalies of the lesser sac.

The view suggested here is that the pneumato-enteric recess develops in a manner similar to the rest of the coelom by the coalescence of separate clefts appearing in the mesoderm lying lateral to the entodermal anlage of the foregut tube. Usually the formation and fusion of the clefts must be so rapid that a continuous cavity results, but sometimes there is an arrest of development as in the 9 mm. embryo of this series. The tendency of the pneumato-enteric recess to communicate with the general pleuro-peritoneal coelom is understandable since the coelomic clefts them-

selves exhibit a similar tendency to coalesce during their formation. The omental portion of the lesser sac develops independently in the substance of the dorsal mesogastrium proper, but normally it soon establishes continuity with the pneumato-enteric recess. The impression is thus given that the omental portion of the lesser sac develops as an extension from the pneumato-enteric recess. Evidence for the independent origin of the omental portion of the lesser sac is furnished by the 9–10 mm. (Thurkettle) and the 30 mm. embryos, which obviously exhibit an arrest in the fusion process, and in which the principal subdivisions of the lesser sac remain separate. In the embryos examined, the portion of the hepato-enteric recess lodging the caudate process of the liver and also the left and caudal portions of the omental bursa proper form large cavities, but in the junctional regions between the subdivisions of the lesser sac the cavity is poorly developed or even absent. The failure of cavity formation results in the so-called 'adhesions' between organs normally separated by the cavity of the lesser sac.

Caval fold. In the 3.8, 4 and 5 mm. embryos, the pneumato-enteric recess is a semilunar cleft running longitudinally in relation to the ventro-lateral and lateral surfaces of the foregut tube. No part of the recess extends farther dorsally than the dorsal limit of the entodermal gut tube, that is, there is no extension into the dorsal mesogastrium proper. The pneumato-enteric recess at this stage is bounded laterally by the caval fold. The caval fold blends cranially and ventrally with the mesodermal anlage of the right lung bud, while dorsally the fold joins the dorsal mesentery of the foregut. In the ventral and caudal direction the fold is connected with the mesoderm of the septum transversum. At the level of the foramen of Winslow the fold is split into dorsal and ventral lips, the ventral lip being very much the larger of the two. The foramen of Winslow may sometimes be in a more dorsal position than normal, and the dorsal lip is then very small or even absent as in one of the 5 mm. embryos. The mesoderm of the caval fold is of doubtful origin. Descriptively it would be the mesoderm forming the right lateral wall of the foregut tube becoming separated from the gut by the formation of the pneumato-enteric recess. But in view of the later potentialities of the caval fold, which forms a portion of the 'septal diaphragm' lateral to the oesophageal hiatus (Wells, 1954), and in view of the fact that the caudate lobe of the liver develops within this fold, the entire caval fold cranial to the foramen of Winslow is best regarded as a derivative of the septal mesoderm. According to this view, the most cranial portion of the caval fold, which forms the mediastino-pulmonary ligament, will also be of septal origin. The migration of mesodermal cells from the septum transversum towards the dorsal mesentery to form the caval fold becomes understandable in view of the anticipated pathway for the inferior vena cava from its subcardinal segment towards the venous end of the heart in the septum transversum. The failure of development of the vena cava on the left probably accounts for the usual failure of a distinct caval fold to develop on that side. The close developmental correlation of the fold and the inferior vena cava is supported by an anomaly recorded by Hochstetter (1888) in a *Salamander maculosa* in which both the vena cava and the right caval fold were absent.

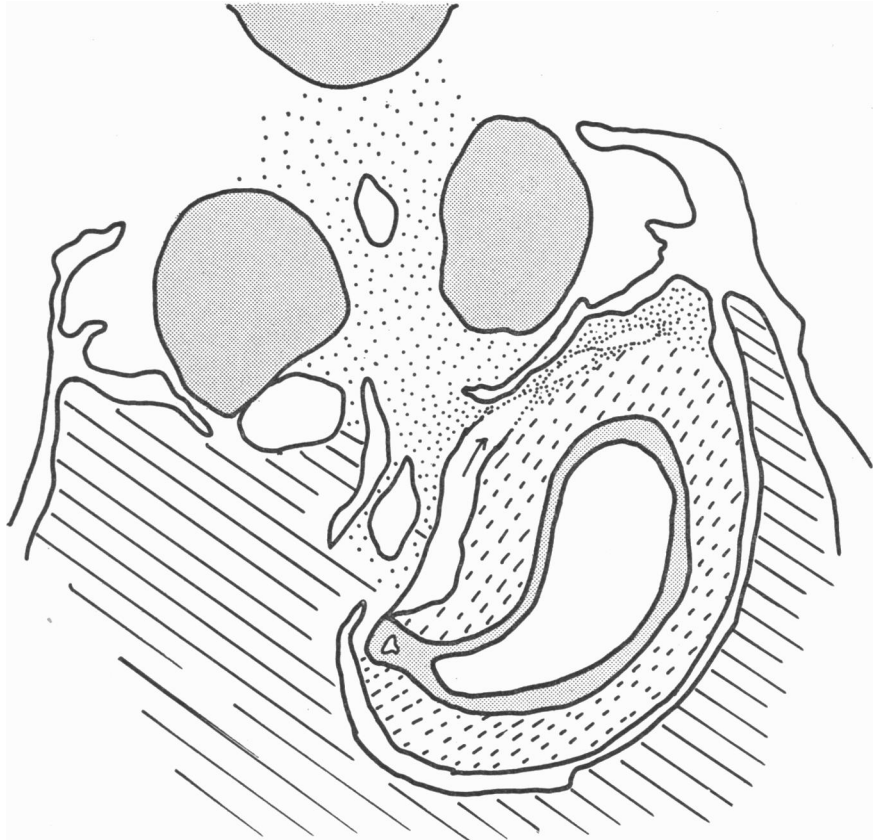
If the view that the caval fold is of septal origin be accepted, then the pneumato-enteric recess is a cavity separating the foregut tube and dorsal mesogastrium from the mesoderm of septal origin in which the whole of the liver, including the caudate

lobe, develops. The cranial portion of the pneumat-enteric recess becomes pinched off by the developing diaphragm at the 13 mm. stage to form the infracardiac bursa. The time of separation of the infracardiac bursa appears to be variable, since Broman (1904) observed that the separation of the bursa was complete in a 11·7 mm. embryo, while Vilkari (1950) found the same in a 12·5 mm. embryo. The 12·25 mm. embryo of the present series shows only a constriction without actual separation of the infracardiac bursa. The portion of the pneumat-enteric recess caudal to the diaphragm remains as the superior recess of the lesser sac. The superior recess has the stomach and dorsal mesogastrium on its left and caudate lobe on its right and ventrally, an arrangement which is retained throughout foetal and post-natal periods.

Rotation of the stomach. It is usually believed that the stomach undergoes a dextro-rotation through an angle of 90° along its longitudinal axis. Enbom (1939) was of opinion that the rotation of the stomach occurred along the dorso-ventral, lateral and sagittal axes; Pernkopf (1922), while denying a mechanical rotation along the longitudinal axis of the stomach, was unable to determine whether the changes in the stomach were due entirely to growth processes or to an actual 'rotation'. The criteria often cited in favour of the theory of rotation are the relative positions of the two gastric nerves, the attachment of the dorsal mesogastrium to the greater curvature of the stomach and the attachment of the ventral mesogastrium to the lesser curvature. If rotation of the stomach is to be judged by the change in position of the gastric nerves, then a similar rotation should also occur in the caudal, intrathoracic portion of the oesophagus, since the vagi have already assumed dorsal and ventral positions in this portion of the gut tube. In embryos of 3·8–22 mm. of this series there is no evidence of rotation of the caudal oesophagus, since this portion of the gut tube shows no change in the shape or orientation of its entodermal lumen which remains compressed from side to side throughout the series. Changes are, however, apparent in the stomach where transverse sections of the entodermal tube of 10–22 mm. embryos reveal an increasing growth and dilatation of the left surface of the stomach, while its right surface remains unaffected (Text-fig. 1A–C). This simple growth process will explain the apparent shift of the ventral mesogastrium towards the right. It may also be added that mere changes in the position of nerves cannot be regarded as proof of rotation.

It is equally erroneous to conclude that the rotation of the stomach occurs because the greater omentum, a derivative of the dorsal mesogastrium, is now attached to the greater curvature (left border) of the stomach. In the 18 mm. embryo the *gastric attachment* of the dorsal mesogastrium, when traced cranio-caudally, changes from the dorsal to the extreme left border of the stomach within a distance of 50 μ (Pl. 4, figs. 14, 15). If this is interpreted to mean that the dorsal border with its mesogastrium has rotated to become the left border of the stomach within this short distance, the 'rotation' appears to be so drastic that it is doubtful whether it could ever occur in normal development. The developmental changes occurring in the gastric attachment of the dorsal mesogastrium could be effected through an extension of the omental bursa to the left into the compound mesodermal anlage of the stomach wall and mesogastrium where previously no cavity existed (Text-fig. 2). It is perhaps due to these changes in the mesogastric attachment that the right

gastric nerve enters the dorsal surface of the stomach after traversing only the extreme cranial portion of the dorsal mesogastrium; this most cranial part of the mesogastrium is sagittally placed and is hardly affected by the growth of the omental bursa. Cases in which partial or complete septa intervene between the superior and inferior recesses afford further evidence against the dorsal mesogastric attachment as a criterion of rotation. These septa are undoubtedly remnants of the original



Text-fig. 2. Based on a section through a 17 mm. embryo (H. 25). The arrow indicates the direction of extension of the lesser sac into the compound mesoderm of the dorsal mesogastrium and the stomach wall.

dorsal mesogastrium, but they are attached to the dorsal surface of the stomach *close to the lesser curvature*. The mode of formation of the septa will be discussed later.

Boundaries of the foramen of Winslow. In the 3.8 mm. embryo, the foramen of Winslow is bounded by the dorsal and ventral lips of mesoderm which cranially continue into the caval fold (Pl. 1, fig. 2). The foramen has no definite caudal boundary at this stage. The inferior vena cava is later formed inside the dorsal lip while a portion of the right lobe of the liver grows inside the ventral lip. The caval fold is gradually invaded by liver tissue forming the caudate lobe during the 6, 7,

7-8 and 8.5 mm. stages. At the 8.5 mm. stage, the foramen is bounded ventrally by the right lobe of the liver and dorsally by the dorsal lip in which the differentiation of the inferior vena cava has not yet begun. The foramen is bounded cranially by the caval fold containing the caudate lobe of the liver, and caudally by the plica arteriae hepaticae. The foramen at this stage is directed caudally and towards the right so that in transverse sections the cavity of the lesser sac communicates with the general peritoneal cavity, ventral to the right mesonephros.

In the 10-18 mm. embryos there is usually no direct communication between the cavity of the lesser sac and the general peritoneal cavity, the two being connected with each other through a cavo-coeliac recess (Broman, 1904). This recess, which is absent in the 8.5 mm. embryo, is brought into existence by the caudal growth of the caudate lobe of the liver and by the approximation of the right suprarenal gland to the right lobe of the liver. These changes effectively seal off the original communication of the lesser sac with the general peritoneal cavity ventral to the right mesonephros, thereby enclosing a pocket of the peritoneal cavity which is bounded ventrally by the ventral mesogastrium and dorsally by the inferior vena cava. On the left of the cavo-coeliac recess lies the plica arteriae hepaticae, and on its right the caudate lobe (Pl. 4, fig. 13). The cavo-coeliac recess opens into the general peritoneal cavity either ventrally as in the 18 mm. embryo (Pl. 4, fig. 15), or dorsally as in the 17 mm. embryo (H. 640). The mode of communication depends on the extent of the caudal growth of the caudate lobe and on the caudal limit of the ventral mesogastrium.

In the 22 mm. embryo, the hepato-enteric portion of the lesser sac communicates directly with the general peritoneal cavity around an obliquely placed free margin of the ventral mesogastrium, an arrangement which to some extent resembles the adult condition. In this embryo the free margin of the ventral mesogastrium runs obliquely caudally and dorsally from the liver towards the duodenum. The final disposition, whereby the free margin of the ventral mesogastrium faces directly towards the right, is not achieved even in the 99 mm. embryo which in fact shows a cavo-coeliac recess. Although Broman (1904) thought that the cavo-coeliac recess resulted from the formation of the fold of the hepatic artery during the caudal extension of the lesser sac, the recess owes its existence partly at least to the caudal prolongation of the ventral mesogastrium, which characterizes all early embryos.

The growth of the omental bursa and the elongation of the stomach between its relatively fixed cranial and caudal ends produce a flexure of the stomach to the left so that its concave border is now directed towards the right. These changes, along with the rapid growth of the left surface of the stomach, bring about a modification in the disposition of the ventral mesogastrium from the sagittal to the coronal plane. The broad caudal limit of the ventral mesentery, which in the 3.8-6 mm. embryos extends to the region of the umbilicus, is gradually displaced cranially owing to the invasion of the peritoneal cavity ventral to the distal part of the duodenum, where in the immediately previous stages no peritoneal coelom existed. The caudal displacement of the stomach relative to the liver brings about the final change whereby the caudal free margin of the ventral mesogastrium becomes now directed towards the right.

Dorsal mesogastrium and transverse mesocolon. A part of the cranial portion of the dorsal mesogastrium stretching between the spleen and the mid-line has begun to fuse with the dorsal body wall opposite the left suprarenal gland by the 37 mm. stage. The fusion has progressed medially in the 46 and 60 mm. embryos and the fusion becomes almost complete in the 99 mm. embryo, except for a small pocket of peritoneal cavity close to the root of the dorsal mesogastrium. This mode of fusion from lateral to medial is significant, since an arrest of the process may give rise to retro-peritoneal cysts originating from isolated pockets of peritoneal cavity. The portions of the mesogastrium which fuse with the body wall appear to be incorporated with tissues forming the body wall rather than disappear after zygosis. A similar view was expressed by Pernkopf (1922).

The portion of the dorsal mesogastrium containing the pancreas is partly fused with the body wall in the 60 mm. embryo and the fusion is complete in the 99 mm. embryo. The fusion progresses from the medial towards the lateral side, thus contrasting with the cranial, supra-pancreatic portion of the mesogastrium. It is therefore apparent that the only portion of the dorsal mesogastrium to retain its primitive attachment close to the mid-line body wall is the extreme cranial part, which is later converted into the gastrophrenic ligament.

The transverse mesocolon, which is a portion of the midgut mesentery, fuses with the right free margin of the dorsal mesogastrium long before the reduction of the midgut loop from the umbilical coelom. The earliest sign of fusion was observed in the 17 mm. embryo, and the fusion was seen to progress in the 27, 37 (Pl. 5, fig. 18), 46, 60 and 99 mm. embryos. This early fusion perhaps accounts for the fact that in a congenital diaphragmatic hernia through a pleuro-peritoneal opening, herniation of the stomach is found only in those cases in which the transverse colon herniates into the pleural cavity (Paul & Kanagasuntheram).

Anomalies. According to Weiss (1939) normal and abnormal developments differ neither in principle nor in character. There is always a gradation from the normal to the grossly abnormal. Such gradation indeed exists with regard to the septum which occasionally intervenes between the superior and inferior recesses of the lesser sac. A similar conclusion was reached by Crymble (1913). A complete septum bursarum is unrecorded for any mammal except the gibbon (Kanagasuntheram, 1954). Even in the gibbon a complete septum appears to be inconstant, for recent examination of a 57 mm. *H. mulleri* foetus and of a juvenile *H. hoolock* revealed in both a narrow slit-like communication between the hepato-enteric and the pancreatico-enteric portions of the lesser sac. In the gibbon foetus, the dorsal mesogastrium continued to be attached close to the lesser curvature of the stomach up to the junction of the body and pyloric regions as in the juvenile hoolock gibbon. A similar mode of attachment of the dorsal mesogastrium was observed in the 18 mm. human embryo, and it is clear that if this condition were to persist it would give rise to a partial septum with a narrow orifice of communication between the hepato-enteric and the pancreatico-enteric portions of the lesser sac. A complete septum owes its origin to the fact that the omental bursa proper could be formed independently within the mesoderm of the dorsal mesogastrium as in the 9-10 mm. (Thurkettle) and 30 mm. embryos. Various gastric adhesions described by Reid (1913) are undoubtedly remnants of the mesogastrium.

If an independently formed pneumato-enteric recess fails to establish communication with the general peritoneal coelom, the foramen of Winslow will be lacking as in the 9–10, 30 and 60 mm. embryos described in this communication. A caudally directed foramen of Winslow, with a cavo-coeliac recess, is due to the persistence of the embryonic ventral mesentery beyond the proximal part of the duodenum. Fusion of the greater and lesser omenta to the liver and gall bladder represents an arrested phase of development and resembles the condition seen in the 17 mm. embryo. Various other minor adhesions, such as those between the caudate lobe and the stomach, between the caudate process and pancreas, or between the liver and the ventral surface of the stomach, are present in some of the embryos examined. These probably owe their origin to irregularities in the formation of the greater and lesser peritoneal cavities. Absence of fusion between the greater omentum and the transverse mesocolon which is normal for lower mammals is an arrest of development in man.

The fusion of the descending mesocolon to the posterior abdominal wall follows the same pattern as that of the supra-pancreatic portion of the dorsal mesogastrium, the fusion progressing from lateral to medial (Pl. 5, fig. 20). These findings contradict the usual belief that the fusion of the mesocolon progresses from the medial to the lateral side (Arey, 1954).

Mesodermal connections were observed between the lungs and the thoracic wall in a number of embryos, and it is therefore probable that at least some of the pleural adhesions met with in the post-mortem room are of congenital origin.

SUMMARY

The cavity of the lesser sac develops in a manner similar to the rest of the coelom by the coalescence of clefts which appear in the mesoderm lying lateral and dorsal to the caudal part of the foregut tube. The formation and fusion of these clefts are so rapid that a continuous cavity usually results.

Reasons have been adduced to show that the mesoderm of the caval fold may be of septal origin.

The position of the gastric nerves and the attachment of the dorsal mesogastrium to the greater curvature of the stomach cannot be regarded as reliable criteria in favour of a rotation of the stomach. Most changes in the stomach are explicable on simple growth processes assisted by enlargement of the cavity of the lesser sac.

Fusion of the dorsal mesogastrium to the transverse mesocolon begins long before the reduction of the midgut loop from the umbilical coelom.

Fusion of the cranial part of the dorsal mesogastrium to the posterior abdominal wall proceeds from the splenic end towards the root of the dorsal mesogastrium.

Most anomalies, including the formation of partial and complete septa in the lesser sac, are due to an arrest of fusion of the coelomic clefts which normally coalesce to form the cavity of the lesser sac.

I am much indebted to Prof. J. D. Boyd for granting me the facilities to work in his laboratory and for his continued interest and assistance throughout this work. I wish to thank Prof. W. J. Hamilton and Dr M. Abercrombie for the loan of a part

of the material used in the present investigation. My thanks are also due to my colleague, Dr M. Amerasinghe, who was kind enough to show me his dissection of the lesser sac in a full-term human foetus with a complete septum bursarum. I am grateful to Mr J. F. Crane and Mr K. W. Iles for their technical assistance.

The expenses of this investigation were defrayed by a research grant from the University of Ceylon.

REFERENCES

- AREY, L. B. (1954). *Developmental Anatomy*, 6th ed. Philadelphia and London: W. B. Saunders Co.
- BROMAN, I. (1904). *Die Entwicklungsgeschichte der Bursa Omentalis und ähnlicher Recessbildungen bei den Wirbeltieren*. Wiesbaden: J. F. Bergmann.
- BROMAN, I. (1938). Warum wird die Entwicklung der Bursa Omentalis in Lehrbüchern fortwährend unrichtig beschrieben? *Anat. Anz.* **86**, 195–202.
- CRYMBLE, P. T. (1913). Gastro-pancreatic folds—their relations to the movements of the stomach and to the subdivisions of the lesser sac. *J. Anat., Lond.*, **47**, 207–224.
- ENBOM, G. (1939). The early looping of the alimentary canal in the mammalian and human foetus and the mechanisms assumed to be active in this process. *Anat. Rec.* **75**, 409–414.
- FRAZER, J. E. (1947). *A Manual of Embryology*, 2nd ed., London: Baillière, Tindall and Cox.
- HAMILTON, W. J., BOYD, J. D. & MOSSMAN, H. W. (1952). *Human Embryology*, 2nd ed. Cambridge: W. Heffer and Sons Ltd.
- HIS, W. (1880). *Anatomie Menschlicher Embryonen*, 1. Leipzig: F. C. W. Vogel.
- HOCHSTETTER, F. (1888). Ueber das Gekröse der hinteren Hohlvene. *Anat. Anz.* **3**, 965–974.
- KANAGASUNTHERAM, R. (1954). Observations on the Anatomy of the Hoolock Gibbon. *Ceylon J. Sci. (section G, Anthrop.)*, **5**, 69–122.
- MALL, F. P. (1891). Development of the lesser peritoneal cavity in birds and mammals. *J. Morph.* **5**, 165–179.
- MALL, F. P. (1897). Development of the human coelom. *J. Morph.* **12**, 395–453.
- MALL, F. P. (1910). Coelom and diaphragm. In *Manual of Human Embryology* (Keibel and Mall), **1**, 523–548. Philadelphia and London, Lippincot.
- MÜLLER, J. (1830). Ueber den Ursprung der Netze und ihr Verhältnis zum Peritonealsacke beim Menschen, aus anatomischen Untersuchungen an Embryonen. *Meckel's Arch. Anat. Physiol.* pp. 395–411.
- PAUL, M. A. & KANAGASUNTHERAM, R. Congenital diaphragmatic hernia of Bochdalek. (In Preparation.)
- PERNKOFF, E. (1922). Die Entwicklung der Form des Magendarmkanales beim Menschen. *Z. Anat. EntwGesch.*, **64**, 136–139, 239–244, 271–273.
- RAVN, E. (1889). Ueber die Bildung der Scheidewand zwischen Brust und Bauchhöhle in Säugthierembryonen. *Arch. Anat. Physiol., Lpz.*, pp. 139–147.
- REID, G. D. (1913). Studies of the intestine and peritoneum in the human foetus. *J. Anat., Lond.*, **47**, 255–267.
- SWAEN, A. (1896). Recherches sur le développement du foie du tube digestif de l'arrière-cavité du péritoine et du mésenterè. *J. Anat., Lond.*, **32**, 76–84.
- VILKARI, S. J. (1950). A study of the bursa infra-cardiaca: development, anatomy and surgical pathology. *Ann. Chir. Gyn. Fenn.* **39**, suppl. 3, 1–97.
- WEISS, P. (1939). *Principles of Development*. New York: Henry Holt and Co.
- WELLS, L. J. (1954). Development of the human diaphragm and pleural sacs. *Cont. Embryol. Carneg. Instn.*, **35**, 107–134.

KEY TO LETTERING

<i>B.D.</i>	Bile duct	<i>Lt.Pn.R.</i>	Left pneumato-enteric recess
<i>C.C.R.</i>	Cavo-coeliac recess	<i>Lt.V.</i>	Left vagus nerve
<i>C.L.</i>	Caudate lobe of liver	<i>M.G.M.</i>	Midgut mesentery
<i>D.A.</i>	Dorsal aorta	<i>M.L.</i>	Mesodermal lips
<i>D.C.</i>	Descending colon	<i>Oe.</i>	Oesophagus
<i>D.M.</i>	Dorsal mesogastrium	<i>P.</i>	Pancreas
<i>D.M.C.</i>	Descending mesocolon	<i>Pl.A.H.</i>	Plica arteriae hepaticae
<i>D.P.</i>	Dorsal pancreatic bud	<i>P.P.C.</i>	Pocket of peritoneal cavity
<i>F.G.</i>	Foregut tube	<i>P.V.</i>	Portal vein
<i>H.E.R.</i>	Hepato-enteric recess	<i>Rt.L.B.</i>	Right lung bud
<i>I.C.B.</i>	Infra-cardiac bursa	<i>Rt.Pn.R.</i>	Right pneumato-enteric recess
<i>I.V.C.</i>	Inferior vena cava	<i>S.</i>	Spleen
<i>K.</i>	Kidney	<i>S.F.</i>	Site of fusion of <i>D.M.</i> and <i>M.G.M.</i>
<i>L.</i>	Liver	<i>S.R.</i>	Supra-renal gland
<i>L.S.</i>	Cavity of lesser sac	<i>St.</i>	Stomach
<i>Lt.L.B.</i>	Left lung bud		

EXPLANATION OF PLATES

PLATE 1

- Fig. 1. Transverse section through the cranial part of the right pneumato-enteric recess of the 3.8 mm. embryo. $\times 84$.
- Fig. 2. Transverse section at the level of the opening of the right pneumato-enteric recess into the general peritoneal coelom in the 3.8 mm. embryo. $\times 84$.
- Fig. 3. Transverse section through the dorsal pancreatic bud of the 3.8 mm. embryo. Note wide apposition of the liver and septal mesoderm with the ventral and lateral walls of the duodenal tube. $\times 84$.
- Fig. 4. Transverse section through the cranial part of the right pneumato-enteric recess of the 5 mm. (Millard) embryo. $\times 245$.

PLATE 2

- Fig. 5. Transverse section through the caudal part of the right pneumato-enteric recess of the 5 mm. (Millard) embryo. Note apposition of the liver to the dorsal mesogastrium closing the foramen of Winslow. $\times 180$.
- Fig. 6. Transverse section through the cranial end of the right pneumato-enteric recess of the 6 mm. embryo. $\times 180$.
- Fig. 7. Transverse section from the 9 mm. embryo showing obliteration of the central portion of the hepato-enteric recess. $\times 196$.
- Fig. 8. Transverse section from the 9–10 mm. (Thurkettle) embryo showing double pneumato-enteric recesses. $\times 130$.

PLATE 3

- Fig. 9. Transverse section through the cavity of the lesser sac of the 9–10 mm. (Thurkettle) embryo. Note that the lesser sac lies on the left side owing to a situs inversus. $\times 150$
- Fig. 10. Transverse section through the caudal part of the lesser sac of the 9–10 mm. (Thurkettle) embryo. Note an almost complete absence of the cavity of the lesser sac. $\times 150$
- Fig. 11. Transverse section through the free portion of the dorsal mesogastrium of the 9–10 mm. (Thurkettle) embryo. Note that the cavity of the lesser sac is larger than in the preceding section. $\times 150$.
- Fig. 12. Transverse section through the infra-cardiac bursa of the 18 mm. embryo. $\times 196$.

PLATE 4

- Fig. 13. Transverse section through the junctional region between the hepato-enteric and pancreatico-enteric recesses of the 14 mm. embryo. $\times 23$.
- Figs. 14, 15. Transverse sections from the 18 mm. embryo to show the sudden shift of the dorsal mesogastric attachment on the stomach from the dorsal to the extreme left border of the stomach. $\times 23$.
- Fig. 16. Transverse section through the region of the lesser sac of the 30 mm. embryo. Note that the cavity of the lesser sac is represented by discrete clefts. $\times 23$.

PLATE 5

- Fig. 17. Transverse section of the 46 mm. embryo showing fusion of the dorsal mesogastrium with the posterior abdominal wall opposite the left suprarenal gland. $\times 23$
- Fig. 18. Transverse section from the 37 mm. embryo showing fusion of the midgut mesentery (transverse mesocolon) with the dorsal mesogastrium. $\times 23$.
- Fig. 19. Transverse section through the hepato-enteric recess of the 60 mm. embryo. Note 'adhesions' between caudate lobe of liver and stomach. $\times 23$.
- Fig. 20. Transverse section of the 99 mm. embryo showing fusion of the descending mesocolon to the posterior abdominal wall. $\times 23$.

