

*Contemporary Themes***Hepatic reactions associated with ketoconazole in the United Kingdom**

G LAKE-BAKAAR, P J SCHEUER, S SHERLOCK

**Abstract**

Ketoconazole was introduced in the United Kingdom in 1981. By November 1984 the Committee on Safety of Medicines had received 82 reports of possible hepatotoxicity associated with the drug, including five deaths. An analysis of the 75 cases that had been adequately followed up suggested that 16, including three deaths, were probably related to treatment with the drug. Of the remainder, 48 were possibly related to treatment, five were unlikely to be so, and six were unclassifiable.

The mean age of patients in the 16 probable cases was 57.9, with hepatotoxicity being more common in women. The average duration of treatment before the onset of jaundice was 61 days. None of these well validated cases occurred within the first 10 days after treatment. The results of serum liver function tests suggested hepatocellular injury in 10 (63%); the rest showed a mixed pattern. In contrast, the results of histological examination of the liver often showed evidence of cholestasis. The characteristics of the 48 patients in the possible cases were similar. Allergic manifestations such as rash and eosinophilia were rare. Hepatitis was usually reversible when treatment was stopped, with the results of liver function tests returning to normal after an average of 3.1 months. In two of the three deaths probably associated with ketoconazole treatment the drug had

been continued after the onset of jaundice and other symptoms of hepatitis.

Clinical and biochemical monitoring at regular intervals for evidence of hepatitis is advised during long term treatment with ketoconazole to prevent possible serious hepatic injury.

**Introduction**

Ketoconazole, an imidazole derivative used to treat systemic fungal infections, has been associated with hepatic injury. Several reports have described icteric reactions with ketoconazole,<sup>1-9</sup> some fatal.<sup>10-12,14</sup> Hepatic injury without overt jaundice has also been described.<sup>2,6,13</sup> In addition, asymptomatic transient increased activity of serum transaminase has been reported in some patients.<sup>2,8,9,13</sup>

Ketoconazole was introduced in the United Kingdom in 1981. By November 1984 the Committee on Safety of Medicines had received 82 reports of possible hepatotoxicity in patients taking oral ketoconazole, including five deaths.<sup>15</sup> As a result the use of the drug is now restricted to patients who have conditions that do not respond to topical treatment. This study analyses the cases reported in the United Kingdom and examines the nature of the injury.

**Patients and methods**

By November 1984 follow up information had been obtained on 75 of the 82 cases reported on yellow cards (adverse reaction reporting forms) to the Committee on Safety of Medicines. The available data included sex and age, but in the interests of confidentiality no other details on patient identification were supplied. Also included were data on the condition being treated, relevant history, concomitant drug treatment, alcohol history, dose and duration of ketoconazole treatment, and the interval between the start of drug treatment and the onset of symptoms. The results of liver function tests, serology for hepatitis A (hepatitis A virus IgM) and hepatitis B (hepatitis B surface antigen), and large bile duct visualisation (cholecystogram, ultrasound scans, or technetium-99 *N-N'*-(2,6-dimethylphenyl)

Janssen Pharmaceutical Ltd, Grove, Wantage, Oxfordshire OX12 0DQ  
G LAKE-BAKAAR, MD, MRCP, director of medical affairs

Royal Free Hospital and School of Medicine, London NW3 2QG  
P J SCHEUER, MD, FRCPATH, professor of histopathology  
DAME SHEILA SHERLOCK, MD, FRCP, emeritus professor of medicine

Correspondence to: Dr G Lake-Bakaar, Division of Digestive Diseases, Downstate Medical Center—State University of New York, 450 Clarkson Avenue, Brooklyn, New York 11203, United States.

carbamoylmethyl iminodiacetic acid (HIDA) scans) and the final clinical outcome were also given. The results of histological examination of the liver in five cases, including three deaths, were reviewed by one of us (PJS).

**Definition of hepatic injury**—The pattern of hepatic injury was defined on the basis of the peak values for the serum liver function tests (table I). Where the results of liver function tests were not available the report was defined as unclassified.

TABLE I—Definition of hepatic injury

	Increased transaminase activity*	Increased alkaline phosphatase activity*
Hepatocellular	>eightfold	<threefold
Cholestatic	<eightfold	>threefold
Mixed	<eightfold, >eightfold	<threefold or >threefold

\*Above upper limit of normal range.

**Validation criteria**—The classifiable reports were divided into three categories of association: probable (group 1), possible (group 2), or unlikely, depending on the extent to which common causes of hepatic injury had been excluded. Table II shows the criteria on which the classification was based. The association was considered to be unlikely when there was overwhelming evidence to support an alternative diagnosis. The concomitant intake of drugs or alcohol was not included in the criteria as this is often difficult to verify.

## Results

### PROBABLE ASSOCIATION

Table III shows the 16 cases in group 1 that were considered to be related to drug treatment. Eleven patients (69%) were women. The mean (SD) age of the group was 57.9 (13.1) years (range 36 to 79). The mean duration of treatment before the onset of symptoms of hepatitis was 61.2 (five) days

TABLE II—Criteria for determining association between treatment with ketoconazole and hepatic injury

Results of hepatitis A virus and hepatitis B virus serology*	Large bile duct	Association
<i>Hepatocellular injury</i>		
Negative	No information or no obstruction	Probable
No information	No information or negative	Possible
<i>Cholestatic injury</i>		
No information or negative	No obstruction	Probable
No information or negative	No information	Possible
<i>Mixed injury</i>		
Negative	No obstruction	Probable
No information	No information	Possible

\*Non-A non-B hepatitis not excluded.

TABLE III—Details of cases of probable and possible association between treatment with ketoconazole and hepatitis. Values are numbers (%) of patients except where otherwise stated

	Probable association	Possible association
No of patients	16	48
No (%) of women	11 (69)	34 (71)
Mean (SD) age (years)	57.9 (13.1)	55.7 (16.7)
Mean (SD) duration of treatment (days) (range)	61.2 (53.5) (5-195)	44.2 (51.2) (4-270)
Daily dose:		
200 mg	6 (38)	26 (54)
400 mg	9 (56)	17 (35)
Type of hepatic reaction:		
Hepatocellular	10 (63)	6 (13)
Cholestatic		5 (10)
Mixed	6 (38)	35 (73)
Anicteric/asymptomatic	1 (6)	8 (17)
Deaths	3 (19)	2 (4)

(range five to 195). The pattern of results from the liver function tests showed primarily hepatocellular damage in 10 cases (63%); the remainder showed mixed damage. None was purely cholestatic.

Abdominal pain was a feature in two (13%) of these 16 patients. One patient was totally asymptomatic, the biochemical abnormalities being found during routine testing after six and a half months of treatment. Peripheral eosinophilia was recorded in only one patient. Hepatic failure (ascites, oedema, and encephalopathy) developed in a 78 year old woman after ketoconazole treatment 200 mg daily for three and a half months; she eventually recovered. There were three deaths. In two treatment had been continued after symptoms of hepatitis and jaundice had developed. In the third the patient seemed to be asymptomatic for two months after the drug had been stopped. Severe hepatitis and liver failure developed later.

Jaundice occurred after at least 10 days' treatment in all patients except one, who was treated for five days. In this patient jaundice occurred during the postoperative period, and other drugs, including cephadrine—probably given because of sepsis—and perphenazine, both of which are potentially hepatotoxic,<sup>16-18</sup> had been given. This case was included in group 1 only because it met the criteria established for this group (table II). The large differential diagnosis, however, suggests a possible rather than a probable association.

The results of histological examination of the liver were available for three patients who died and two who survived. The first fatality was a 63 year old woman treated with 400 mg ketoconazole daily for a candidal nail infection. A histological examination of specimens of liver taken at necropsy showed evidence of severe hepatitis with early regeneration (fig 1). In many parts multiacinar necrosis was seen, while in others the surviving liver tissue

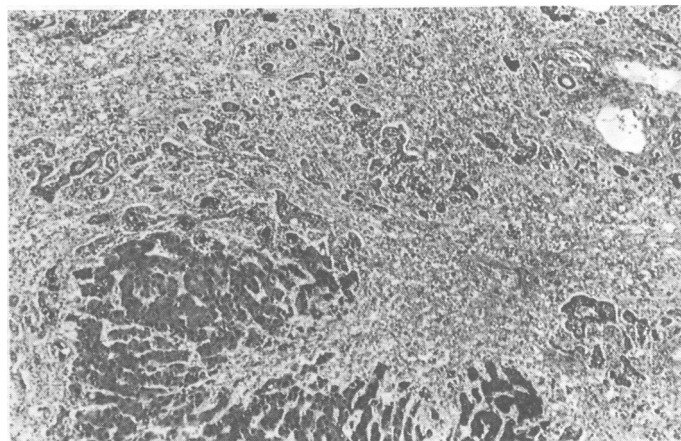


FIG 1—Liver sample, stained with chromotrope aniline blue, taken at necropsy showing surviving hepatocytes (lower left) and proliferated duct like structures (above).

showed necrosis predominantly in acinar zone 3 as well as bridging between portal tracts and terminal hepatic venules. There was a moderate, mixed inflammatory infiltrate in the sections with necrosis as well as in portal tracts, which contained many proliferated bile ducts. Cholestasis in the form of bile thrombi within canaliculi was seen in surviving parenchymal areas. The changes were not like those seen after a reaction such as that caused by paracetamol toxicity and were consistent with either drug idiosyncrasy or viral hepatitis.

The second patient was a 70 year old man with mitral valve disease who had been treated for a fungal toe infection with 200 mg ketoconazole daily. Many of the histological changes seen in specimens of liver taken at necropsy were considered to be secondary to the underlying cardiac disease. Such changes included extensive fibrosis in perivenular regions and some old fibrous narrowing of veins. Bridging fibrosis was also present, and there was moderate inflammatory infiltration. Frank necrosis was not evident, and the minor degree of liver cell degeneration seen was consistent with agonal hypoperfusion injury. There was severe canalicular cholestasis (fig 2), the cause of which could not be established with certainty but which was compatible with injury by drugs.

The third death was that of a 57 year old woman who had been treated for 28 days with 400 mg ketoconazole for chronic monilial vulvovaginitis. About eight weeks after she stopped taking ketoconazole she developed malaise and later became jaundiced. The results of liver function tests suggested a primary hepatocellular pattern of liver damage. Five weeks after the onset of jaundice she died in hepatic failure. A small needle biopsy specimen showed panacinar necrosis with proliferation of bile ductules and infiltration by lymphoid cells and segmented leucocytes. The surviving parenchyma

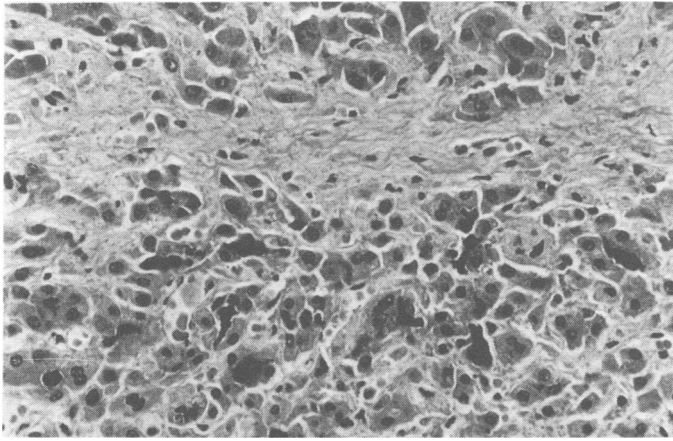


FIG 2—Liver sample, stained with haematoxylin and eosin, taken at necropsy showing severe cholestasis in form of dark bile plugs in dilated canaliculi between hepatocytes. The pale staining fibrous septum crossing the field is thought to be the result of longstanding venous congestion.

showed cholestasis and evidence of regeneration in the form of thickened liver cell plates. The appearance was like that caused by severe hepatitis starting some weeks or months previously. In all three patients who died bile was present in ductules of a type described in sepsis.<sup>19</sup>

One of the two liver biopsy specimens taken from patients who did not die showed minimal infiltration of the portal tracts, evidence of recent loss of liver cells, in the form of ceroid laden macrophages and reticulum condensation, and cholestasis. The second specimen showed canalicular cholestasis in perivascular regions that had little inflammation but mild hepatocellular swelling and increased multinucleation. The cholestasis that showed up on histological examination was probably induced by drugs but the possibility that it, like the ductular cholestasis, was related to sepsis could not be completely excluded.

#### POSSIBLE ASSOCIATION

Group 2 comprised 48 patients who had had reactions possibly related to ketoconazole (table III). Thirty four (71%) were women. The mean (SD) age was 55.7 (16.7) years (range 17 to 93), and the average duration of treatment was 44.2 (51.2) days (range four to 270). Two patients died. In four patients symptoms appeared after fewer than 10 days' treatment. In three patients peripheral eosinophilia, erythema nodosum, or rash was observed. In all patients the results of the liver function tests returned to normal when treatment was stopped. No histological examinations were performed on liver specimens from any of these patients.

#### UNLIKELY ASSOCIATION

It was considered that five cases were unlikely to be associated with ketoconazole treatment as there were alternative and more likely causes for the liver injury—for example, Gilbert's disease, gall stones, phenytoin associated hepatitis, and, in two patients, intrahepatic cholestasis associated with septicaemia.

#### UNCLASSIFIED CASES

Six cases were considered to be unclassifiable, as the results of liver function tests were not available.

#### Discussion

The findings reported here are similar to those described previously.<sup>6, 14, 20</sup> In the 33 cases described by Lewis *et al* 55% of the patterns obtained from liver function tests showed primarily hepatocellular damage and 25% showed mixed damage.<sup>14</sup> In contrast with our histological findings, however, cholestasis was not a major histological feature in any of their three patients for whom the results of histological examination were available.

The age and sex distribution of patients developing liver reactions to ketoconazole may merely reflect the profile of patients treated with the drug. Other workers, however, have described a considerable contrast between the age distribution of patients who develop hepatitis and the age distribution of patients in whom the drug is used.<sup>6, 20</sup> In common with many hepatic drug reactions middle aged women seem to be particularly susceptible.

Most patients recovered when they stopped taking the drug, the results of their liver function tests returning to normal within an average of 3.1 months (range seven days to six months). Of the three fatal cases in group 1, two patients had continued to receive treatment after symptoms of hepatitis and jaundice had developed, a pattern described in previous reports.<sup>6, 14</sup> In the third the results of histological examination of the liver suggested that subclinical hepatitis with severe necrosis might have occurred initially during treatment with the drug. The patient remained asymptomatic for two months but later developed hepatic decompensation. To our knowledge this is the first such case described, and it underlines the need for regular biochemical monitoring during prolonged treatment.

The mechanism of liver damage induced by ketoconazole is unclear. The reaction seems to be idiosyncratic. The low incidence of fever, rash, and eosinophilia and the absence of eosinophil rich infiltrations or granulomas in liver tissue are uncharacteristic of an immune mediated reaction, as is the variable duration of drug administration before the onset of liver injury (four to 270 days). This variability has been reported previously.<sup>6, 14</sup> No rechallenge with the drug was well documented for our patients. Other workers, however, have found that rechallenge is not followed by prompt recurrence as might be expected in an allergic phenomenon.<sup>3</sup> Though a second course of treatment in two of the patients in group 2 was followed by a prompt recurrence of the reaction, the poor record of liver dysfunction makes interpretation difficult. The possibility that immune hypersensitivity mechanisms may be partly responsible for liver damage cannot therefore be totally excluded.

Paracetamol is one of many metabolites of ketoconazole in the dog.<sup>21</sup> Paracetamol overdose leads to liver damage in man. The amount of paracetamol generated by the normal therapeutic dosage of ketoconazole, however, is unlikely to be significant. Furthermore, the results of histological examination were not characteristic of paracetamol toxicity.

Recent data have suggested that ketoconazole might interfere with the synthesis of deoxyribonucleic acid (DNA).<sup>22</sup> This might result in cumulative damage over a variable period, culminating in overt dysfunction of liver cells. The idiosyncratic nature of the damage might be due to genetically determined differences in DNA repair mechanisms or to individual differences in drug metabolism.

Serious hepatic toxicity caused by ketoconazole treatment is rare and has been estimated to be about 1/15 000 exposed patients.<sup>14</sup> Our results confirm those of Lewis *et al*, which showed that hepatitis caused by ketoconazole is rare during the first week of treatment.<sup>14</sup> The risks are therefore minimal with treatment of short duration (<10 days) but seem to be greater with prolonged treatment. Hepatitis associated with ketoconazole is usually reversible when treatment is stopped. Fatal cases have occurred when treatment has been continued after symptoms of hepatitis have developed. Data from one of the cases described in this report suggest that severe hepatitis may occur subclinically during prolonged treatment with ketoconazole. It is currently not possible to predict which individuals are susceptible to liver damage, so it would seem prudent to instruct patients to stop following the treatment as soon as any symptoms suggestive of hepatitis (malaise, dark urine, pruritus) occur and before overt jaundice develops. Liver function tests should be performed before treatment to exclude hepatitis. Biochemical tests should be performed after the first 10 days of treatment and then twice a month during treatment with ketoconazole.

Transient asymptomatic increases in serum transaminase activity also occur during treatment with ketoconazole<sup>6</sup> as during treatment with several other drugs. These increases are generally considered to be harmless but should alert the doctor to perform a further test within one week, as they could signal early hepatotoxicity. If the

activity of serum transaminases increases progressively or rises significantly (>threefold) above normal or symptoms develop treatment should be stopped.

We thank the Committee on Safety of Medicines for making available the data reported on yellow cards on suspected adverse hepatic reactions to ketoconazole. We also thank the staff of the medicines division, Department of Health and Social Security, for their cooperation, especially Dr Mary Glen-Bott, who collated many of the yellow card data and organised the follow up. Finally, we acknowledge the help of the several histopathologists who provided liver biopsy material.

## References

- 1 Firebrace DAJ. Hepatitis and ketoconazole therapy. *Br Med J* 1981;283:1058-9.
- 2 McNair AL, Gascoigne E, Heap J, Schuermans V, Symoens J. Hepatitis and ketoconazole therapy. *Br Med J* 1981;283:1058.
- 3 Heiberg JK, Sveigaard E. Toxic hepatitis during ketoconazole treatment. *Br Med J* 1981;283:825-6.
- 4 Sveigaard E, Ranek L. Hepatic dysfunction and ketoconazole therapy. *Ann Intern Med* 1982;96:788-9.
- 5 Tkach JR, Rinaldi MG. Severe hepatitis associated with ketoconazole therapy for chronic mucocutaneous candidiasis. *Cutis* 1982;29:482-3.
- 6 Janssen PAJ, Symoens J. Hepatic reactions during ketoconazole treatment. *Am J Med* 1983;74:80-5.
- 7 Rollman O, Loof L. Hepatic toxicity of ketoconazole. *Br J Dermatol* 1983;108:376-8.
- 8 Janssen PAJ, Cauwenbergh G, Symoens J. *Hepatic reactions during ketoconazole treatment: a one year update*. Beerse, Belgium: Janssen Pharmaceutica, 1983.
- 9 Strauss JS. Ketoconazole and the liver. *J Am Acad Dermatol* 1982;6:546-7.
- 10 Dreis MW. *Nizoral (ketoconazole) fatal hepatic necrosis*. Rockville, Md: FDA Division of Drug Experience, 1982. (ADR Highlight No 82-6; 20 July.)
- 11 Duarte PA, Chow CC, Simmons F, Ruskin J. Fatal hepatitis associated with ketoconazole therapy. *Arch Intern Med* 1984;144:1069-70.
- 12 Bercoff E, Bernuau J, Degott C, et al. Ketoconazole-induced fulminant hepatitis. *Gut* 1985;26:636-8.
- 13 Petersen EA, Alling DUV, Kirkpatrick CH. Treatment of chronic cutaneous candidiasis with ketoconazole: a controlled clinical trial. *Ann Intern Med* 1980;93:791-5.
- 14 Lewis JH, Zimmerman HJ, Benson GD, Ishak KG. Hepatic injury associated with ketoconazole therapy. Analysis of 33 cases. *Gastroenterology* 1984;86:503-13.
- 15 Goldberg A. *Oral ketoconazole and liver damage*. London: Committee on Safety of Medicines, 1985. (Adverse Reactions Series No 19.)
- 16 Fung-Herrera CG, Mulvaney WP. Nephrohepatotoxicity of cephalixin. *JAMA* 1974;229:318.
- 17 Eggleston SM, Belandres MM. Jaundice associated with cephalosporin therapy. *Drug Intell Clin Pharm* 1985;19:553-5.
- 18 Rodriguez M, Paronetto F, Schaffner F, Popper H. Antimitochondrial antibodies in jaundice following drug administration. *JAMA* 1969;208:148-50.
- 19 Lefkowitz JH. Bile ductular cholestasis: an ominous histopathologic sign related to sepsis and "cholangitis lenta." *Hum Pathol* 1982;13:19-24.
- 20 Cauwenbergh G. *Development of idiosyncratic hepatic dysfunction during treatment with ketoconazole: worldwide situation in March 1984*. Beerse, Belgium: Janssen Pharmaceutica, 1984.
- 21 Ortho Pharmaceutical Corporation. *The excretion and biotransformation of ORF 15400 (R41400) in the adult beagle dog after oral administration of the tritium labelled drug*. New Jersey: Ortho Pharmaceutical Corporation, 1978.
- 22 Buttke TM, Chapman SW. Inhibition by ketoconazole of mitogen-induced DNA synthesis and cholesterol biosynthesis in lymphocytes. *Antimicrob Agents Chemother* 1983;24:478-85.

(Accepted 20 November 1986)

## MATERIA NON MEDICA

### Craftsman at work

Outside toilets were ubiquitous in my northern childhood. With grants and rising affluence (or effluence), inside toilets were installed, and outside "lavs" were demolished or converted to sheds. My prewar house still had its outside toilet and adjoining washhouse, and, having a week's holiday, I decided to demolish the dividing wall and two sides to expand it into a sizable workshop. A friend who was a builder agreed to help with the bricklaying, with me as his "mate."

I demolished the necessary walls, laid the foundations, and salvaged any reusable bricks. Chipping off the black lime was frustrating. Some pieces fell off with one blow. Others didn't give up a fifty year attachment easily. I would have made the mortar with a ready made mix ("just add water and stir") but the pro insisted we made it ourselves, "four of sand to one of cement." I duly obliged. My friend frowned as he cut the mortar with his trowel. Like a chef with a sauce he added a soupçon more cement and a dash of water, and smiled (it seemed pretty much the same to me).

His trowel became an extension of his arm. He made the bricks seem featherweight as he effortlessly juggled them and buttered them with mortar. Crouching on his haunches, he gave a gentle tap here, a nudge there with the handle of his trowel, straightening out imperceptible leanings. Half bricks were needed. With a blow from his trowel blade he was able to break a brick, neatly, cleanly, and in the place required.

Keen to learn new skills, I had a go. It looked straightforward. After the first two layers of bricks it was obvious which ones I had laid. The level, neat, professional layering was replaced by a slightly askew, irregular, off centre patchwork. My friend took a sharp intake of breath, but as the mortar was still wet he rescued the situation. A bit more mortar to raise this brick up, a bit scraped out to level that one, a few taps here and there, and there was no difference.

The building took shape. The corners were right angles, the walls straight, and the door fitted neatly into the frame. Years of experience showed in subtle touches, measurements judged by eye, minute realignments. The pointing was finished off and the "new" outhouse was completed. Admiring the result, I wished that I had learnt a trade.—CHARLES ESSEX, clinical medical officer, Huddersfield.

### Birthday bidding

From the descending jumbo, Singapore's Chinatown had been a Legoland of skyscrapers, but close up on a warm Saturday night the streets seemed dilapidated. Signs were bilingual and exotic: "May Sin, Hairdresser," "Oriental Slasher Emporium" (prices, I hoped), and, on the back of a car, "Another Toyota from Borneo Motors."

Through the silence among the shuttered shops came an imperative monotone like a country auctioneer's; when I headed towards it I found a street party. A roof had been erected over the roadway with lights and electric fans hanging from the temporary rafters. A few hundred Chinese

people sat in family groups at round tables, the men in open necked shirts, the little girls in party frocks. Food was being cooked at temporary barbecues on the pavements, and on a dais a perfectly bald auctioneer with a microphone and a team of assistants was working hard to sell ornaments and potted plants. A huge red shrine had been set up with rows of small brass bowls in front of tiers of painted figures, and six foot ornamental candles stood unlit nearby.

I stared from a distance—a solitary European—as a ceremonial dragon worked by a dozen men with poles danced round the shrine, its jaw flapping and short brightly coloured antennae wobbling. When I asked a bystander if I could buy beer from a trestle table I was made to sit as a guest while one man found a glass, two more produced bottles of beer, and another brought a paper cup full of ice cubes. A young woman with a beautiful toddler explained that tomorrow was their god's birthday. The auction suddenly ended and people streamed slowly away, pausing to buy handfuls of incense sticks and place them in the brass bowls. "Come back tomorrow," I was told, "and see the procession."

At noon next day the parade set off: lorries—old Bedfords and new Mitsubishis—bright with banners and flags, deafening percussion bands with gongs and drums, baggy trousered boys waving more flags, men carrying long leafy boughs with lemonade bottles tied to one end, a self conscious god walking along in frightening makeup and a green costume, and the sinuous dancing dragon. No women took part, and only a few spectators watched as the procession wound its halting way past dusty building sites before disappearing out of the sun's glare between the shining, silent skyscrapers.—JAMES DRIFE, Leicester.

*Is it harmful to a juvenile diabetic to substitute sorbitol and fructose for ordinary sugar?*

Since sorbitol and fructose are more slowly absorbed and have only a small immediate effect on blood glucose concentration these carbohydrates have been recommended as substitutes for ordinary sugar (sucrose, glucose, etc) in diabetic patients. Special diabetic products (diabetic jam, marmalade, chocolates, etc) which contain these substances, however, are sometimes taken in the mistaken belief that they contain fewer calories. Sorbitol if taken in large amounts may produce intestinal side effects, especially osmolar diarrhoea. Both fructose and sorbitol (which is converted to fructose in the liver) can increase plasma triglyceride, lactate, and urate concentrations. The British Diabetic Association in its dietary recommendations has advised that sorbitol and fructose intake should each be limited to 25 g (just under 1 oz) a day. Diabetic food products containing these substances are expensive, do not have an important role in diabetic diets, and their use is generally not encouraged.—BASIL F CLARKE, consultant physician in diabetes, Edinburgh.