



Role of Liver Transplantation in Cancer Therapy

SHUNZABURO IWATSUKI, M.D., ROBERT D. GORDON, M.D., BYERS W. SHAW, JR., M.D.,
THOMAS E. STARZL, M.D., PH.D.

*From the Department of Surgery, University of Pittsburgh
School of Medicine, Pittsburgh, Pennsylvania*

Fifty-four patients underwent total hepatectomy and liver replacement in the presence of a primary liver malignancy. In 13 recipients in whom the hepatic tumors were incidental to some other endstage liver disease, recurrence was not seen and 12 of the 13 patients are alive after 4 months to 15½ years. In contrast, tumors recurred in 3 of every 4 patients who received liver replacement primarily because of hepatic malignancies that could not be resected by conventional techniques of subtotal hepatectomy and who lived for at least 2 months after transplantation. The most encouraging results were in patients with the fibrolamellar hepatocellular carcinomas that grow slowly and metastasize late, but even with this lesion, the recurrence rate was 57%. In future trials, additional effective anticancer therapy will be needed to improve the results of liver transplantation for primary liver malignancy, but what an improved strategy should be has not yet been defined.

A recent review of our 54 patients who received orthotopic liver transplantation in the presence of primary hepatic malignancy has provided a more definitive idea of the role of liver replacement in cancer therapy.

Case Material and Methods

During the 22-year period of March 1, 1963, to March 3, 1985, 500 patients with various liver diseases received orthotopic liver transplants. Treatment was provided at the University of Colorado Health Sciences Center until the end of 1980 and at the University Health Center of Pittsburgh thereafter. Fifty-four (10.8%) of the 500 recipients had transplantation in the presence of a primary hepatic malignancy. They were divided into two groups for analysis.

Group I consisted of 13 patients who had liver replacement primarily to treat an endstage non-neoplastic liver disease, but who were found to have a coincidental primary hepatic malignancy either before transplantation or after examination of the excised whole liver (Table 1). The tumors could have been totally removed by partial hepatectomy, if the liver had not been so seriously diseased. In contrast, Group II consisted of 41 patients whose sole or principal reason for liver replacement was a malignancy that could not be removed by subtotal hepatectomy (Table 2). The patients in both Groups I and II were stratified according to whether immunosuppression was with azathioprine, corticosteroids, and antilymphocyte globulin (ALG), as in Subgroup A, or, after March 1980, with cyclosporine and corticosteroids, as in Subgroup B.

IN THE EARLY TRIALS of liver transplantation, an unequivocal indication for liver replacement was thought to be a primary hepatic malignancy that could not be removed by conventional techniques of subtotal hepatic resection. Enthusiasm for the approach was dampened in several major centers by the high recurrence rates of original malignancies.¹⁻⁴ Nevertheless, the impulse to treat malignant tumors by liver transplantation is still present today because of: (1) the lack of other effective therapy; (2) rare examples of cure of malignancy by total hepatectomy and liver replacement; and (3) the improved overall survival after liver transplantation with cyclosporine-steroid therapy in recent years.

Presented at the 105th Annual Meeting of the American Surgical Association, April 25-27, 1985, New Orleans, Louisiana.

Supported by Research Grants from the Veterans Administration and Project Grant No. AM-29961 from the National Institutes of Health, Bethesda, Maryland.

Reprint requests: Shunzaburo Iwatsuki, M.D., Department of Surgery, 3601 Fifth Avenue, Room 103 Falk Clinic, Pittsburgh, PA 15213.

Submitted for publication: April 29, 1985.

TABLE 1. Fate of 13 Patients Who Had Liver Transplantation Primarily for Endstage Non-neoplastic Liver Disease, But Who Had Incidental Primary Liver Malignancies as well (Group I)

Patient	Age (Yr.)	Sex	Primary Indication for Transplant	Nature of Liver Malignancy	Survival	Tumor Recurrence
Group I-A: Immunosuppression with Azathioprine + Prednisone + ALG						
OT 33	3	F	Biliary atresia	Hepatocellular carcinoma	Alive 15½ yrs.	No
OT 80	7	F	Biliary atresia	Hepatocellular carcinoma	Died 1 day after surgery	No residual tumor at autopsy
OT 142	5	F	Alpha-1-antitrypsin deficiency disease	Hepatoblastoma	Alive over 7½ yrs.	No
Group I-B: Immunosuppression with Cyclosporine + Prednisone						
OT 198	47	F	Alpha-1-antitrypsin deficiency disease	Hepatocellular carcinoma	Alive 3½ yrs.	No
OT 206	2	F	Tyrosinemia	Hepatocellular carcinoma	Alive 3½ yrs.	No
OT 222	7	F	Sea-blue histiocyte syndrome	Hepatocellular carcinoma	Alive 3¼ yrs.	No
OT 288	21	F	Tyrosinemia	Hepatocellular carcinoma	Alive 2 yrs.	No
OT 344	52	M	Alcoholic cirrhosis	Hepatocellular carcinoma	Alive 16 mos.	No
OT 356	3	F	Tyrosinemia	Hepatocellular carcinoma	Alive 15 mos.	No
OT 379	8	F	Biliary atresia	Hepatocellular carcinoma	Alive 12 mos.	No
OT 400	3	M	Tyrosinemia	Hepatocellular carcinoma	Alive 11 mos.	No
OT 475	9	M	Alagille's syndrome	Hepatocellular carcinoma	Alive 4 mos.	No
OT 483	45	F	Cirrhosis, HBsAg-pos.	Hepatocellular carcinoma	Alive 4 mos.	No

The patient identification number (OT), age, sex, diagnosis, survival as of April 15, 1985, tumor recurrence, and main cause of death for all patients are listed in Tables 1 and 2. The recipient ages ranged from 2 to 68 years (mean: 30). There are 22 males and 32 females. There were 37 hepatocellular carcinomas (HCC), of which seven were the fibrolamellar variant. The other tumors were eight bile duct carcinomas (Klatskin tumors), three epitheloid hemangioendothelial sarcomas, two cholangiocarcinomas, and one each hepatoblastoma, angiosarcoma, adenocarcinoma of unknown primary site, and sarcoma of undetermined cell type (Table 3).

Results

Residual Tumor

No patients with primary liver malignancy who underwent liver transplantation were known preoperatively to have extrahepatic involvement. However, three patients of Group II (OT 114, 305, and 473) were left with gross residual neoplasm at the time of transplantation. One (OT 114) with sarcoma of undetermined cell type had fine metastases to the lung and peritoneum. She is still alive and well without any signs of tumor regrowth more than 8 years later. Another woman (OT 305) with hemangiosarcoma had metastases to the lungs and omentum at the time of transplantation. When she died 3 months after operation as the result of pneumonia and liver graft failure, her autopsy also revealed metastases to the bone marrow. The third patient (OT 473) had adenocarcinoma of unknown primary site with metastases to abdominal lymph nodes at the time of transplantation. This patient is alive

and well without any clinical and radiological evidence of tumor enlargement or further metastasis in the fifth post-transplant month.

Eleven other patients in Group II (OT 2, 3, 4, 5, 6, 17, 25, 79, 185, 234, 251) died within 2 months from various complications of liver transplantation. Before operation, all 11 were thought to be free of extrahepatic tumor. At autopsy, only one patient (OT 4) had gross or histopathologic evidence of residual neoplasm. This patient, who survived only 5 days after liver transplantation, had metastatic cholangiocarcinoma in the lungs, vertebra, kidneys, and some abdominal lymph nodes. The remaining 10 patients were tumor free insofar as this could be determined from complete post-mortem examination, indicating that screening for candidacy had been grossly accurate in the great majority of cases.

Tumor Recurrence

With incidental malignancies. In Group I, 12 of the 13 patients whose excised livers contained incidental primary liver malignancies are still alive and well without evidence of tumor recurrence after 4 months to more than 15 years (median: 16 months) (Table 1). Eleven of the 12 surviving patients, as well as the patient who died, had hepatocellular carcinoma. The other recipient had a hepatoblastoma.

With unresectable malignancies. In Group II, 30 of the 41 patients whose main reason for liver transplantation was primary liver malignancy, survived for at least 2 months after transplantation and thus became available for meaningful observations about recurrence. The 30 recipients included the three (OT 114, 305, 473) who were

found at transplantation to have extrahepatic involvement, as described in the preceding section. The other 27 (Table 4) were considered to have all gross tumor removed by total hepatectomy.

In 20 (74%) of the 27 patients who were made potentially tumor free by transplantation, the original tumor recurred after 1 to 42 months (median: 8 months). Non-fibrolamellar hepatocellular carcinoma recurred in nine (82%) of 11 patients, all within a year (median: 4 months) (Table 4). Recurrence of fibrolamellar hepatocellular carcinoma also was seen in four (57%) of seven patients (Table 4) but always after 1 year (median: 15 months). Four of the five bile duct carcinomas recurred, two before and two after the 1-year mark; the exceptional patient who did not have a recurrence died of other causes only 2 months after the operation. Two of the three epitheloid hemangioendothelial sarcomas recurred within a year. One patient with cholangiocarcinoma developed a tumor recurrence in the 15th postoperative month.

Patient Survival

The overall results after liver transplantation have improved greatly since the introduction of cyclosporine-steroid therapy in March 1980.⁵ Since this time, the survival expectation at 1 postoperative year and each year thereafter for at least 5 years has more than doubled compared to that previously obtained with azathioprine, prednisone, and ALG (Fig. 1). The projected actuarial 5-year survival in all patients treated since 1980 is 63%.

Group I tumor patients. Twelve of the 13 patients who had incidental hepatic malignancies are still alive from 4 months to 15½ years after surgery (Table 1). The only mortality was of a patient treated with azathioprine, prednisone, and ALG (Subgroup A), who died on the first postoperative day. The two other patients of Subgroup A, as well as all 10 of the recipients treated with cyclosporine and steroids (Subgroup B), are living (Table 1).

Group II tumor patients. Of the 20 patients of Subgroup A who were treated with azathioprine, prednisone, and ALG, 13 (65%) had died by the end of the first 6 months. At the end of the year, only 6 (30%) remained alive, of whom all but one have subsequently died (Fig. 2). The single survivor, now 8¾ years after surgery, had a sarcoma of undetermined cell type with peritoneal and pulmonary metastases at the time of transplantation.

The patients of Subgroup B had greatly improved early postoperative results, with a 6-month actuarial survival of more than 80%. This reflected the better overall prognosis for early recovery using cyclosporine-steroid therapy. However, after the half-year mark, survival continued to decline, primarily because of the recurrent disease, as will be described in the next two sections. The actuarial 1- and 3-year survivals in the cyclosporine-treated patients

are projected at 68% and 25% (Fig. 2). At the present time, only 10 (48%) of the original 21 recipients in Subgroup B are still alive after 4 months to 3¾ years. One of the survivors (at 4 months) is a patient who had tumor positive regional lymph nodes at the time of transplantation, and four others are living with known recurrences.

Main Causes of Group II Patient Deaths

Thirty of the 41 patients whose principal reason for liver transplantation was the presence of a primary liver malignancy had died before April 15, 1985. Twenty-one of the 30 deaths were within 1 year after transplantation, and five of the 21 deaths were directly caused 5 to 12 months after transplantation by tumor recurrence. The rest of the deaths during the first year were due to non-neoplastic complications such as graft failure or infections, or both (Table 2); the majority of these cases were from our early experience before 1970. Of the nine deaths that occurred a year or more after transplantation, eight were caused directly by tumor recurrence (Table 2). Thus, the shape of the life survival curves both before and after the introduction of cyclosporine was dominated from the fifth month onward by the deadly effects of tumor recurrence.

Histology versus Survival in 41 Group II Patients

Of the seven patients with fibrolamellar hepatocellular carcinoma, one, who is free of tumor after 5 months, has too short a follow-up to merit comment. The other six lived for at least 1 year and were thought to be free of tumor at the end of that time. Subsequently, metastases developed in four of the six recipients, of whom two died. The two patients who are living with known recurrent fibrolamellar neoplasms have been followed for 17 and 36 months, and one has seemed to respond to adriamycin and other chemotherapeutic agents.

In contrast, patients with nonfibrolamellar hepatocellular carcinomas had earlier and more lethal metastases. Of 25 such recipients, two who are alive after 5 and 6 months have too short a follow-up to be discussed. Of the other 23, five lived for as long as 1 year, at which time all but one had known metastases. The four who had metastases at 1 year died 12 to 17 months after transplantation; the fifth patient remains tumor free after 15 months. Thus, the conventional hepatomas carried a far poorer prognosis than the fibrolamellar variant.

Of the 16 patients with malignancies other than hepatocellular carcinoma, six lived more than 1 year, and one (OT 473) is alive in the fourth month (Table 4).

Location of Recurrences

The grafted liver and the lung were the two organs most commonly affected by tumor recurrence (Table 2). The

TABLE 2. Fate of 41 Patients Who Had Liver Transplantation Because of Primary Liver Malignancy

Patient	Age (Yr.)	Sex	Primary Indication for Transplant	Coexisted Liver Disease	Timing and Location of First Recurrence or (Location of Residual Tumor)	Treatment for Recurrence	Organs Ultimately Involved by Tumor	Survival	Main Cause of Death
Group II-A: Immunosuppression with Azathioprine + Prednisone + ALG									
OT 2	48	M	Hepatocellular carcinoma	Post-necrotic cirrhosis	(No residual tumor)	—	—	Died < 1 mo.	Pulmonary emboli, sepsis
OT 3	68	M	Bile duct cancer (Klatskin tumor)	—	(No residual tumor)	—	—	Died < 1 mo.	Sepsis, pulmonary emboli, GI-bleeding
OT 4	52	M	Cholangiocarcinoma	Post-necrotic cirrhosis	(Residual: bone, lung, kidney, lymphnodes)	—	—	Died < 1 mo.	Graft failure, sepsis, pulmonary emboli
OT 5	29	F	Hepatocellular carcinoma	Post-necrotic cirrhosis	(No residual tumor)	—	—	Died < 1 mo.	Sepsis, bile peritonitis, graft failure
OT 6	29	M	Hepatocellular carcinoma	—	(No residual tumor)	—	—	Died < 1 mo.	Graft failure, sepsis
OT 8	2	F	Hepatocellular carcinoma	—	3 mos.; lungs	Chemotherapy, radiation, debulking	Lungs, liver, brain, other abdominal organs	Died/14 mos.	Carcinomatosis
OT 14	16	F	Hepatocellular carcinoma-FL*	—	13 mos.; liver, diaphragm, retroperitoneum	None	Liver, diaphragm, pancreas, peritoneum	Died/15 mos.	Carcinomatosis, infection after retransplant
OT 15	43	M	Hepatocellular carcinoma	Post-necrotic cirrhosis	2 mos.; lungs	None	Lungs, liver, diaphragm	Died/12 mos.	Carcinomatosis
OT 17	24	F	Hepatocellular carcinoma	—	(No residual tumor)	—	—	Died/2 mos.	Pneumonitis
OT 23	15	M	Hepatocellular carcinoma	—	1 mo.; lungs	None	Lungs, liver, brain, peritoneum	Died/5 mos.	Carcinomatosis
OT 25	45	M	Hepatocellular carcinoma	—	(No residual tumor)	—	—	Died/2 mos.	Bile peritonitis, sepsis, graft failure
OT 26	11	F	Hepatocellular carcinoma	Biliary atresia	3 mos.; lungs	None	Lungs	Died/3 mos.	GI-bleeding, sepsis
OT 45	53	M	Epitheloid hemangioendothelial sarcoma	—	2 mos.; lungs, liver	None	Lungs, liver, brain, spleen, kidneys	Died/3 mos.	Sarcomatosis
OT 78	48	F	Bile duct cancer (Klatskin tumor)	—	21 mos.; liver, bile duct	Radiation	Liver, bile duct	Died/25 mos.	Tumor recurrence
OT 79	60	M	Bile duct cancer (Klatskin tumor)	—	(No residual tumor)	—	—	Died < 1 mo.	Graft failure due to bile duct obstruction
OT 90	41	M	Bile duct cancer (Klatskin tumor)	—	42 mos.; bile duct	radiation	Bile duct, liver, duodenum	Died/54 mos.	Tumor recurrence
OT 102	51	F	Bile duct cancer (Klatskin tumor)	—	None	—	—	Died/3 mos.	Candidiasis, brain abscess
OT 111	9	F	Hepatocellular carcinoma	Tyrosinemia	None before autopsy	—	Micrometastasis in lung and para-aortic nodes at autopsy	Died/3 mos.	Portal vein thrombosis, death during retransplant
OT 114	27	F	Sarcoma of undetermined cell type	—	(Fine intra-abdominal and pulmonary metastasis at transplant)	None	No recurrence over 8 yrs.	Alive/8½ yrs.	—
OT 121	32	F	Hepatocellular carcinoma	—	None	None	None	Died/6 mos.	Brain injury after falling, inanition, pneumonia
Group II-B: Immunosuppression with Cyclosporine + Prednisone									
OT 172	24	M	Hepatocellular carcinoma-FL*	—	30 mos.; pelvis	None	Pelvis, rectum, bladder, peritoneum	Died/33 mos.	Carcinomatosis, pulmonary emboli, pulmonary abscess

TABLE 2. (Continued)

Patient	Age (Yr.)	Sex	Primary Indication for Transplant	Coexisted Liver Disease	Timing and Location of First Recurrence or (Location of Residual Tumor)	Treatment for Recurrence	Organs Ultimately Involved by Tumor	Survival	Main Cause of Death
OT 176	33	F	Bile duct cancer	Sclerosing cholangitis	10 mos.; bile duct	Radiation	Bile duct, liver, jejunum	Died/12 mos.	Tumor recurrence
OT 185	56	M	Bile duct cancer (Klatskin tumor)	—	(No residual tumor)	—	—	Died/1 mo.	Sepsis, graft failure
OT 194	26	M	Hepatocellular carcinoma-FL*	—	None	—	—	Alive/3½ yrs.	—
OT 200	27	M	Bile duct cancer (Klatskin tumor)	—	6 mos.; skin	Radiation	Skin, bile duct, liver, peritoneum	Died/8 mos.	Tumor recurrence
OT 227	53	M	Hepatocellular carcinoma	Post-necrosis cirrhosis	12 mos.; bone	None	Bone, no autopsy	Died/14 mos.	Myocardial infarction
OT 231	23	F	Hepatocellular carcinoma-FL*	—	13 mos.; lungs	Chemotherapy	Lungs	Alive/3 yrs.	—
OT 234	24	F	Hepatocellular carcinoma	—	(No residual tumor)	—	—	Died/2 mos.	Ischemic colon necrosis, sepsis, graft failure
OT 251	52	F	Hepatocellular carcinoma	Thorotrast liver	(No residual tumor)	—	—	Died/2 mos.	Candida sepsis, graft failure
OT 260	36	F	Cholangiocarcinoma	—	15 mos.; liver	Radiation	Liver, lungs, bile duct, peritoneum	Died/20 mos.	Carcinomatosis
OT 300	25	M	Hepatocellular carcinoma-FL*	—	None	—	—	Alive/22 mos.	—
OT 305	35	F	Hemangiosarcoma	—	(Residual: lungs, peritoneum)	—	Lungs, peritoneum bone marrow	Died/3 mos.	Pneumonia, graft failure
OT 316	33	F	Epitheloid hemangioendothelial sarcoma	—	None	—	—	Alive/20½ mos.	—
OT 322	26	F	Epitheloid hemangioendothelial sarcoma	—	12 mos.; liver	Chemotherapy, radiation	Liver, lungs	Died/16 mos.	Tumor recurrence
OT 324	29	F	Hepatocellular carcinoma	—	5 mos.; bone	Chemotherapy	Bone, liver, lungs, lymph nodes	Died/17 mos.	Carcinomatosis
OT 338	24	M	Hepatocellular carcinoma-FL*	—	16 mos.; liver, lung	—	—	Alive/17 mos.	—
OT 351	32	F	Hepatocellular carcinoma	—	None	—	—	Alive/15 mos.	—
OT 454	5	M	Hepatocellular carcinoma	Tyrosinemia	4 mos.; liver	Chemotherapy†	—	Alive/6 mos.	—
OT 462	51	M	Hepatocellular carcinoma	Post-necrotic cirrhosis, HBsAg+	4 mos.; liver, lung	Chemotherapy†	—	Alive/5 mos.	—
OT 466	47	F	Hepatocellular carcinoma-FL*	—	None	Chemotherapy†	—	Alive/5 mos.	—
OT 473	54	F	Adenocarcinoma of undetermined primary site	—	(Residual: abdominal lymph nodes)	—	—	Alive/4 mos.	—

* Fibrolamellar hepatocellular carcinoma.

† Chemotherapy started before clinical evidence of recurrent tumor.

liver was ultimately involved by recurrent tumor in 12 cases. Other locations within the abdomen such as abdominal lymph nodes and the peritoneum were affected in 13 cases. The lung became involved in 11 cases, and the brain and the bones in three cases each.

The first locations of tumor recurrence and the organs ultimately involved by tumors were examined in the 20 patients of Group II (Table 2) who were rendered potentially tumor free at the time of transplantation but who

later developed metastases. The liver was the first site of recurrence in eight cases, the lung in six cases, both the liver and the lung simultaneously in two cases, the bone in two cases, and the skin and the pelvic peritoneum in one case each.

Discussion

The most encouraging aspect of this experience was the almost uniform survival of patients of Group I whose

TABLE 3. *Histological Diagnosis of 54 Primary Liver Malignancies*

	I-A	I-B	II-A	II-B	Total
Hepatocellular carcinoma (Nonfibrolamellar type)	2	10	12	13	37
(Fibrolamellar type)	(2)	(10)	(11)	(7)	(30)
Bile duct cancer	0	0	5	3	8
Epitheloid hemangio- endothelial sarcoma	0	0	1	2	3
Cholangiocarcinoma	0	0	1	1	2
Hepatoblastoma	1	0	0	0	1
Angiosarcoma	0	0	0	1	1
Sarcoma of undetermined cell type	0	0	1	0	1
Adenocarcinoma of unknown primary site	0	0	0	1	1
Total	3	10	21	20	54

otherwise diseased livers also contained incidental hepatomas or, in one instance, a hepatoblastoma. The fact that none of these patients developed a recurrence during the 4 months to 15½ years of follow-up proved that the mere presence of a hepatic malignancy is not an absolute contraindication to transplantation.

Nevertheless, there was a tumor recurrence rate of 74% in the patients of Group II who had neoplasms that were the fundamental reason for the total hepatectomy and transplantation and who survived for at least 2 months. It is possible that the high recurrence rate in Group II recipients merely reflected the advanced development of the neoplasms by the time a decision was made to attempt therapy with transplantation. An alternative and not necessarily mutually exclusive explanation is that the immunosuppression necessary to prevent graft rejection may actually have expedited the growth of residual nests of cells left after the total hepatectomy, as was suggested a number of years ago¹ and supported by many recent investigations host factors promoting metastases.⁶⁻⁸ The tendency of the metastases from hepatic malignancies to come back to the liver grafts has been noted before.^{1,2}

Of all the tumor types for which experience has been accumulated so far, the fibrolamellar hepatocellular carcinoma has emerged as the best for treatment with trans-

TABLE 4. *Tumor Recurrence in 27 Patients of Group II*

	No. Cases	No. Recurred	No. Recurred Less Than 1 Yr.
Hepatocellular carcinoma (Nonfibrolamellar type)	18	13 (72%)	9
(Fibrolamellar type)	11	9 (82%)	9
Bile duct cancer	7	4 (54%)	0
Epitheloid hemangio- endothelial sarcoma	5	4 (80%)	2
Cholangiocarcinoma	3	2 (67%)	2
	1	1 (100%)	0
Total	27	20 (74%)	13

PERCENT SURVIVAL

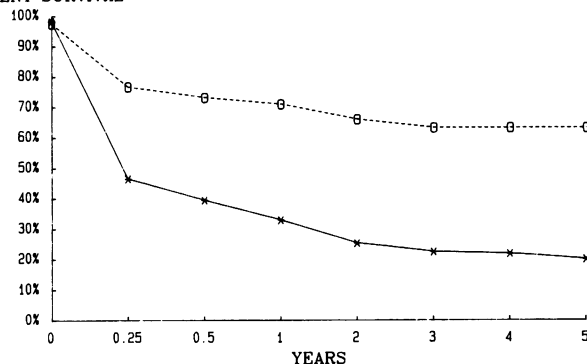


FIG. 1. Survival (actuarial) of all cyclosporine-treated, compared to survival (actuarial) of all azathioprine-treated, liver transplant recipients. O Cyclosporine group, 1980-1985 (n = 330); X Azathioprine group, 1963-1980 (n = 170).

plantation. This hepatoma variant, which was originally recognized by Edmondson⁹ and Peters,¹⁰ is known to behave less aggressively than most other malignant hepatic neoplasms, including the more common kind of hepatocellular carcinoma.¹¹⁻¹³ Although four of our seven patients with fibrolamellar hepatomas developed metastases, these tended to appear late and to grow relatively slowly. One of our patients with recurrence is in very good health 2 years after multiple pulmonary metastases were first proved.

With all other kinds of tumors, including the rest of the hepatocellular carcinomas, metastases have tended to appear early and to lead to death promptly. The prognosis with conventional hepatocellular carcinomas has been grim. Similarly, none of our patients with proximal duct cell carcinomas (Klatskin tumors) has been "cured," and, to our knowledge, this has not been accomplished in any other center.

It has been tempting during the acquisition of this experience to conclude that liver replacement for malignant hepatic neoplasms is conceptually unsound, except for fibrolamellar hepatomas, and to abandon such efforts.

PERCENT SURVIVAL

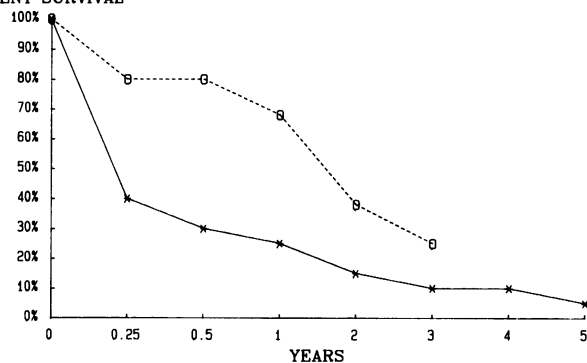


FIG. 2. Survival rates for Group II-B patients (cyclosporine-treated) compared to Group II-A (azathioprine-treated) patients. X Group II-A (n = 20); O Group II-B (n = 21).

However, arrest and control of the malignant process have been accomplished under some of the least likely circumstances, as with the woman who had pulmonary and peritoneal seeding from a sarcoma at the time of transplantation, the recipient with epithelioid hemangioendothelial sarcoma, and the patient with a conventional hepatoma. There has been no identifiable reason why the patients were spared recurrence and why the others were not.

Liver transplantation will have to be tied to some other kind of therapeutic effort in future trials. The usual approach of giving adjuvant chemotherapy will not be good enough, as was shown in two of our recent patients with nonfibrolamellar hepatocellular carcinomas who developed metastases within a few months in spite of very aggressive prophylactic treatment with adriamycin and other chemotherapeutic agents. Huber et al.¹⁴ have described a novel approach in which two patients with metastatic liver disease had liver replacement as well as total body irradiation, chemotherapy, and bone marrow transplantation. One of their recipients whose original disease was a carcinoma of the breast was alive 3 years later after liver replacement and was free of tumor.¹⁵

References

1. Starzl TE (with the assistance of Putnam CW). Experience in Hepatic Transplantation. Philadelphia: WB Saunders, 1969; 350-373.
2. Iwatsuki S, Klintmalm GBG, Starzl TE. Total hepatectomy and liver replacement (orthotopic liver transplantation) for primary hepatic malignancy. *World J Surg* 1982; 6:81-85.
3. Calne RY. Liver Transplantation: The Cambridge and King's College Hospital Experience. London: Grune and Stratton, 1983; 306-311.
4. Pichlmayr R, Brolsch CH, Wonigiet K, et al. Experiences with liver transplantation in Hannover. *Hepatology* 1984; 4:56S-60S.
5. Starzl TE, Iwatsuki S, Shaw BW Jr, Gordon RD. Orthotopic liver transplantation in 1984. *Transplant Proc* 1985; 17:250-258.
6. Alexander P, Eccles SA. Host mediated mechanisms in the elimination of circulating cancer cells. *Symp Fundam Cancer Res* 1983; 36:293-308.
7. Hanna N. Role of natural killer cells in host defense against cancer metastasis. *Symp Fundam Cancer Res* 1983; 36:309-320.
8. Milas L, Peters TJ. Conditioning of tissues for metastasis formation by radiation and cytotoxic drugs. *Symp Fundam Cancer Res* 1983; 36:321-336.
9. Edmondson HA. Differential diagnosis of tumors and tumor-like lesions of the liver in infancy and childhood. *Am J Dis Child* 1956; 91:168-186.
10. Peters RL. Pathology of Hepatocellular Carcinoma. In Okuda K, Peters R, eds. *Hepatocellular Carcinoma*. New York: Wiley, 1975; 107-168.
11. Craig JR, Peters RL, Edmondson HA, Omata M. Fibrolamellar carcinoma of the liver: a tumor of adolescents and young adults with distinctive clinicopathologic features. *Cancer* 1980; 46:372-379.
12. Berman MM, Libbey NP, Foster JH. Hepatocellular carcinoma: Polygonal cell type with fibrous stroma—an atypical variant with a favorable prognosis. *Cancer* 1980; 46:1448-1455.
13. Starzl TE, Iwatsuki S, Shaw BW Jr, et al. Treatment of fibrolamellar hepatoma with partial hepatectomy or with total hepatectomy and liver transplantation. *Surg Gynecol Obstet*, in press.
14. Huber C, Niederwieser D, Schonitzer D, et al. Liver transplantation followed by high-dose cyclophosphamide, total-body irradiation, and autologous bone marrow transplantation for treatment of metastatic breast cancer. *Transplantation* 1984; 37:311-312.
15. Huber C. Personal communications.

DISCUSSION

DR. PAUL RUSSELL (Boston, Massachusetts): All of us know that the Pittsburgh experience is unique, impressive, and, from what we have heard today, quite helpful.

In Boston we are just beginning our efforts in liver transplantation. We have a combine of four hospitals (the New England Deaconess, Tufts-New England Medical Center, Children's, and Massachusetts General Hospital), which has now achieved something over 50 transplants.

At the Massachusetts General Hospital, we have four patients who received liver transplants for malignant disease. One patient with a primary cholangiocarcinoma succumbed to rapidly progressive metastatic disease less than a year after transplantation. The three others are alive within a year. It seems from the experience of Starzl and his colleagues that many of these patients, even with primary liver tumors, already have tumor outside the liver when they come for treatment.

The question is clearly whether we can better identify patients whose tumors are still confined to the liver. My questions to Dr. Iwatsuki are: What place, if any, does he think that preliminary exploration of the abdomen has? That is, should a "first look" with careful evaluation of lymph-node spread always be done? Also, are there any other diagnostic measures we might use in selecting patients with liver tumors who will most benefit from transplantation?

DR. J. P. O'LEARY (Dallas, Texas): Dr. Iwatsuki, this paper causes me to think of two things.

Number one, you suggest that further chemotherapy will be necessary. Have you had any experience with such treatment?

Number two, the new liver seems to harbor the major area for the recurrence. Is this actually recurrence from another deposit of tumor in the abdomen, or is this a new primary tumor?

DR. JAMES H. FOSTER (Farmington, Connecticut): Dr. Iwatsuki, can you tell us anything about liver transplantation for secondary or metastatic cancer?

DR. SHUNZABURO IWATSUKI (Closing discussion): Thank you very much, Dr. Russell. To answer your question as to how to select the patients, the way we usually handle the cancer patient for transplant is that we set up liver transplantation for two patients; the first patient, who is known to have a malignancy, and the second patient, who is known to have a benign disease. We start the operation earlier than the usual time and explore the cancer patient first. If the patient has extrahepatic involvement of the tumor, we stop the procedure there and call for the second patient.

Answering the question of Dr. O'Leary, as I mentioned briefly during the presentation, we have tried chemotherapy after transplant before the recurrence. Adriamycin® was used in a pretty heavy dose in a short period of time for a few patients with hepatomas. Two patients who had hepatoma suffered a recurrence within 3 months in spite of the chemotherapy. Therefore, we need more effective chemotherapeutic agents, or something else has to be added to liver replacement.

Answering the question of Dr. Foster, we have not done any transplantation for the patient with secondary metastasis. The Cambridge group and the Hanover group tried in several patients with metastatic liver malignancy, and they all died in 1 year with aggressive metastasis.

Answering the question of whether the liver tumor after transplant is actually a recurrence or a *de novo* tumor, we do not know it for sure, but histologic characteristics of the recurrent tumor were quite similar to the original tumor that the recipient had before transplant, and there was almost always extrahepatic involvement by the time liver tumor was clinically detected.