

Endoscopic Decompression of Acute Colonic Obstruction

Avoiding Staged Surgery

SHLOMO LELCUK, M.D.
JACOB RATAN, M.D.*

JOSEPH M. KLAUSNER, M.D.
YEHUDA SKORNICK, M.D.

ARIE MERHAV, M.D.
ROLAND R. ROZIN, M.D., F.A.C.S.

Colostomy is the traditional treatment for acute obstruction of the sigmoid colon. This entails two or three surgical procedures in a high-risk group of patients. Presented is a nonsurgical approach used in three patients with acute colonic obstruction. Decompression of the bowel was achieved with a tube introduced proximal to the obstruction with the aid of a flexible sigmoidoscope. In a fourth patient, in whom the obstruction was next to the splenic flecture, the procedure failed. In all instances where decompression was successful, a one-stage procedure—primary resection and anastomosis—was performed.

THE TRADITIONAL TREATMENT for obstructive carcinoma of the left colon is by a staged procedure, namely, proximal colostomy or resection of the tumor with a colostomy. Definitive treatment is reserved as a later procedure. This usually entails two or three laparotomies. To avoid multiple operations for acute left colonic obstructions, we decompress the obstructed colon by inserting a tube proximal to the obstruction with the aid of a flexible sigmoidoscope. This allows immediate decompression and further mechanical preparation of the colon for a one-stage procedure.

Technique

For the performance of sigmoidoscopic decompression, the patient is placed on his left side. Following insertion, the sigmoidoscope (short colonoscope, Olympus CF-MB3W, Olympus Optical, Tokyo, Japan) is advanced to the site of the tumor. The obstructed lumen is identified by a black hole or by small gas bubbles escaping from the obstructed segment. A well-lubricated flexible guide wire, identical to that used for esophageal dilation, is then introduced through the tumor beyond the point of obstruction. The sigmoidoscope is withdrawn and a lubricated tube is advanced over the protruding guide wire. The wire is then withdrawn. The immediate escape of air and liquid feces through the catheter indicates successful de-

From the Surgical and Gastro-Enterology Departments, Hadassah (Rokach) Hospital, Tel Aviv Medical Center and Sackler School of Medicine, Tel Aviv University, Tel Aviv, Israel*

compression. The correct position of the tube is identified by plain abdominal roentgenogram, indicating the adequacy of the procedure. The tube is secured to the perianal skin with sutures.

Further preparation of the colon for surgery is achieved using the rectal tube for daily irrigation with saline and paraffin oil. Antibiotics, as well as paraffin oil and MgSO₄, are administered orally as the regular preparation of the colon for surgery. After several days of decompression and cleansing of the colon, the patient is ready for definitive surgery.

Case 1

A 73-year-old man was admitted for colicky abdominal pain and obstipation of 3 days duration. Physical examination showed a distended and tympanic abdomen. Plain abdominal roentgenogram revealed a distended large bowel. Barium enema demonstrated an obstruction of the sigmoid colon (Fig. 1). Colonoscopy was then performed and a nasogastric tube was introduced proximally to the obstruction as described previously (Fig. 2). A large amount of air and fluid escaped. The patient was prepared for surgery for 5 days by paraffin enemas through the rectal tube and parenteral feeding. Repetitive abdominal roentgenograms showed a reduction of the colonic distension (Fig. 3). At operation, an obstructive carcinoma of the sigmoid colon (Dukes B2) was found. The colon proximal to the tumor was not distended and was found to be sufficiently clean for a primary resection and anastomosis. The postoperative course was uneventful.

Case 2

A 68-year-old man was admitted suffering from obstipation, abdominal pain, and vomiting of several days duration. Physical examination revealed a malnourished patient, dehydrated with marked abdominal distension. Plain abdominal roentgenogram demonstrated a distended large bowel. Barium enemas disclosed a sigmoid obstruction. The patient was decompressed *via* a nasogastric tube (Fig. 4), using the same technique and prepared for surgery as previously described. At surgery the colon was found to be adequately decompressed. Wide intraperitoneal meta-

Reprint requests: S. Lelcuk, M.D., Department of Surgery, Hadassah (Rokach) Hospital, 8 Balfour Street, P.O. Box 51, Tel Aviv, Israel.

Submitted for publication: September 27, 1985.

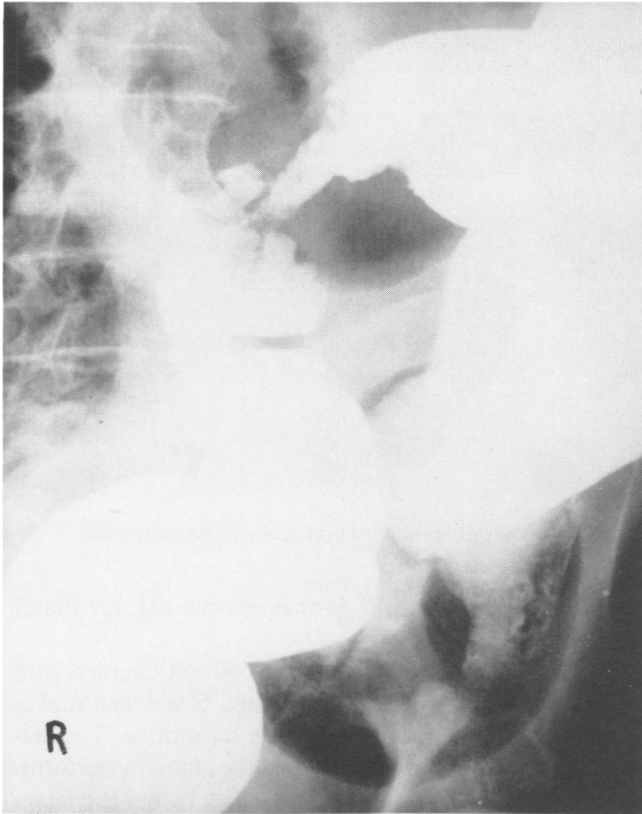

FIG. 1. Obstructing tumor of the sigmoid colon.

static spread prevented resection and a diverting colostomy was performed.

Case 3

A 49-year-old man was admitted for large bowel obstruction and 15 kg of weight loss. Two years previously he had undergone a left transverse colostomy for a sigmoid diverticular abscess, followed by an extended left colectomy. One year prior to this admission repeated episodes of constipation and diarrhea developed. Sigmoidoscopy revealed a severe stricture 25 cm above the anus, through which a pediatric scope could hardly be passed. On admission, examination revealed a distended abdomen. Barium enema showed an obstructed large bowel and plant seeds in the area of the obstruction (Fig. 5). Sigmoidoscopy revealed an obstruction 25 cm proximal to the anus. The rectal tube was passed proximally to the stricture and decompression achieved as previously described (Fig. 6). The patient was prepared for surgery for 5 days. Laparotomy revealed a severe stricture at the site of the anastomosis with water melon seeds above it. The stricture was resected and primary anastomosis performed.

Case 4

A 68-year-old man was admitted for symptoms of colonic obstruction. Barium enema showed an obstruction distally to the splenic flexure. Colonoscopic examination revealed an obstructive tumor 70 cm from the anus. The flexible wire was introduced easily proximally to the obstruction but the rectal tube could not be advanced because of the distance involved and the coiling nature of the colon. The patient underwent a left transverse loop colostomy.

In all patients, there were no signs of peritonitis either prior to the surgical procedure nor in the explorative laparotomy.

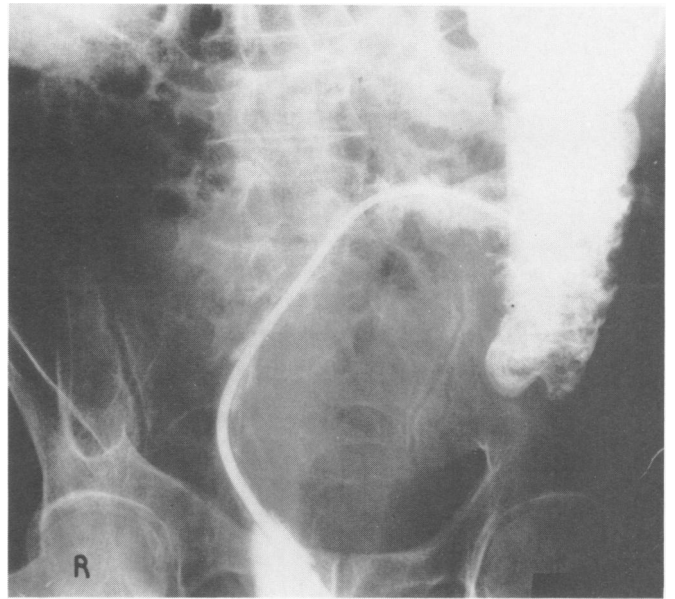


FIG. 2. Nasogastric tube introduced proximally to the obstruction.

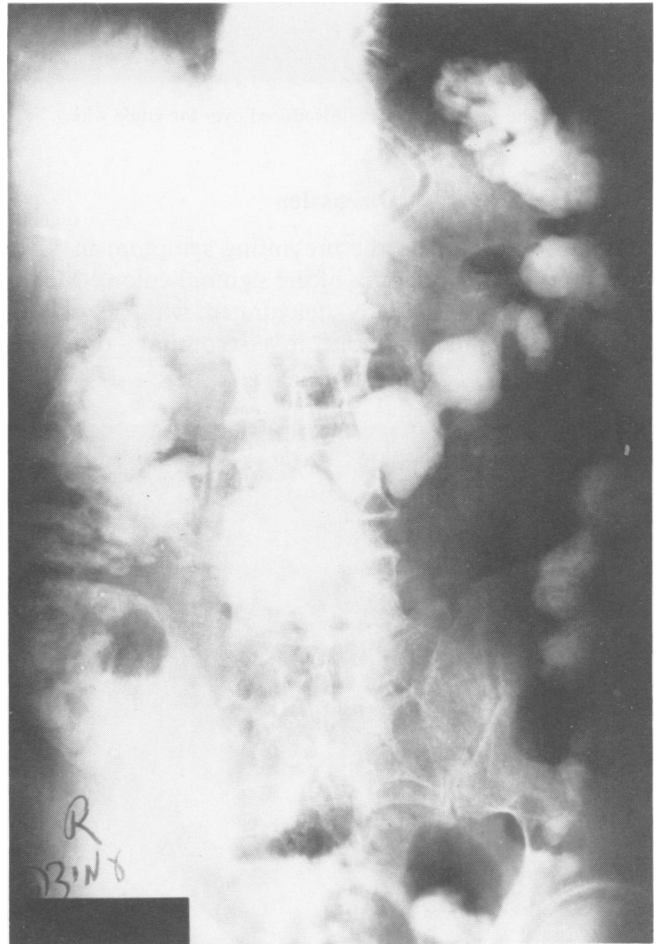


FIG. 3. A day later, the bowel is decompressed.

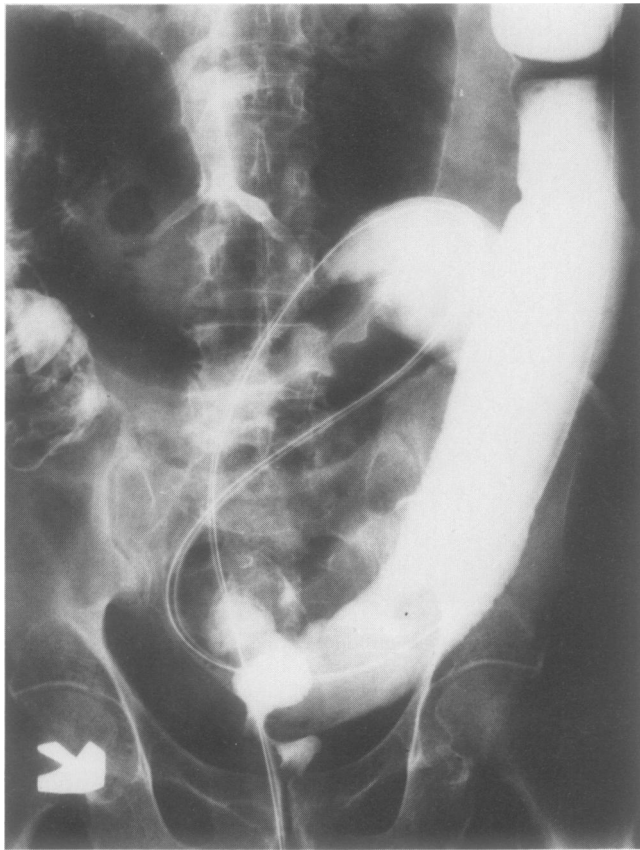

FIG. 4. The nasogastric tube introduced over the guide wire.

Discussion

Acute obstruction is the presenting symptom in 15% of patients with carcinoma of the sigmoid colon.¹ Many of these patients are elderly, dehydrated, with electrolyte imbalance, and unstable due to concomitant diseases,

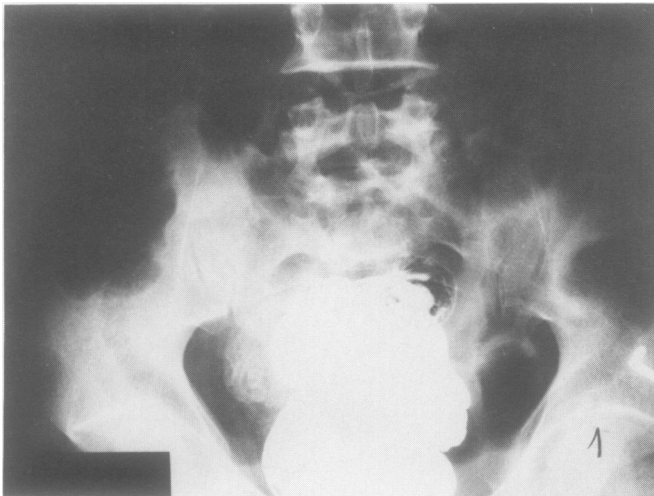


FIG. 5. Barium enema showing complete obstruction with plant seeds proximal to it.

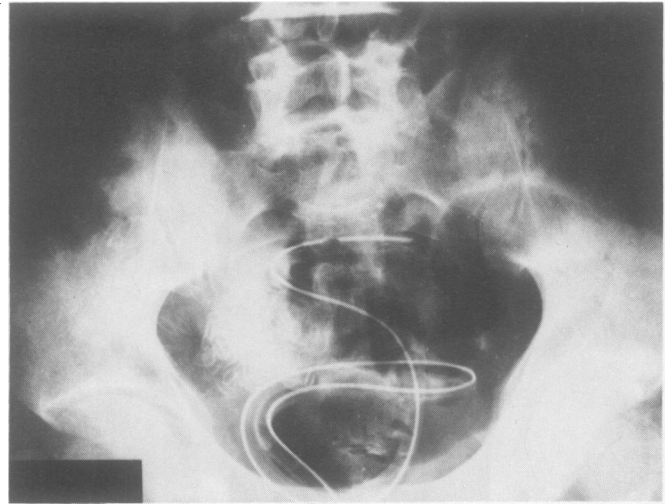


FIG. 6. The tube positioned proximally to the obstruction.

which make this group a poor operative risk for major surgery.

The septic nature of the colonic content coupled with the friable condition of the obstructed bowel wall makes primary resection and anastomosis hazardous. The traditional treatment is to decompress the colon by performing different kinds of colostomies. Thus, two or three laparotomies are required in this group of high-risk patients. Definitive treatment is reserved for a later operation. Only in those cases where the patients are in good condition can primary resection and anastomosis be performed.

In other diseases of acute colonic obstruction such as volvulus of the sigmoid colon² and colonic pseudo-obstruction,^{3,4} an attempt at nonsurgical decompression is always preferable. It might be feared that the procedure would leave the patient exposed to the risk of perforation of the bowel, but this complication is rare.⁵

Our experience, although still limited, shows that colonic decompression *via* a colonoscope is a short procedure, simple to perform and safe when it is applied for obstructive carcinoma of the sigmoid colon. This alternative kind of treatment should be considered as a first line nonsurgical treatment for decompression of the large bowel before contemplating any kind of surgical intervention.

References

1. Ohman U. Prognosis in patients with obstructing colorectal carcinoma. *Am J Surg* 1982; 143:742-747.
2. Starling JR. Initial treatment of sigmoid volvulus by colonoscopy. *Ann Surg* 1979; 190(1):36-39.
3. Nivatvongs S, Wermeullen FD, Fang DT. Colonoscopic decompression of acute pseudo-obstruction of the colon. *Ann Surg* 1982; 196(5):598-600.
4. Bode WE, Beart RW, Spencer RJ, et al. Colonoscopic decompression for acute pseudo-obstruction of the colon. *Am J Surg* 1984; 147: 243-245.
5. Goligher JC. *Volvulus: Surgery of the Anus and Rectum*. London: Baillier Tinoal, 1977; 1133-1135.