

STRUCTURAL CHANGES IN THE ISOLATED VISUAL CORTEX

BY W. E. LE GROS CLARK AND S. SUNDERLAND

Department of Human Anatomy, Oxford

THESE is still lack of agreement on the question of the functional significance of the laminar differentiation of the cerebral cortex. If functional localization referable to the cortical cell laminae does occur, it must presumably be reflected in a difference in their fibre connexions. This, again, should be demonstrable by a study of the changes in the cell and fibre architecture of the cortex which may occur after interruption of its connexions with other parts of the cortex and with subcortical centres. In this paper is recorded an experimental study of the visual cortex in the monkey (*Macaca*) to ascertain whether this is the case. The visual cortex is particularly suitable for such an investigation, partly because the lamination here is very well differentiated, and partly because recent work has established in considerable detail the organization of the striate area in relation to subcortical centres.

In these experiments small areas of the visual cortex have been completely isolated without interference of their vascular supply in order to determine, primarily, the laminar distribution of cells concerned with efferent functions (whether related to neighbouring or distant areas of the cerebral cortex, or to subcortical centres), and also the alteration in fibre architecture consequent on the interruption of afferent connexions.

LITERATURE

Current ideas regarding the allocation of specific functions to particular cell laminae generally reflect the conclusions drawn by Kappers (1909) from morphological studies of the neocortex. Kappers supposed that the cortex can be divided into three functionally different laminated zones: a supragranular (superficial to Brodmann's lamina IV) which is essentially receptor-correlative in function, an infragranular which gives origin to corticofugal and commissural fibres, and between the two a granular zone (Brodmann's lamina IV) which is predominantly receptive. A good deal of evidence has been adduced in support of this conception. For example, it has been noted that the granular layer is best developed in cortical areas which are known to be sensory in function, and is absent or poorly developed in motor areas. The allocation of receptive functions to this layer is also substantiated by the evidence of Marchi preparations. After section of afferent connexions, the degenerating fibres can be seen to run up into the granular layer and there break up into a fine

deposit of Marchi granules (see, for example, Poliak, 1927, 1932). This appearance, however, does not preclude the possibility that many of the fibres may terminate (either directly or by collaterals) in the infragranular zone, or that others, after losing their myelin sheaths, may extend into the more superficial layers of the cortex. Lorente de Nó (1923), in his study of Golgi preparations of the cortex in the mouse, found relatively coarse fibres (which emerged from the corona radiata) entering lamina IV without giving off any significant numbers of collaterals to deeper layers. On the other hand, however, he also traced finer fibres to the pyramidal layer and even to the superficial lamina zonalis, some of which do give off numerous collaterals to laminae V and VI. According to a more recent statement by Lorente de Nó (1938), the cells of lamina IV certainly have the greatest number of synapses with specific afferent fibres, while other fibres (believed to have their origin in the thalamus) ascend as far as the lamina zonalis, giving off collaterals to other laminae in their course through the thickness of the cortex. A third type of afferent path is represented by association fibres which give off collaterals in the deep layers, but whose main territory of distribution is laminae I to IV, and especially II and III. O'Leary & Bishop (1938) arrived at somewhat similar conclusions from a study of the visual cortex of the rabbit; they found that the afferent fibres end predominantly in lamina IV and the lower two-thirds of lamina III.

As regards the associative functions of the supragranular layers, it has been pointed out that these are exceptionally well developed in certain of the so-called "association" areas, they are on the whole relatively better developed in more highly organized brains, while, according to Bolton (1900), they are the main site of pathological cell involvement in the cortex in conditions of amentia and dementia. It has been mentioned above, also, that Lorente de Nó's observations led him to infer that association fibres reaching an area of the cortex are distributed mainly to the lamina pyramidalis.

Nissl (1911) found that cell atrophy in the cortex following separation of the hemispheres from subcortical centres in young rabbits is most marked in the infragranular layers, while the superficial layers show little change, or even retain the capacity for further development. This observation is in accord with the generally accepted opinion that the infragranular zone gives rise to corticofugal pathways of all types. It is, of course, well established that in the motor cortex the cells of origin of the pyramidal tracts are situated in the infragranular layers. As far back as 1909 this was determined experimentally by Holmes & May. These authors divided the pyramidal tract in the upper cervical region of the spinal cord in the cat, dog, lemur, monkey and chimpanzee, and found the resulting cell atrophy in the motor cortex to be localized to the giant cells of Betz. So far as the other cells are concerned, they write, "we never succeeded in detecting chromatolytic changes in the superficial pyramids, in the polymorphous layer, or in any of the smaller pyramids or granule cells". On the other hand, following a capsular lesion (in man) and a

lesion in the crus cerebri (in the lemur), additional changes were observed in the pyramidal cells of the supragranular and infragranular layers, but especially the latter. In a recent paper, Levin & Bradford (1938) have reported similar findings after experimental section of the pyramidal tract in monkeys. Seventeen days after operation, they found that chromatolysis of the Betz cells had for the most part become fully developed, and after 28 days most of the degenerating cells had already disappeared. These authors also found no evidence of cell change in the supragranular layers. The relation of the infragranular layer of the motor cortex to the pyramidal tract has been further substantiated by the thermo-coagulation experiments of Dusser de Barenne (1934). Lastly, there is some evidence (van Valkenburg, 1913; de Vries, 1912), based on retrograde cell degeneration, that callosal fibres take their origin chiefly from pyramidal cells of the infragranular layers of the cortex, and terminate in the cortex of the opposite hemisphere mainly in relation to the granular layer.

In general, it may be said that the recent work of Lorente de Nó on cortical organization has thrown considerable doubt on any rigid conception of a laminar type of functional localization in the cortex, for his observations have shown that it is possible for cells in any layer to have synaptic connexions with afferent fibres. In every layer, also, there are cells giving origin to descending axones which reach the white matter. These conclusions, however, do not eliminate the possibility that the different cell laminae may each be predominantly concerned with different functions.

METHODS

In the experiments recorded in this paper, the choice of the operative technique employed to isolate cortical areas has taken account of the fact (Sunderland, 1938) that the cortex and the immediately subjacent white matter receive their entire effective blood-supply from the superficial pial vessels. In three monkeys, a strip of cortex along the margin of the occipital operculum (containing portions of area 17 and area 18) was isolated by means of a curved sub-pial incision with a Graefe knife, care being taken to avoid injury to the superficial vessels passing to the isolated area (Text-fig. 1). In one animal (O.M. 164), a small rectangular area of cortex in the central part of the occipital lobe was also isolated by incisions the position of which is indicated diagrammatically in Text-fig. 1. Of the three animals, one (O.M. 149) was allowed to survive for only 14 days after the operation, to allow of the study of chromatolytic changes in affected cells before total atrophy had occurred. Of the others, one (O.M. 164) survived for 46 days, and a third (O.M. 226) for 118 days. After such lengths of time, atrophy of cells giving rise to efferent fibres should be complete.

After the brains had been removed at death, suitable blocks containing the isolated areas of cortex were prepared, while corresponding areas from the

normal hemisphere were also removed for purposes of comparison. The blocks were fixed in 90% alcohol containing 2% acetic acid, and embedded in paraffin. Sections were cut at 15μ ; some of these were stained with Borrel's methylene blue, and others by Bodian's silver technique.

In order to give some indication of the extent of the isolated cortex, it may be noted that the maximal width of the isolated opercular lip was 7 mm. in O.M. 149, 4 mm. in O.M. 164, and 6 mm. in O.M. 226. The maximal diameter of the isolated area in the central part of the occipital lobe in O.M. 164 was 8 mm.

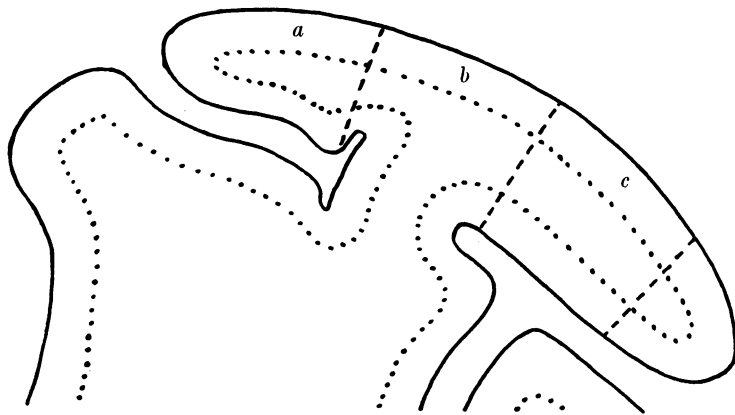


Fig. 1. Diagram of a horizontal section through the occipital lobe of the brain of a monkey to show the position of the sections made in the cortex. *a*, the opercular lip, which was separated from the rest of the cortex in three experiments. In one experiment (O.M. 164), an area situated more posteriorly was also isolated, *c*. Between *a* and *c* an area of cortex *b* was left which still retained its connexion with the medullary white matter of the occipital lobe while separated in front and behind from the neighbouring visual cortex.

OBSERVATIONS

Before discussing the structural changes which ensue in an isolated area of visual cortex, certain features of its normal histological structure require a brief mention. The general structure of the visual cortex of Primates has been described in detail by Brodmann (1903), Beck (1930), Ngowyang (1935, 1937) and others. Beck and Ngowyang, in particular, have shown that the area striata of the cortex may be subdivided into a number of subsidiary cytoarchitectural fields; this fact is of considerable importance in the present study, since it makes it necessary that, for comparative study, the isolated sections of the cortex and the normal control should be taken from identically equivalent areas in order to avoid errors related to regional variations.

In the lamina pyramidalis of area 17, well-formed pyramidal elements are relatively inconspicuous in methylene blue and silver preparations; they show considerable variation in size, and they are not disposed in layers as they are in adjacent cortical areas. In area 18, on the other hand, one of the most

characteristic features is the conspicuous number of pyramidal cells which occupy mainly the deeper levels of the lamina pyramidalis.

In the visual cortex of the monkey's brain, the large cells of Meynert in lamina VI present a very striking appearance (Pl. II, fig. 7). In size, their cell body may reach a diameter of $45\ \mu$. Some are pyramidal in shape, but many are irregularly angular, with numerous stout dendrites extending for considerable distances in a horizontal direction. In some cases an apical dendrite can be traced up as far as the pyramidal layer, and an axonal process descending into the white matter. These cells tend to be arranged in a single linear series, and they vary considerably in number in different sections. They are often quite widely spaced, so that in a single section adjacent cells may be separated by an interval of several millimetres.

In lamina IV *b* (the stria of Gennari), large stellate or pyramidal cells are present in large numbers, and in some regions of the visual cortex (particularly the central and posterior parts) they are arranged in a fairly well-defined band (Pl. II, fig. 5). These large cells were also originally described by Meynert (1872) as characteristic of the visual area of the cortex. In the monkey they are much more conspicuous than in Man, but, though large, they do not reach the size of the solitary cells of Meynert in lamina VI. In silver preparations they can be observed to give off apical and horizontal dendrites.

Changes in the isolated cortex. It may be stated at the outset that perhaps the most striking feature of the isolated visual cortex is the extent to which its cytoarchitecture persists unchanged. This can be seen by reference to Pl. I, figs. 3, 4, which show a microphotograph of the opercular lip from the normal hemisphere of O.M. 226, compared with the operated side in which the opercular lip had been isolated from the rest of the occipital cortex for 118 days. At first sight, indeed, the cytoarchitecture appears hardly to be affected, the only noteworthy feature being the gliosis in the medullary white matter of the isolated area.

Attempts were made at a numerical computation of cells in normal and isolated areas of O.M. 164 and O.M. 226 in order to determine the extent of total cell atrophy. This was done by taking microphotographs of sections (stained with methylene blue) and counting directly the cells in random areas of different laminae. Such estimates presented considerable difficulty, partly because of the absence of a clear line of demarcation between the various layers, and partly because it was not possible to take into account any slight local shrinkage which may have affected the cortex as a whole. Furthermore, there remains the possibility that the initial vascular disturbance following immediately on the operative interference may have led to degenerative changes in some of the cortical cells, even though their direct blood supply was not interrupted. In O.M. 164 (killed 46 days after operation) a definite reduction of cells was demonstrated by this method and is, indeed, directly evident by a comparison of Pl. II, figs. 5, 6. It is interesting to note, however, that the reduction has involved all the cell laminae to some degree, amounting

to 15–20 % in the supragranular and granular layers, and not more than 6 % in the infragranular layers. Such a result is hardly in accordance with the general assumption that the infragranular layers consist predominantly of efferent neurones. It should be pointed out, however, that, in so far as callosal fibres may take their origin from the infragranular layers, some of the reduction of cells in the latter may be masked by the fact that a similar reduction would also have occurred in the visual cortex of the normal (contralateral) hemisphere. In O.M. 226 (which survived 118 days after operation) the reduction of cells as estimated by the methods employed appeared to be very much less, amounting to 7 % in the supragranular layers, 9 % in the infragranular layers, while there was no apparent reduction in the granular layer. In this case, however, there seems to be some reduction in the thickness of the cortex as a whole, consequent on atrophic shrinkage, but unfortunately the degree of shrinkage cannot be estimated with any degree of accuracy because of the possibility that the sections may not have been cut in a plane precisely vertical to the surface. Our conclusions from these observations are that, in the isolated visual cortex, there is certainly some reduction of cells, but that this affects no particular lamina to the exclusion of others. We may now refer to the cell changes which occur in individual laminae of the isolated cortex.

Lamina pyramidalis. After 14 days, no changes in the pyramidal cells were observed; medium-sized pyramids of quite normal appearance are present in their usual numbers. After 46 days there is a reduction in number, but no abnormal appearance is presented by the remaining cells, except that many of them stain less deeply and less sharply. After 118 days little further change has occurred; the larger cell elements of the pyramidal layer appear less conspicuous in number, and some of them have taken on a vesicular appearance.

Lamina granularis. Brodmann's lamina IV is divided into three layers in the visual cortex. Of these, the outermost (IVa) is so difficult to separate topographically from the pyramidal layer that we found it impracticable to consider it separately. Lamina IVb contains the large stellate cells to which reference has already been made, and these elements show very definite changes following isolation of the cortex. After 14 days they are still easily recognizable, but, while the majority of them appear quite normal cytologically, some give the appearance of undergoing chromatolytic changes, with eccentric nuclei, vacuolation of the cytoplasm, and less clearly defined cell processes. After 46 and 118 days, most of the large stellate cells have disappeared (see Pl. II, figs. 5, 6). A few persist unchanged, but even these do not stain with their normal sharpness. Bodian sections give a rather better contrast in some respects, for they demonstrate more clearly the relatively complete absence in lamina IVb on the operated side of the characteristic large cells with branching processes.

It should be noted that, in O.M. 164, while the large stellate cells have mostly disappeared in the isolated areas marked *a* and *c* in Text-fig. 1, they

remain apparently unaffected in area *b*. It thus appears probable that their disappearance is consequent on the interruption of fibres which run into the medullary white matter of the occipital lobe, and not on the interruption of association fibres passing to the immediately adjacent cortex.

Infragranular layers. Apart from a general small reduction of cells in these layers of the isolated cortex, the most striking change is that which affects the large solitary cells of Meynert. After 14 days these cells show significant changes. In Nissl sections some of them present a chromatolytic appearance; many of them, however, are still quite normal in their cytological characters though they are smaller. This shrinkage is more clearly demonstrated in Bodian sections (Pl. II, figs. 7, 8). Here the alteration in size is quite evident, the shrunken cells in the isolated cortex also staining more densely. After 46 and 118 days, many of the cells have undergone complete atrophy, leading to a reduction in number of approximately 50%. Those that remain are small; in no case has it been possible to find large branching Meynert cells of the type seen in normal visual cortex. It may be observed, again, that in O.M. 164, while typical Meynert cells have disappeared from the isolated areas *a* and *c*, some were still present in areas whose subcortical connexions had not been interrupted.

Discussion of cell changes in the isolated visual cortex. We have already emphasized the small extent of the change in the cytoarchitecture of a completely isolated area of the visual cortex. This may be taken to indicate how rich must be the intracortical connexions of any point on the cortex with the immediately adjacent region of the cortex, since it is reasonable to expect that neurones which are entirely concerned with efferent connexions to more distant parts of the visual cortex, to other cortical areas, or to subcortical centres, would undergo rapid degeneration after interruption of their axonal processes (as occurs, for example, with the Betz cells in the motor cortex). It seems evident from our experiments that there is a small reduction of cells affecting all the laminae of the isolated visual cortex, but we have found no certain evidence that any particular cell lamina is more concerned with efferent functions than others. Such a conclusion is in general accord with the observations of Lorente de Nó on the organization of the cerebral cortex. However, this statement may be qualified by reference to the large stellate cells in lamina IV *b*, and the large cells of Meynert in lamina VI. The experiments have shown that most of the former and many of the latter undergo complete atrophy in isolated areas. It may be inferred, therefore, that they are predominantly concerned with giving origin to efferent connexions. The question now arises whether these are relatively short connexions passing to the adjacent areas of the visual cortex, longer association fibres passing to the parietal cortex, or subcortical projection fibres. That they are not fibres of the first category is indicated by the observations already recorded in the experiment O.M. 164, for they persist in their normal numbers in a small area of cortex separated in front and behind from other parts of the visual cortex,

but still retaining its connexion with the medullary white matter of the occipital lobes. That they do not project on to the parietal cortex is shown by the results of an experiment reported elsewhere (Clark & Northfield, 1937) in which the whole of the parietal lobe of the brain was removed in a monkey 2 months before the animal was killed. In this case, a careful study of the cytoarchitecture of the visual cortex failed to show any recognizable change—large stellate cells and Meynert cells were still present, apparently in their normal numbers. It appears, therefore, that these cells are concerned with subcortical efferent projection, and it may be suggested that these include the corticotectal connexions of the visual cortex.

The absence of demonstrable changes in the cytoarchitecture of the visual cortex following ablation of the parietal cortex is somewhat remarkable in view of the general assumption that the two are closely linked by association fibres. However, Poliak's studies on the monkey's brain (1932), with the use of the Marchi technique, have indicated that association fibres arising in the visual area are mainly dispersed to the neighbouring portions of the visual cortex itself, some also reaching the immediately adjacent segments of areas 18 and 19, but not extending to other cortical areas in the parietal lobe.

Structural changes in area 18. It has been mentioned that a small portion of area 18 (area peristriata) was included in the isolated regions of the opercular lip of the occipital cortex. The cytoarchitectural changes here affect mainly the large pyramidal cells in the deeper levels of the lamina pyramidalis. Many of these undergo complete atrophy and disappear, especially those that lie close to the margin of the area striata. On the other hand, large numbers of conspicuous pyramidal cells remain in this small strip of cortex unchanged, even after it has been isolated for a period of 118 days (Pl. I, fig. 4).

Changes in the fibre architecture of the isolated visual cortex. The fibre architecture of the cortex was studied in the Bodian sections. As with the cytoarchitecture, a striking feature is the relatively small degree of change which follows isolation. For purposes of description, three categories of fibres may be recognized in the cortex, (1) radial fibres which run vertically through the lower levels of the cortex in discrete fasciculi; in sections cut at $15\ \mu$ there are between fifty and sixty of these fasciculi in each millimetre, (2) a diffuse network of obliquely disposed fibres of varying calibre, which are not collected in discrete bundles, and (3) the closely meshed felt-work of fibres which forms the basis of the stria of Gennari.

With regard to the radial fasciculi, comparative study of the isolated and normal visual cortex shows that, although the number of fasciculi remains unchanged, there is some thinning out of individual fibres (Text-fig. 2). With

LEGEND TO FIGURE 2

Fig. 2. Sections of the normal (A) and isolated (B) cortex of O.M. 226, stained by Bodian's silver technique. The sections include lamina IV c, with a portion of the stria of Gennari above, and lamina V below. Note that in the isolated cortex the background of interlacing, obliquely running fibres has largely disappeared, while there is also a reduction of fibres in the individual radial fasciculi. $\times 350$.

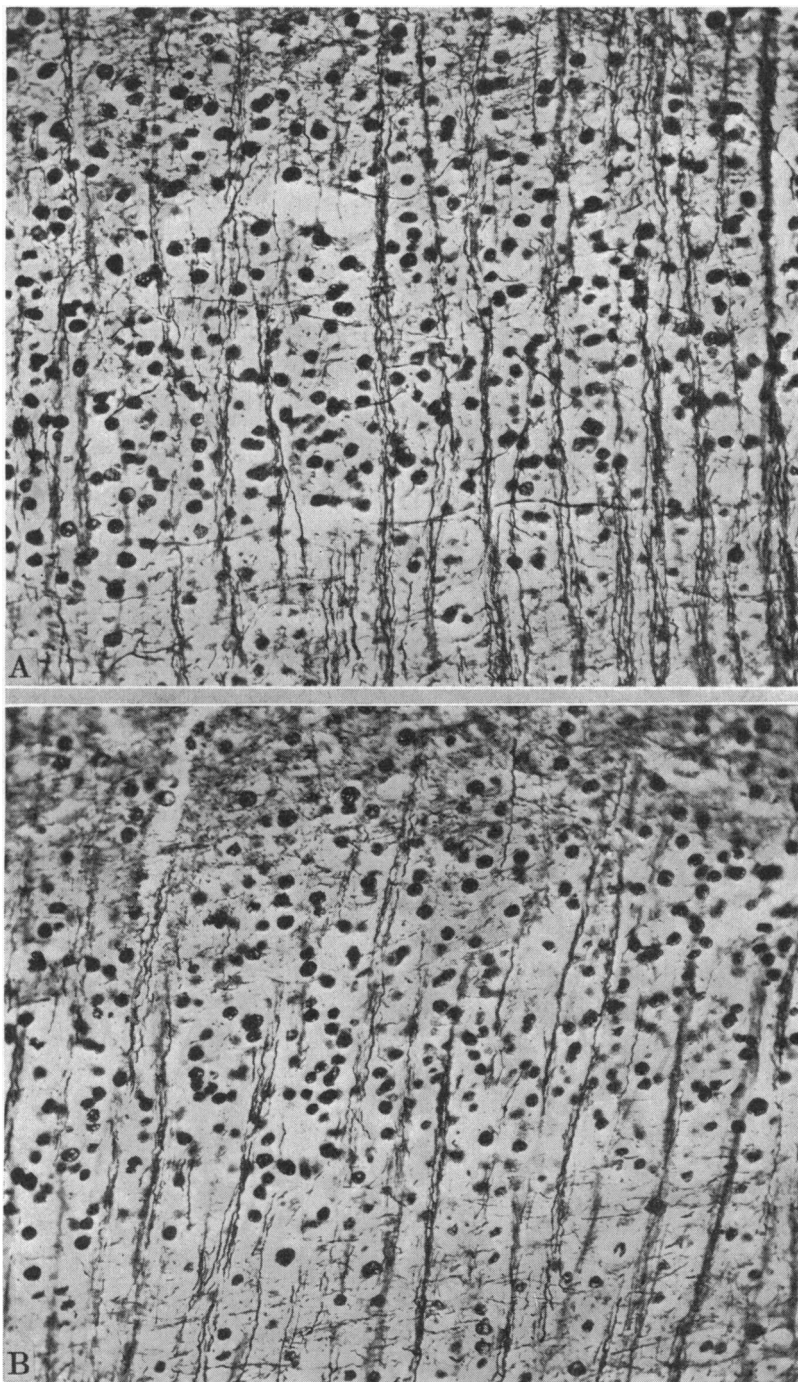


Fig. 2.

an ocular micrometer and the use of a 1/12th oil immersion lens, actual counts of fibres were made in fifty different fields of the normal and isolated cortex in O.M. 226. These showed that in a length of normal cortex of 80 μ there was an average of twenty-four fibres, while on the operated side the average was 20.5. There appears, therefore, to be a reduction in the isolated cortex of rather less than 15%. It is interesting to note that in O.M. 164, this reduction affected not only the isolated cortex of the opercular lip, but also the area *b* (shown in Text-fig. 1) which had been separated on either side from the adjacent visual cortex while still retaining its connexions with the medullary white matter of the occipital lobe. It thus appears that the radial fasciculi are made up of association fibres connected with adjacent regions of the cortex and not of projection fibres connected with subcortical levels. This is in accordance with the observations of Poliak (1932) in his studies of Marchi degeneration in the cortex of the monkey's brain following capsular lesions. Lastly, it may be noted that the reduction of the radial fibres affects mainly those of larger calibre, and that it involves no reduction in the number of the radial fasciculi in a given length of cortex.

Perhaps the most evident change in the fibre architecture of the isolated cortex is the disappearance of a large proportion of the obliquely running fibres in the lower levels of the cortex. This is made evident in the microphotographs shown in Text-fig. 2 in which the "background" of lamina IV *c* is manifestly much clearer in the isolated cortex. This reduction of the obliquely disposed fibres (particularly affecting the axones of larger calibre) is not present in area *b* of O.M. 164, which suggests that they are predominantly composed of projection fibres reaching the cortex from subcortical levels, rather than association fibres from neighbouring regions of the cortex. This, again, is in accord with Poliak's observations noted above.

The stria of Gennari appeared to be unaffected by isolation; we were unable to discern any alteration in the thickness of this stria or in its density. This is somewhat surprising in view of the statements made by several observers that changes in the area striata following on prolonged blindness take the form of a reduction of the stria. Bolton (1900), for example, maintained that in congenital anophthalmos the stria becomes narrowed to two-thirds of its normal thickness. Poliak (1927) has also stated that in the cat the stria does not originate in the cortex itself; in other words, it is not an endogenous association layer but an exogenous projection system. However, he qualifies this statement by observing that "this view does not conflict with the existence of ramifications of other axis cylinders in the same stratum, fibres which originate in the cells of the visual cortex itself". Our own observations suggest that, in the monkey, the stria of Gennari is predominantly composed of endogenous fibres.

SUMMARY

1. The structure of an isolated area of visual cortex shows relatively little change in its cell or fibre architecture. This is taken to indicate the richness of the intracortical connexions of each part of the cortex with the immediately neighbouring cortex.

2. In the isolated cortex there is a slight general reduction of cells which affects all the laminae. Most of the large stellate cells of lamina IV *b* and many of the large solitary cells of Meynert in lamina VI undergo atrophy and disappear. Evidence is adduced that these cells give origin to projection fibres passing to subcortical centres, rather than to association fibres either to neighbouring or distant areas of the cortex.

3. In the isolated cortex there is a reduction of the number of individual radial fibres, while the number of fasciculi which they compose remains unchanged. It is probable that these radial fibres are association fibres derived from other parts of the visual cortex. The network of obliquely disposed fibres in the deeper levels of the cortex mostly disappears; the experiments suggest that these fibres are projection fibres derived from subcortical centres. The stria of Gennari remains apparently unchanged in width and density.

REFERENCES

BECK, E. (1930). *J. Psychol. Neurol.* Bd. XLVI, S. 193.
 BOLTON, J. S. (1900). *Philos. Trans. B*, vol. CXCH, p. 165.
 BRODMANN, K. (1903). *J. Psychol. Neurol.* Bd. II, S. 133.
 CLARK, W. E. LE GROS & NORTHFIELD, D. W. C. (1937). *Brain*, vol. LX, p. 126.
 DUSSER DE BARENNE, J. G. (1934). *Arch. Neurol. Psychiat., Lond.*, vol. XXXI, p. 1129.
 HOLMES, G. & MAY, W. P. (1909). *Brain*, vol. XXXII, p. 1.
 KAPPERS, C. U. ARIENS (1909). *Arch. Neurol. (Mott's)*, vol. IV, p. 161.
 LEVIN, P. M. & BRADFORD, F. K. (1938). *J. comp. Neurol.* vol. LXVIII, p. 411.
 LORENTE DE NÓ, R. (1923). *Trab. Lab. Invest. Biol.* vol. XX, p. 1.
 — (1938). *Fulton's Physiology of the Nervous System*, Chapter xv. Oxford Medical Publications.
 MEYNERT, T. (1872). *Stricker's Handbuch Gewebelehre*, Bd. II.
 NGOWYANG, G. (1935). *J. Psychol. Neurol.* Bd. XLVI, S. 353.
 — (1937). *J. comp. Neurol.* vol. LXVII, p. 89.
 NISSL, F. (1911). *Versamml. dtsch. Nat. Aertze Heidelberg*.
 O'LEARY, J. L. & BISHOP, G. H. (1938). *J. comp. Neurol.* vol. LXVIII, p. 423.
 POLIAK, S. (1927). *J. comp. Neurol.* vol. XLIV, p. 197.
 — (1932). *Univ. Calif. Publ. Anat., Lond.*, vol. II, p. 1.
 SUNDERLAND, S. (1938). *J. Anat., Lond.*, vol. LXXIII, p. 120.
 VAN VALKENBURG, C. T. (1913). *Brain*, vol. XXXVI, p. 119.
 DE VRIES, I. (1912). *Folia neurobiol., Lpz.*, Bd. VI, S. 289.


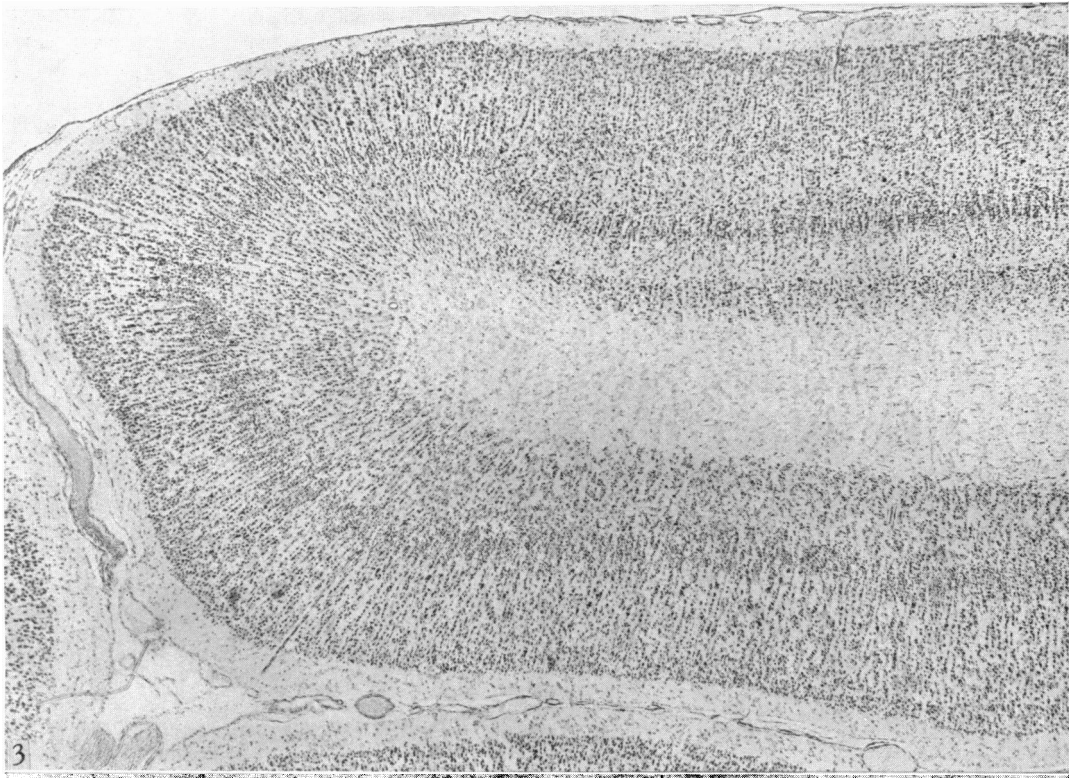
EXPLANATION OF PLATES I AND II

PLATE I

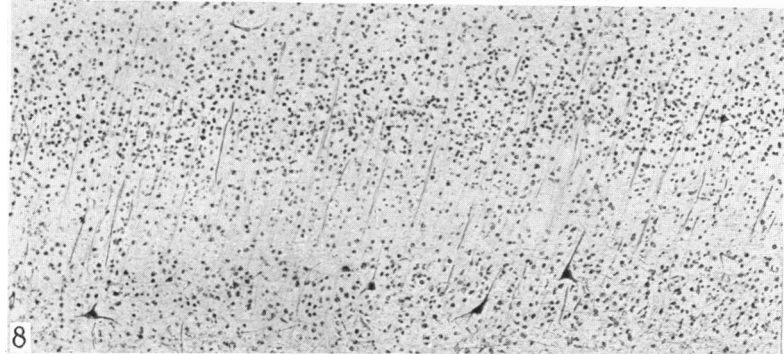
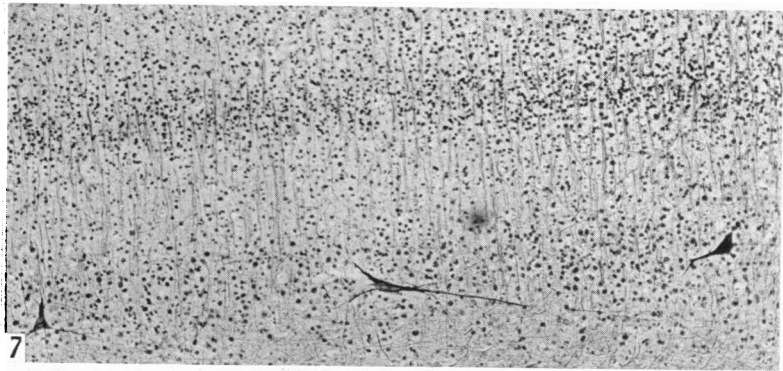
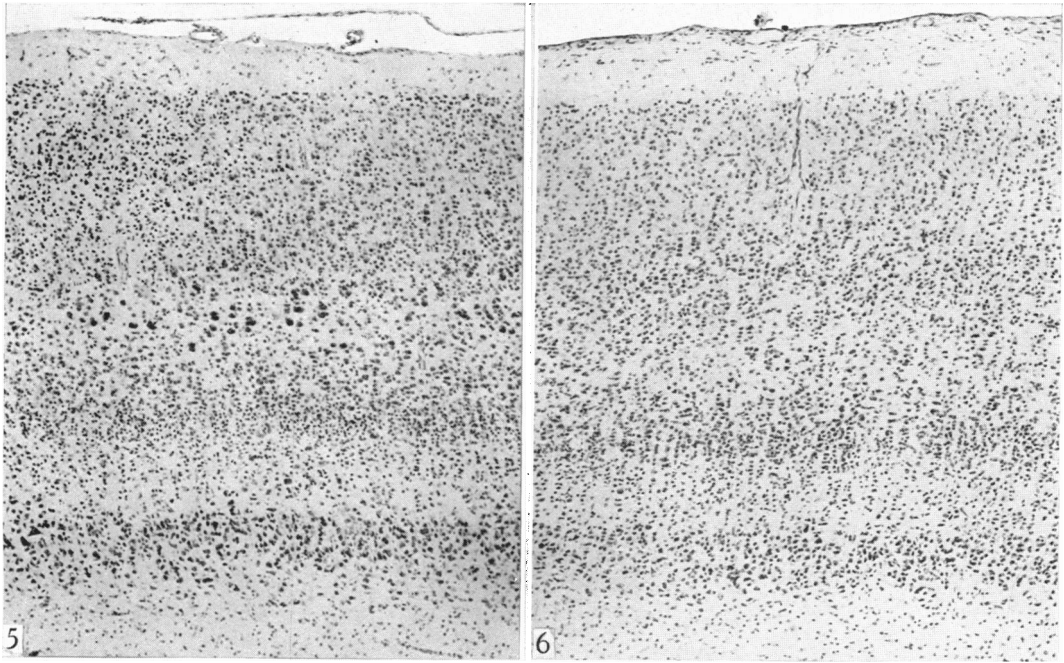
Fig. 3. Section through the opercular lip of the normal visual cortex of O.M. 226. ×35.
 Fig. 4. Section through the isolated opercular lip of O.M. 226. ×35. These sections demonstrate the small degree of alteration in the cytoarchitecture of the visual cortex even after it has been isolated for a period of 118 days.

PLATE II

- Fig. 5. Section through the normal visual cortex of O.M. 164, taken from the central region of the occipital lobe. $\times 72$.
- Fig. 6. Section through an isolated area of visual cortex from a corresponding region of the occipital lobe (area *c* in Text-fig. 1), showing disappearance of the large stellate cells in lamina IV*b*, and a general reduction of cells in all the laminae. $\times 72$.
- Fig. 7. Section of the normal visual cortex of O.M. 149, stained with Bodian's silver method. The section shows the granular and infragranular laminae. Note the characteristic large cells of Meynert in lamina VI. $\times 90$.
- Fig. 8. Corresponding section through the isolated cortex of O.M. 149. Note the shrinkage and denser staining of the Meynert cells which occurs 14 days after isolation. $\times 90$.



LE GROS CLARK AND SUNDERLAND—STRUCTURAL CHANGES IN THE ISOLATED VISUAL CORTEX



LE GROS CLARK AND SUNDERLAND—STRUCTURAL CHANGES IN THE ISOLATED VISUAL CORTEX