

OBSERVATIONS ON THE NEUROHISTOLOGICAL BASIS OF CUTANEOUS PAIN

BY THE LATE H. H. WOOLLARD, GRAHAM WEDDELL
AND J. A. HARPMAN

From the Department of Anatomy, University College, London

THE hypothesis that characteristic morphological nerve endings subserve specific modalities of sensation is widely accepted. Conclusive histological evidence in support of this theory has not, however, been forthcoming. In this paper, the relation of cutaneous pain to the doctrine of specific nervous activity is discussed in the light of new physiological and histological observations.

PHYSIOLOGICAL INVESTIGATIONS

Experiments were carried out on six human subjects. Pain was aroused by the introduction of either glass or steel needles into the skin. Deformation was reduced to a minimum by the use of fine, sharp needles inserted at right angles to the surface under vision through a dissecting microscope. Touch and cold spots were identified by methods previously described (Woollard, 1935). Warmth spots were mapped out by means of electrically heated platinum loops 1 mm. in diameter.

Penetration experiments

The introduction of fine, sharp needles into the skin of the forearm may arouse either no sensation whatever, or sensations of touch, pain, pressure, cold or warmth. Insertion of the needle into previously identified warmth or cold spots frequently arouses the corresponding sensations.

When a fine, sharp needle is used, no pain is felt until penetration occurs. Two types of pain can be aroused, the first being abrupt in onset, hurting little, and lasting for a period corresponding to that during which the stimulus is being applied; the second is delayed in onset, rises gradually in intensity, gives the impression of a small stinging area and disappears slowly. The phase of maximum intensity may occur as much as 2 sec. after the application of the stimulus, even if this be withdrawn immediately.

Both types of cutaneous pain are obtained with equal frequency in the forearm; they may occur independently or successively during the course of a single penetration. When a fine, sharp needle penetrates rapidly and deeply, the delay in onset of the second pain is usually greater in the distal than in the proximal parts of the extremities. Sometimes, however, throughout the extremity the interval between the two sensations of pain may be so brief that

a single prolonged phasic sensation is experienced. Two pain sensations, separated by a distinct interval, as well as phasic sensations, can be aroused from the skin of the face, forehead, neck, upper part of the chest and shoulders. Two distinct types of pain cannot be provoked from the skin of the back or abdomen, where successful stimulation leads only to phasic sensations. The distance from the skin surface at which the fundamental modalities of cutaneous sensation can be aroused was determined by the following method. The forearm, wrist and hand were rigidly held in a plaster cast, which left a portion of the volar aspect of the forearm exposed. A very fine needle was clamped vertically over the exposed area in a rack and pinion mount. The needle was lowered into the skin under vision through a dissecting microscope and the depths of penetration read off directly. The measurements were confirmed by painting the protruding shaft of the needle with Indian ink, after particular sensations had been aroused, and determining the length of needle free from ink after withdrawal.

Table I. *Levels at which various sensations are aroused in the skin of the forearm*

Sensation aroused	Depth of penetration
Pressure	2.0-2.5 mm.
Warmth	1.75-2.5 mm.
Touch	Surface contact-2.0 m.
Cold	1.0-1.5 mm.
Second or deep pain	1.0 mm. (average)
First or superficial pain	0.25-0.5 mm.

When the surface of the skin is stimulated by rapid, brief application of bristles or glass beads of not more than 0.5 mm. in diameter, touch, accompanied by both pain sensations, is aroused. The sensation can be described as one of pricking touch. Itching often follows the application of such stimuli.

Observations on cutaneous sensation during and after removal of the epidermis

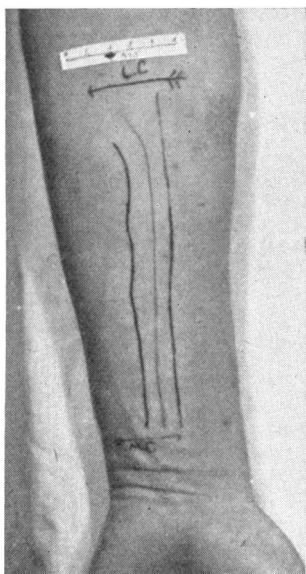
An area of skin on the forearm was scraped with a scalpel so as to remove as much of the epidermis as possible without drawing blood. There was no change in the frequency or distribution of either pain or warmth spots. Cold spots, however, were more numerous. The thresholds for all three sensations were reduced. Pain resulted from slight friction or contact.

No pain was aroused during removal with a razor of as much epidermis as possible without causing bleeding. The area soon became hyperalgesic, and accurate measurements of levels at which pain was provoked were difficult to obtain. The hyperalgesia was allayed by covering the denuded surface with lint smeared thickly with lanoline for a period of 6 hr. Penetration experiments using needles were then carried out. The relation of the point of the needle to dermal capillary loops was observed through a dissecting microscope. No pain

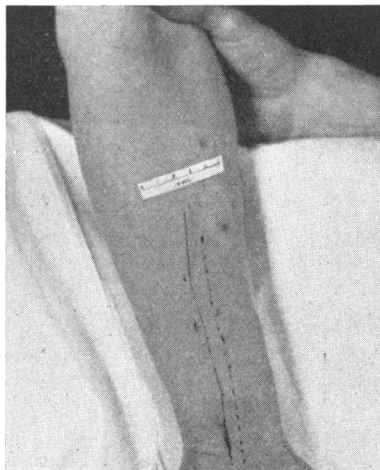
was aroused until the needle reached the level of the capillary bed. At this subepidermal level, the pain provoked was of the type aroused in normal areas by needles penetrating to depths of around 1 mm., and was of the usual intensity. The more superficial variety of pain could also be aroused at depths of around 0.5 mm. from the lanoline-covered normal margin surrounding the denuded area. Hyperaesthesia to cold was abolished by the ointment.

Relation of the subepidermal pain mechanism to capillaries

Dermal capillary loops were rendered visible by the application of cedar-wood oil to the skin overlying the nail bed. Pain was experienced when the point of the needle lay at the level of a capillary loop. The sensation aroused was similar to the delayed, more intense type of cutaneous pain.



Text-fig. 1.



Text-fig. 2.

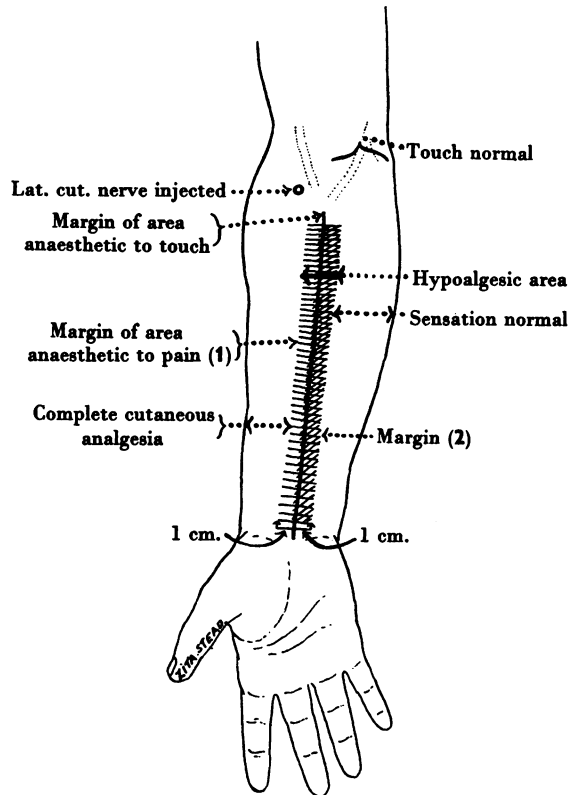
Text-fig. 1. Photograph of a forearm in which complete anaesthesia of the lateral and media cutaneous nerves was obtained on successive days. There is no detectable overlap of touch (centre line). Pain overlaps for a distance of approximately 1 cm. on either side of this line.

Text-fig. 2. Photograph of the volar aspect of a forearm in which complete anaesthesia of the lateral cutaneous nerve had been obtained. The margin of the area insensitive to pain is represented by a broken line, the margin of the area anaesthetic to touch by a continuous line. The distance between the two margins is approximately 1 cm.

Sensory dissociation experiments

Cutaneous nerves of the forearm and digital nerves in the upper extremity were anaesthetized by infiltration, around the trunks, of 2-4 c.c. of 4% novocain containing 1 in 10,000 to 1 in 20,000 adrenalin. The nerves were located by faradic stimulation (Thompson & Inman, 1928).

When anaesthesia of either the medial or lateral cutaneous nerve of the forearm is complete, the margins of the respective areas anaesthetic to touch on the volar aspect of the limb coincide within the limits of experimental error. The margins of the areas anaesthetic to pain, on the other hand, fall short of those anaesthetic to touch, due presumably to overlap of fibres from the adjacent nerve (Text-figs. 1, 2). No sensation other than pain can be aroused



Text-fig. 3. Volar aspect of forearm. Areas in which \equiv = superficial pain, \parallel = deep pain, can be aroused from the hypoalgesic area. (1) The number of spots from which pain can be aroused is least near this margin. The number increases gradually through the hypoalgesic area until margin (2) is reached where the frequency is normal.

from the area of overlap. The distance between the margins of the areas anaesthetic to pain and to touch is approximately 1 cm. on the forearm, somewhat less than 1 cm. on the thenar eminence, and undetectable on the fingers. When anaesthesia is incomplete, the area anaesthetic to pain may be larger or smaller than that insensitive to touch.

When anaesthesia of the medial or lateral cutaneous nerves of the forearm is complete, the number of spots from which pain can be aroused is below normal on either side of the margin of the area anaesthetic to touch for a

distance of 1 cm. In the area from which pain only can be provoked, the superficial type alone is obtainable to within 3 mm. of the margin of the area insensitive to touch. From the remainder of the hypoalgesic area, both varieties of pain can be aroused (Text-fig. 3).

An ulcer was made on the volar aspect of the forearm with solid carbon dioxide. Eight days later, the ulcer was 5 mm. in diameter and the base extended into the dermis. The margin of the ulcer was hyperalgesic. In an area of skin of 4 sq. mm. situated immediately distal to the ulcer, pain only could be aroused. In the remainder of the surrounding skin, touch and temperature sensations could also be aroused.

Sensory localization experiments

Needles and electrodes supplied with induction shocks (Lewis, 1936, 1937b) were used. The minimum distance at which two successive stimuli provoking pain can be recognized as having been applied at different sites is about 1 cm. on the forearm, about $\frac{1}{2}$ cm. on the palm of the hand, and too small to be accurately determined on the pad of the finger. Two stimuli arousing pain of equal intensity applied simultaneously are perceived individually when the distance between them is not less than 1 cm. across the forearm, 1.2 cm. along the length of the forearm, 3-7 mm. on the palm of the hand, and 1 mm. on the pad of the finger. When the distance between such stimuli is less than 1 cm. on the forearm, pain appears to emanate from a single point, but is of greater intensity than the pain provoked by a single such stimulus. The localization of both the superficial and deep varieties of cutaneous pain is of the same order of accuracy.

Two-point discrimination of tactile stimuli averages 2 mm. on the volar aspect of the forearm.

Observations in a case of antero-lateral chordotomy

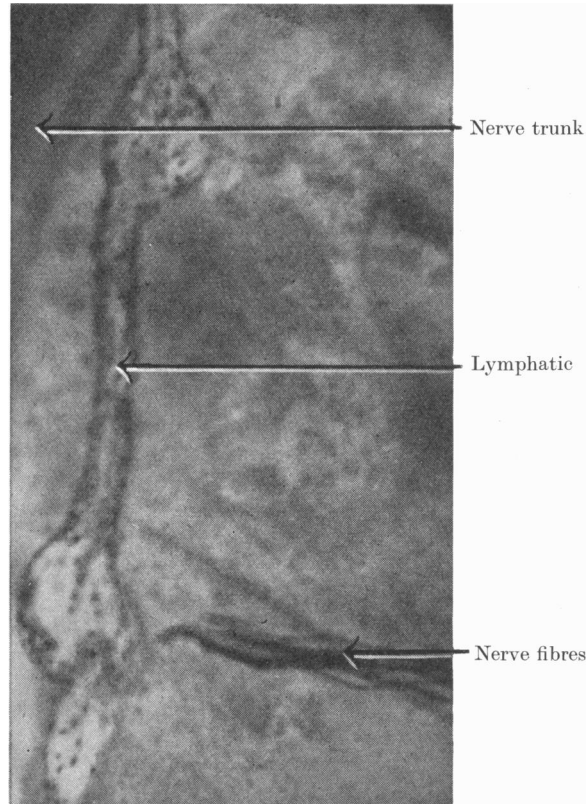
Superficial and deep cutaneous pain, cold, and warmth could not be aroused from the affected regions of the body. The sense of touch was apparently unimpaired. Itching was not experienced in the analgesic area subsequent to operation.

HISTOLOGICAL INVESTIGATIONS

The innervation of the skin and blood vessels of the ear of the rabbit

Staining technique. Clark *et al.* (1934) stained nerve fibres supplying capillaries in the ear of the rabbit *in vivo* by injecting small volumes of methylene-blue solutions into local blood vessels. Their observations suggested the possibility of experimenting upon cutaneous nerves and nerve endings in the surviving animal. The subcutaneous and intradermal injection of solutions of methylene blue in normal saline into the ear of the rabbit was found to stain

nervous tissue selectively (Text-fig. 4). Concentrations of 0.005–0.5 % methylene blue were used. The best average results were obtained by using a concentration of 0.01 % methylene blue in normal saline solution. Precautions to be observed in preparing the solutions have already been described (Weddell *et al.* 1940). The volume of solution injected was between 1 and $1\frac{1}{2}$ c.c. at each puncture, the number of injections depending upon the area it was desired to



Text-fig. 4. Photomicrograph showing nerves stained *in vivo*. Rabbit ear. $\times 550$.

investigate. Observations were made after shaving the ear and rendering the surface layers of the skin transparent by the application of olive oil or liquid paraffin. Nerves and nerve endings did not stain satisfactorily when the local vessels remained constricted after the injection. Good results, however, were obtained when the dye was introduced into ears in which the vessels were at first constricted, but dilated by warmth 10 min. after the injection. Good results were also obtained when the dye was introduced into ears the vessels of which were dilated, provided the circulation was arrested for 10 min. subsequent to injection. Particularly good results were obtained in animals

previously subjected to cervical sympathetic neurectomy. Permanent preparations were made by removing pieces of skin in which the nerves and their endings were stained, and fixing and clearing them in the usual way.

Observations on normal and sympathectomized material. During and for a short time subsequent to introduction of the dye, the skin and subcutaneous tissues of the ear stain uniformly blue. After 15–20 min., nerves and nerve endings close to blood vessels begin to stain specifically. Twenty to thirty min. after injection, the remaining nerves become stained and nerve endings become visible. The colour fades from the surrounding tissues as the nerves become

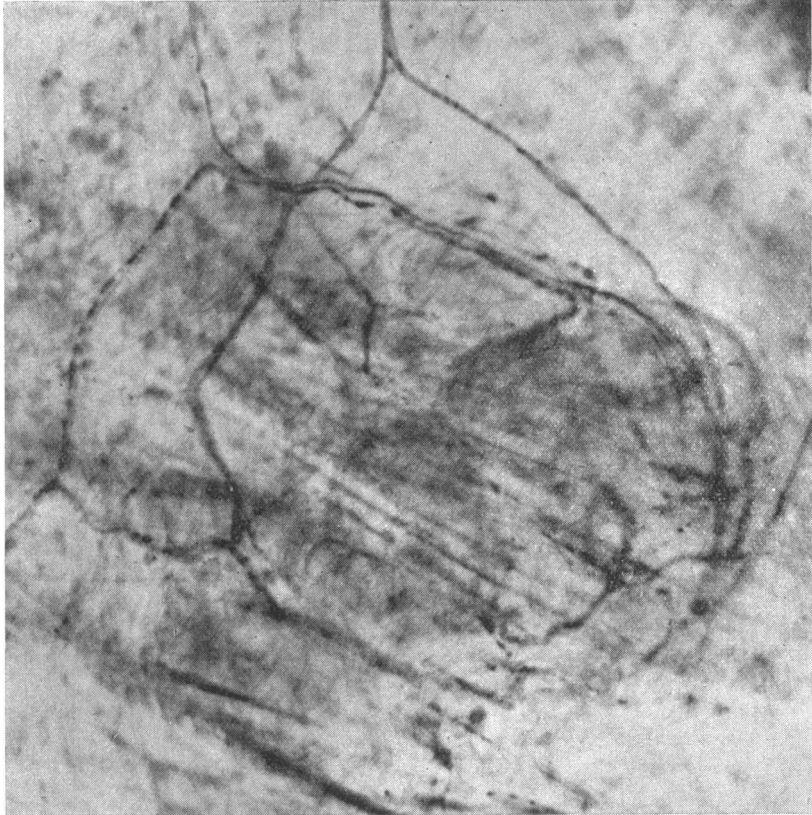


Text-fig. 5. Photomicrograph showing deep and superficial nerve plexuses in the skin of the ear of the rabbit. Methylene blue. $\times 33$.

stained. Hair follicles and sebaceous glands remain blue for a longer period than other non-nervous tissues (Text-figs. 5, 9 and 10 and Pl. I, fig. 1). The blue begins to disappear from the nerves and nerve endings about 45 min. after the injection of the dye. If large lymphatic vessels are ruptured during the injection, the dye is seen to pass along these channels and no staining of nerve results. Fibroblasts (Pl. I, fig. 1), macrophages, endothelial cells, reticular connective tissue and muscle fibres around vessels stain markedly when the concentration of the dye exceeds 0.02%. Neurilemma sheath cells frequently stain, but become clearly outlined only when the concentration of the dye exceeds 0.01%.

In the deeper layers of the dermis there is a nerve plexus (Text-fig. 5 and

Pl. I, fig. 1) consisting of thick and thin medullated and non-medullated fibres. The medullated fibres are sometimes of smaller diameter than the non-medullated fibres. This plexus gives rise to a more superficial plexus consisting of thinner medullated and non-medullated fibres (Text-fig. 5 and Pl. I, fig. 1). The finer fibres often appear varicose. In both plexuses, several axis cylinders of both thick and thin varieties commonly course within a single



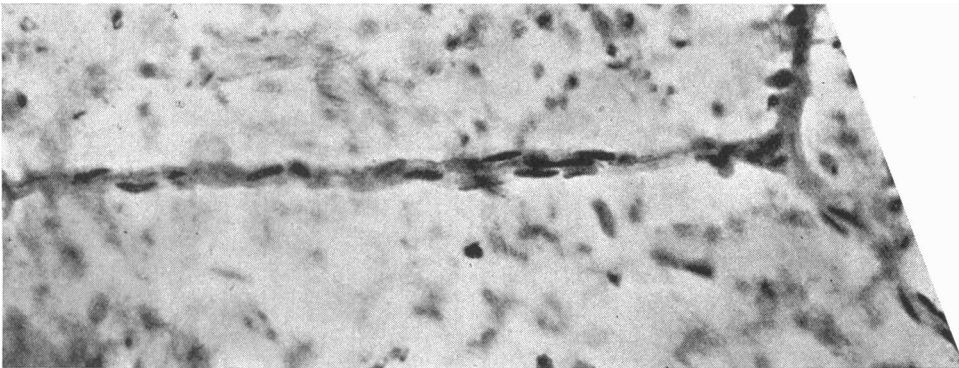
Text-fig. 6. Photomicrograph showing nerve fibres innervating a group of hair follicles. Methylene blue. Rabbit ear. $\times 470$.

neurilemma sheath. The thick fibres supply hair follicles (Text-fig. 6), as many as seven fibres ending on a single follicle; finer medullated fibres from both plexuses may also supply hair follicles (Pl. II, fig. 3). Nerve fibres leave the superficial plexus—the medullated fibres losing their medullary sheaths—assume a varicose appearance, branch repeatedly over a wide area, and end in fine, naked, beaded terminals (Pl. II, fig. 5) disposed below and among the cells of the deeper layers of the epidermis. Similar nerve fibres and nerve endings occur in the adventitia of blood vessels (Pl. I, fig. 2 and Pl. II, fig. 4.)

Non-medullated fibres end on blood capillaries, blood vessels and larger lymphatic vessels by small expansions, a single fibre undergoing a minimum of branching and covering a relatively small area of vessel wall. No encapsulated nerve endings occur in the skin of the ear of the rabbit.

Unilateral cervical sympathetic neurectomies were performed on two rabbits. Persistent Horner's syndromes ensued. After 74 and 21 days respectively, the only nerve fibres and nerve endings not demonstrable were those supplying limited portions of the walls of capillaries, blood vessels and larger lymphatic vessels (Pl. I, figs. 1, 2 and Pl. II, figs. 4, 5).

Stimulation by a fine needle of the stained free nerve endings in the skin, or stimulation previous to section by a spear-headed needle of the stained nerve bundles of the superficial or deep dermal plexus in lightly anaesthetized

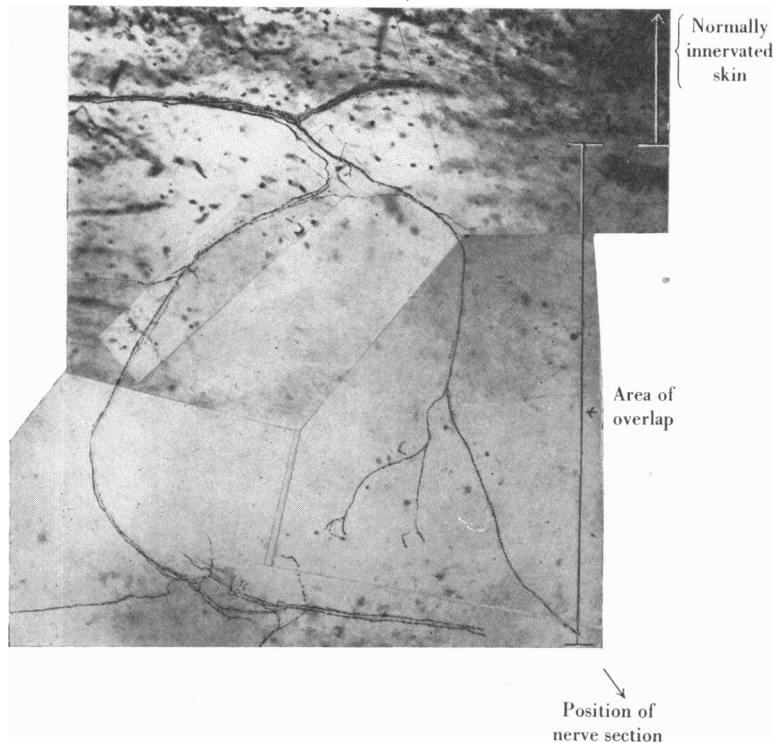


Text-fig. 7. Photomicrograph showing a neurilemmal sheath containing a degenerating fibre. From a denervated area of skin in the ear of a rabbit. Methylene-blue preparation, 2 days after nerve section. $\times 450$.

animals causes struggling. Stimulation of stained nerves passing to, and of the terminal nerve apparatus around, hair follicles calls forth no such reaction.

Experimental observations. Cutaneous nerve bundles consisting of two to four axones were sectioned. On completion of the section, the ends sprang apart, and a small quantity of blue substance exuded from each cut end. A day later, in a continuous area surrounding the site of section, the dye persisted unchanged in intensity of colour for a considerable period of time. The hair follicles were more deeply stained than in normal material, but less clearly outlined, neurilemma sheath cells were enlarged, their nuclei stained more intensely, and nerve fibres within the sheaths were fragmented. Two days later, only the outlines of nerve sheaths were demonstrable (Text-fig. 7). The size of the affected area varied from 2×3 mm. to 10×17 mm. according to the number of axis cylinders in the nerve bundle sectioned. Approximately 5 days after a nerve bundle had been sectioned, two to four regenerating nerve fibres were seen invading the periphery of the denervated area. When the denervated area was small, complete regeneration was found to take place in 8 days.

Examination of the margins of denervated areas revealed that a number of nerve fibres arising from the superficial plexus and a few of the finer fibres from the deep plexus extended farther towards the denervated area than other fibres (Text-fig. 8 and Pl. III, fig. 6) for distances averaging 1 mm. The overlapping somatic fibres from the superficial plexus gave rise to fine beaded naked nerve terminals distributed to the superficial layers of the dermis,



Text-fig. 8. Photomicrograph showing overlap between collaterals of nerve fibres extending towards a denervated area in the skin of the ear of a rabbit. Methylene-blue preparation 3 days after nerve section. $\times 160$.

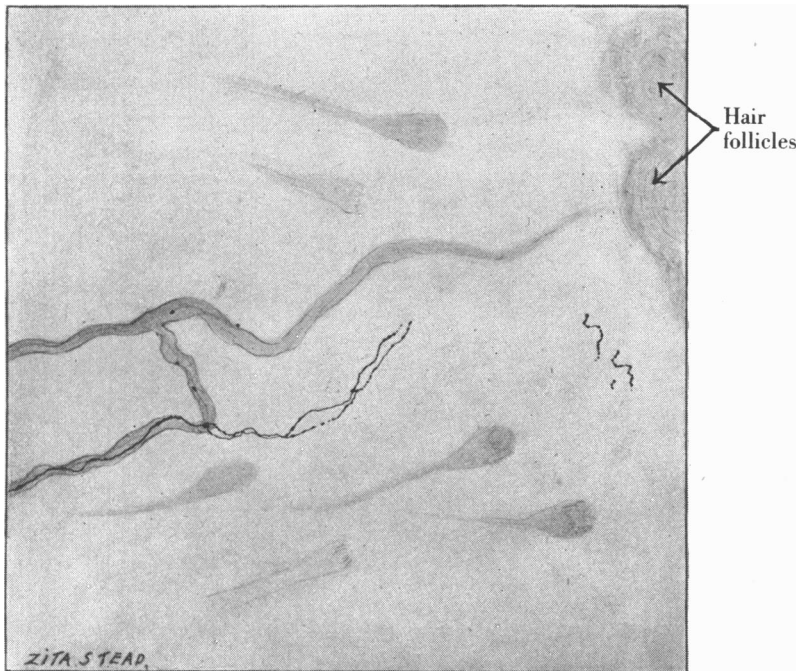
deeper layers of the epidermis, and the adventitia of blood vessels. The thin overlapping fibres often ran for some distance within a sheath common to fragmented degenerating axis cylinders passing to diffusely outlined hair follicles within the denervated area. When axis cylinders supplying hair follicles had degenerated completely, their previous existence could often be inferred from the outline of the persisting neurilemma sheath (Text-fig. 9).

When a fine fibre overlaps towards the denervated area, it sometimes gives off divergent terminal branches (Text-fig. 8 and Pl. III, fig. 6). These branches overlap with similar collaterals from a neighbouring fibre within the marginal

area (Text-fig. 8). The number of nerve fibres bearing free endings in the area of overlap is less than in normally innervated skin.

Stimulation, by pricking with a fine needle, of the overlapping epidermal and subepidermal branched varicose fibres and free nerve endings at the margins of denervated areas, elicited struggling in lightly anaesthetized animals.

Similar observations were made on the margins of artificially produced ulcers on the skin of the rabbit's ear.

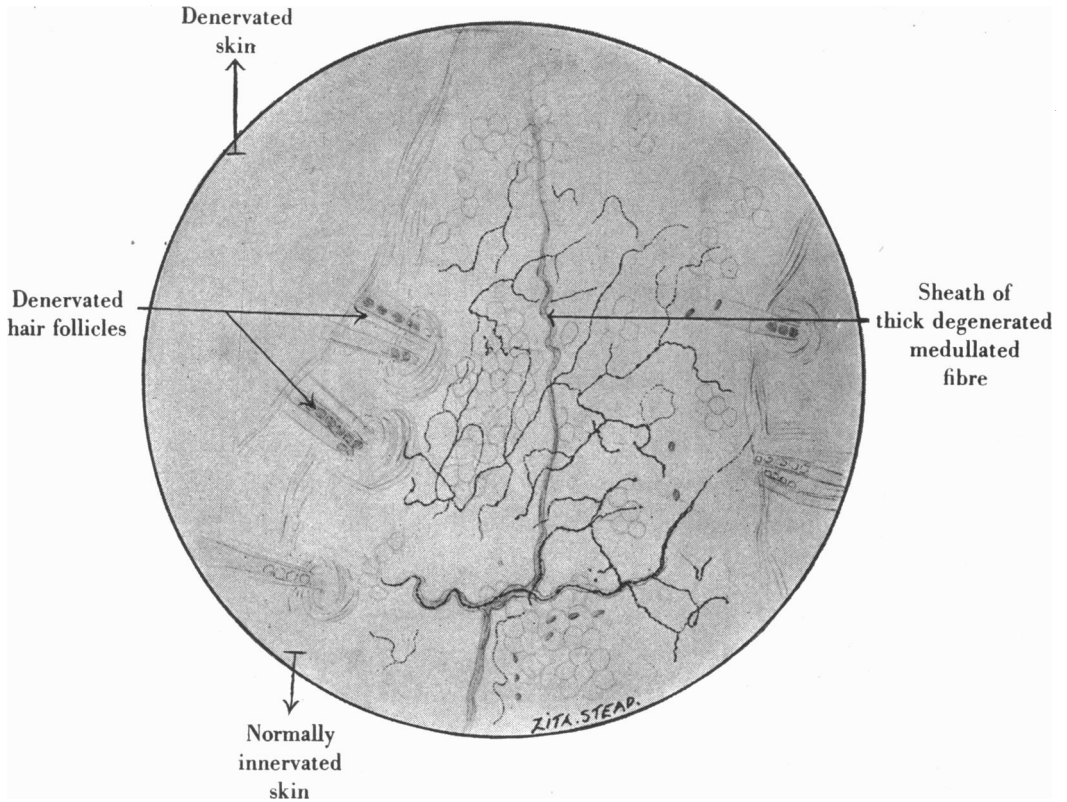


Text-fig. 9. Camera lucida drawing showing a fine medullated nerve fibre giving rise to free nerve endings in an overlap area of skin in the ear of a rabbit. The sheath of a degenerated medullated fibre supplying a hair follicle is outlined. Methylene-blue preparation 3 days after nerve section.

Nerve overlap in the thoracic skin of the rabbit

Two adjoining intercostal nerves were avulsed close to the intervertebral foramina. Ten to twelve days later, preparations were made by perfusion of 0.1 methylene blue in normal saline solution through the aorta. The finer medullated and non-medullated nerve fibres bearing free endings extended for 3-5 mm. from the adjoining normally innervated skin into the affected area. The overlapping nerve fibres and nerve endings have the same morphological characteristics as those at the margins of denervated areas in the ear (Text-

fig. 10). There is a reduction in the number of nerve fibres bearing free endings per unit area in comparison with normal regions.



Text-fig. 10. Camera lucida drawing showing fine nerve fibres and free nerve endings in an overlap area in the thoracic skin of a rabbit. Methylene-blue preparation 10 days after avulsion of two adjacent intercostal nerves.

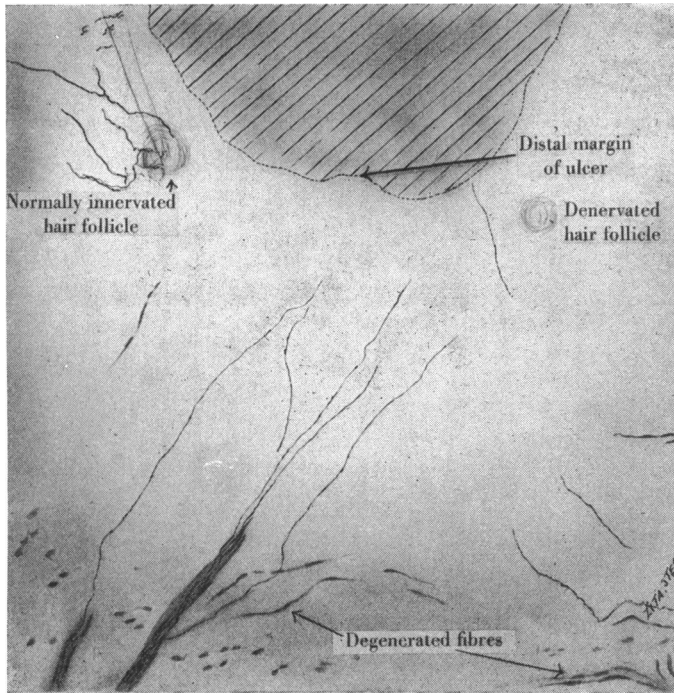
Observations on human skin

Eight days after producing the ulcer on the forearm, 0.02% methylene blue in normal saline solution was injected into the surrounding skin. After 30 min., the skin around the ulcer was excised, and prepared for histological examination. In the skin immediately distal to the ulcer, only fine nerve fibres occur, giving rise to free subepidermal and intraepidermal nerve endings (Text-fig. 11).

Methylene blue and reduced silver preparations of normal skin from the finger, forearm and thigh were examined. The superficial, subepidermal, nerve plexus and its associated nerve endings are similar to those in the rabbit (Pl. IV, fig. 7 and Text-fig. 12). The intraepidermal nerve endings occupy the deeper layers of the stratum mucosum, except in the fingers where they some-

times extend into the stratum granulosum. In silver material, they occupy an intercellular position and rarely present a varicose appearance. The plexus and nerve endings in question are present in material from the forearm of a patient on whom a "stellate" ganglionectomy had been performed.

"Accessory" nerve endings to Meissner's corpuscles and Krause's end bulbs (Text-fig. 13) were observed in methylene-blue and reduced silver

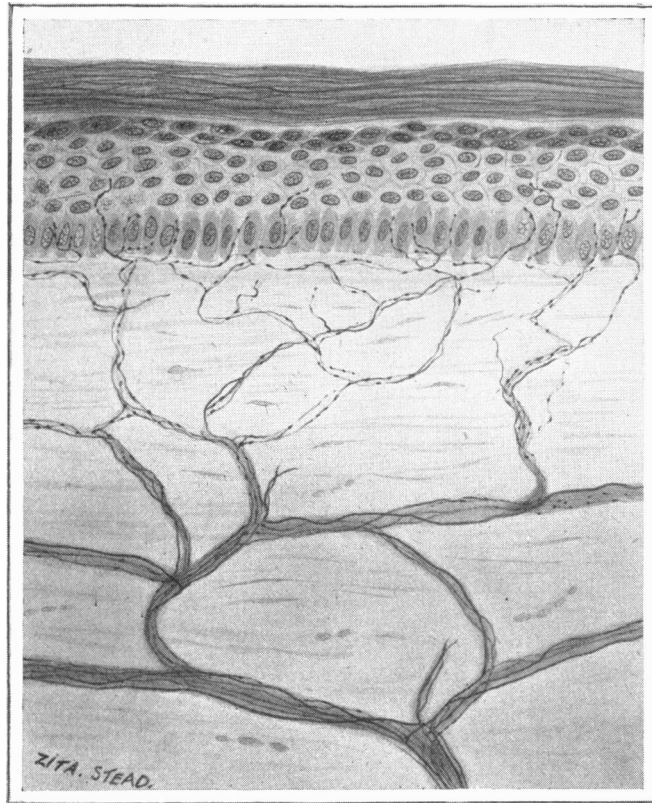


Text-fig. 11. Camera lucida drawing showing the innervation of the skin immediately distal to an ulcer on the human forearm. Methylene blue. $\times 85$.

preparations of normal material. They are derived from fine medullated or non-medullated fibres and course in close proximity to the thick medullated fibres which give rise to the principal nervous components of the endings. The "accessory" fibres often expand somewhat on approaching the ending, and then terminate by again becoming thinner and forming a fine skein within the corpuscle. From the fibre arise free nerve terminals distributed to the surrounding dermal tissues. "Accessory" fibres and endings present a varicose appearance in methylene-blue material and are similar to the fibres and free nerve endings of the subepidermal plexus.

**CORRELATION BETWEEN THE HISTOLOGICAL
AND PHYSIOLOGICAL FINDINGS**

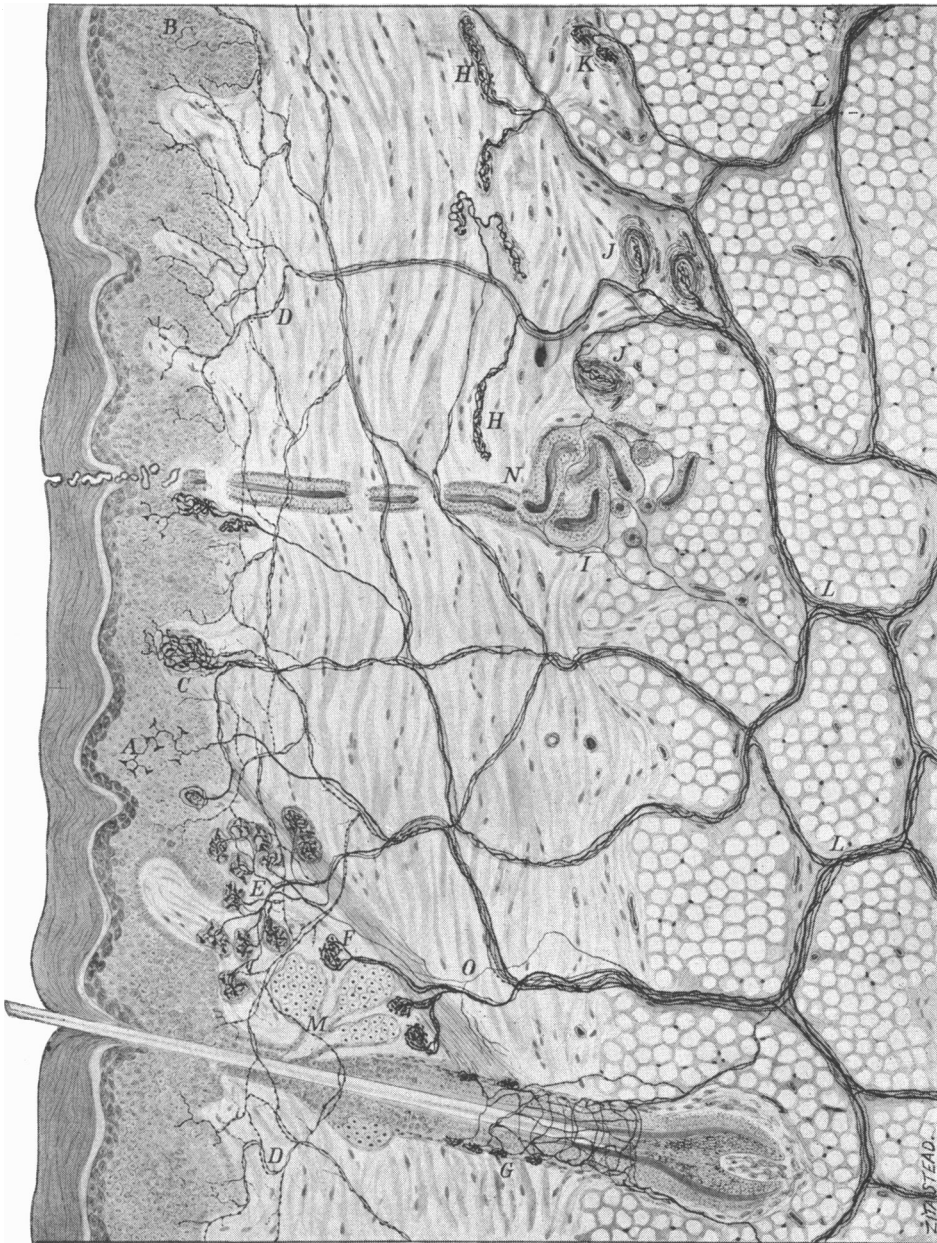
In the skin of the ear of the lightly anaesthetized rabbit, direct stimulation of the finer medullated and non-medullated fibres, and of free nerve endings to which they give rise, leads to struggling. No such reaction results from similar stimulation of the nerve fibres supplying hair follicles. These facts suggest



Text-fig. 12. Drawing showing the arrangement in the skin of the human forearm of nerve fibres and nerve endings subserving pain. Composite drawing from methylene-blue and reduced silver preparations. $\times 1100$.

that the fine nerve fibres and their associated endings subserve pain. From a small area of skin at the distal margin of the ulcer on the human forearm, pain only could be aroused. The neuro-histology of this area establishes that in the human skin pain is subserved by fine nerve fibres bearing free nerve endings.

The nerve fibres bearing free nerve endings extend farther towards denervated areas than other cutaneous nerve fibres and endings in the ear



Text-fig. 13. Composite diagram showing the innervation of the human skin. *A.* Merkel's discs, subserving touch. *B.* Free endings, subserving pain. *C.* Meissner's corpuscles, subserving touch. *D.* Nerve fibres, subserving pain. *E.* Krause's end bulbs, subserving cold. *F.* Nerve endings, subserving warmth (sometimes called Ruffini's endings). *G.* Nerve fibres and endings on hair follicle, subserving touch. *H.* Ruffini's endings, subserving pressure. *I.* Sympathetic nerve fibres innervating a sweat gland. *J.* Pacinian corpuscles, subserving pressure. *K.* Golgi-Mazzoni endings, subserving pressure. *L.* Nerve trunks containing thick and thin fibres. *M.* Sebaceous gland. *N.* Sweat gland. *O.* Sympathetic nerve fibres supplying arrector pili muscle. Drawing composed from methylene-blue and reduced silver preparations. The functional interpretations summarized above are based upon observations by the writers.

and thoracic skin of the rabbit. On the volar aspect of the human forearm and hand, dissociation of sensation on complete local anaesthetization of a cutaneous nerve demonstrates overlap of the nerve apparatus subserving pain.

In the rabbit, the nerve fibres presumably subserving pain dichotomize repeatedly, innervating relatively large areas of skin. The extent to which the fibres in question overlap towards denervated areas is also indicative of the relatively large area of skin supplied by the terminals of one such fibre. In man, the distance to which the nerve fibres and endings subserving pain overlap those subserving other cutaneous sensations is of the same order as the minimum distance at which two simultaneously applied stimuli arousing pain of equal intensity are perceived individually. This distance is as much as 1-1.2 cm. on the forearm. The facts suggest that, in man, a nerve fibre subserving pain derived from one dorsal root ganglion cell supplies a considerable area of skin. Thus, although cutaneous sensation has been found to be punctate, this does not imply that each spot contains a receptor derived from a separate neurone.

The extent and position of the hypoalgesic area in the sensory dissociation experiments on the human forearm, and the neuro-histology of the overlapping nerve fibres and endings presumably subserving pain at the margins of denervated areas in the skin of the rabbit, indicate that plexiform interlocking systems of fine nerve fibres bearing free nerve endings subserve the sensation of pain in man. The occurrence of spatial summation when two stimuli arousing pain are simultaneously applied at a distance of less than 1 cm. on the human forearm is in agreement with this interpretation.

The extent of overlap of the nerve fibres and endings presumably subserving pain in the skin of the rabbit is greater in the thoracic region than in the ear. In man, the extent of overlap of the cutaneous nerve apparatus mediating pain is greater in the proximal than in the distal regions of the upper extremity. It is inferred that there are corresponding regional differences in the neuro-anatomy in man.

Both superficial and deep pain are localized with the same order of accuracy, and cannot be aroused from the areas affected by antero-lateral chordotomy. The neuro-histology of normal skin in man and in the rabbit, the histology of nerve overlap, and the relative extent of overlap of superficial and deep pain in the human forearm, suggest that both varieties of cutaneous pain are subserved by the same nerve apparatus, deep pain being experienced when several fibres of the nerve plexus in question are stimulated. This interpretation accounts for the greater intensity and diffuse character of deep pain on the basis of spatial summation. It is suggested that the delay in onset and the persistence after stimulation of deep pain are related to the number of nerve fibres stimulated in a single nerve bundle. The differences in the time relations between the two types of pain aroused by a single rapid stimulus in various regions of the body are in accordance with the suggestion of a varying neuro-histology.

Hyperalgesia occurred at the margin of the ulcer on the human forearm. In a hyperalgesic area of skin immediately distal to the ulcer, pain only could be aroused, and the neuro-histology of this area established that only one type of nerve fibre and associated ending was present. Hyperalgesia is therefore associated with no nerves and endings other than those subserving pain.

DISCUSSION

Blix (1884, 1885), Donaldson (1885), v. Frey (1894, 1895, 1896, 1897, 1926), Goldscheider (1886, 1898), Sherrington (1900), Sommer (1900), Rivers & Head (1908), Trotter & Davies (1909), Haggqvist (1914), Strughold (1923), Foerster (1927), Dallenbach (1927), Pendleton (1928) and Waterston (1923, 1933 *a, b*) have brought forward evidence in support of the punctate theory of cutaneous sensation. The present findings, in conjunction with unpublished histological observations summarized in Text-fig. 13, and the findings of Strughold & Karbe (1925), Bazett (1935) and Woollard (1935, 1936*a*) concur in allocating specific sensory functions to morphologically characteristic nerve endings. The findings of the present writers as to the relative depths at which the various specific receptors are located in the skin of the human forearm are in agreement with the observations of Williams (1935), working on the human prepuce. The nature of the sensations aroused by the introduction of a needle depends upon both the spot at, and the depth to which, the needle is introduced (Text-fig. 13). Thus the theory of punctate sensation must be considered from a three-dimensional point of view. Waterston's (1923) finding that warmth and cold spots vary in position at different times is explained by the fact that the receptors concerned lie deep in the skin and are influenced by the state of the local blood vessels as well as by the external temperature. Burnett & Dallenbach (1927) have demonstrated that the feeling of heat is a complex of warmth and paradoxical cold with or without pain. The anatomical basis for this conception is implicit in a three-dimensional theory of punctate sensibility.

The large number of pain spots in the skin has made it difficult to establish the punctate representation of this sensation. v. Frey (1894), by the use of bristles, was able to evoke pain without an accompanying sensation of contact. Foerster (1927), from observations on blistered skin, has concluded that cutaneous pain is punctate. The same conclusion was reached by Rivers & Head (1908) and Foerster (1927) from observations on cutaneous areas the nerves to which were in process of regeneration. Waterston (1933 *a, b*) has found that in the skin there are small analgesic areas, and describes cutaneous pain as being punctate. Blix (1885) has denied that pain is represented in the skin in a punctate form analogous to warmth and cold spots. v. Frey (1899) states that every nerve ending is distinct from every other nerve ending and that it is not possible to distinguish distances of sensation on the skin smaller than the distance between two nerve endings. Tower (1935) states that in the cornea of the cat a single nerve fibre supplies an area of $\frac{1}{2}$ sq. cm. or more. The

findings recorded in the present paper show that cutaneous pain can be provoked from constant spots, but that many such spots occur within the relatively large area of skin supplied by one axone.

Waterston (1933 *a, b*) states that the introduction of a needle into the skin elicits no pain until the needle enters the superficial layers of the dermis, and that shaving off thin slices of the epidermis arouses no pain until the dermis is reached. Waterston considers that only touch can be aroused from the epidermis. Woollard (1936 *a*) has correlated histological observations with the results of shaving off thin slices of skin, and has concluded that in man the receptors for pain occur mainly immediately below the epidermis, and only occasionally in the epidermis. The present observations concerning the depths at which various modalities of sensation are aroused show that pain can be aroused from the deeper layers of the epidermis. Shaving off slices of skin is too crude a method of testing for epidermal pain.

Ranson (1913, 1914, 1931) has shown that the centripetal processes of the dorsal root ganglion cells which give rise to peripheral fine medullated and non-medullated fibres, lie in the lateral part of the dorsal roots and enter the tract of Lissauer. Ranson & Billingsley (1916) have shown that in the cat, stimulation of the portion of the dorsal roots containing the fine medullated and non-medullated nerve fibres leads to struggling, a rise in blood pressure and rapid respiration. These reactions are interpreted as resulting from a sensation of pain. Gasser & Erlanger (1929), Gasser (1935), Heinbecker *et al.* (1934) and Clark *et al.* (1935), from studies with the cathode-ray oscilloscope, have shown that pain is transmitted by slowly conducting fine medullated and non-medullated nerve fibres. The observations recorded in the present paper are in agreement with such conclusions.

Ranson *et al.* (1935) have indicated that there is no sharp distinction in function between fine medullated and non-medullated nerve fibres. There are individual and species variations in the relative numbers of these types of fibre in the same nerve or nerve root. The proportion of medullated fibres is greater in larger animals, in which the diameter of nerve fibres is in general greater. These findings are stated to be in agreement with Duncan's (1934) theory of progressive myelinization with increasing diameter of nerve fibres. Observations by Weddell *et al.* (1940) on the innervation of the musculature of the tongue, and the present study of the innervation of the skin, show that whilst medullated nerve fibres commonly lose their myelin sheaths on becoming finer in diameter, medullated nerve fibres are sometimes of smaller diameter than non-medullated fibres.

Adrian (1926, 1932) has shown that in the frog the impulses produced by painful stimuli are distinct from those produced by touch. Heinbecker & Bishop (1935) state that stimulation of nerve fibres conducting tactile or pressure sensation never results in pain. Heinbecker *et al.* (1934) have claimed that near-threshold stimulation of the fibre group conducting pain results in a sensation of pricking touch. In their experiments the possibility that tactile

receptors were being stimulated at the same time as pain receptors was not satisfactorily excluded. In the present experiments no sensation other than pain could be provoked from overlap areas. The evidence indicates that nerve-fibres transmitting pain are specific in this respect.

Cattell & Hoagland (1931) have shown that in the frog, no reactions that can be interpreted as resulting from pain take place when tactile receptors are caused to discharge impulses at very high frequency. Adrian (1932) has shown that in mammals pain is not provoked by high-frequency impulses from hair receptors. Thus pain is not aroused by overstimulation of these tactile receptors. Heinbecker & Bishop (1935) state that nerve endings subserving pain contrast with tactile receptors in having a relatively lower threshold for electrical than for mechanical stimuli. They interpret this finding as suggesting that electrical stimulation of pain receptors is essentially nerve-fibre stimulation, which in turn suggests the non-encapsulated character of these endings. Goldscheider (1926) considers that pain may result from excessive stimulation of endings recording deformation. Timofeyev (1895), Ruffini (1902), Dogiel (1892, 1893, 1904), Sokolow (1899), Sala (1899), Sfameni (1901), Michailow (1908), Ohmori (1923), Lalowy (1935), Woollard (1936*b*, 1937), Weddell & Harpman (1940), and others have described "accessory" nerve fibres and endings to encapsulated touch receptors, and to nerve endings subserving pressure, cold and proprioception from tendon. Lavrenko (1938) has established that the "accessory" fibres are somatic in origin. The "accessory" nerve fibres and endings are morphologically similar to the nerve fibres and terminals subserving pain. Woollard (1937) has described "accessory" fibres derived from the sub-epidermal nerve plexus.

v. Frey (1925) and Strughold & Karbe (1925) state that stimulation of the central part of the cornea arouses pain only. Nagel (1895), Marx (1921) and Pritchard (1931) remark that after cocainization of the conjunctiva a sensation of contact can be evoked from the cornea. This finding is explicable on the grounds of stimulation of extra-corneal sensory nerve endings by deformation. This explanation is suggested by the findings of Carmichael & Woollard (1933). The innervation of the cornea has been described by Ranvier (1878), Dogiel (1890), Attias (1912), Agabow (1912), Cajal (1933) and others. Medullated nerve fibres of small calibre reach the cornea *via* the sclera and ciliary body. The majority lose their myelin sheaths on entering the cornea. At times, several non-medullated nerve fibres lie within a single sheath (Nageotte, 1932). The nerve fibres form plexuses at various levels in the corneal connective tissues. In methylene blue and gold chloride preparations, the nerve fibres often present a varicose appearance. The fibres become smaller in diameter on approaching the epithelium. Free varicose nerve endings extend among the epithelial cells. The innervation of the cornea is thus similar to the subepidermal and intraepidermal nerve apparatus consisting of fine nerve fibres and free nerve terminals.

It is generally accepted that from teeth, as opposed to periodontal tissues, pain only can be provoked. Nerve fibres which are mostly medullated enter

the pulp cavity and here form a plexus from which arises a more peripherally situated plexus of finer non-medullated fibres (Schafer, 1934; Maximow & Bloom, 1938) bearing free nerve endings distributed to the pulp, dentinal tubules and odontogenic zone (Lewinsky & Stewart, 1938*a*). Free nerve terminals only have been described in the tympanic membrane (Wilson, 1911), from which pain only can be provoked (Clark, 1939). Similar nerve endings derived from fine somatic nerve fibres occur in mucous membranes (Retzius, 1908; Huber, 1900; Cajal, 1933; Kadanoff, 1927; Lewinsky & Stewart, 1938*b*, 1939; Stewart & Lewinsky, 1939), serous membranes (Dogiel, 1902; Timofeyev, 1902), intermuscular connective tissue (Hinsey, 1927, 1930), adventitia of blood vessels (Woollard, 1926; Hinsey, 1927, 1928, 1930; present writers), tendon and periosteum (Weddell & Harpman, 1940), from all of which pain can be aroused (Foerster, 1927; Capps & Coleman, 1932; Waterston, 1933*b*; Lewis, 1938; Kellgren, 1938; Lewis & Kellgren, 1939; and others). Weddell & Harpman have found in the tongue of a rabbit, on which a cervical sympathetic neurectomy had been performed, a subepithelial plexus of fine nerve fibres giving rise to free nerve endings similar to that occurring in the skin (Pl. IV, fig. 8).

Free intraepidermal nerve endings have been described in many vertebrates (Langerhans, 1868; Ranvier, 1878; Merkel, 1880; Retzius, 1892; Dogiel, 1893; v. Gehuchten, 1906; Bielschowsky, 1907; Botezat, 1908, 1912; Cajal, 1909, 1933; Ackert, 1914; Ohmori, 1923; Kadanoff, 1924, 1928, 1929-30; Ludford, 1930; Lalowy, 1935; Woollard, 1936*a*; and others). In general, they are abundant, derived from medullated and non-medullated fibres, and sometimes extend into the stratum granulosum. Intraepidermal free nerve endings extending into the stratum granulosum have been seen by the present writers in the human finger, but not in skin from the human forearm or thigh. No general agreement has been reached as to whether intraepithelial free nerve endings are intra- or extracellular in position (Boeke, 1932). In the sections examined by the present writers, however, the intraepidermal free nerve endings are extracellular in position.

In methylene-blue preparations fine nerve fibres and free nerve terminals commonly present a varicose appearance, whilst in material impregnated with silver they rarely appear varicose. Woollard & Harpman (1939) have suggested that in coelenterates the large varicosities are due to toxic effects of methylene blue upon nerve fibres. Strughold & Karbe (1925) studied the innervation of the human cornea and conjunctiva *in vivo*, by the instillation of 0.01-1 % methylene-blue solutions. They found that introduction of the dye at first caused intense pain, followed by analgesia and anaesthesia to cold; the receptors concerned with the latter sensation were more resistant to the effects of the dye. In the present experiments stimulation by needle pricks of cutaneous nerve fibres and free endings stained with methylene blue in the living rabbit caused struggling.

There has been much controversy concerning the problem of syncytial

continuity in the nervous system. Many discrepant descriptive observations have been made on the cutaneous nerve plexuses (Dogiel, 1890, 1893, 1904, 1905; Ruffini; Ohmori, 1923; Tello, 1932; Woollard, 1936*a*, 1937). The occurrence of degenerating along with normal axis cylinders within one sheath after nerve section in the ear of the rabbit suggests that the nerve plexuses in question are not a neuromyotium.

Foerster (1925, 1927) has recorded the occurrence of pain from stimulation of the distal ends of sectioned cutaneous nerves in the human subject. The pain is abolished by section of adjacent overlapping cutaneous nerves. The anatomical basis for this phenomenon is the fact that nerve fibres and endings subserving pain form closely interlocked systems.

Lewis & Pochin (1937) have confirmed and expanded observations by Rosenbach (1884), Gad & Goldscheider (1892), Thunberg (1902) and Alrutz (1909), showing that from human skin two pain sensations can be aroused by a single stimulus. On the volar aspect of the forearm or dorsum of the finger, "light pricks" arouse a second pain which is more intense, diffuse and longer lasting than the first pain, which is frequently not felt. "Heavier jabs" evoke a first pain which is more intense than the second pain. Application of a hot metal cylinder 1 cm. in diameter for $\frac{1}{4}$ – $\frac{1}{2}$ a second is accompanied by a brief pain, followed after an interval, during which the metal has been removed, by a second pain which, "if the contact has been short", exceeds the first in intensity. The type of pain provoked, therefore, depends upon the stimulus used. It is noteworthy that the "most certain method" of evoking the double pain sensation was the application of hot metal cylinders 1 cm. in diameter.

Lewis & Pochin (1937) have demonstrated that in man the interval between the two pain sensations diminishes as skin nearer the spinal cord is tested. The margin at which the two cutaneous pain sensations fuse is stated to be at an approximately constant distance from the spinal cord, if measurements be made along the corresponding nerve trunks. The present workers have found that by using fine needles inserted rapidly and deeply, two pain sensations separated by an interval can be aroused from the skin covering the extremities, face, forehead, neck, upper part of the chest and shoulders, from which regions, however, a phasic sensation can also be provoked. From the skin of the back or abdomen, phasic sensations only can be provoked. Lewis & Pochin (1937) have also recorded that although hot metal contacts evoke a single pain sensation from the face, a needle prick is "often followed by a second sensation, which comes gradually, and lasts for very many seconds. It is a little sense of continuous sting, the nature of which we have not investigated, but which is to be distinguished from the fleeting pain of a second response, as this is felt in finger or toe." The present writers are, however, unable to detect a fundamental distinction between the second pain sensation aroused from the skin of the face and that provoked from the skin of other regions of the body, thus agreeing with Lewis's later (1938) statement that cutaneous pain of only one "quality" can be provoked from the skin. The present observations

indicate that there are regional differences in the extent of skin supplied by one dorsal root ganglion cell subserving pain. This inference is supported by the fact that the number of nerve fibres supplying similar areas of skin varies in different regions of the body (Ingbert, 1903; Ranson *et al.* 1935), and the fact that section of a dorsal root may or may not produce an area of cutaneous anaesthesia according to the region from which it derives its fibres (Sherrington, 1893, 1898; Foerster, 1933, 1936). A hot metal cylinder 1 cm. in diameter applied to the skin would stimulate a different number, or a different relative distribution of components, of discrete terminal nerve plexuses subserving pain, derived from single dorsal root ganglion cells, in different regions of the body.

Lewis & Pochin (1937) state that in man the two varieties of cutaneous pain can be dissociated from each other by asphyxia or cocainization of a cutaneous nerve. The same authors later (1938) state that "in asphyxia of a limb, defects of touch, cold sense, warm sense and fast conducted pain begin almost simultaneously. The defect in slow conducted pain comes later, and is preceded by exaggerated pain response. The only sense to be lost early is touch; the rest all decline slowly, and together are eliminated within a relatively short time period of each other. The declines of fast and slow conducted pain do not occupy separate phases of asphyxia; they overlap considerably. In asphyxia of a limb, the separate sensory functions are not eliminated in a simple precise order, neither do nerve fibres fall out in the order of their conduction rates." Gasser (1935), from a review of the literature and cathode-ray oscilloscope studies, concludes that the fibres conducting different modalities of sensation are widely distributed throughout the various fibre sizes. The observation that the diameter of fibres supplying hair follicles in the skin of the ear of the rabbit is sometimes less than that of fibres from the nerve apparatus presumed to subserve pain lends support to the conclusions of Lewis & Pochin (1938) and Gasser (1935). The fact that asphyxia does not eliminate separate sensory functions "in a simple precise order", and the fact that nerve trunk asphyxiation does not cause nerve fibres to "fall out in the order of their conduction rates", suggest that nerve trunk asphyxiation might have the same effect as an alteration of the anatomical relationships between the plexiform closely interlocking nerve fibres and endings subserving pain. The present writers, therefore, are of the opinion that the findings of Lewis & Pochin may equally well be explained on a basis of regional differences in the relationships, either present anatomically or induced by asphyxia, between the plexiform interlocking fibres and endings subserving pain. The histological observations here recorded show that there are not two sharply separated groups of fibre sizes mediating two varieties of cutaneous pain, but that fibres heterogeneously distributed through a spectrum of sizes bear endings of a single morphological type.

Lewis (1936, 1937*a*) has brought forward evidence showing that cutaneous hyperalgesia, flare, whealing and antidromic dorsal root vasodilatation are

probably mediated by a single system of nerves, which he has designated "nocifensor". Lewis (1937*b*) states that asphyxia of the skin prevents the development of hyperalgesia by paralysing "nocifensor" nerves; these nerves are paralysed before the sensory nerves. Asphyxia must be carried a stage further to prevent the development of flare reaction. Cocaine introduced electrophoretically into the skin paralyses nerves subserving pain completely, and nerves subserving touch entirely or almost entirely, before it interferes with the hyperalgesia reaction. Hinsey & Gasser (1930), from studies using the cathode-ray oscilloscope, have determined that vasodilatation due to dorsal root stimulation is mediated by slowly conducting fibres. Heinbecker & Bishop (1935) state that fibres conducting pain evoked from the skin have a lower threshold and a faster conduction rate than autonomic fibres of similar morphological type and size. The present observations show that hyperalgesia occurs in skin supplied only by nerves and nerve endings subserving pain. The observations of Hinsey & Gasser, and Heinbecker & Bishop, suggest that the interpretation of the results of dissociation experiments using asphyxia or cocaine must be accepted with caution. The plexiform closely interlocked nerves and endings subserving pain are anatomically similar to the complex and branching system of axones postulated by Lewis (1936, 1937*a*) as being necessary to explain the phenomena of hyperalgesia, flare, whealing and vasodilatation. The findings with regard to hyperalgesia, and the impossibility of demonstrating histologically several systems of plexiform interlocking fibres, establish that these reactions must take place within the one demonstrable system subserving pain.

Trotter & Davies (1909) postulated a chemical factor to explain the mechanism of hyperalgesia occurring in nerve regeneration. Lewis (1933) and Lewis & Hess (1933) conclude that after-sensations of pain are dependent upon the liberation by injury of some chemical irritant to the nerves, since this after-sensation of pain may be modified by changes in the circulation. Bazett (1935) suggests that the persisting itching sensation which follows light touch, particularly in the neighbourhood of orifices (v. Frey & Rein, 1929), is due to a chemical factor. Feng (1933) has shown that the balance of excitability between receptors for touch and those for pain may be upset peripherally by the liberation by injury of simple chemical substances such as potassium. Lewis (1936) has found that extracts of human or guinea-pig skin, when injected in small quantities intradermally, after a short delay give rise to smarting which increases in intensity. The smarting is sometimes accompanied by a sensation of itching. Hyperalgesia soon develops around the site at which the juice was injected. A wheal forms at the site of injection. Lewis (1936, 1937*a*) believes that a pain-producing substance is released in the skin, either from direct injury of the skin or through the action of "nocifensor" nerves. The "nocifensor" nerves, it is suggested, cause the release of a substance from skin cells; this substance produces hyperalgesia, itching, and vasodilatation. The present writers suggest that damage to the skin injures the terminal

nerve apparatus subserving pain, and that the impulses thus set up not only pass to the central nervous system resulting in a sensation of pain, but also spread within the terminal nerve plexus derived from one dorsal root ganglion cell. The ionic shifts consequent upon the passage of impulses throughout the discrete plexuses of interlocking nerve fibres and endings subserving pain may cause either chemical changes in the immediate neighbourhood of the free nerve endings arising from the plexuses in question, or cause cells in close proximity to such endings to liberate chemical substances. Such substances, in addition to those liberated by tissue injury, may in turn cause neighbouring closely interlocked fibres to discharge in a similar manner. Limited local spread could thus take place without the necessity of invoking the presence of a neurencytium, and in addition would explain whealing, flare and hyperalgesia. Sensory pain nerves could in this manner subserve all "nocifensor" reactions as well as transmit the sensation of pain. The present observations show that in the skin there is no anatomical foundation for the usual conception with regard to "axone reflexes".

The evidence presented in the present paper, like most modern investigations (Lanier, 1935), offers no support for Head's (1920) theory of protopathic and epicritic systems of fibres in cutaneous nerves.

CONCLUSIONS

1. Pressure, warmth, touch, cold and pain are represented in the skin in punctate form. The theory of punctate sensibility must be interpreted from a three-dimensional point of view. Multiple spots from which one of the primary modalities of sensation can be aroused occur within the area of skin supplied by a single specific sensory neurone.
2. Cutaneous pain is subserved only by the finer medullated and non-medullated nerve fibres bearing free endings. These fibres and endings are specific and arranged in a plexiform interlocking manner.
3. Non-medullated nerve fibres derived from different neurones often lie within the same neurilemma sheath.
4. There are regional differences in the disposition of, and in the area supplied by, the terminal nerve plexus and endings derived from a single dorsal root ganglion cell subserving pain.
5. Pain can be aroused from the deeper layers of the epidermis and the superficial layers of the dermis.
6. Several varieties of cutaneous pain can be aroused by a single stimulus, depending upon the nature of the stimulus and the region of the body stimulated.
7. All varieties of cutaneous pain are subserved by the same nerve apparatus.
8. The "accessory" innervation to encapsulated touch receptors and to nerve endings subserving pressure, cold, and proprioception from tendon, is morphologically similar to nerve fibres and endings subserving pain.
9. Fine somatic nerve fibres bearing free nerve endings similar to those subserving pain in the skin occur in the adventitia of blood vessels.

10. No nerve apparatus other than that subserving pain is involved in the production of hyperalgesia. "Nocifensor" reactions are mediated by the nerve apparatus subserving pain.

11. There is no anatomical foundation for the usual conception with regard to "axone reflexes".

12. The facts presented establish that cutaneous pain behaves in accordance with the doctrine of specific nervous activity.

The writers are indebted to Dr L. Young, of the Department of Biochemistry, University College, London, for suggestions with regard to, and standardization of, the staining technique employed in the experiments on the ear of the rabbit; also for the preparation of the solutions of dye used. The writers are also indebted to Miss Z. M. Stead for her valuable help with the physiological and histological experiments, for the drawings and for the photomicrographs reproduced in Text-fig. 6, Pl. II, figs. 3, 4 and Pl. IV, figs. 7, 8. Thanks are due to Mr F. J. Pittock for the remainder of the photomicrographs.

Dr E. A. Carmichael kindly allowed the writers to examine cases at the National Hospital for Diseases of the Nervous System, London.

REFERENCES

- ACKERT, L. E. (1914). *J. Morph.* **25**, 301.
ADRIAN, E. D. (1926). *J. Physiol.* **62**, 33.
— (1932). *The Mechanism of Nervous Action*. Philadelphia.
AGABOW, G. (1912). *v. Graefes Arch. Ophthal.* **83**, 317.
ALBUTZ, S. (1909). *Skand. Arch. Physiol.* **21**, 237.
ATTIAS, G. (1912). *v. Graefes Arch. Ophthal.* **83**, 207.
BAZETT, H. C. (1935). *Proc. Ass. Res. Nerv. Ment. Dis.* **15**, 83.
BIELSCHOWSKY, M. (1907). *Anat. Anz.* **31**, 187.
BLIX, M. (1884). *Z. Biol.* **20**, 141.
— (1885). *Z. Biol.* **21**, 145.
BOEKE, J. (1932). *Cytology and Cellular Pathology of the Nervous System*, ed. by W. Penfield, **1**, 241. New York.
BOTEZAT, E. (1908). *Anat. Anz.* **33**, 45.
— (1912). *Anat. Anz.* **42**, 193, 273.
BURNETT, N. C. & DALLENBACH, K. M. (1927). *Amer. J. Psychol.* **38**, 418.
CAJAL, S. R. Y. (1909). *Histologie du système nerveux de l'homme et des vertébrés*, **1**. Paris.
— (1933). *Histology*. London.
CAPPS, J. A. & COLEMAN, G. H. (1932). *An Experimental and Clinical Study of Pain in the Pleura, Pericardium and Peritoneum*. New York.
CARMICHAEL, E. A. & WOOLLARD, H. H. (1933). *Brain*, **56**, 109.
CATTELL, MCK. & HOAGLAND, H. (1931). *J. Physiol.* **72**, 392.
CLARK, D., HUGHES, J. & GASSER, H. S. (1935). *Amer. J. Physiol.* **114**, 69.
CLARK, E. R., CLARK, E. L. & WILLIAMS, R. G. (1934). *Amer. J. Anat.* **55**.
CLARK, W. E. LE GROS (1939). *The Tissues of the Body*, p. 287. Oxford Univ. Press.
DALLENBACH, K. M. (1927). *Amer. J. Psychol.* **39**, 402.
DOGIEL, A. (1890). *Anat. Anz.* **5**, 483.
— (1892). *Int. Mschr. Anat. Physiol.* **9**, 76.
— (1893). *Arch. mikr. Anat.* **41**, 585.

- DOGIEL, A. (1902). *Arch. mikr. Anat.* **59**, 1.
 — (1904). *Anat. Anz.* **25**, 558.
 — (1905). *Anat. Anz.* **27**, 97.
 DONALDSON, H. H. (1885). *Mind*, **10**, 399.
 DUNCAN, D. (1934). *J. comp. Neurol.* **60**, 437.
 FENG, T. P. (1933). *J. Physiol.* **79**, 103.
 FOERSTER, O. (1925). *Rossolimo'sche Festschrift*, p. 145. Berlin.
 — (1927). *Die Leitungsbahnen des Schmerzgefuehls und die chirurgische Behandlung der Schmerz-zustände*. Berlin and Vienna.
 — (1933). *Brain*, **56**, 1.
 — (1936). *Handbuch der Neurologie*, by O. Bumke and O. Foerster. 2nd ed. **6**, 1. Berlin.
 FREY, M. v. (1894). *Ber. sächs. Ges. Akad. Wiss.* pp. 184, 283.
 — (1895). *Ber. sächs. Ges. Akad. Wiss.* p. 166.
 — (1896). *Ber. sächs. Ges. Akad. Wiss.* p. 175.
 — (1897). *Ber. sächs. Ges. Akad. Wiss.* p. 462.
 — (1899). *S.B. phys.-med. Ges. Warburg*.
 — (1926). *Handb. norm. path. Physiol.*, ed. by A. Bethe, **11**, 94. Berlin.
 FREY, M. v. & REIN, H. (1929). *Handbuch der Haut und Geschlechtskrankheiten*, 1–2, 1.
 GAD & GOLDSCHIEDER, A. (1892). Quoted by T. Lewis & E. E. Pochin (1937).
 GASSER, H. S. (1935). *Proc. Ass. Res. Nerv. Ment. Dis.* **15**, 35.
 GASSER, H. S. & ERLANGER, J. (1929). *Amer. J. Physiol.* **88**, 581.
 GEHUCHTEN, A. v. (1906). *Anatomie du système nerveux*. Louvain.
 GOLDSCHIEDER, A. (1886). *Arch. Anat. Physiol.* supplement. vol.
 — (1898). *Gesammelte Abhandlungen*, 1. Leipzig.
 — (1926). *Handb. norm. path. Physiol.*, ed. by A. Bethe, **11**, 131. Berlin.
 HAGGQVIST, V. G. (1914). *Anat. Anz.* **45**, 46.
 HEAD, H. (1920). *Studies in Neurology*. Oxford Univ. Press.
 HEINBECKER, P. & BISHOP, G. H. (1935). *Proc. Assoc. Res. Nerv. Ment. Dis.* **15**, 226.
 HEINBECKER, P., BISHOP, G. H. & O'LEARY, J. (1934). *Arch. Neurol. Psychol., Chicago*, **31**, 34.
 HINSEY, J. C. (1927). *J. comp. Neurol.* **44**, 87.
 — (1928). *J. comp. Neurol.* **47**, 23.
 — (1930). *Proc. Ass. Res. Nerv. Ment. Dis.* **9**, 153.
 HINSEY, J. C. & GASSER, H. S. (1930). *Amer. J. Physiol.* **92**, 679.
 HUBER, G. C. (1900). *J. comp. Neurol.* **10**, 135.
 INGBERT, C. E. (1903). *J. comp. Neurol.* **13**, 53, 209.
 KADANOFF, D. (1924). *Z. ges. Anat. 1. Z. Anat. EntwGesch.* **73**, 431.
 — (1927). *Z. Zellforsch.* **5**, 615.
 — (1928). *Z. Zellforsch.* **7**, 553.
 — (1929–30). *Z. Zellforsch.* **10**, 427.
 KELLGREN, J. H. (1938). *Clin. Sci.* **3**, 175.
 LALOWY, B. (1935). *Z. Zellforsch.* **23**, 85.
 LANGERHANS, P. (1868). *Virchows Arch.* **44**, 325.
 LANIER, L. H. (1935). *Proc. Ass. Res. Nerv. Ment. Dis.* **15**, 437.
 LAVRENKO, V. V. (1938). *Bull. biol. med. exp.* **5**.
 LEWINSKY, W. & STEWART, D. (1938a). *Brit. Dent. J.* p. 1.
 — (1938b). *J. Anat., Lond.*, **72**, 531.
 — (1939). *J. Anat., Lond.*, **74**, 53.
 LEWIS, T. (1933). *Clin. Sci.* **1**, 175.
 — (1936). *Clin. Sci.* **2**, 373.
 — (1937a). *Brit. med. J.* **1**, 431.
 — (1937b). *Clin. Sci.* **3**, 59.
 — (1938). *Brit. med. J.* **1**, 321.
 LEWIS, T. & HESS, W. (1933). *Clin. Sci.* **1**, 39.
 LEWIS, T. & KELLGREN, J. H. (1939). *Clin. Sci.* **4**, 47.
 LEWIS, T. & POCHIN, E. E. (1937). *Clin. Sci.* **3**, 67.
 — (1938). *Clin. Sci.* **3**, 141.

- LUDFORD, R. J. (1930). *Imp. Cancer Res. Fund Rep.* **9**, 99.
- MARX, E. (1921). *Extrait des annales d'occulistique*, 158.
- MAXIMOW, A. A. & BLOOM, W. (1938). *Textbook of Histology*, 3rd ed. p. 373. Philadelphia and London.
- MERKEL, F. (1880). *Ueber die Endigungen der sensiblen Nerven der Haut*. Rostock.
- MICHAŁOW, S. (1908). *Arch. mikr. Anat.* **71**, 254.
- NAGEL (1895). *Pflug. Arch. ges. Physiol.* **59**, 563.
- NAGEOTTE, J. (1932). *Cytology and Cellular Pathology of the Nervous System*, ed. by W. Penfield, **1**, 189. New York.
- OHMORI, D. (1923). *Z. ges. Anat. 1. Z. Anat. EntwGesch.* **70**, 346.
- PENDLETON, C. R. (1928). *Amer. J. Psychol.* **40**, 353.
- PRITCHARD, E. A. B. (1931). *Brain*, **54**, 350.
- RANSON, S. W. (1913). *J. comp. Neurol.* **23**, 259.
- (1914). *J. comp. Neurol.* **24**, 531.
- (1931). *Arch. Neurol. Psychiat., Chicago*, **26**, 1122.
- RANSON, S. W. & BILLINGSLEY, P. R. (1916). *Amer. J. Physiol.* **40**, 571.
- RANSON, S. W., DROEGEMUELLER, W. H., DAVENPORT, H. K. & FISHER, C. (1935). *Proc. Ass. Res. Nerv. Ment. Dis.* **15**, 3.
- RANVIER, M. L. (1878). *Leçons sur l'histologie du système nerveux*. 2 vols. Paris.
- RETZIUS, G. (1892). *Biol. Untersuch.* N.F. **3**, 37.
- (1908). *Proc. roy. Soc. B*, **80**, 414.
- RIVERS, W. H. R. & HEAD, H. (1908). *Brain*, **31**, 323.
- ROSENBAUGH (1884). Quoted by T. Lewis & E. E. Pochin (1937).
- RUFFINI, A. (1902). *Bibliogr. anat.* **11**, 267.
- SALA, G. (1899). *Anat. Anz.* **16**, 193.
- SCHAFFER, E. A. SHARPEY- (1934). *Essentials of Histology*, 13th ed. p. 333.
- SFAMENI, P. (1901). *Arch. ital. biol.* **35**, 198.
- SHEBBINGTON, C. S. (1893). *Philos. Trans. B*, **184**, 641.
- (1898). *Philos. Trans. B*, **190**, 45.
- (1900). *Text-book of Physiology*, ed. by E. Sharpey-Schafer, **2**, 949, 961.
- SOKOLOW, A. (1899). *Anat. Anz.* **16**, 421.
- SOMMER (1900). *S.B. phys.-med. Ges. Würzburg*, **63**.
- STEWART, D. & LEWINSKY, W. (1939). *Proc. roy. Soc. Med.* **32**, 1054.
- STRUGHOLD, H. (1923). *Z. Biol.* **21**, 154.
- STRUGHOLD, H. & KARBE, M. (1925). *Z. Biol.* **83**, 189, 201, 207, 297.
- TELLO, J. F. (1932). *Trav. Lab. Invest. biol. Univ. Madr.* **28**, 1.
- THOMPSON, I. M. & INMAN, V. T. (1928). Cited by I. M. Thompson (1935), *Proc. Ass. Res. Nerv. Ment. Dis.* **15**, 98.
- THUNBERG, T. (1902). *Skand. Arch. Physiol.* **12**, 394.
- TIMOFEEV, T. (1895). *Anat. Anz.* **11**, 44.
- (1902). *Arch. mikr. Anat.* **59**, 629.
- TOWER, S. S. (1935). *Proc. Ass. Res. Nerv. Ment. Dis.* **15**, 167.
- TROTTER, W. & DAVIES, H. M. (1909). *J. Physiol.* **38**, 134.
- WATERSTON, D. (1923). *Brain*, **47**, 200.
- (1933a). *J. Physiol.* **77**, 251.
- (1933b). *Lancet*, **1**, p. 943.
- WEDDELL, G. & HARPMAN, J. A. (1940). To be published.
- WEDDELL, G., HARPMAN, J. A., LAMBLEY, D. G. & YOUNG, L. (1940). *J. Anat., Lond.*, **74**, 255.
- WILLIAMS, R. G. (1935). Quoted by H. C. Bazett (1935).
- WILSON, J. G. (1911). *Amer. J. Anat.* **11**, 101.
- WOOLLARD, H. H. (1926). *Heart*, **13**, 319.
- (1935). *Brain*, **58**, 352.
- (1936a). *J. Anat., Lond.*, **71**, 54.
- (1936b). *Brit. med. J.* **2**, 861.
- (1937). *J. Anat., Lond.*, **71**, 480.
- WOOLLARD, H. H. & HARPMAN, J. A. (1939). *J. Anat., Lond.*, **73**, 559.

EXPLANATION OF PLATES I-IV

All figures are photomicrographs of methylene-blue preparations

PLATE I

- Fig. 1. Deep and superficial cutaneous nerve plexuses in the ear of a rabbit. A cervical sympathetic neurectomy had been performed 74 days previously. $\times 80$.
- Fig. 2. Fine non-medullated nerve fibres and free nerve endings in the adventitia of an artery in the ear of a rabbit. A cervical sympathetic neurectomy had been performed 74 days previously. Nuclei of neurilemma sheath cells surrounding non-medullated nerve fibres are stained. $\times 260$.

PLATE II

- Fig. 3. The innervation of a hair follicle in the ear of a rabbit. $\times 600$.
- Fig. 4. A fine medullated nerve fibre giving rise to free nerve endings in the adventitia of an artery in the ear of a rabbit. A cervical sympathetic neurectomy had been performed 21 days previously. $\times 320$.
- Fig. 5. Free nerve endings arising from a fine medullated nerve fibre in the skin of the ear of a rabbit. A cervical sympathetic neurectomy had been performed 74 days previously. The neurilemma sheath cells are darkly stained. $\times 260$.

PLATE III

- Fig. 6. A cutaneous nerve fibre, bearing free nerve endings, overlapping towards a denervated area in the ear of the rabbit. Preparation made 3 days after nerve section. $\times 500$.

PLATE IV

- Fig. 7. The subepidermal nerve plexus subserving pain in the human forearm. $\times 370$.
- Fig. 8. A plexus of fine nerve fibres, giving rise to free nerve endings, immediately subjacent to the mucous membrane of the tongue of a rabbit. A cervical sympathetic neurectomy had been performed 74 days previously. $\times 320$.

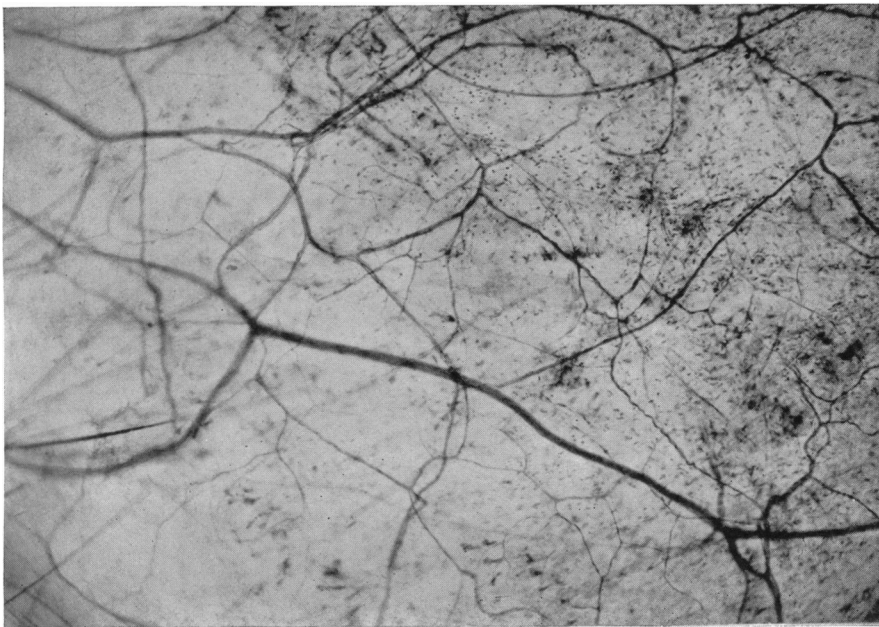


Fig. 1.

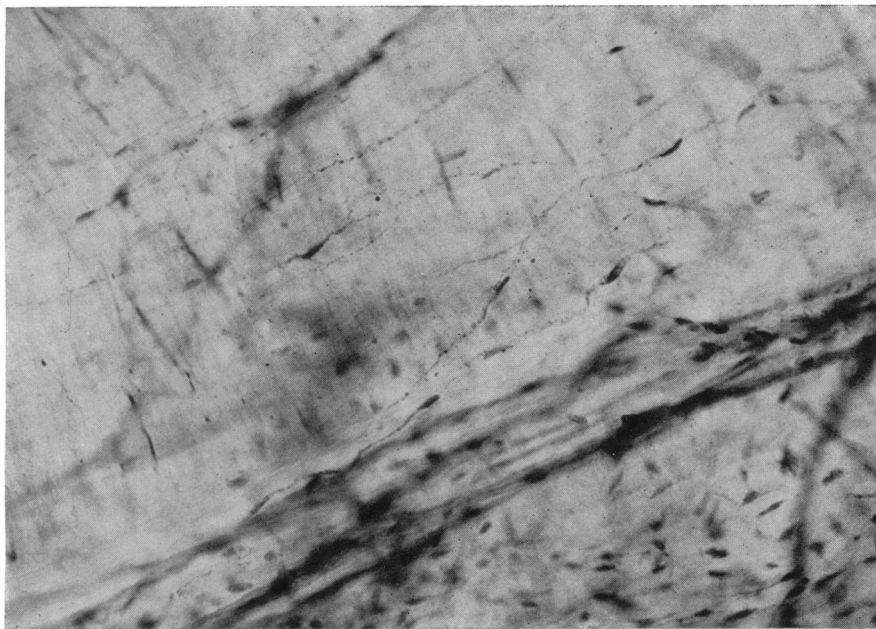


Fig. 2.

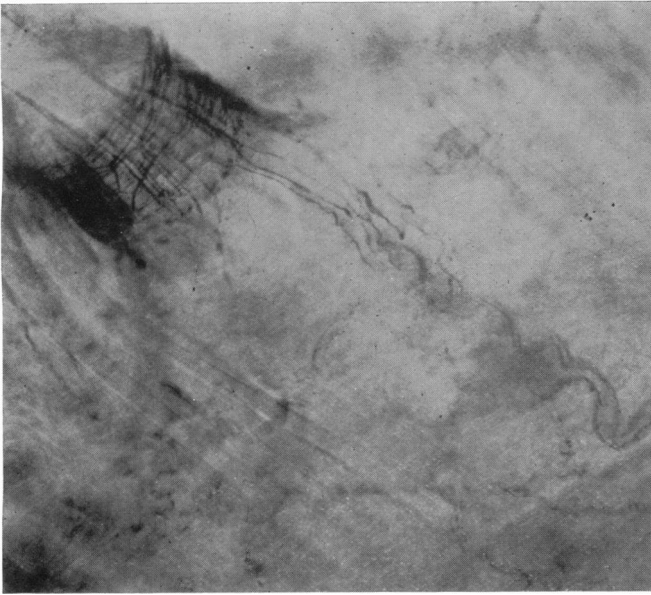


Fig. 3.

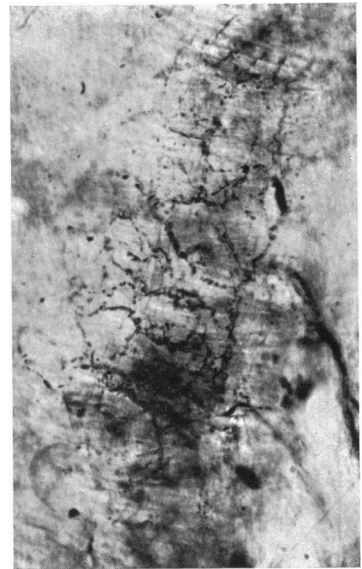


Fig. 4.

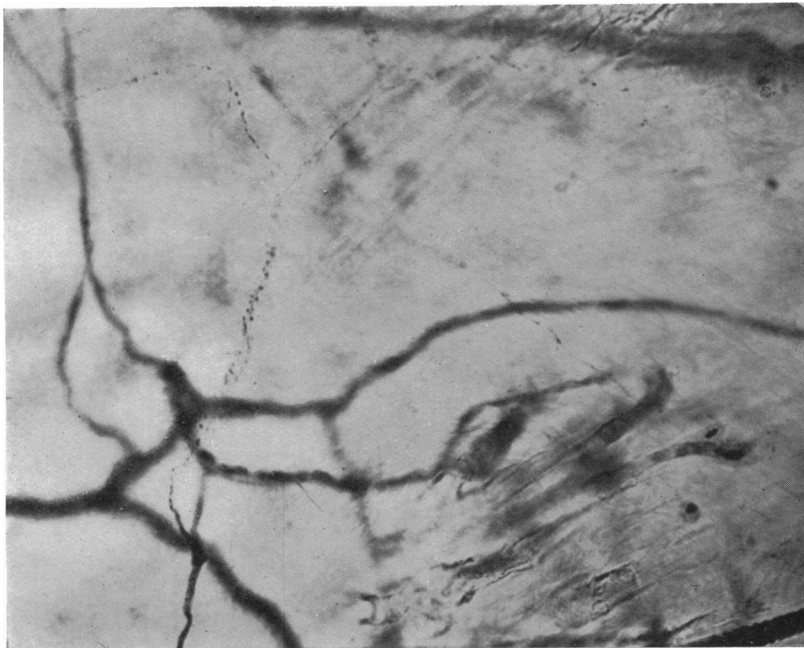


Fig. 5.




Fig. 6.

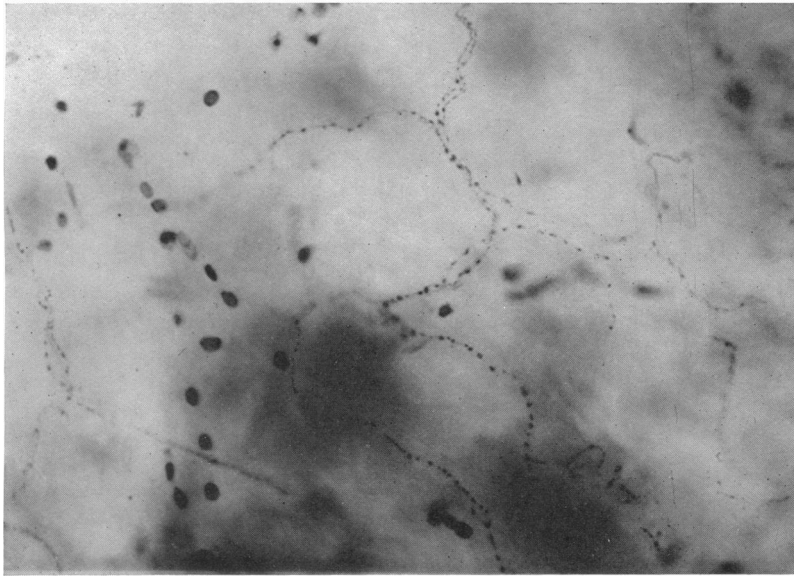


Fig. 7.

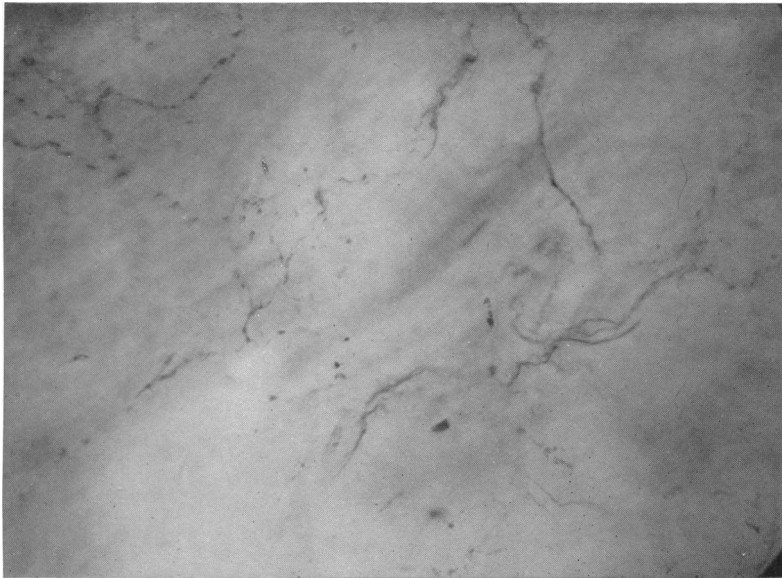


Fig. 8.