

Cell proliferation in palatal processes and Meckel's cartilage during development of the secondary palate in the mouse

D. A. LUKE

*Unit of Anatomy in relation to Dentistry, United Medical and Dental Schools
(Guy's Campus), London SE1 9RT*

(Accepted 8 November 1988)

INTRODUCTION

The development of the mammalian secondary palate occurs at a time of rapid cell proliferation in the embryo. Using a stathmokinetic technique (Luke, 1984) it has been shown that prior to shelf elevation mitotic activity is greater in the epithelium of the lateral surface of the palatal process than in that of the medial (future nasal) surface, especially at sites of developing rugae, and this differential growth has been causally linked with shelf reorientation (Bulleit & Zimmerman, 1985). Several investigators have used autoradiography to assess proliferation in epithelium and mesenchyme of palatal processes (Hudson & Shapiro, 1973; Brinkley, 1984, 1986) but have ignored the regional variations that are likely to be associated with rugal morphogenesis.

The present study has utilised ^3H -thymidine and autoradiography to investigate further epithelial and mesenchymal proliferation in palatal processes of mice during the critical period of their elevation, comparing rugal and inter-rugal areas. The opportunity has also been taken to examine the growth of Meckel's cartilage following a study by Diewert (1980) of this structure in the rat.

MATERIALS AND METHODS

Pregnant mice of strain CD1 were used and the day following mating was regarded as Day 0 of gestation. At 10.00 a.m. on Days 13 and 15 and at 8.00 p.m. on Days 12, 13 and 14, ^3H -thymidine, specific activity 5 Ci per mmol was administered by intraperitoneal injection in a dose of $1.5 \mu\text{Ci}$ per gram body weight to three animals at each age. Adults were killed one hour later by cervical dislocation under ether anaesthesia, fetuses were removed, decapitated and the heads fixed in Carnoy's fluid for 3–5 days. Six average-sized fetuses, two from each pregnancy, were selected at each age. Following routine processing for histology, heads were serially sectioned in the coronal plane at $7 \mu\text{m}$ and sections were coated with Ilford K2 nuclear emulsion diluted with an equal volume of water according to the technique of Rogers (1979). Slides were stored at 4°C for 3 weeks, developed in Kodak D19 for 4 minutes and stained with Harris' haematoxylin.

Slides were examined using a $\times 40$ objective and $\times 8$ eyepiece incorporating a graticule scale and counts were made of labelled nuclei, defined as those overlaid by 5 or more silver grains, in the regions shown in Figure 1. In the palatal process labelled nuclei were counted per 0.175 mm of lateral (1) and medial (2) epithelium; the percentage of labelled nuclei was assessed in the mesenchyme of the lateral (3) and medial (4) halves. The percentage of labelled nuclei in Meckel's cartilage (5) and the total of such nuclei judged to be within its perichondrium (6) were also estimated. The

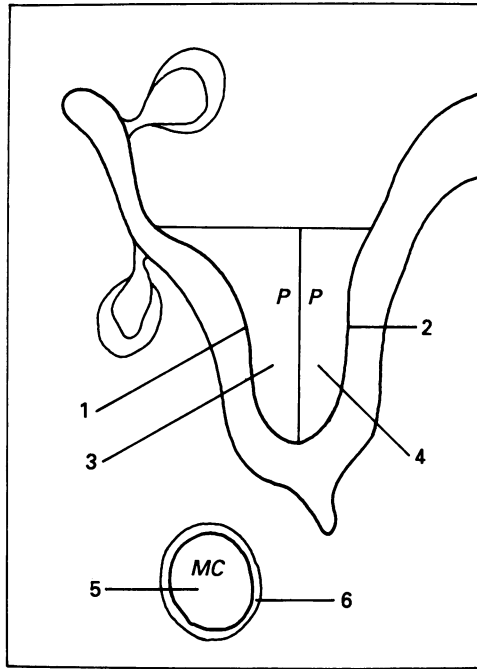


Fig. 1. Diagram of coronal section through palatal process (*PP*) and Meckel's cartilage (*MC*) of mouse. Numbered regions in which labelled nuclei were counted are referred to in the text.

diameter of the cartilage was calculated as the mean of its maximum and minimum diameters, in this case excluding the perichondrium. The above counts and measurements were made on sections from the mid-anteroposterior region of the developing secondary palate, involving the third and fourth rugae from the front and the adjacent and intervening inter-rugal zones. The fourth ruga from the anterior extremity of the palate is the first in the intermolar region so that the area investigated was limited to the antemolar/molar junction. This was chosen because at the start of the study (12.5 days) rugae posterior to the first four are just beginning to develop and are difficult to detect (Luke, 1984). For each embryo, mean estimates of the above data were derived from 10 sections through rugal and 10 through inter-rugal regions.

RESULTS

The autoradiographs revealed generally high cell proliferation in palatal processes (Fig. 2) and Meckel's cartilage (Fig. 3) especially during the early stages of the period under investigation. Estimated per unit length of surface, epithelial proliferation was greater on the lateral than the medial aspect of the palatal process, this difference being accentuated at rugal sites (Fig. 4). Where rugae were developing, differences between lateral and medial epithelia were greatest at 13 and 13.5 days of gestation but were statistically significant at all ages: at 12, 13, 13.5 days $P < 0.001$; at 14.5 and 15 days $P < 0.01$. At 13.5 days, just prior to shelf elevation, proliferation of medial epithelium declined to a minimum (Fig. 8).

At inter-rugal sites, greater proliferation was found on lateral compared with medial epithelium until 15 days when opposite sides of the now elevated processes showed similar activity (Fig. 5). Statistically significant differences were detected at 12 and 12.5 days ($P < 0.01$), at 14.5 days ($P < 0.05$) and 13.5 days ($P < 0.001$). Just as in rugal sites,

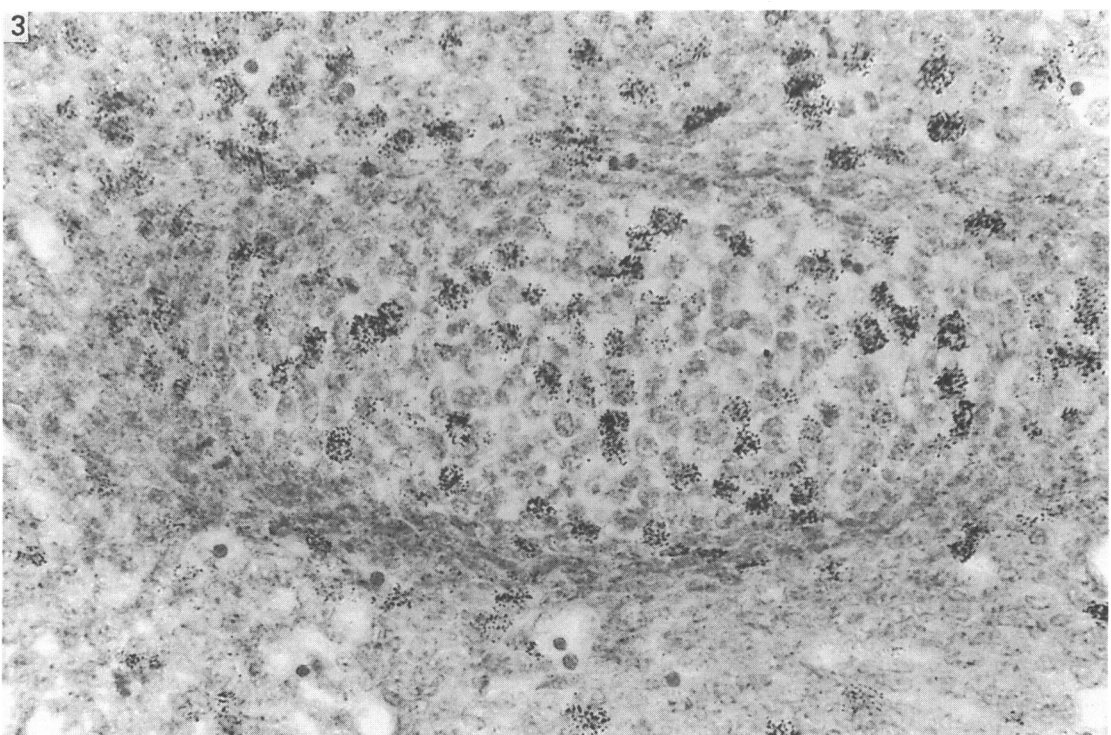
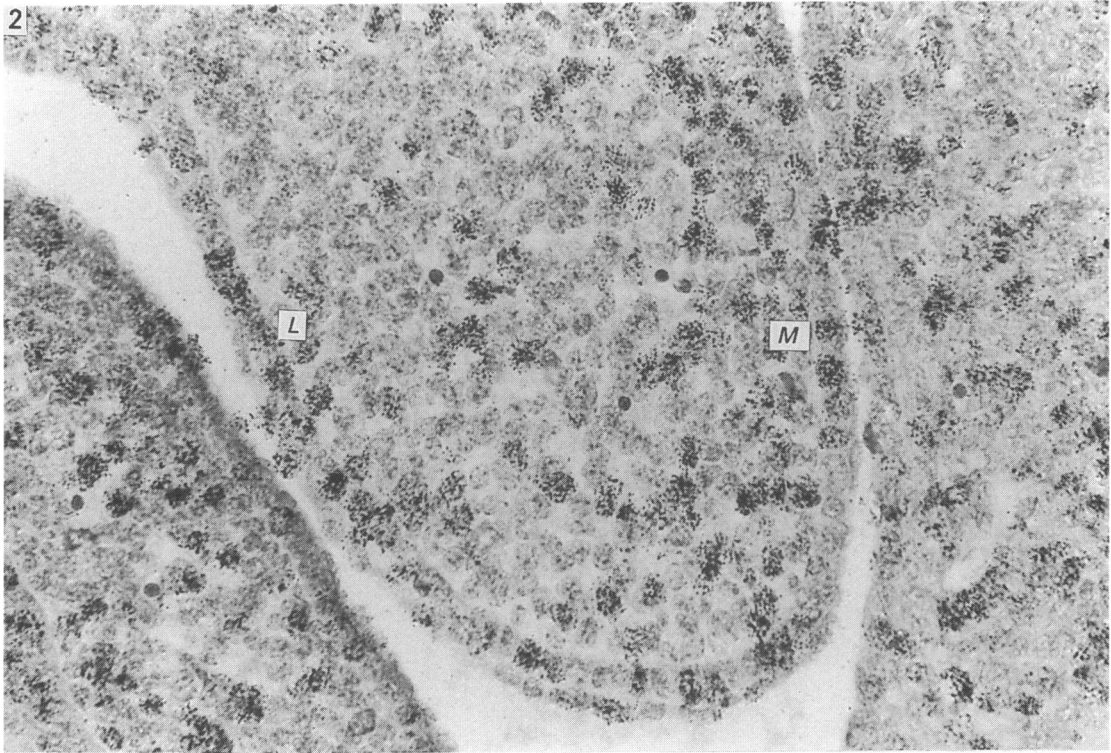


Fig. 2. Coronal section through inter-rugal region of palatal process at 13 days postconception. *L*, lateral; *M*, medial. Autoradiograph; haematoxylin. $\times 600$.

Fig. 3. Coronal section of Meckel's cartilage at 12.5 days postconception. Autoradiograph; haematoxylin. $\times 600$.

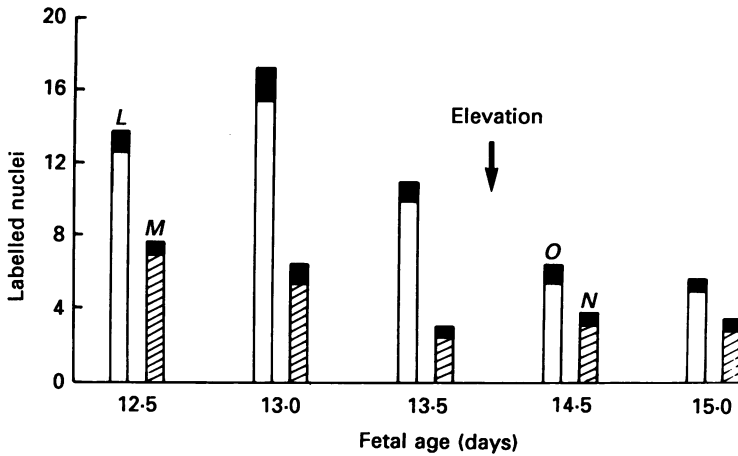


Fig. 4. Labelled nuclei per 0.175 mm of surface in lateral (*L*) and medial (*M*) epithelia of palatal process and, following elevation, in oral (*O*) and nasal (*N*) epithelia. Results from sections through rugae. Solid areas within bars in this and subsequent graphs indicate one standard deviation ($n = 6$).

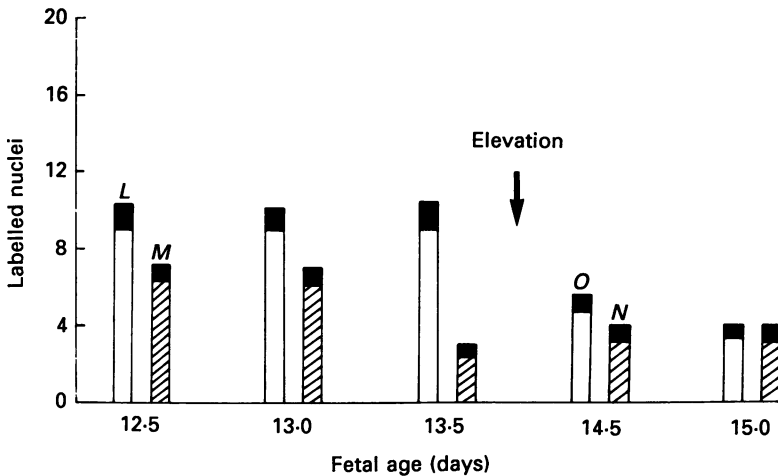


Fig. 5. Labelled nuclei per 0.175 mm epithelium of lateral (*L*), medial (*M*), oral (*O*) and nasal (*N*) surfaces of palatal process. Results from inter-rugal regions.

epithelial proliferation on the medial aspect of processes in inter-rugal areas declined to a minimum at 13.5 days.

Comparing results shown in Figures 4 and 5, on the lateral surface epithelial proliferation was consistently greater at rugal than inter-rugal regions, particularly at 12.5 and 13 days when the differences were statistically significant ($P < 0.01$ and 0.001 respectively).

No difference in the percentage of labelled nuclei was found when medial or lateral halves of the connective tissue in rugal areas were compared with the equivalent half in inter-rugal sites. Results of mesenchymal labelling from rugal and inter-rugal areas were therefore aggregated and the results are presented in Figure 6. There was a slight decline in the percentage of labelled mesenchymal nuclei between 13 and 15 days but no statistically significant difference was recorded between lateral and medial halves.

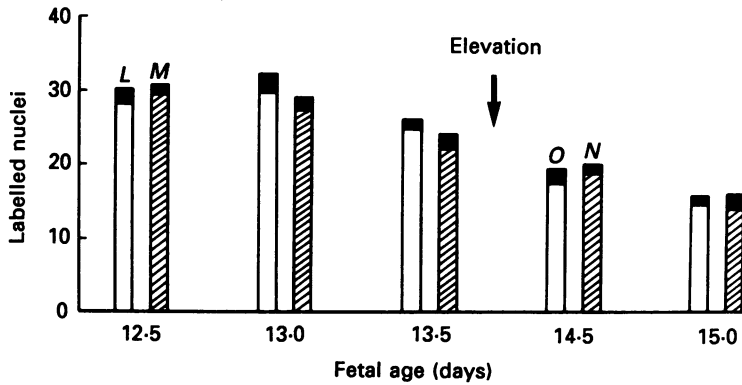


Fig. 6. Percentage labelled nuclei in mesenchyme of lateral (*L*), medial (*M*), oral (*O*) and nasal (*N*) halves of palatal process. Mean results from rugal and inter-rugal regions.

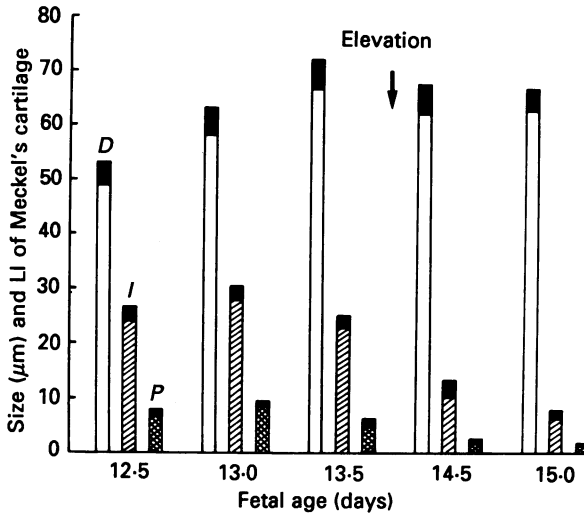


Fig. 7. Mean diameter (*D*), percentage of labelled nuclei within Meckel's cartilage (*I*) and total labelled nuclei per section within its perichondrium (*P*). LI = labelling index.

The diameter of Meckel's cartilage increased until 13.5 days and changed little thereafter (Fig. 7). Likewise, the percentage of labelled nuclei within the cartilage (Fig. 9) rose to a maximum of about 30% at 13 days while the total number of labelled cells in the perichondrium of the cartilage remained low throughout the experimental period and declined between 13 and 15 days.

DISCUSSION

The present study differs from earlier ones (Hudson & Shapiro, 1973; Nanda & Romeo, 1975) in two main respects: (i) estimating epithelial proliferation per unit length of surface rather than as a proportion of epithelial cells; (ii) attempting to compare proliferation at rugal with that at inter-rugal sites. Thus although Hudson & Shapiro found that proliferation declined in epithelial cells at the tip (edge) of the vertical process just prior to elevation, they did not remark on the different proliferative activity of opposite sides of the process. Since the epithelium is generally

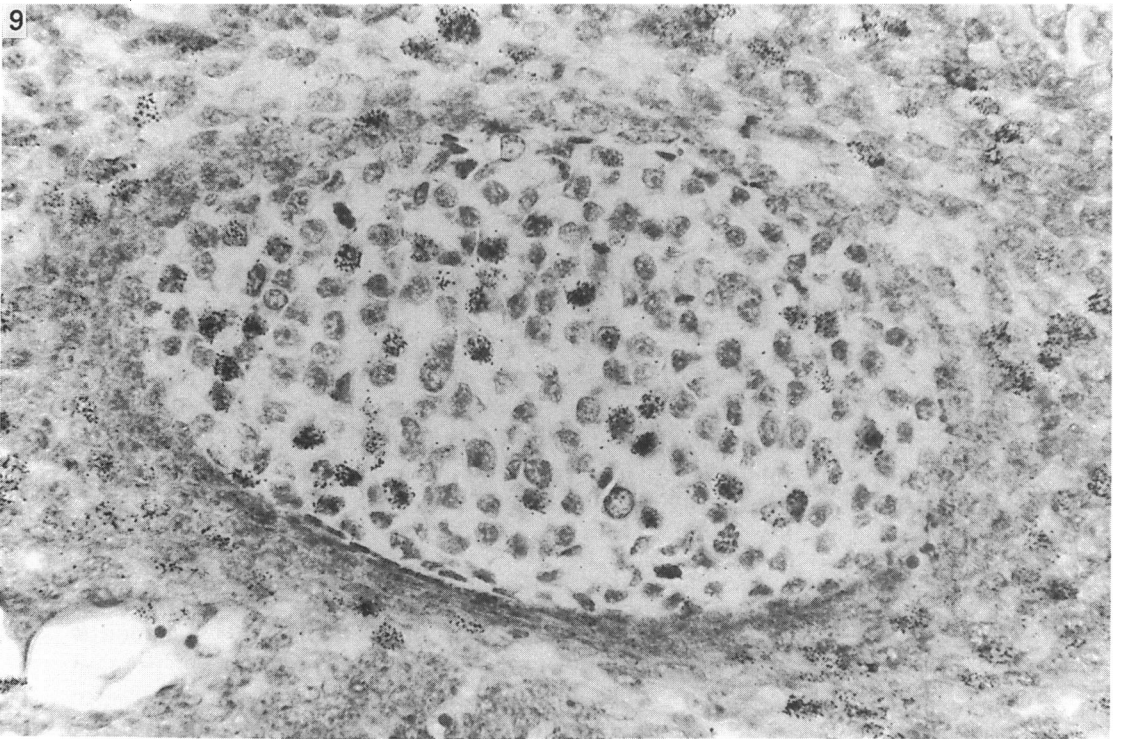
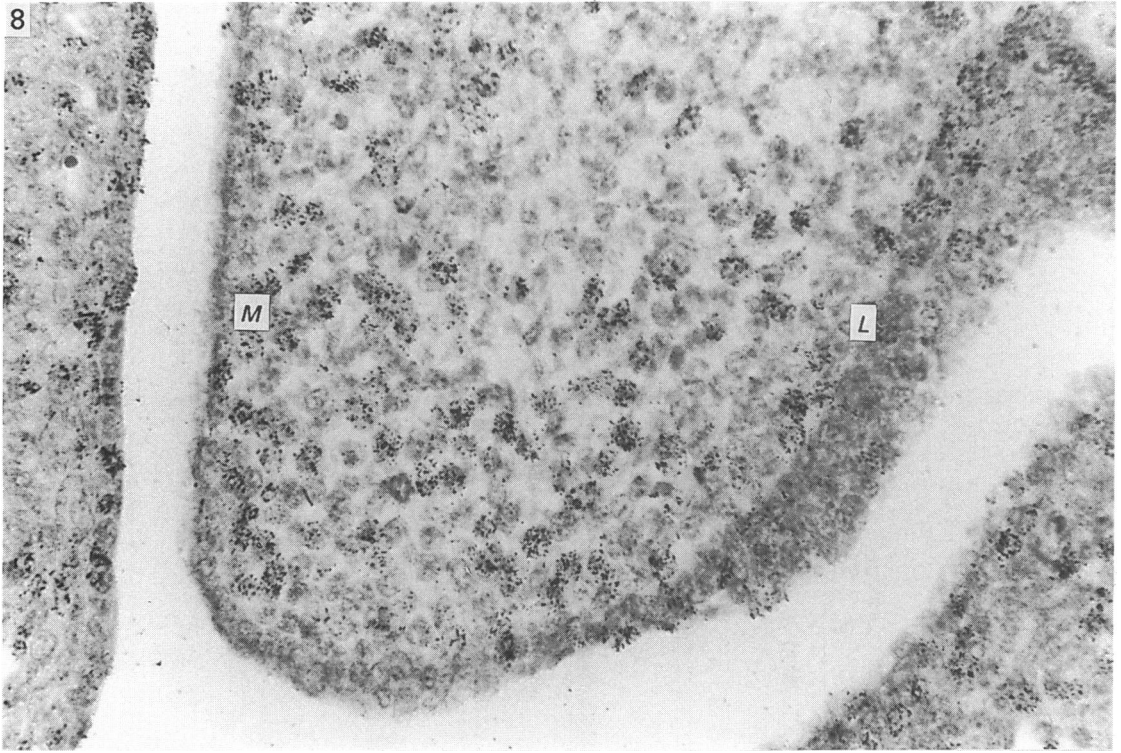


Fig. 8. Coronal section through palatal process with developing ruga at 13.5 days. *L*, lateral; *M*, medial. Autoradiograph; haematoxylin. $\times 600$.

Fig. 9. Coronal section through Meckel's cartilage at 14.5 days postconception. Autoradiograph; haematoxylin. $\times 600$.

thicker on the lateral compared with the medial surface (Luke, 1984), a feature which is accentuated where rugae form, and division occurs in suprabasal as well as basal cells, an index based on a fraction of labelled cells will differ from one based on unit length. It is suggested that the latter is more useful when assessing the growth of a tissue with respect to its size. When estimated per unit length of surface, more epithelial proliferation occurs on the lateral than on the medial surface at rugal and at inter-rugal positions, although the difference is greater where rugae develop.

The differential cell proliferation on opposite sides of the palatal process and the development of rugae with which it is partly associated, have been causally linked with the intrinsic shelf force (Pourtois, 1972; Luke, 1984) and there is some experimental evidence indicating that the presence of the lateral surface epithelium is particularly crucial for normal palate development (Bulleit & Zimmerman, 1985). However, a feature of perhaps greater significance is the marked decline in epithelial proliferation along the medial surface of the process, a feature associated with an apparent thinning of this epithelium consistent with its being stretched as growth proceeds in the enclosed mesenchyme. That the lateral, medial and edge epithelia pursue individual pathways of differentiation is a well-substantiated phenomenon of palate formation (Ferguson, 1984). In particular, changes have been described in the epithelium of the free edges of processes preparatory to their fusion (Waterman & Meller, 1974). Proliferation at the edge was not specifically examined in the present study partly because its surface is small and curved and also because the epithelium at the edge after elevation is not the same epithelium that was there before elevation. Throughout most of the anteroposterior extent of the secondary palate, elevation is accompanied by remodelling of the process, medial surface epithelium being incorporated into the tip (Yasuda & Fugimoto, 1986). This idea was confirmed in the present study by observation of serial coronal sections: the point of transition between the highly proliferative lateral epithelium and the slowly growing medial epithelium was situated within the tip, the lateral part of the tip epithelium usually containing many labelled cells.

Mesenchymal proliferation reached a peak just before elevation and then gradually declined but no differences were detected in the proportion of labelled cells in lateral and medial halves of the process. A similar observation was made in the rat fetus by Cleaton-Jones (1976) and is perhaps surprising since the development of rugae is associated with a conspicuous mesenchymal condensation adjacent to the epithelium. It therefore seems likely that this accumulation of mesenchyme is achieved by lack of migration from rugal sites rather than by a localised increase in cell division.

Most of the growth of Meckel's cartilage is apparently achieved by interstitial rather than appositional growth, although it was difficult to locate precisely the border of the perichondrium especially in early stages. The cartilage reached its maximum diameter shortly before shelf elevation and afterwards its growth substantially declined, a pattern similar to that found by Diewert in the rat. This pattern has been related to the growth spurt of the lower jaw which thereby draws the tongue, through its muscular attachments to the cartilage, downwards and forwards thus creating space for the shelves to elevate (Diewert, 1980, 1981).

Meckel's cartilage therefore makes an important contribution to the extrinsic factors responsible for shelf elevation and a hypothesis can also be suggested to explain the source of the intrinsic force: three factors are required: (i) increase in size of the palatal process by mesenchymal proliferation and glycosaminoglycan synthesis (Ferguson, 1978); (ii) growth of the lateral epithelium, partly associated with the early stages of rugal development; (iii) a marked reduction in proliferation of the medial

epithelium which in conjunction with (i) becomes stretched thereby encouraging the process to remodel and reorientate.

SUMMARY

Autoradiography and ^3H -thymidine labelling were used to study cell proliferation in the palatal process and Meckel's cartilage of mice during formation of the secondary palate. Epithelial proliferation was greater on the lateral (future oral) than on the medial (future nasal) surface, especially at sites of developing rugae. Just prior to shelf elevation, proliferation in medial surface epithelium markedly declined. Mesenchymal proliferation in the lateral half of the palatal process was the same as that in the medial half. The growth of Meckel's cartilage was most rapid just prior to shelf elevation. It is concluded that differences in proliferative activity on opposite sides of the palatal process are partly but not entirely related to the development of rugae and that the sharp fall in growth of the medial surface epithelium may play a role in elevation.

The author gratefully acknowledges the assistance of Mr S. Kariyawasam and Mr J. Carlile in producing histological preparations and of Mr K. Fitzpatrick for the illustrations.

REFERENCES

- BRINKLEY, L. L. (1984). Changes in cell distribution during mouse secondary palate closure *in vivo* and *in vitro*. *Developmental Biology* **102**, 216–227.
- BRINKLEY, L. L. (1986). Cell distribution during mouse secondary palate closure. *Journal of Embryology and Experimental Morphology* **96**, 111–130.
- BULLEIT, R. F. & ZIMMERMAN, E. F. (1985). The influence of the epithelium on palate shelf reorientation. *Journal of Embryology and Experimental Morphology* **88**, 265–279.
- CLEATON-JONES, P. (1976). Radioautographic study of mesenchymal cell activity in the secondary palate of the rat. *Journal of Dental Research* **55**, 437–440.
- DIEWERT, V. M. (1980). Differential changes in cartilage cell proliferation and cell density in the rat craniofacial complex during secondary palate development. *Anatomical Record* **198**, 219–228.
- DIEWERT, V. M. (1981). Correlation between alterations in Meckel's cartilage and induction of cleft palate with β -aminopropionitrile in the rat. *Teratology* **24**, 43–52.
- FERGUSON, M. W. J. (1978). The teratogenic effects of 5-fluoro-2-desoxyuridine (FUDR) on the Wistar rat fetus with particular reference to cleft palate. *Journal of Anatomy* **126**, 37–49.
- FERGUSON, M. W. J. (1984). Epithelial-mesenchymal interactions during vertebrate palatogenesis. *Current Topics in Developmental Biology* **19**, 137–164.
- HUDSON, C. D. & SHAPIRO, B. L. (1973). A radioautographic study of deoxyribonucleic acid synthesis in embryonic rat palatal shelf epithelium with reference to the concept of programmed cell death. *Archives of Oral Biology* **18**, 77–84.
- LUKE, D. A. (1984). Epithelial proliferation and development of rugae in relation to palatal shelf elevation in the mouse. *Journal of Anatomy* **138**, 251–258.
- NANDA, R. & ROMEO, D. (1975). Differential cell proliferation of embryonic rat palatal processes as determined by incorporation of tritiated thymidine. *Cleft Palate Journal* **12**, 436–443.
- POURTOIS, M. (1972). Morphogenesis of the primary and secondary palate. In *Developmental Aspects of Oral Biology* (ed. H. C. Slavkin & L. A. Bavetta), pp. 81–108. New York and London: Academic Press.
- ROGERS, A. W. (1979). *Techniques of Autoradiography*, 3rd ed, pp. 368–370. Amsterdam: Elsevier.
- WATERMAN, R. E. & MELLER, S. M. (1974). Alterations in the epithelial surfaces of human palatal shelves prior to and during fusion: a scanning electron microscope study. *Anatomical Record* **180**, 111–136.
- YASUDA, Y. & FUJIMOTO, T. (1986). The anterior half of mouse palatal shelf is elevated by a remodelling movement. *Acta anatomica* **125**, 37–41.