

## **Morphological, histochemical and immunohistological studies of the paracervical ganglion in prepubertal, pregnant and adult, non-pregnant guinea-pigs**

**B. S. MITCHELL AND V. V. STAUBER**

*Human Morphology, Faculty of Medicine, University of Southampton, Medical and Biological Sciences Building, Bassett Crescent East, Southampton SO9 3TU*

(Accepted 11 April 1990)

### INTRODUCTION

The major pathways taken by nerves supplying the uterus in guinea-pigs have been determined by Thobert, Alm & Sjöberg (1977). They found that nerve fibres passed via the suspensory ligaments of the uterus, the hypogastric nerves and the paracervical ganglia. Alm, Lundberg, Wharton & Polak (1988*a, b*) and Alm & Lundberg (1988) found that the extrinsic and intrinsic innervation of the guinea-pig uterus was predominantly noradrenergic, with a few peptidergic fibres. Acetylcholinesterase-positive fibres were found only around the uterine artery (Alm *et al.* 1988*a*) and were scarce intramurally (Thobert *et al.* 1977).

The paired paracervical ganglia which supply the uterus lie in the paracervical connective tissues. Kanerva & Teravainen (1972) observed two main cell types in the rat paracervical ganglion: principal neurons (the majority) and small granule-containing cells which were believed to correspond to the small, intensely fluorescent (SIF) cells seen in other autonomic ganglia. The ultrastructure of these two cell types was similar to that seen in other autonomic ganglia.

Of the principal neurons in the rat paracervical ganglion Kanerva, Lietzen & Teravainen (1972) concluded that approximately one-fifth were cholinergic and one-third were catecholaminergic. The fluorescence for noradrenaline in SIF cells was more intense than that of the principal neurons (Baker *et al.* 1977). In rats neuropeptide-like immunoreactivities detected in paracervical ganglion tissues include vasoactive intestinal peptide (VIP) and neuropeptide tyrosine (NPY), as well as the enzymes tyrosine hydroxylase (TH) and dopamine  $\beta$  hydroxylase (D $\beta$ H) in principal neurons (Gu *et al.* 1984; Inyama *et al.* 1985; Papka, Traurig & Klenn, 1987), VIP, NPY, substance P (SP), calcitonin gene-related peptide (CGRP), cholecystokinin (CCK-8), enkephalin (ENK), and atrial natriuretic factor (ANF) in nerve terminals (Papka, Traurig & Wekstein, 1985; Papka *et al.* 1987) and NPY, CGRP and CCK-8 in SIF cells (Papka *et al.* 1987). In guinea-pigs, neuropeptides detected in paracervical ganglion tissues included VIP, NPY, peptide histidine isoleucine (PHI), dynorphin (Dyn), neurotensin (NT), somatostatin (SOM), TH or D $\beta$ H immunoreactivities in principal neurons, and TH, D $\beta$ H, NPY, PHI, ENK, SP, SOM, CGRP, Dyn or VIP immunoreactivities in nerve fibres (Morris & Gibbins, 1987; Alm & Lundberg, 1988).

During pregnancy it has been established that there is a loss of catecholamine fluorescence from nerve fibres within the uterine wall in guinea-pigs (Bell & Malcolm, 1978). During late pregnancy in guinea-pigs Alm, Bjorklund, Owman & Thobert (1979) noted that TH levels in the fetus-containing uterine horn were progressively

reduced. In pregnant guinea-pigs, degenerative changes in the noradrenergic nerve fibres in the uterine wall adjacent to fetal tissues were noted by Alm *et al.* (1988*b*). In rats, Kanerva (1972) found that there was an increase in catecholamine fluorescence, but not in acetylcholinesterase activity, of the principal neurons of the paracervical ganglion in late pregnancy.

In the present study of the guinea-pig paracervical ganglion the disposition and the ultrastructure of neuronal perikarya were studied to determine whether the ganglion in this species is similar to that of rats. An attempt was made to assess the effects of pregnancy on the paracervical ganglion. The neuropeptide content of ganglion tissues from guinea-pigs at late stages of gestation was examined qualitatively and compared to that of ganglion tissues from prepubertal and adult non-pregnant guinea-pigs.

#### MATERIALS AND METHODS

Six prepubertal female Hartley guinea-pigs, four pregnant Hartley guinea-pigs (full term) and two adult female Hartley guinea-pigs of the same age as the pregnant animals were given a lethal dose of Euthatal (sodium pentobarbitone), perfused with ice-cold heparinised isotonic saline followed by either 4% paraformaldehyde in 0.1 M phosphate buffer (pH 7.4) or a 2% glutaraldehyde:4% paraformaldehyde mixture (Karnovsky, 1965). Tissues from the uterovaginal junction (including paracervical and paravaginal tissues) and from the gut (positive control) were removed and postfixed in the same fixatives for four hours. The tissues were divided and prepared for light and electron microscopy or immunohistology.

##### *Microscopy*

Tissues for immunohistology were washed in sucrose for 18 hours and then sectioned (16  $\mu\text{m}$  thick) on a cryostat. Sections were mounted on slides coated with either 0.1% poly-L-lysine, or with 0.5% gelatine, and air dried. Appropriately sized pieces of tissues were embedded in methacrylate for examination with the light microscope or in Araldite for examination with the light or electron microscope. Sections for light microscopy (1  $\mu\text{m}$  or 4  $\mu\text{m}$  thick) were stained with 1% toluidine blue, and sections for electron microscopy (ultrathin) were stained with lead citrate and uranyl acetate (Reynolds, 1963). Location and extent of ganglion tissues was determined in prepubertal guinea-pigs, whilst ultrastructure and neuropeptide content was examined in prepubertal and pregnant guinea-pigs. Ganglion tissues from non-pregnant guinea-pigs were also examined for neuropeptides.

##### *Quantitation*

Sections (4  $\mu\text{m}$  thick) of some methacrylate-embedded material were cut at 40  $\mu\text{m}$  intervals and stained with 1% toluidine blue. Using a microscope fitted with a drawing tube, outlines of ganglionic clusters were drawn at each 40  $\mu\text{m}$  interval and their cross-sectional areas determined using an IBAS-2 (Kontron) image analysis system. The number of clusters and the numbers of neuronal perikarya within each cluster were counted.

##### *Immunohistology and histochemistry*

The cryostat sections were used to demonstrate either acetylcholinesterase activity following the method of Karnovsky & Roots (1964), using acetylthiocholine iodide as substrate, or in an indirect immunofluorescence method for tyrosine hydroxylase, neuropeptide Y, vasoactive intestinal peptide, substance P, leucine enkephalin, or atrial

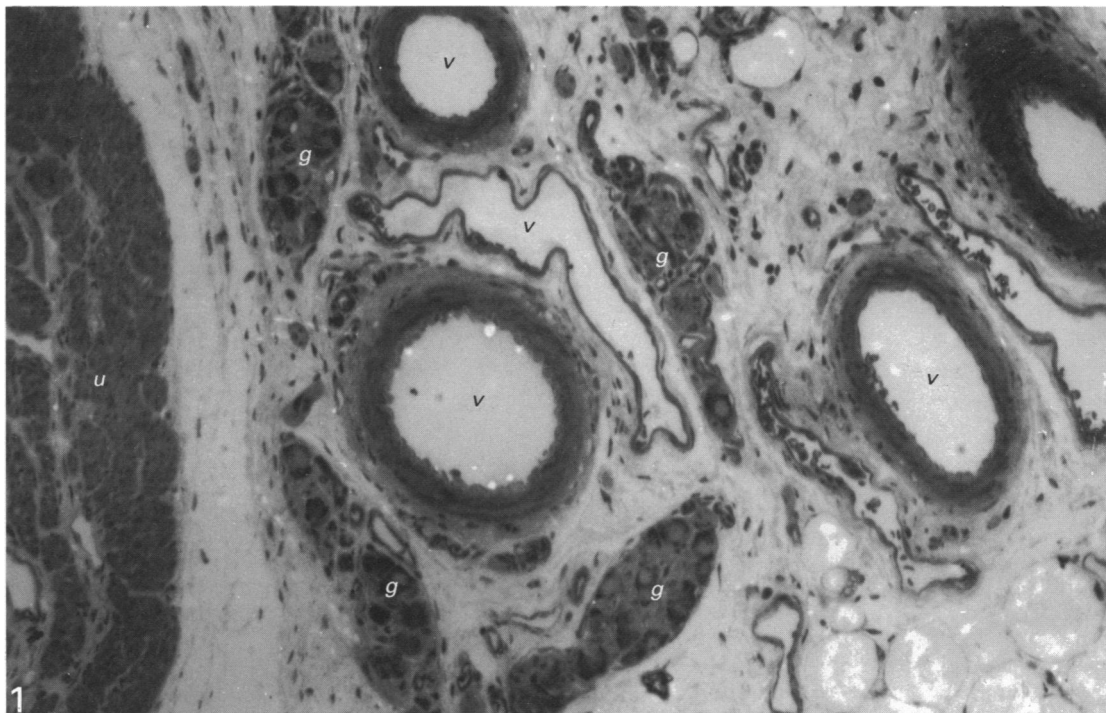


Fig. 1. A photomicrograph of a methacrylate section of tissues stained with 1% toluidine blue from the uterovaginal region of a prepubertal guinea-pig, showing uterine tissues (*u*), several blood vessels (*v*) and four ganglionic clusters (*g*).  $\times 410$ .

natriuretic factor immunoreactivities. Antibodies (raised in rabbits) were obtained from Cambridge Research Biochemicals, UK, for the neuropeptides and from Eugene Tech International, US, for tyrosine hydroxylase. Sites of immunoreactivity were labelled using a fluorescein isothiocyanate (FITC) sheep anti-rabbit IgG conjugate (Nordic Immunological). The first layer antibodies were applied for 18 hours at room temperature and the second layer FITC conjugate was applied for one hour at room temperature. Immunofluorescence preparations were mounted in AF 1 glycerol/PBS (Citifluor) to prevent fading and examined on an Olympus fluorescence microscope.

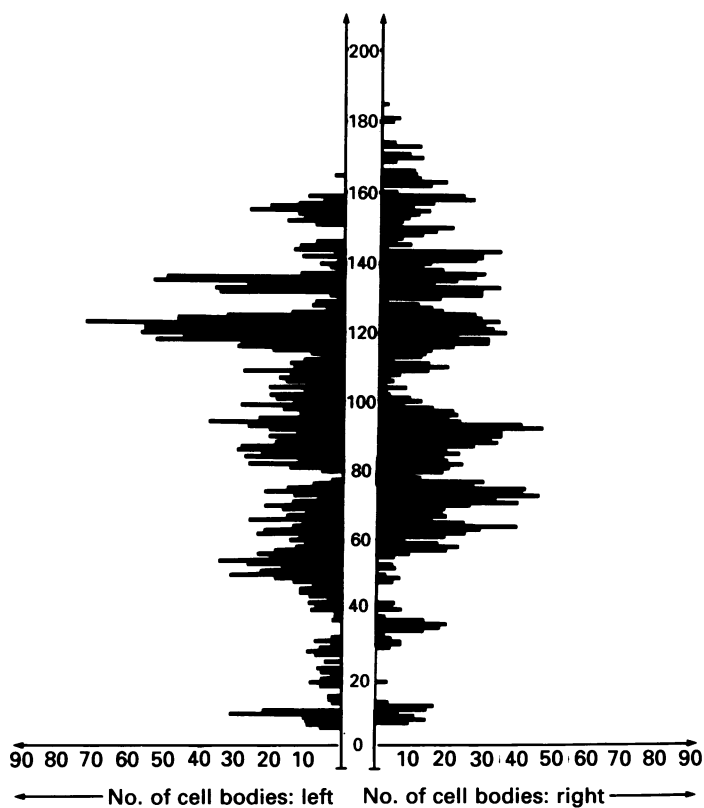
Controls for the acetylcholinesterase method consisted of omission of the substrate or its substitution by butyrylthiocholine iodide. Controls for the immunofluorescence method included omission of the first layer of antibody or application of the neuropeptide antibodies to sections of guinea-pig gut.

## RESULTS

### *Prepubertal guinea-pigs*

#### *Location and extent of the ganglion*

The paracervical ganglion consisted of different sized clusters of ganglion cells (Fig. 1), which were found at intervals in the paracervical and paravaginal tissues, lying parallel to the long axis of the uterus and upper vagina. The clusters were not disposed symmetrically (Fig. 2) and the disposition of the clusters varied between animals. The largest number of clusters, which could consist of 60 or more perikarya, though often less, and sometimes of only a single perikaryon, was located around the uterovaginal



2

Fig. 2. A histogram showing the numbers of cell bodies (neuronal perikarya) on the right and left sides of the uterovaginal junction in the paracervical ganglion of a prepubertal guinea-pig. The vertical axis represents the number of the serial section: 0 = vaginal pole, 200 = uterine pole.

junction. At any one level 100 perikarya or more could be found in up to seven clusters in the same animal, though there was a rapid fall off in numbers of clusters towards the uterine pole.

Within each cluster the number of neuronal perikarya seen was related to the total area of the cluster (Fig. 3). There were on average 2200 neuronal perikarya in the totality of ganglionic clusters on any one side of the uterovaginal junction in a prepubertal guinea-pig.

#### *Light microscopy*

Neuronal perikarya were grouped together and enclosed by a thin capsule (Fig. 4). Many capillaries were seen within the ganglionic clusters, as well as myelinated and non-myelinated nerve fibres which were seen entering or leaving the clusters (Fig. 4). There seemed to be no regional differences in appearances within the ganglionic clusters. Commonly the clusters were situated close to large blood vessels (Fig. 1).

#### *Ultrastructure*

*Principal neurons* (Fig. 5a). These cells measured from 10 to 15  $\mu\text{m}$  in diameter. They contained the usual array of cytoplasmic organelles found in neurons of autonomic ganglia. The mitochondria were often elongated and occurred in large

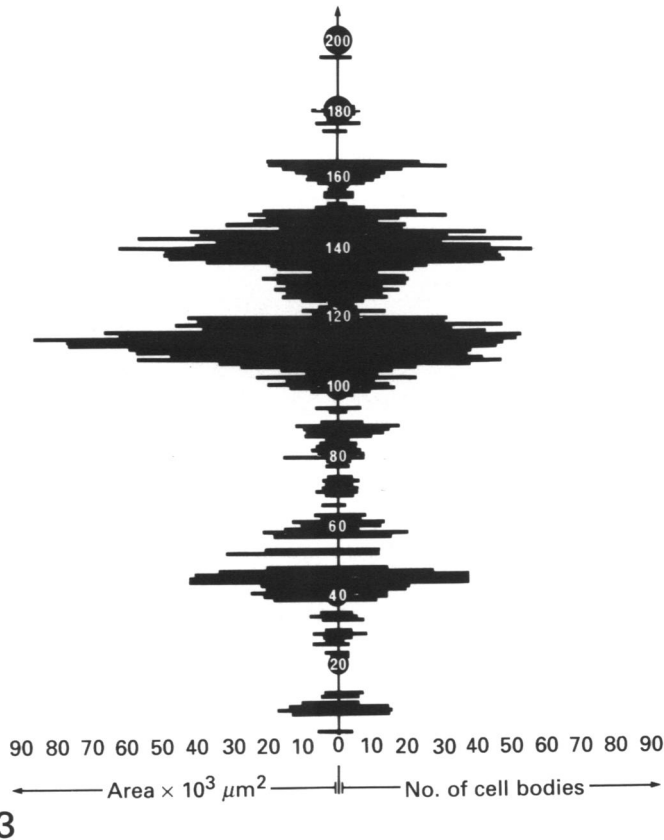


Fig. 3. A histogram showing the relationship between the numbers of cell bodies (neuronal perikarya) and the area they occupy in the paracervical ganglion of a prepubertal guinea-pig. The vertical axis represents the number of the serial section: 0 = vaginal pole, 200 = uterine pole.

numbers throughout the cytoplasm. Vesicles (70–110 nm in diameter) with an electron-dense core were seen randomly and peripherally within the cytoplasm. Sometimes the principal neurons gave rise to cytoplasmic projections that were apposed to nerve terminals. The junction between principal neurons and satellite cells was usually very close, except where there were nerve terminals or nerve varicosities (Fig. 5*b*). Vacuolated perikarya, as reported in ganglia of certain other species, were not seen.

*Satellite cells.* This cell type surrounded the principal neurons very closely (Fig. 5*a*). Sometimes the apposition of the plasma membranes of the satellite cells and the principal neurons was complex (Fig. 5*b*). The cytoplasm of the satellite cells was slightly more electron-dense than that of the principal neurons, but not so densely packed with cytoplasmic organelles as principal neurons.

*Nerve terminals and nerve varicosities.* These structures were of a variety of shapes and sizes, though frequently in sections they appeared elliptical, and were occasionally quite long. They were often found together in groups of three or more. Occasionally the terminals were obviously enveloped by the cytoplasm of a Schwann cell. Sometimes two terminals lay one on each side of a projection from a principal neuron (Fig. 5*c*).

The synaptic vesicles in the nerve terminals were of two types: small clear round vesicles measuring 20–40 nm in diameter (Fig. 5*d*) and vesicles possessing an electron-

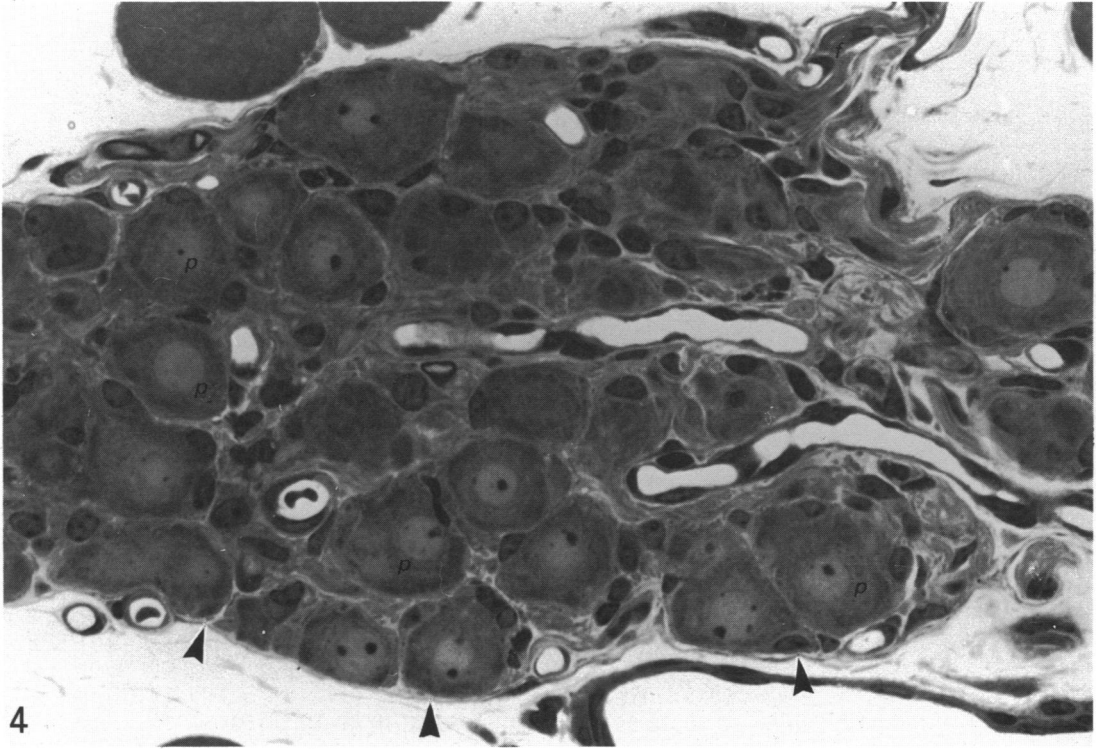


Fig. 4. A photomicrograph of an Araldite section of paracervical tissues stained with 1% toluidine blue from a prepubertal guinea-pig, containing a ganglionic cluster with examples of neuronal perikarya (*p*), nerve fibres (*f*) and the capsule shown by arrowheads.  $\times 590$ .

dense core measuring 70–110 nm in diameter (Fig. 5e). Occasionally the small clear vesicles were elliptical in shape, though these were often mixed in with the round vesicles. Rarely the vesicles with electron-dense cores predominated, though more often the small clear vesicles were in the majority. In some terminals the small clear vesicles were found alone. A small number of terminals had glycogen-like particles interspersed amongst the vesicles. Commonly 3–5 mitochondria were seen within the terminal and were sometimes clumped together on one side of it. On occasions the terminal appeared to be surrounded by an axon with which it synapsed.

Synapses tended to be of the asymmetric type and were most frequently axosomatic (Fig. 5f), though an occasional axoaxonal or axodendritic (Fig. 5g) synapse was seen.

#### *Pregnant guinea-pigs*

##### *Ultrastructure*

No obvious changes in ultrastructure were noted.

##### *Neuropeptides and neurotransmitters in ganglionic clusters from pregnant, non-pregnant adult, and prepubertal guinea-pigs*

Neuronal perikarya, nerve fibres and nerve terminals were immunoreactive for VIP (Fig. 6a), TH (Fig. 6b), NPY (Fig. 6c), but SP (Fig. 6d) and ENK (Fig. 6e) were only detected in nerve fibres and nerve terminals. No immunoreactivity was detected for ANF. The majority of perikarya reacted for VIP or NPY, whilst relatively fewer were immunoreactive for TH. Not all the ganglionic clusters at any one level exhibited

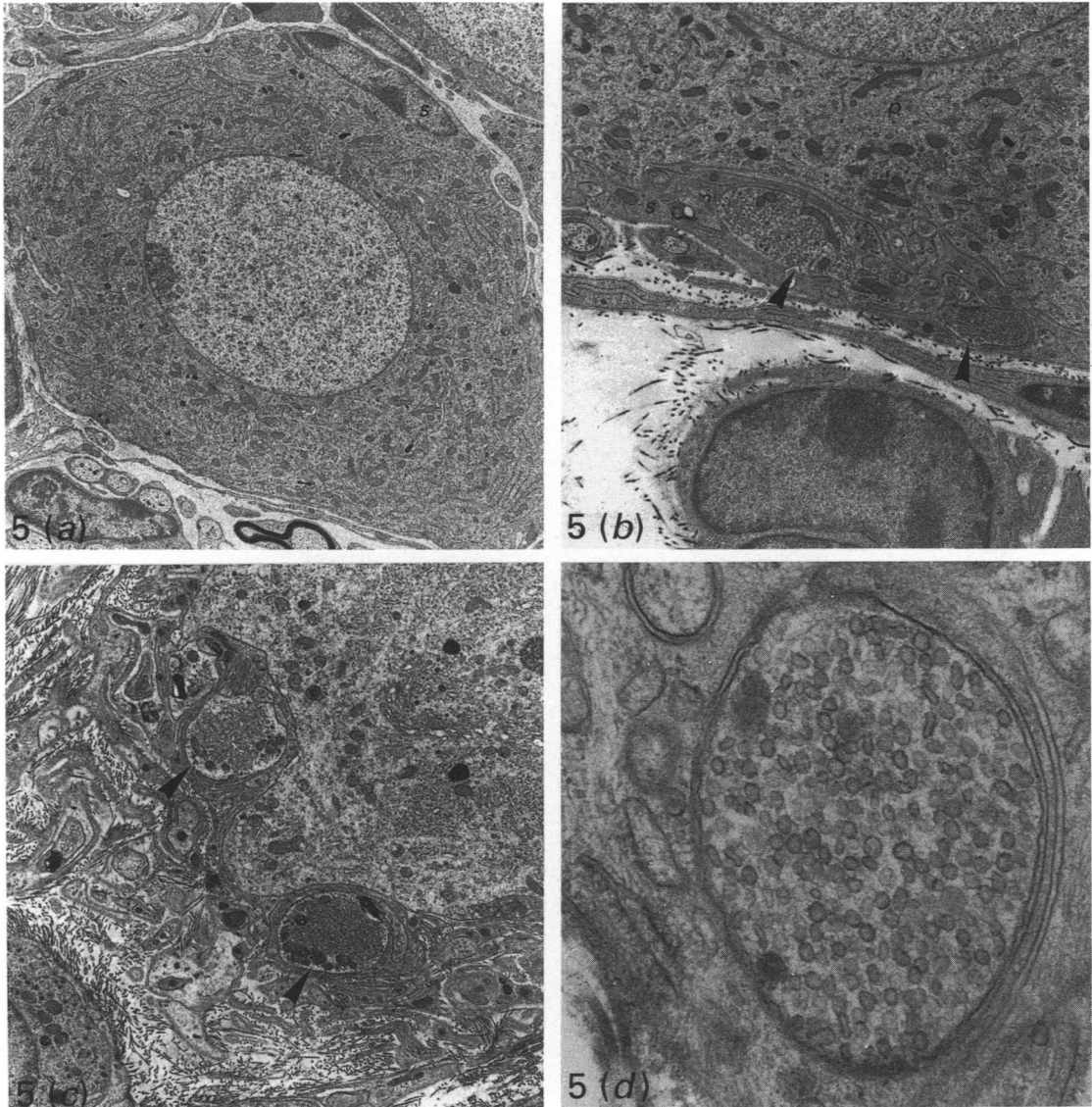


Fig. 5 (a-d). For legend see p. 184.

immunoreactivity for particular neuropeptides and there was some variation in immunoreactivity for the neuropeptides in principal neurons.

Whilst no differences in immunoreactivity were found between ganglion tissues from non-pregnant adult and prepubertal guinea-pigs, there was an apparent small decrease in the numbers of neuronal perikarya labelled for VIP, TH or NPY (Fig. 6a, b, c) immunoreactivities in pregnancy, though no quantitative studies were carried out. Furthermore, in pregnancy, no SIF cells were detected, though in non-pregnant adult and prepubertal guinea-pigs such cells were found to contain TH or NPY or, on one occasion, SP, as identified by their size and particularly intense fluorescence.

Application of neuropeptide antibodies to sections of gut resulted in neuropeptide demonstration in the intramural gut plexuses. Omission of the first layer antibodies produced no significant reaction.

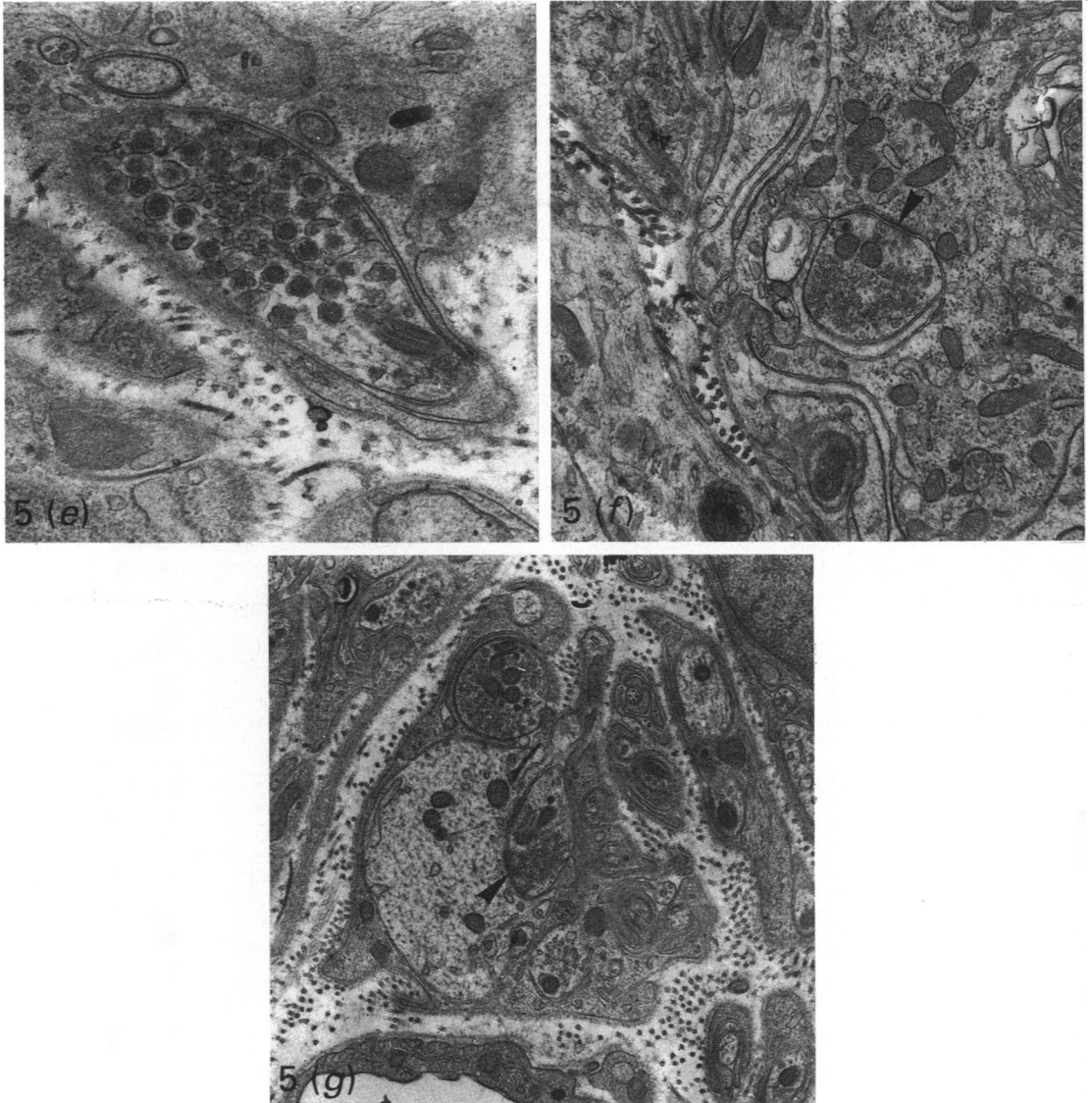


Fig. 5(a-g). Electron micrographs from the paracervical ganglion of a prepubertal guinea-pig. (a) The neuronal perikaryon of a principal neuron. A satellite cell (*s*) can be seen closely apposed to the principal neuron.  $\times 3955$ . (b) The apposition between a principal neuron (*p*) and a satellite cell (*s*) enclosing several nerve terminals/varicosities (arrowheads).  $\times 21105$ . (c) A cytoplasmic projection from a principal neuron with a nerve terminal/varicosity on each side (arrowheads).  $\times 6488$ . (d) A nerve terminal/varicosity containing predominantly small, clear, round synaptic vesicles.  $\times 55825$ . (e) A nerve terminal/varicosity containing predominantly synaptic vesicles with electron-dense cores.  $\times 33495$ . (f) An axosomatic synapse (arrowhead).  $\times 13567$ . (g) An axodendritic synapse (arrowhead).  $\times 13050$ .

#### *Acetylcholinesterase* (Fig. 7)

The majority of perikarya exhibited acetylcholinesterase activity. The positive cells were of differing sizes. Some nerve fibres reacted. There seemed no obvious differences from the reaction obtained in pregnant, non-pregnant adult or prepubertal guinea-pigs. In control preparations no significant reaction was observed.



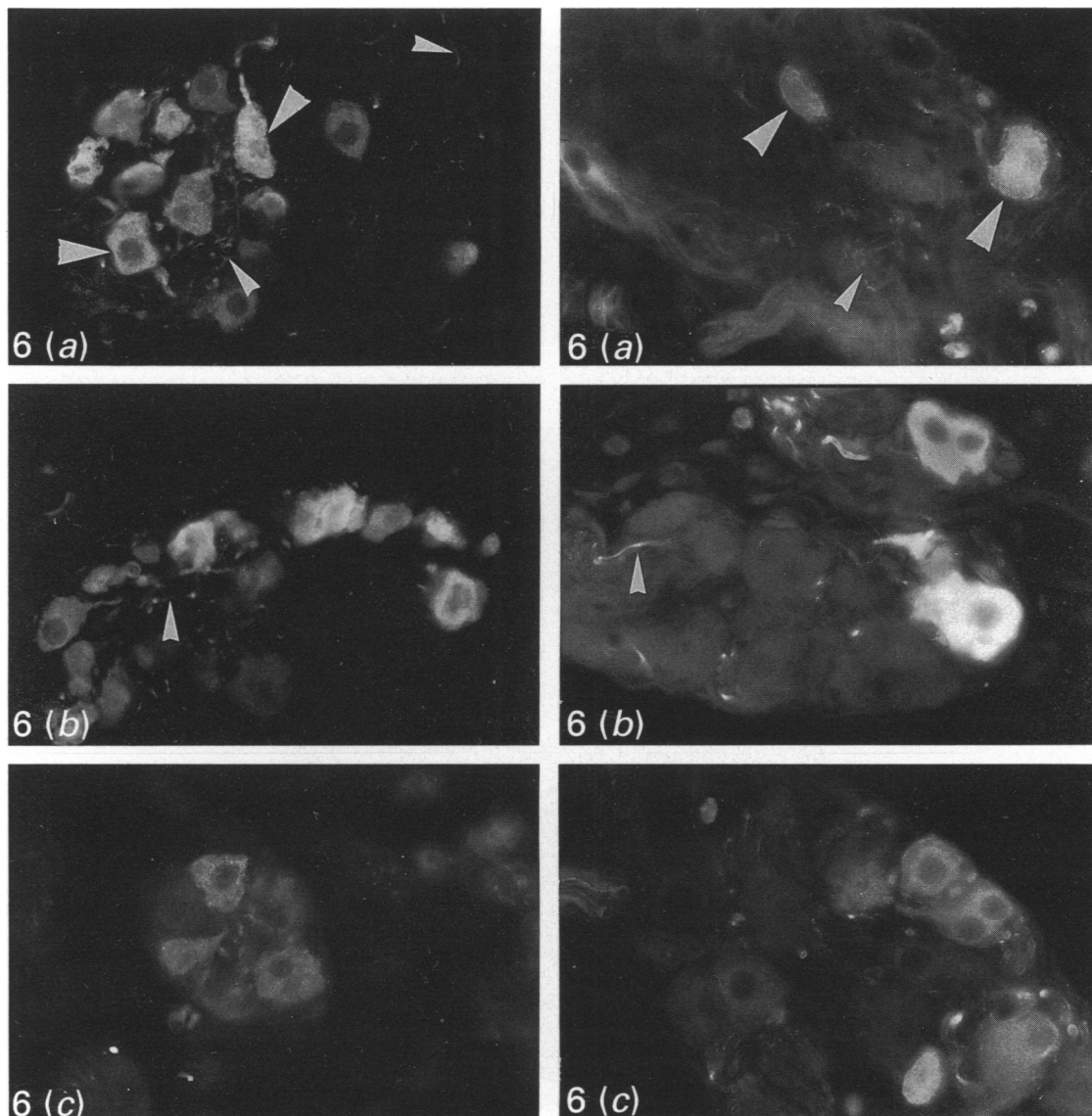


Fig. 6 (a-c). For legend see p. 186.

#### DISCUSSION

The paracervical ganglion has received relatively little attention in guinea-pigs. The location and light microscopy of the ganglion was studied in prepubertal animals to note any effects of ovarian or placental steroids, or of age. It therefore provided a baseline comparison. Clusters of ganglion cells were detected at various levels in the paracervical connective tissue. Variation in number and size of ganglionic clusters was evident by the lack of symmetry in the organisation of the clusters and the different disposition of the clusters in different animals. In the study of the guinea-pig paracervical ganglion by Morris & Gibbins (1987) dissection revealed 6–10 ganglionic clusters consisting of a total mean number of nearly 1200 neuronal perikarya. This




Fig. 6 (*a-e*). Photomicrographs of fluorescence preparations of the paracervical ganglion from prepubertal guinea-pigs on the left and pregnant guinea-pigs on the right, showing immunoreactivity for the following. (*a*) VIP in some principal neurons (large arrowheads) and nerve fibres (small arrowheads).  $\times 410$ . (*b*) TH in some principal neurons and nerve fibres (arrowed). Note the variation in intensity of fluorescence in different neurons.  $\times 410$ . (*c*) NPY in principal neurons. Note the granularity of immunoreactivity.  $\times 410$ . (*d*) SP in a perineuronal distribution for some of the nerve terminals/varicosities (arrowheads). (Note only nerve fibres shown on right)  $\times 410$ . (*e*) ENK where there are some particularly large varicosities, typical of ENK immunoreactivity (arrowheads).  $\times 410$ .

Fig. 7. A photomicrograph of a preparation for acetylcholinesterase in the paracervical ganglion of a prepubertal guinea-pig. Some positive principal neurons (large arrowheads) and nerve fibres (small arrowheads) are indicated.  $\times 165$ .

compares with 2200 perikarya in the present study. Use of serial sections in the present study has eliminated the likelihood of missing clusters, which could happen using the dissection method.

In the main the cell distribution and ultrastructure of the ganglion in guinea-pigs are

similar to the findings in rats (Kanerva & Teravainen, 1972) and are typical of autonomic ganglia. However, the vacuolated neuronal perikarya that Kanerva & Teravainen (1972) reported in the rat ganglion were not present in the guinea-pig. Whilst it is possible such structures are artefacts of fixation, they have also been demonstrated in rat hypogastric ganglion (Partenen *et al.* 1979). It is possible that they are a species-dependent phenomenon.

The majority of nerve terminals appeared to make axosomatic synapses with the neuronal perikarya of principal neurons. Similar findings have been made by Kanerva & Teravainen (1972) in rats. This unusual observation could indicate that the cells are not typical multipolar autonomic neurons and that they possess fewer cell processes than usual. Ultrastructural observations suggest that this may be so. The shape of the synaptic vesicles in the nerve terminals may in part be attributable to fixation variables which Williams, Warwick, Dyson & Bannister (1989) suggest are likely to reflect differences in chemical composition of the vesicles. That some varicosities and terminals appear to contain only vesicles with electron-dense cores or only small clear vesicles may indicate that the section may not be truly representative of the entire terminal, as pointed out by Burnstock (1986).

Thobert *et al.* (1977) were able to demonstrate acetylcholinesterase activity in the guinea-pig paracervical ganglion but not in the uterus. The present study has confirmed the presence of acetylcholinesterase in the ganglion and indicates that these putative cholinergic neurons project to pelvic visceral structures other than the uterus.

In immunofluorescence preparations VIP, NPY, TH, SP and ENK were localised within the paracervical ganglion. The different intensities of fluorescence for neuropeptides in principal neurons could indicate different stages in cell synthetic activities. The absence of immunoreactivities in different clusters of neuronal perikarya could indicate polarity with, perhaps, different populations of paracervical neuronal perikarya projecting to different pelvic viscera. The absence of ANF in the ganglionic tissues examined accords with the findings of Alm & Lundberg (1988) in guinea-pigs; however, Papka *et al.* (1985, 1987) did detect this neuropeptide in the nerve terminals of paracervical ganglia of rats.

There seemed to be a scarcity of SIF cells in the guinea-pig paracervical ganglion compared to the rat ganglion (Kanerva & Teravainen, 1972). It is well established that the numbers of such cells vary in the autonomic ganglia of different species (Boch, 1982; Taxi, Derer & Domich, 1983). In immunofluorescence preparations in the present study the finding of TH or NPY immunoreactivities in SIF cells of the ganglion confirms the findings of Morris & Gibbins (1987), though the present study is the first to report that SIF cells contained SP immunoreactivity. It was interesting that SIF cells were not detected in ganglionic tissues during pregnancy, and it is possible to speculate that this cell type might be responsive to ovarian hormonal influences as suggested by Kanerva & Teravainen (1972). However, the absence of SIF cells from ganglionic tissues of pregnant guinea-pigs has not been confirmed by serial sectioning.

Whilst no obvious changes were detected in the ultrastructure of the ganglion in late pregnancy, the apparent reduction in numbers of immunoreactive neuronal perikarya may be important. Though quantitative studies were not undertaken, the reduction in immunoreactive cells does not necessarily imply an actual reduction in cell numbers present, merely a switching off of neuropeptide production. Such a possibility might in part account for the observation that TH and NPY immunoreactive nerve fibres disappear from the uterus during pregnancy (Alm *et al.* 1988*a*) if their neuronal perikarya are located in the paracervical ganglion. Since no ultrastructural changes

were found in the ganglion, the degeneration observed in the nerves of the uterus in pregnant guinea-pigs by Alm *et al.* (1988a) presumably did not extend centripetally. The remaining principal neurons immunoreactive for TH or NPY in ganglia from pregnant guinea-pigs in the present study could indicate the possibility that these neurons project to viscera other than the uterus. It could also indicate that the principal neurons projecting to the uterus do not lose their neuropeptides in their perikarya, merely in their axons. Morris & Gibbins (1987) noted that TH and NPY (and other combinations of neuropeptides/catecholamine synthesising enzymes) co-existed in the ganglion. It would be of interest to determine whether there are changes in the pattern of co-existence in pregnancy, where factors such as hormones may alter the synthesis, storage and release of neuropeptides. Indeed, Kanerva (1972) found an increase in formaldehyde-induced fluorescence (another marker of adrenergic neurons) of principal neurons of the paracervical ganglion during pregnancy (but not of SIF cells).

There could be a difference in hormonal sensitivity of pre- and postganglionic neurons and interneurons (regarded as Type I SIF cells by Williams *et al.* 1976) of the paracervical ganglion. Nerve terminals of preganglionic neurons immunoreactive for SP or ENK in the ganglion remained unchanged in pregnancy, whereas there seemed to be some reduction in numbers of immunoreactive neuronal perikarya within ganglia, the postganglionic neurons. In addition there was an apparent absence of SIF cells in ganglion tissues of pregnant animals.

Morris & Gibbins (1987) and Alm & Lundberg (1988) both studied sexually mature guinea-pigs. The ovarian hormone levels of pregnant, non-pregnant adult and prepubertal guinea-pigs are different. Nevertheless, the same neuropeptides were identified in the ganglion tissues of each group of animals, though there was an apparent reduction of neuronal neuropeptide content in pregnancy. The demonstration of neuropeptides in the neuronal perikarya of paracervical ganglia of prepubertal guinea-pigs indicates that the neuropeptides are involved in activities which are not solely concerned with adult reproductive activities; indeed, it may reflect the likelihood of the ganglion being involved in the regulation of other pelvic visceral functions.

#### SUMMARY

The morphology and ultrastructure of the paracervical ganglion were examined in prepubertal and pregnant guinea-pigs using the light and electron microscope. The neuropeptide and acetylcholinesterase content of the neuronal perikarya and SIF cells, nerve fibres and nerve terminals of the ganglion were examined in prepubertal, adult, non-pregnant and pregnant guinea-pigs.

The ganglion consisted of up to seven different sized clusters of neuronal perikarya lying parallel to the long axis of the uterovaginal junction, with 60 or more neuronal perikarya in any one cluster in the paracervical connective tissues. The number of neuronal perikarya within each cluster was related to the total area of each cluster. The light and electron microscopy of the clusters was typical of autonomic ganglia, though no vacuolated neurons were observed as has been reported in the rat.

The neuropeptide and acetylcholinesterase content of the ganglionic clusters was not different in prepubertal and adult, non-pregnant guinea-pigs. In pregnant guinea-pigs there was an apparent small decrease in numbers of neuronal perikarya containing the neuropeptides VIP, NPY or TH immunoreactivities, though no quantitative studies were undertaken. In pregnancy no SIF cells were detected, though in prepubertal and non-pregnant, adult guinea-pigs these cells contained TH, NPY or SP immunoreactivity.

The authors would like to thank the following people for their help in the preparation of this paper: Mr Charles Courtenay for help with illustrations and photography, Mrs Freida Jones for word processing, and Dr John Mitchell and Professor Donald Mayor for critical advice during the preparation of the manuscript.

## REFERENCES

- ALM, P., BJORKLUND, A., OWMAN, CH. & THOBERT, G. (1979). Tyrosine hydroxylase and dopa decarboxylase activities in the guinea pig-uterus: further evidence for functional adrenergic denervation in association with pregnancy. *Neuroscience* **4**, 145–154.
- ALM, P. & LUNDBERG, L. (1988). Co-existence and origin of peptidergic and adrenergic nerves in the guinea pig uterus. Retrograde tracing and immunocytochemistry, effects of chemical sympathectomy, capsaicin treatment and pregnancy. *Cell and Tissue Research* **254**, 517–530.
- ALM, P., LUNDBERG, L., WHARTON, J. & POLAK, J. M. (1988*a*). Organisation of the guinea-pig uterine innervation. Distribution of immunoreactivities for different neuronal markers. Effects of chemical- and pregnancy-induced sympathectomy. *Histochemical Journal* **20**, 290–300.
- ALM, P., LUNDBERG, L., WHARTON, J. & POLAK, J. M. (1988*b*). Effects of pregnancy on the extrinsic innervation of the guinea pig uterus. A histochemical and ultrastructural study. *Histochemical Journal* **20**, 414–426.
- BAKER, H. A., BURKE, J. P., BHATNAGER, R. K., VAN ORDEN, D. E., VAN ORDEN III, L. S. & HARTMAN, B. K. (1977). Histochemical and biochemical characterisation of the rat paracervical ganglion. *Brain Research* **132**, 393–405.
- BELL, C. & MALCOLM, S. J. (1978). Observations on the loss of catecholamine fluorescence from intrauterine adrenergic nerves during pregnancy in the guinea pig. *Journal of Reproduction and Fertility* **53**, 51–58.
- BOCH, P. (1982). *The Paraganglia*. Berlin: Springer-Verlag.
- BURNSTOCK, G. (1986). Research review: autonomic neuromuscular junctions: current developments and future directions. *Journal of Anatomy* **146**, 1–30.
- GU, J., POLAK, J. M., SU, H. C., BLANK, M. A., MORRISON, J. F. B. & BLOOM, S. R. (1984). Demonstration of paracervical ganglion origin for the vasoactive intestinal peptide-containing nerves of the rat uterus using retrograde tracing techniques combined with immunocytochemistry and denervation procedures. *Neuroscience Letters* **51**, 377–382.
- INYAMA, C. O., JACKER, G. W., GU, J., DAHL, D., BLOOM, S. R. & POLAK, J. M. (1985). Cytochemical relationships in the paracervical ganglion (Frankenhäuser) of rat studied by immunocytochemistry. *Neuroscience Letters* **55**, 311–316.
- KANERVA, L. (1972). Development, histochemistry and connections of the paracervical (Frankenhäuser) ganglion of the rat uterus. A light and electron microscope study. *Acta Instituti anatomici Universitatis Helsinkiensis Suppl.* **2**.
- KANERVA, L., LIETZEN, R. & TERAVAINEN, H. (1972). Catecholamines and cholinesterases in the paracervical (Frankenhäuser) ganglion of normal and pregnant rats. *Acta physiologica scandinavica* **86**, 271–277.
- KANERVA, L. & TERAVAINEN, H. (1972). Electron microscopy of the paracervical (Frankenhäuser) ganglion of the adult rat. *Zeitschrift für Zellforschung und mikroskopische Anatomie* **129**, 161–177.
- KARNOVSKY, M. J. (1965). A formaldehyde-glutaraldehyde fixative of high osmolality for use in electron microscopy. *Journal of Cell Biology* **27**, 137A–138A.
- KARNOVSKY, M. J. & ROOTS, L. (1964). A 'direct-colouring' thiocholine method for cholinesterases. *Journal of Histochemistry and Cytochemistry* **12**, 219–221.
- MORRIS, J. L. & GIBBINS, I. L. (1987). Neuronal colocalisation of peptides, catecholamines and catecholamine-synthesizing enzymes in guinea pig paracervical ganglia. *Journal of Neuroscience* **7**, 3117–3130.
- PAPKA, R. E., TRAUIG, H. H. & KLENN, P. (1987). Paracervical ganglia of the female rat; histochemistry and immunohistochemistry of neurons, SIF cells and nerve terminals. *American Journal of Anatomy* **179**, 243–257.
- PAPKA, R. E., TRAUIG, H. H. & WEKSTEIN, M. (1985). Localisation of peptides in nerve terminals in the paracervical ganglion of the rat by light and electron microscopic immunohistochemistry: enkephalin and atrial natriuretic factor. *Neuroscience Letters* **61**, 285–290.
- PARTENEN, M., HERVONEN, A., VAALASTI, A., KANERVA, L. & HERVONEN, H. (1979). Vacuolated neurons in the hypogastric ganglion of the rat. *Cell and Tissue Research* **199**, 373–386.
- REYNOLDS, E. S. (1963). The use of lead citrate at high pH as an electron opaque stain in electron microscopy. *Journal of Cell Biology* **17**, 208–212.
- TAXI, J., DERER, M. & DOMICH, A. (1983). Morphology and histophysiology of SIF cells in the autonomic ganglia. In *Autonomic Ganglia* (ed. Lars-Gosta Elfvin), pp. 67–95. Chichester: John Wiley.
- THOBERT, G., ALM, P. & SJOBERG, N.-O. (1977). Regional distribution of autonomic nerves in guinea pig uterus. *American Journal of Physiology* **233**, C25–C34.
- WILLIAMS, P. L., WARWICK, R., DYSON, M. & BANNISTER, L. H. (1989). *Gray's Anatomy*, 37th ed. London: Churchill Livingstone.
- WILLIAMS, T. H., CHIBA, T., BLACK, A. C., BHALLA, R. C. & JEW, J. (1976). Species variation in SIF cells of superior cervical ganglia: Are there two functional types? SIF cells, structure and function of the small, intensely fluorescent sympathetic cells (ed. D. Eränko). *Fogarty International Center Proceedings* No. 30, pp. 143–162.