

Short Report

Association of nerve fibres with myoid cells in the chick thymus

AN SOO CHAN

Department of Anatomy, National University of Singapore

(Accepted 28 September 1992)

ABSTRACT

The presence of nerve fibres in the medulla of the chick thymus has been investigated ultrastructurally. Unmyelinated nerve fibres were found not only in the perivascular space but also among the myoid cells. The nerve fibres were situated in close proximity to the myoid cells. The unmyelinated axons, containing predominantly clear vesicles and some dense-core vesicles, were found in recesses of the plasmalemma of the Schwann cell. Contacts between nerve fibres and fibroblasts were also observed.

INTRODUCTION

The ultrastructure of the myoid cells has been extensively studied (Sato & Hirose, 1966; Raviola & Raviola, 1967; Bockman & Winborn, 1969; Ito et al. 1969; Toro et al. 1969; Van de Velde & Friedman, 1970; Frazier, 1973; Gilmore & Bridges, 1974; Hanzliková, 1974). These cells are apparently contractile but attempts to demonstrate their innervation have been negative (Raviola & Raviola, 1967; Bockman & Winborn, 1969; Toro et al. 1969; Van de Velde & Friedman, 1970; Gilmore & Bridges, 1974; Hanzliková, 1979; Kendall et al. 1989). This report describes the presence of nerve fibres located in close proximity to the myoid cells in the chick thymus.

MATERIALS AND METHODS

Thymuses from 20 3-wk-old White Leghorn chicks were used. The chicks were perfused through the left ventricle, first with 0.85% sodium chloride and then with 2% paraformaldehyde and 3% glutaraldehyde in 0.1 M cacodylate buffer, pH 7.4 under sodium pentobarbital anaesthesia. Following perfusion, the thymic tissues from the 3rd to the 5th lobes were excised bilaterally, further fixed in the same solution for 3 h, postfixed in 1% osmium tetroxide in cacodylate buffer for 1.5 h, dehydrated and embedded in Araldite. Sections were stained with uranyl acetate

and lead citrate (Reynolds, 1963) and examined in a JEOL 1200 EX electron microscope at 60 kV.

OBSERVATIONS

Small bundles of unmyelinated nerves were observed in the medulla of the chick thymus, predominantly near blood vessels (Fig. 1) or in the vicinity of myoid cells (Figs 2–4). An estimate of the frequency of nerves close to myoid cells is less than 5%. The nerve fibres were separated by variable distances from the myoid cells, sometimes by a gap of about 100 nm. The intervening space contained basal laminae, amorphous material and occasional collagen fibres (Fig. 5). Nerve fibres also came to lie in close contact with fibroblasts (Fig. 2).

The nerve bundles contained a variable number (2–15) of unmyelinated axons, partly or completely surrounded by Schwann cell processes. The axons measured 0.3–1.8 μm in diameter and contained mitochondria and a mixture of small, clear vesicles, 30–50 nm in diameter (Fig. 4) and occasionally large, dense-core vesicles (Fig. 5). Neurofilaments and neurotubules were also evident in some axons.

Schwann cells were variable in their structure. At times they appeared simply as a round nucleus surrounded by a thin layer of cytoplasm. In others, the cytoplasm contained mitochondria, endoplasmic reticulum and lipid-like bodies (Fig. 5).

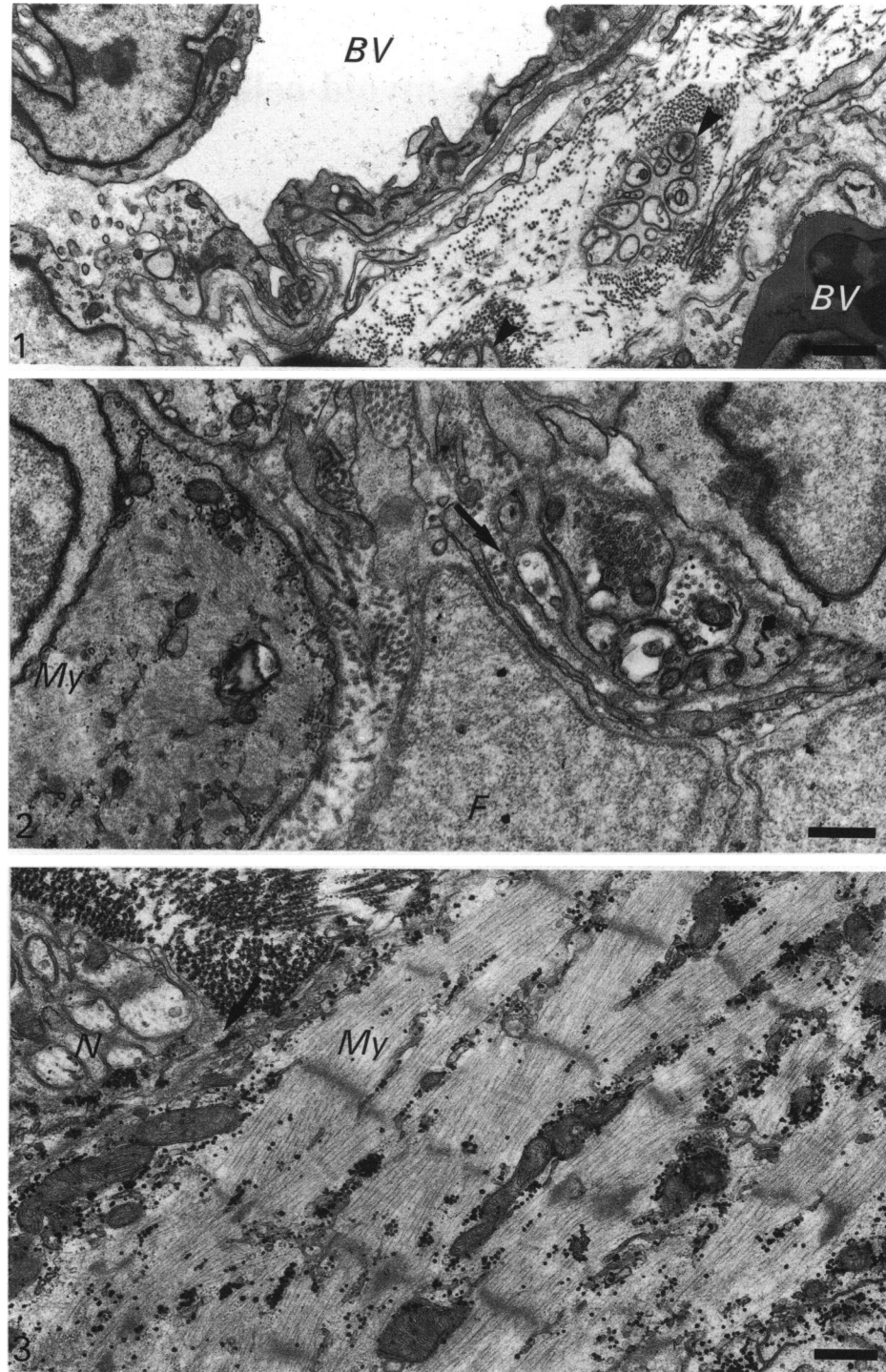


Fig. 1. Medulla of the chick thymus showing unmyelinated nerve bundles (arrowheads) located between blood vessels (*BV*). Bar, 0.5 μ m.

Fig. 2. Unmyelinated nerve bundle (arrow) in close proximity to fibroblast (*F*) and adjacent myoid cells (*My*). Bar, 0.5 μ m.

Fig. 3. Nerve bundle (*N*) containing unmyelinated axons lies in direct contact (arrow) with the myoid cell (*My*). Bar, 0.5 μ m.

DISCUSSION

Attempts to demonstrate the presence of nerves related to the myoid cells of the thymus have produced conflicting results. Terni (1929) observed numerous nerve endings on myoid cells in tissue stained by

Cajal's silver impregnation technique. Other studies, however, have produced negative results (Hammar, 1905; Raviola & Raviola, 1967; Bockman & Winborn, 1969; Toro et al. 1969; Van de Velde & Friedman, 1970; Gilmore & Bridges, 1974; Hanzliková, 1979; Kendall et al. 1989).

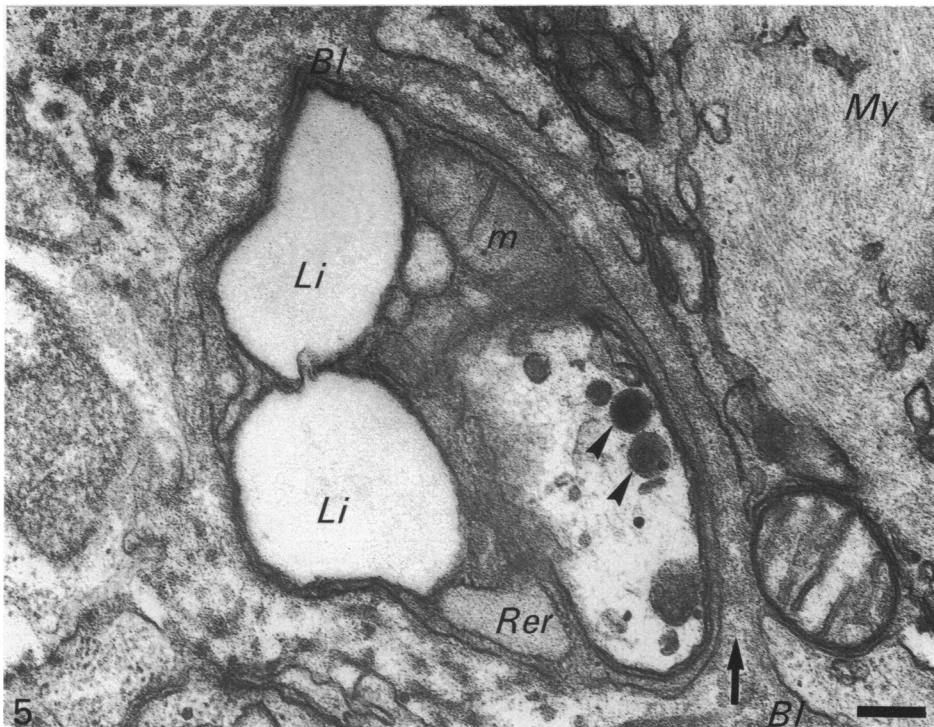
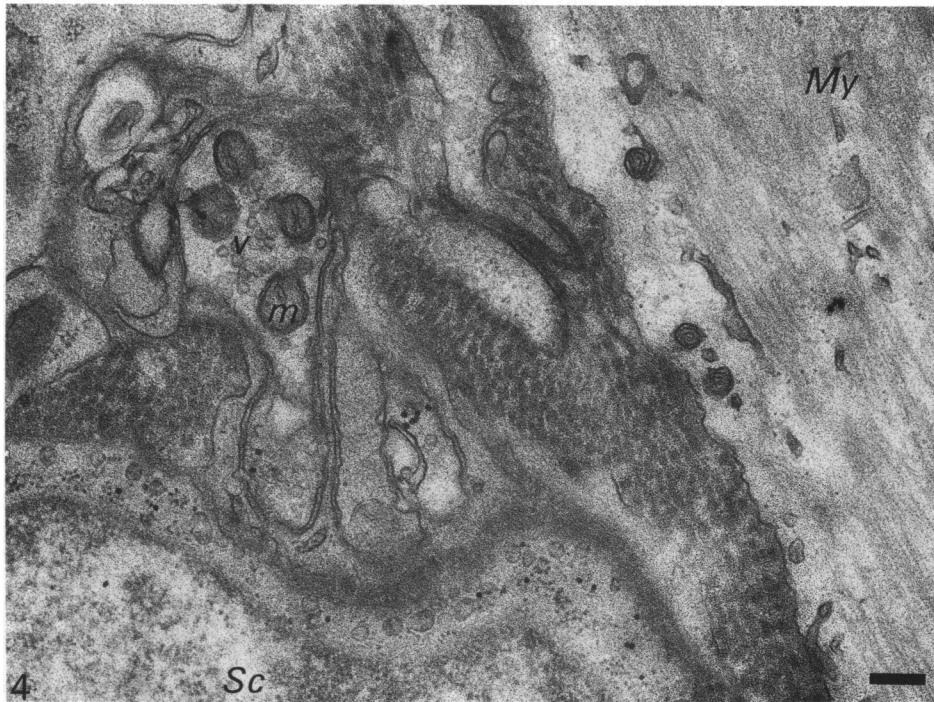

Fig. 4. Portion of a Schwann cell (*Sc*) partly invests axons, one containing clear vesicles (*v*) and mitochondria (*m*). Notice the adjacent myoid cell (*My*). Bar, 0.2 μ m.

Fig. 5. Nerve bundle in close contact with myoid cell (*My*). Intervening space (arrow) contains basal laminae (*Bl*) and amorphous material. The axon contains dense core vesicles (arrowheads). The Schwann cell contains mitochondria (*m*), rough endoplasmic reticulum (*Rer*) and lipid-like structures (*Li*). Bar, 0.2 μ m.

The present results provide ultrastructural evidence for the presence of unmyelinated nerve fibres located in close proximity to the myoid cells in the medulla of the chick thymus. Association of unmyelinated nerve fibres with myoid cells has also been reported in the

frog thymus, but the nerves apparently terminate at the subjacent granulated cells (Toro et al. 1969). Similar cellular arrangements were not observed in the present study and the site of termination of the nerve fibres is not clear.

Myoid cells are apparently contractile and sarcomeres in both contracted and relaxed states have been observed (Toro et al. 1969). The presence of acetylcholine receptors in the myoid cells (Kao & Drachman, 1976) therefore, raises the possibility of a functional link between myoid cells and neurotransmitters. Acetylcholine receptors on myoid cells may also be of pathogenic relevance. In hyperplastic thymuses, the evidence suggests that acetylcholine receptors on these cells are involved in the pathogenesis of myasthenia gravis (Kirchner et al. 1988). However, in myasthenia gravis-associated thymomas, proteins with acetylcholine receptor epitopes have also been identified in the epithelial cells (Marx et al. 1989, 1990).

ACKNOWLEDGEMENTS

This study was supported by a grant from the National University of Singapore. The technical and secretarial assistance of Ng Leh See, Tajuddin b M. Ali and Carolyne Wong is gratefully acknowledged.

REFERENCES

- BOCKMAN DE, WINBORN WB (1969) The ultrastructure of thymic myoid cells. *Journal of Morphology* **129**, 201–210.
- FRAZIER JA (1973) Ultrastructure of the chick thymus. *Zeitschrift für Zellforschung und mikroskopische Anatomie* **136**, 191–206.
- GILMORE RSC, BRIDGES JB (1974) Histological and ultrastructural studies on the myoid cells of the thymus of the domestic fowl, *Gallus domesticus*. *Journal of Anatomy* **118**, 409–416.
- HAMMAR JA (1905) Zur Histogenese und Involution der Thymusdrüse. *Anatomischer Anzeiger* **27**, 41–89.
- HANZLIKOVÁ V (1979) Histochemical and ultrastructural properties of myoid cells in the thymus of the frog. *Cell and Tissue Research* **197**, 105–112.
- ITO T, HOSHINO T, ABE K (1969) The fine structure of myoid cells in the human thymus. *Archivum Histologicum Japonicum* **30**, 207–215.
- KAO I, DRACHMAN DB (1976) Thymic muscle cells bear acetylcholine receptors: possible relation to myasthenia gravis. *Science* **195**, 74–75.
- KENDALL MD, AL-SHAWAF A, ZAIDI SAA (1989) The cholinergic and adrenergic innervation of the rat thymus. *Advances in Experimental Medicine and Biology* **237**, 255–261.
- KIRCHNER T, HOPPE F, SCHALKE B, MÜLLER-HERMELINK HK (1988) Microenvironment of thymic myoid cells in myasthenia gravis. *Virchows Archiv B Cell Pathology* **54**, 295–302.
- MARX A, KIRCHNER T, HOPPE F, O'CONNOR R, SCHALKE B et al. (1989) Proteins with epitopes of the acetylcholine receptor in epithelial cell cultures of thymomas in myasthenia gravis. *American Journal of Pathology* **134**, 865–877.
- MARX A, O'CONNOR R, GEUDER KI, HOPPE F, SCHALKE B et al. (1990) Characterization of a protein with an acetylcholine receptor epitope from myasthenia gravis-associated thymomas. *Laboratory Investigation* **62**, 279–286.
- RAVIOLA E, RAVIOLA G (1967) Striated muscle cells in the thymus of reptiles and birds: an electron microscopic study. *American Journal of Anatomy* **121**, 623–646.
- REYNOLDS ES (1963) The use of lead citrate at high pH as an electron-opaque stain in electron microscopy. *Journal of Cell Biology* **17**, 202–212.
- SATO M, HIROSE T (1966) Fine structure of the myoid cell in the thymus of the domestic fowl. *Acta Medica Universitatis Kagoshimaensis* **8**, 137–140.
- TERNI T (1929) Ricerche istologiche sull'innervazione del timo del sauropsi. *Zeitschrift für Zellforschung und mikroskopische Anatomie* **9**, 377–424.
- TORO I, OLAH I, ROHLICH P, VIRACH SZ (1969) Electron microscopic observations on myoid cells of frog's thymus. *Anatomical Record* **165**, 329–342.
- VAN DE VELDE RL, FRIEDMAN NB (1970) Thymic myoid cells and myasthenia gravis. *American Journal of Pathology* **59**, 347–367.