

## **Immunocytochemical localisation of tenascin during the development of scleral papillae and scleral ossicles in the embryonic chick\***

**D. M. FYFE, M. W. J. FERGUSON AND R. CHIQUET-EHRISMANN†**

*Animal Reproduction, Development and Growth Research Group, Department of Cell and Structural Biology, School of Biological Sciences, University of Manchester, Coupland III Building, Manchester, M13 9PL, England and †Fredrich Miescher Institut, Postfach 2543, CH-4002 Basel, Switzerland*

(Accepted 13 October 1987)

### INTRODUCTION

This paper reports the immunocytochemical distribution of tenascin in the development of the *anlagen* of scleral ossicles in the embryonic chick. Tenascin is an extracellular matrix glycoprotein with a disulfide bonded subunit of 240 KDa. While fibronectin and collagens Type I and III are ubiquitous in the mesenchyme of developing embryos e.g. in limb buds, the palate (Silver, Foidart & Pratt, 1981; Fyfe & Ferguson, 1988), dermal papillae of feathers (Mauger, Demarchez & Herbage, 1982) and teeth (Thesleff *et al.* 1981), tenascin has a restricted distribution in a variety of mesenchymal condensations e.g. around budding epithelia of developing organs such as hair follicles, tooth germs and mammary glands in addition to the palate (Fyfe, Ferguson & Chiquet-Ehrismann, 1988) and the perichondrial and tendinous *anlagen* in which this glycoprotein was first discovered (Chiquet & Fambrough, 1984; Chiquet-Ehrismann, Mackie, Pearson & Sakakura, 1986).

The eyes of most reptiles and all birds contain a ring of overlapping plates of membrane bones known as the scleral ossicles encircling the margin of the cornea (Walls, 1942). The primordium of each scleral ossicle arises as a condensation of mesenchymal cells of neural crest origin (Johnston *et al.* 1979) subjacent to a transient thickening of conjunctival epithelium known as a conjunctival or scleral papilla. In the chick, 14 papillae appear starting at 6 days of incubation (Hamburger & Hamilton, 1951 – Stage 29) in each eye overlying the sites of the 14 scleral ossicles. The first papillae to appear form over the ciliary arteries and the later papillae form around these until the ring of papillae is complete at 8 days of incubation (HH Stage 32) (Coulombre, Coulombre & Mehta, 1962; Ambrosi, Comasso & Roncali, 1972).

Each papilla undergoes a complex morphogenesis which Murray (1943) has divided into six convenient stages (see Fig. 1). At Stage 1, the conjunctival epithelium shows a slight thickening. At Stages 2–4, the papilla bulges downwards into the mesenchyme. The epithelium folds inwards at the edges of the papilla and the central area begins to elevate at Stage 4. At Stage 5, the papilla contains a core of mesenchymal cells within the elevated structure, in place of the central epithelial mass. At its final, 6th stage, the papilla has collapsed into a fine filament of epithelium on the eye surface. The mesenchyme has a uniform cell density beneath and between Stage 1 papillae. A

\* Reprint requests to Professor M. W. J. Ferguson.

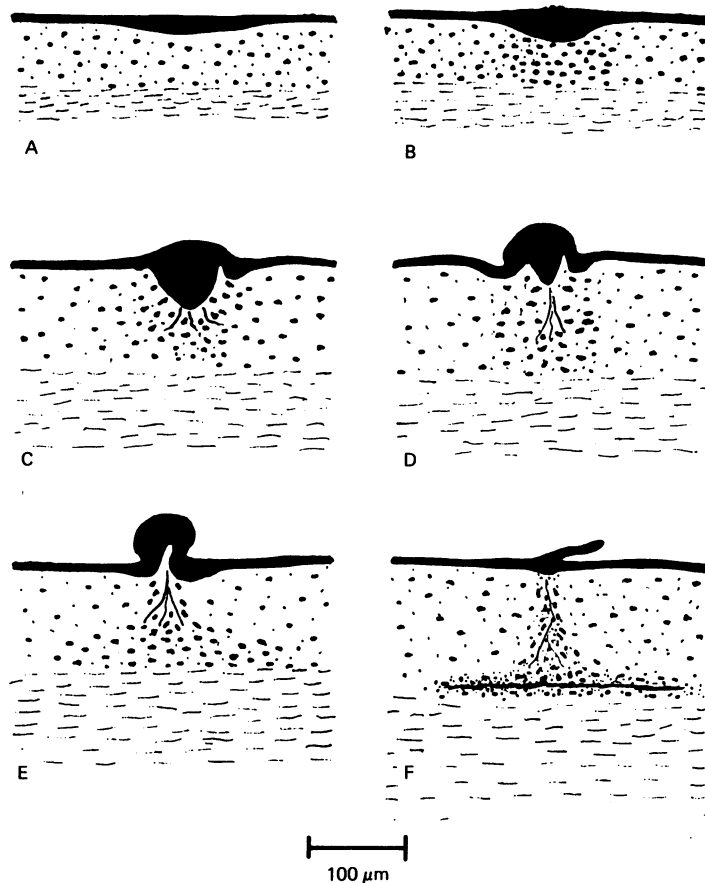


Fig. 1 (A-F). The sequence of six stages of papilla development redrawn from Murray (1943). The black upper surface of each block (A-F) represents conjunctival epithelium with the profile of the scleral papilla at the stages of transition from a placode to an intrusion into the mesenchyme and finally to a filament on the surface of the eye. The concentration of dots represents the development of a mesenchymal condensation (area of tight cell packing) in the epifibrous sclera - the tissue underlying the papilla. The diagrams C-F show the fine vertical lines extending from the basal surface of the papilla into the mesenchyme as included in Murray's (1943) schematic diagrams to represent fibrils which he described as "descending collagenous strands." The layers of mesenchyme represented are termed the 'epifibrous sclera' (the area containing dots) and the fibrous sclera (the area containing horizontal lines).

mesenchymal condensation is recognisable in histological sections subjacent to the Stage 2 papilla (Murray, 1943). In histological sections cut through Stage 4 and 5 papillae in a plane perpendicular to the front of the eye, this condensation has the profile of a column of tightly packed, predominantly vertically orientated cells extending from the basal surface of the papilla to the fibrous sclera. At Stage 6, there is still a column of vertically orientated cells extending internally from the papilla to the fibrous sclera. At the internal extent of this column there is now a flat condensation lying just above and parallel to the fibrous sclera which is the *anlage* of the scleral ossicle. Osteogenesis commences at 11 days of incubation just as the papillae go through their final degenerative stage and as the column of vertically orientated cells between the papilla and the ossicular bed disappears. Murray (1943) observed fibrils of material which he called "descending collagen strands" originating at the basal

surface of the papilla as early as Stage 2. In his analysis of Stage 6 papillae he showed that fibrils descended internally from the papilla, through the column of condensed cells which were orientated vertically among the fibrils, to the *anlage* of the scleral ossicle where they fanned out and became continuous with the newly formed osteoid. Since there have been no immunocytochemical investigations of the extracellular matrix (ECM) composition beneath papillae to extend the pioneering histological studies (Murray, 1943; Coulombre, Coulombre & Mehta, 1962; Puchkov, 1965; Van de Kamp, 1968) we were particularly interested to determine whether tenascin was localised in the condensations preceding ossicle formation. Therefore, we analysed the distribution of tenascin using a polyclonal antibody raised against the tenascin molecule (Chiquet-Ehrismann *et al.* 1986) and indirect immunofluorescence in the various developmental stages of papillae and their subjacent condensations.

#### MATERIALS AND METHODS

Chick embryos were incubated at 37.5 °C for 6–12 days and staged according to the criteria of Hamburger & Hamilton (1951). To reduce anatomical variability due to the sequential development of groups of papillae, explants were taken from the area where the first group of papillae formed i.e. in the region of Papilla 12 overlying the temporal long ciliary artery after Coulombre *et al.* (1962). The blocks of the eye wall including the three papillae adjacent to the temporal ciliary artery and the subjacent mesenchyme were excised in Hanks balanced salt solution. The tissue was embedded in O.C.T. compound at 4 °C and immediately immersed in cold isopentane and snap frozen in liquid nitrogen. The blocks were sectioned at 7–8  $\mu\text{m}$  using a Leitz cryostat and mounted on clean glass slides. The specimens were incubated for 30 minutes with polyclonal antisera raised in rabbits and diluted 1:200 (Chiquet-Ehrismann *et al.* 1986) and then washed with phosphate-buffered saline (PBS). After a second incubation with fluorescein-conjugated sheep anti-rabbit secondary antibody (Serotec) and further washing with PBS, the specimens were mounted under coverslips with glycerol containing PBS and 1,4 diazobicyclo-(2,2,2) octane (Johnson *et al.* 1982) (DABCO) to inhibit fading. Sections were examined under incident light fluorescence (Ploempak) with suitable FITC filters using a Leitz Orthoplan fluorescence microscope and photographed using Ektachrome ASA 160 slide film from which black and white prints were made. Incubation of sections with pre-immune serum and appropriate secondary antibody revealed no staining: pre-incubation of the antiserum with tenascin but not fibronectin abolished the staining patterns.

#### RESULTS

The scleral mesenchyme has two layers which are distinct from Stage 1 of papilla development throughout all the stages investigated here. The mesenchyme adjacent to the subsurface of the papilla has a loose stroma and is termed the epifibrous sclera (Puchkov, 1965). The inner mesenchymal layer adjacent to the pigmented epithelium has a dense stroma with tightly packed horizontal connective tissue and is known as the fibrous sclera (Murray, 1943). The mesenchymal condensations form within the epifibrous sclera (see Fig. 1) giving rise to the scleral ossicles forming just above the fibrous sclera, whereas the fibrous sclera gives rise to the scleral cartilage in addition to muscle and connective tissue (Johnston *et al.* 1979).

*Stages 1–2 of papilla development (Fig. 2)*

At Murray's Stages 1–2 of papilla development in HH Stage 29–30 embryos tenascin was not detectable in the epithelium (as it was at all stages examined in this study) and there was a very sparse distribution of randomly orientated fine fibrils of tenascin in the epifibrous sclera. No tenascin was evident in the putative mesenchymal condensation at this stage, which corresponds to the earliest appearance of an increased cell density in the sub-papillary mesenchyme (Murray, 1943). There was a slight accumulation of tenascin along the epithelial-mesenchymal interface of the papilla at these stages. No extensive vertical tenascin fibrils were evident in the mesenchyme. There were tightly packed horizontal fibrils of tenascin throughout the fibrous scleral layer making its boundary with the epifibrous layer distinctive as the latter has sparse tenascin fibrils (Fig. 2). The appearance of tightly packed tenascin fibrils in the fibrous sclera continued throughout all the stages of specimens (up to HH Stage 37) examined in this study. Interestingly, the fibrous sclera develops scleral cartilage starting at HH Stage 32, whereas the epifibrous sclera does not form cartilage.

*Stage 3 of papilla development (Figs. 3, 4)*

At Stage 3 of papilla development (Figs. 3, 4) (in HH Stage 31–32 embryos), tenascin staining was not observable in the epifibrous mesenchyme subjacent to the unthickened epithelium between papillae. On the basal surface of the epithelial tongue extending into the mesenchyme there was intense staining for tenascin. Several vertical strands extended to distances of up to 20  $\mu\text{m}$  into the mesenchyme in sections at the centre of the papilla. There was a slightly denser distribution of fine tenascin fibrils, randomly distributed in the condensation area, under the papilla than in the surrounding area. The boundary between the epifibrous and fibrous sclera was distinctive with the higher concentration of tenascin fibrils in the latter area.

*Stage 4 of papilla development (Figs. 5, 6)*

The distribution of tenascin extending from the subsurface of the papilla through the area of the mesenchymal condensation was essentially the same as in the previous stage. There were fine branching filaments of tenascin in an 8  $\mu\text{m}$  basal layer of the papilla adjacent to the epithelial-mesenchymal interface. It looked as if there was a fuzzy accumulation of tenascin on each side of the basement membrane (Fig. 6) suggesting that tenascin was present in the most basal epithelial cells of the papilla. This accumulation was not seen at the unthickened epithelium away from the papilla or at any other stage of papilla development.

There was faint granular staining in Stage 3 and 4 papilla which was definitely not

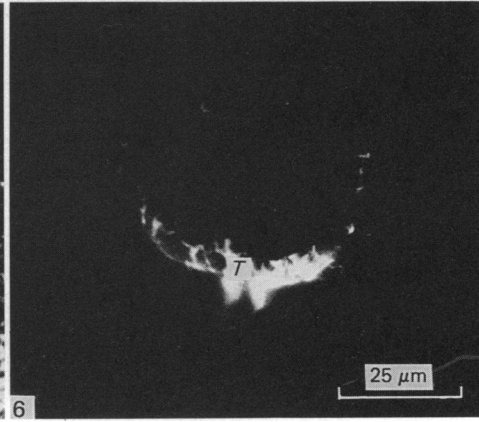
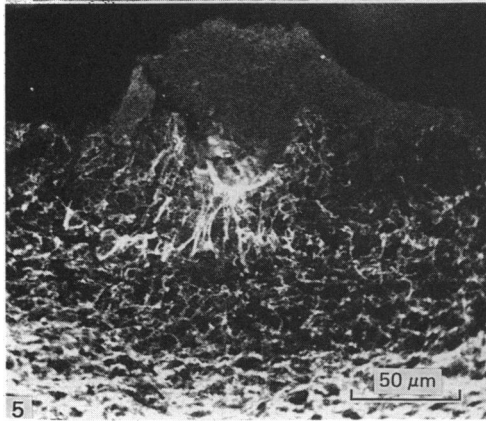
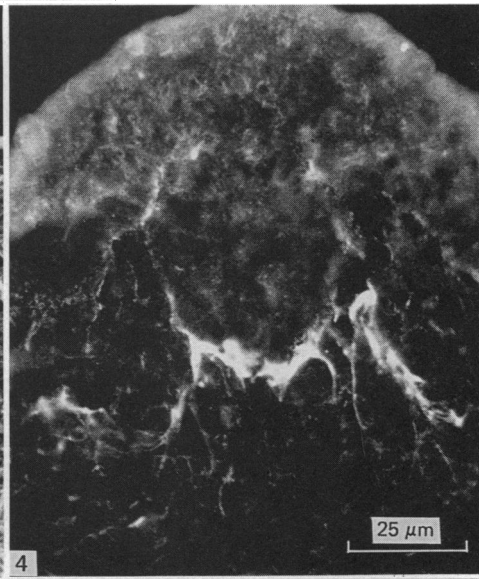
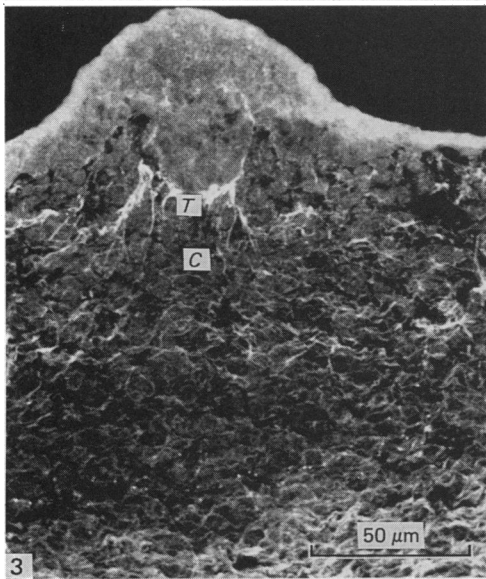
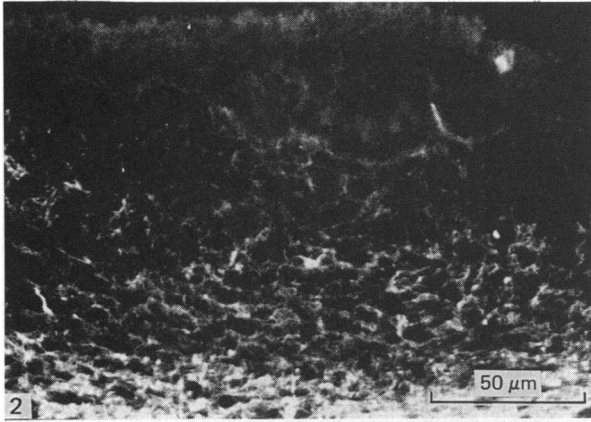
Fig. 2. Immunolocalisation of tenascin in the sclera at HH Stage 30 (7 days of incubation). The Stage 2 papilla has a slight accumulation of tenascin along its epithelial-mesenchymal interface with no extensive vertical tenascin fibrils in the subjacent mesenchyme as at later stages.

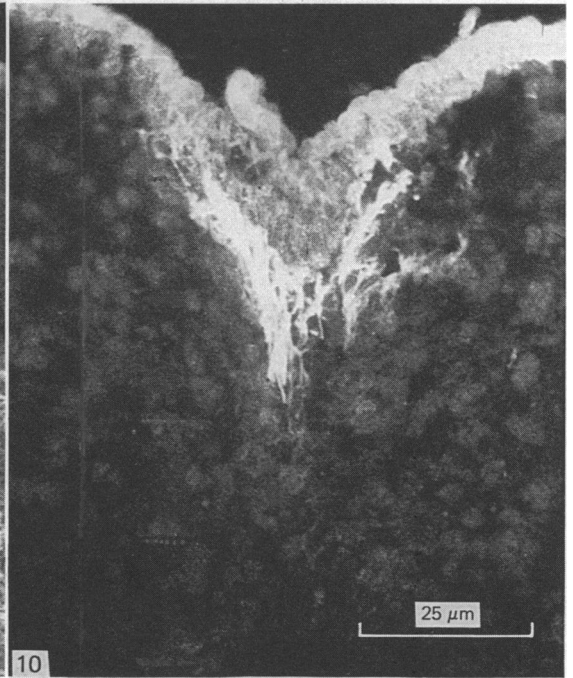
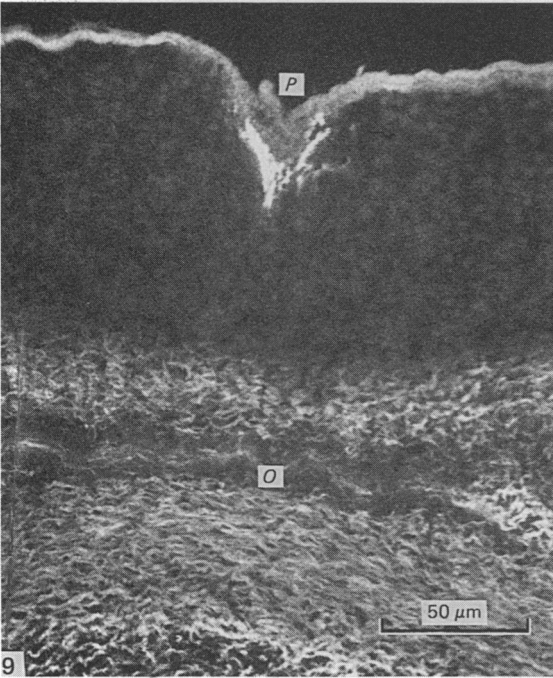
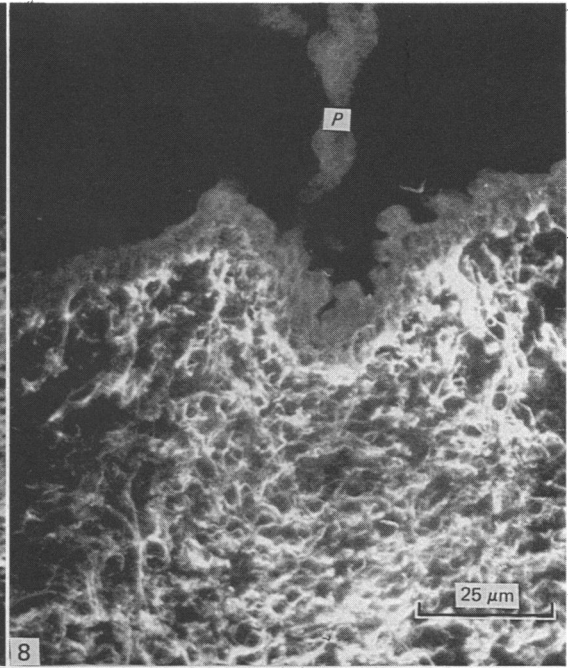
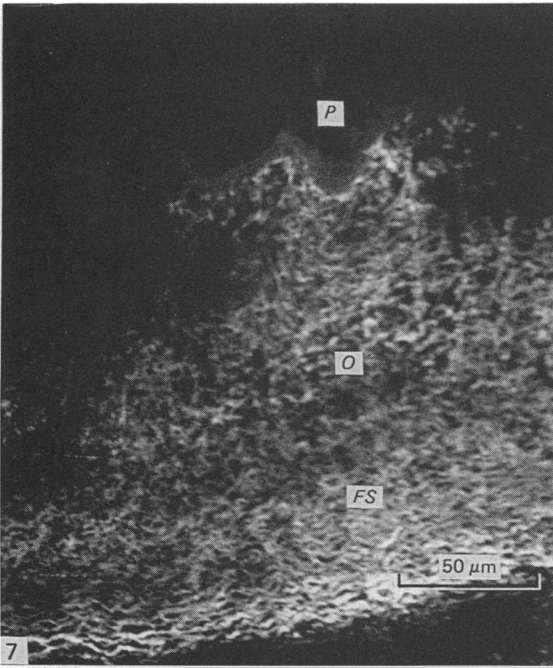
Fig. 3. Immunolocalisation of tenascin in the sclera at HH Stage 32 (8 days of incubation). The papilla is at Stage 3 and tenascin fibrils (*T*) are concentrated along the subsurface of its epithelial mass. The fibrils extend into the mesenchyme where a mesenchymal condensation (*C*) forms.

Fig. 4. A high magnification view of the specimen in Fig. 3 showing the accumulation of tenascin on the subsurface of the papilla's epithelial mass.

Fig. 5. Immunolocalisation of tenascin in the sclera at HH Stage 32 (8 days of incubation) showing a Stage 4 papilla. Note the fuzzy accumulation of tenascin possibly extending into the basal epithelial layer of the papilla and also the extension of strands of tenascin through the subjacent mesenchyme.

Fig. 6. A high magnification view of the specimen in Fig. 5. Tenascin fibrils appear to extend onto the basal layer of the papilla's epithelial mass at *T*.





fibrillar, and which was also evident in sections which were exposed only to secondary antibody, suggesting that this was non-specific fluorescence.

#### Stage 5 of papilla development

The Stage 5 papilla was elevated above the eye surface and contained a core of mesenchymal cells. There was no fuzzy accumulation of tenascin-positive material along the basal surface of the interior of the papilla as at previous stages. From the core of the papilla, vertical fibrils of tenascin extended into the mesenchyme where they reached at least 50  $\mu\text{m}$  into the area of the mesenchymal condensation. Thus tenascin was concentrated in the area of the mesenchymal condensation and subsurface of the Stage 5 papilla within the epifibrous sclera.

#### Stage 6 of papilla development (Figs. 7–10)

At early Stage 6 of papilla development (Figs. 7, 8) in HH Stage 36 embryos, brightly staining fibrils were localised beneath the papilla and extended into a column and into the area of the putative mesenchymal condensation with a similar profile to that seen at Stage 5 except the column seemed somewhat narrower beneath the papilla. The column was continuous from the papilla to the boundary with the fibrous sclera. In the most mature specimens examined (HH Stage 37 embryos) (Figs. 9, 10) wherein the papillae had just disappeared from the surface, the column of tenascin staining between the papilla and the fibrous sclera had disappeared. There were numerous tightly packed tenascin fibrils descending at the subsurface of the remains of the papilla; however these no longer extended to the level of the fibrous sclera. Osteoid appeared around the ossicle *anlage*; there was a halo of tenascin staining surrounding the plate of developing osteoid, over 100  $\mu\text{m}$  deep in the epifibrous sclera and just overlying the boundary with the fibrous sclera. Thus between early Stage 6 and completion of Stage 6 in papilla development, tenascin staining disappeared from the epifibrous sclera between the papilla and the ossicle *anlagen* except for the fibrils remaining connected to the subsurface of the papilla.

### DISCUSSION

Tenascin has been localised in many systems during the period of mesenchymal cell accumulation in condensations: e.g. hair, teeth, mammary glands, skeletal derivatives and the palate (Chiquet-Ehrismann *et al.* 1986; Fyfe *et al.* 1988).

Previous investigations of extracellular matrix in the sclera from the first appearance of the scleral papillae to the formation of the scleral ossicles have been confined to histochemical and ultrastructural studies. Murray (1943) in examining histological sections of eyes between 7 to 12 days of incubation, described fine aniline-positive

---

Fig. 7. Immunolocalisation of tenascin in the sclera at HH Stage 36 (10 days of incubation). With the papilla (*P*) at Stage 6, there is a column of tenascin fibrils extending from the papilla's subsurface to the area of the ossicular anlagen (*O*) above the fibrous sclera (*FS*).

Fig. 8. A high magnification view of the tenascin fibrils localised along the basal surface of the Stage 6 papilla (*P*) in Fig. 7 and extending in a column towards the ossicular anlagen.

Fig. 9. Immunolocalisation of tenascin in the sclera at HH Stage 37 (12 days of incubation). Note the concentration of tenascin fibrils extending about 20  $\mu\text{m}$  internally from the subsurface of the late Stage 6 papilla (*P*). The epifibrous mesenchyme underlying the unthickened conjunctival epithelium on either side of the papilla shows an absence of tenascin. The scleral ossicle (*O*) has formed in a bed about 100  $\mu\text{m}$  from the surface.

Fig. 10. A high magnification view of the tenascin fibrils localised beneath the Stage 6 papilla shown in the previous Figure.

fibrils confined to the subpapillary region as "collagenous strands". The strands extending into the mesenchyme from the basal papilla surface were vertical and more intensely stained than the predominantly horizontal aniline-positive fibres in the surrounding stroma. Murray (1943) described the "descending fibres" as extending from the base of the Stage 6 papilla through the subjacent mesenchyme to the pre-ossicular plate. Since Coulombre *et al.* (1962) traced fibres in the same area, staining positively with PAS stain, and Van de Kamp (1968) found numerous banded fibrils with an interval periodicity of 60  $\mu\text{m}$  in channels open to the mesenchyme along the subsurface of Stage 4 papillae, it has been widely accepted that Murray's "descending fibres" were in fact collagen (Van de Kamp & Hilfer, 1985). As previously found by Von der Mark, Von der Mark, Timpl & Trelstad (1977) in the stroma of the corneal limbus and as found in unpublished studies of the papilla-ossicle system in our laboratory, fibronectin and collagen Type I are densely distributed throughout the stroma and are not particularly concentrated beneath the papillae at any of the developmental stages. However, Van de Kamp & Hilfer (1985) went so far as to suggest that the collagenous strands beneath the papillae have a role in determining the location of the scleral ossicles. Based on the restricted distribution of tenascin in these areas, it, rather than collagen, may have a role in determining the location of scleral ossicles.

Murray (1943) reported the appearance of the condensations during Stage 2 of papilla development, a stage when we saw sparse tenascin fibrils throughout the epifibrous sclera and only a slight accumulation along the epithelial mesenchymal interface. Interestingly, tenascin fibrils were noticeably concentrated beneath the Stage 3 and 4 papillae when the mesenchymal condensation is clearly recognisable in contact with the papilla's basal surface. The tenascin fibril localisation was most distinctive when the mesenchymal condensation was maximal. The Stage 5 and early Stage 6 papillae had a column of tenascin fibrils extending beneath the papillae to the ossicular bed. When the ossicular bed was undergoing differentiation into membrane bone, with the appearance of osteoblasts in a bony matrix, the tenascin column disappeared and there remained an accumulation of tenascin beneath the site of the papillae. Thus, the change in distribution of tenascin corresponds very closely with the time of development of the pre-ossicular condensation.

Hall (1982) suggested that the development of skeletal derivatives of condensations (cartilages and membrane bones) depends on a threshold number of mesenchymal cells accumulating in the preceding condensations. The role of tenascin in pre-ossicular condensation formation could be either in promoting mitosis or migration so as to accumulate sufficient cells for osteogenesis.

Various studies have demonstrated the regional differences in mitosis associated with the development of the condensations beneath the papillae. The condensing mesenchyme, corresponding to the area of tenascin accumulation beneath Stage 3-6 papillae, has a significantly higher mitotic index than the mesenchyme overlain by the unthickened epithelium (Hale, 1956; Fyfe & Hall, 1983; Van de Kamp & Hilfer, 1985; Fyfe, 1986). Furthermore, the mitotic index peaks in the mesenchyme in contact with the subsurface of the Stage 6 papilla (Fyfe, 1986) when the tenascin fibrils appear most prominent in the same area. Also, Fyfe & Hall (1983) showed there was a halo of dividing cells around the newly formed plate of osteoid while proliferation ceased in the bony *anlagen*. We saw a halo of tenascin around the ossicular plate which corresponded to this area of dividing cells.

Experimental evidence for migration as a mechanism for accumulation of cells in



the condensations in the ossicular beds is lacking. While the stromal fibroblasts have a predominantly horizontal orientation between papillae, the mesenchymal cells directly beneath each papilla are orientated vertically at Stage 5 and 6 (Murray, 1943; Puchkov, 1965; Van de Kamp, 1968; Van de Kamp & Hilfer, 1985). This was interpreted as evidence of internally directed mesenchymal cell migration along or between the "descending collagen strands" (Murray, 1943; Van de Kamp, 1968). These investigators thought that additional evidence for internal migration was provided by the dispersal of necrotic debris from the subsurface of the degenerating papilla to the depth of the ossicular bed along the length of the "descending strands". Particle movement was hypothesised to be due to displacement by migrating cells (Van de Kamp, 1968). Carbon particles placed on the surface of the Stage 2-5 papillae are phagocytosed by fibroblasts or remain extracellular and in either case reach the depth of the ossicular bed within a period of three days *in vivo* (Fyfe, 1986). Thus the tissue beneath the papilla, with localised tenascin as one known matrix component, may promote particle translocation and cell migration in a similar way to the neural crest pathway supporting "matrix driven translocations" of latex beads and neural crest cell migration (Bronner-Fraser, 1982, 1984).

As the papilla's internal tongue of epithelial cells disappears between Stages 4 and 5, mesenchymal cells ultimately extend into the core of the elevating papilla while the margins of the papilla fold. Mesenchymal cells within the core of Stage 5 papillae have ruffled cytoplasmic processes (pseudopodia) on the externally directed surfaces so these cells could be migratory (Fyfe, 1986). Tenascin fibrils extend into the core of the Stage 5 papilla and so might be involved in influencing the movement of subjacent mesenchymal cells into the papilla at this stage.

Tenascin fibrils appear to cross the epithelial-mesenchymal interface so that there are tiny filaments in the basal layer of the Stage 3 and 4 papillae adjacent to the basement membrane region. There is also evidence that tenascin fibrils accumulate along, and infiltrate, the basement membrane in the medial epithelial seam of the mouse palate just before this breaks down prior to palatal closure (Fyfe *et al.* 1988). Does the tenascin accumulation on the subsurface of the Stage 4 papilla play any role in the reduction of the internal epithelial mass of the papilla? The highest concentration of tenascin in the mouse secondary palate is in the mesenchyme at the medial edges of the palatal shelves before and during the breakdown of the epithelial seam (Fyfe *et al.* 1988). The epithelial seam in the palate breaks down by programmed cell death, lysosomal activity and dispersal of the debris and individual epithelial cells into the mesenchyme (Fyfe & Ferguson 1988; Hall & Ferguson, 1988). In this system tenascin could promote dispersal of the debris or cell migration out of the seam. The papilla is also a centre of programmed cell death as shown by its build-up of necrotic cells and lysosomal vacuoles as its mass reduces during Stage 4 (Murray, 1943; Van de Kamp, 1968; Fyfe, 1986). The dead papillary cells from the internal mass at Stage 4 disperse in the area corresponding to tenascin filament localisation in the mesenchymal condensation (Van de Kamp, 1968). In addition, the interruption of the subpapillary basement membrane with protrusion of epithelial cells into the extracellular spaces of the mesenchyme could signify that some cells from the papilla migrate into the mesenchyme (Fyfe, 1986) having become fibroblastic, like the cells dispersing from the palatal epithelial seam (Fyfe & Ferguson, 1988). Both the medial epithelial seam of the mouse palate and the internal mass of the papilla disappear within a surprisingly short time of 12 hours or less (Fyfe *et al.* 1988; Fyfe, 1986). Since we found a localised distribution of tenascin beneath maturing scleral papillae, we speculate that

this molecule could influence the epithelial-mesenchymal interaction, cell death in the papilla, dispersal of dead or migrating papilla cells and accumulation of mesenchymal cells in the ossicular condensation either by localised mitosis or cell migration.

#### SUMMARY

We have used a polyclonal antibody against tenascin (a 240 kDa extracellular matrix glycoprotein) and indirect immunofluorescence to investigate the distribution of tenascin in cryostat sections of the chick sclera during the six stages of scleral papilla development (Murray, 1943) and formation of membrane bone *anlagen* (mesenchymal condensations between 6–12 days of incubation – HH Stage 29–37). At Stages 1 and 2, when the papilla was a slight thickening in the conjunctival epithelium and mesenchymal condensation formation was initiated, tenascin was sparse in the sclera. At Stage 3, when the papilla had an epithelial mass intruding into the mesenchyme, there was an accumulation of tenascin fibrils along the subsurface of the papilla with fibrils extending from this region into the mesenchymal condensation. Interestingly, tenascin was sparse between papillae and between mesenchymal condensations. The Stage 4 papilla had a similar localisation of tenascin fibrils and in addition fine arborising fibrils of tenascin were observed within the basal epithelia of the papilla adjacent to the epithelial-mesenchymal interface (which suggested that the fibrils infiltrated through the basement membrane region). The Stage 5 and 6 papillae had a column of vertical tenascin fibrils extending from the subsurface of the papilla to the interior mesenchyme corresponding exactly to the location of the mesenchymal condensation which was then forming the *anlage* of the ossicle in a flat bed about 100  $\mu\text{m}$  from the conjunctival surface. The column of tenascin disappeared as the osteoid appeared in the ossicular bed on the 12th day of incubation but a dense accumulation of tenascin remained along the subsurface of the papilla. With the exception of tenascin fluorescence in the basal region of the Stage 4 papilla, tenascin fibrils were not observed in the other stages of papilla development in the epithelium covering areas between the mesenchymal condensation. This restricted distribution of tenascin may be important in the morphogenesis of scleral papillae and scleral ossicles.

#### REFERENCES

- AMBROSI, G., COMOSSO, M. E. & RONCALI, L. (1972). Morphological data regarding conjunctival papillae and scleral ossicles in the chick embryo. *Bollettino della Società italiana di biologia sperimentale* **49**, 135–140.
- CHIQUET, M. & FAMBROUGH, D. M. (1984). Chick myotendinous antigen. I. A monoclonal antibody as a marker for tendon and muscle morphogenesis. *Journal of Cell Biology* **98**, 1926–1936.
- CHIQUET-EHRISMANN, R., MACKIE, E. J., PEARSON, C. A. & SAKAKURA, T. (1986). Tenascin: an extracellular matrix protein involved in tissue interactions during fetal development and oncogenesis. *Cell* **47**, 131–139.
- COULOMBRE, A. J., COULOMBRE, J. L. & MEHTA, H. (1962). The skeleton of the eye, I Conjunctival papillae and scleral ossicles. *Developmental Biology* **5**, 382–401.
- BRONNER-FRASER, M. E. (1982). Distribution of latex beads and retinal pigmented epithelial cells along the ventral neural crest pathway. *Developmental Biology* **91**, 50–63.
- BRONNER-FRASER, M. E. (1984). Latex beads as probes of neural crest pathway. The effects of laminin, collagen and surface charge on bead translocation. *Journal of Cell Biology* **98**, 1947–1960.
- FYFE, D. M. (1986). An analysis of the development of the scleral ossicle system in the eye of the chick embryo. Ph.D. thesis, University of Aberdeen.
- FYFE, D. M. & HALL, B. K. (1983). The origin of the ectomesenchymal condensations which precede development of the bony scleral ossicles in the eyes of embryonic chicks. *Journal of Embryology and Experimental Morphology* **73**, 69–86.
- FYFE, D. M. & FERGUSON M. W. J. (1988). Immunocytochemical localisation of collagens types I–XII, proteoglycans, laminin and fibronectin during mouse secondary palate development. *Developmental Biology* (In the Press.)

- FYFE, D. M., FERGUSON, M. W. J. & CHIQUET-EHRISMANN, R. (1988). Immunocytochemical localisation of tenascin during mouse secondary palate development. *Anatomy and Embryology* (In the Press.)
- HALE, L. J. (1956). Mesodermal activity during early differentiation of the scleral bones of the chick. *Quarterly Journal of Microscopical Science* **97**, 333–353.
- HALL, B. K. (1982). The role of tissue interactions in the growth of bone. In *Factors and Mechanisms Influencing Bone Growth* (ed. A. D. Dixon & B. G. Sarnat), pp. 205–215, New York: Alan R. Liss Inc.
- HALL, K. & FERGUSON, M. W. J. (1988). Ultrastructure of the epithelial-mesenchymal interface during mouse secondary palate development. *Anatomy and Embryology* (In the Press.)
- HAMBURGER, V. & HAMILTON, H. L. (1951). A series of normal stages of development of the chick embryo. *Journal of Morphology* **88**, 49–92.
- JOHNSON, G. D., DAVIDSON, R. S., MCNAMEE, K. C., RUSSELL, G., GOODWIN, D. & HOLBOROW, E. J. (1982). Fading of immunofluorescence during microscopy: a study of the phenomenon and its remedy. *Journal of Immunological Methods* **55**, 231–242.
- JOHNSTON, M. C., NODEN, D. M., HAZELTON, R. D., COULOMBRE, J. L. & COULOMBRE, A. J. (1979). Origin of avian ocular and periocular tissue. *Experimental Eye Research* **29**, 27–45.
- MAUGER, A., DEMARCHEZ, M. & HERBAGE, D. (1982). Immunofluorescent localization of types I and III and of fibronectin during feather morphogenesis in the chick embryo. *Developmental Biology* **94**, 93–105.
- MURRAY, P. D. F. (1943). The development of the conjunctival papillae and of the scleral bones of the embryo chick. *Journal of Anatomy* **77**, 225–240.
- PUCHKOV, V. (1965). Morphogenetic apparatus of the scleral ossicles of the chick embryo eye. (In Russian: translated into English by the Translating Unit, NIH Library; provided by Dr A. J. Coulombre). *Arkhiv anatomii, gistologii i émbriologii* **48**, 11–21.
- SILVER, M. H., FOIDART, J. & PRATT, R. M. (1981). Distribution of fibronectin and collagen during mouse limb and palate development. *Differentiation* **18**, 141–149.
- THESLEFF, I., BARRACH, H. J., FOIDART, J. M., VAHERI, A., PRATT, R. M. & MARTIN, G. (1981). Changes in the distribution of type IV collagen, laminin, proteoglycan and fibronectin during mouse tooth development. *Developmental Biology* **81**, 182–192.
- VAN DE KAMP, M. (1968). Fine structural analysis of the conjunctival papillae in the chick embryo: a reassessment of their morphogenesis and developmental significance. *Journal of Experimental Zoology* **169**, 447–462.
- VAN DE KAMP, M. & HILFER, S. R. (1985). Cell proliferation in condensing scleral ectomesenchyme associated with the conjunctival papillae in the chick embryo. *Journal of Embryology and Experimental Morphology* **88**, 25–37.
- VON DER MARK, K., VON DER MARK, H., TIMPL, R. & TRELSTAD, R. L. (1977). Immunofluorescent localisation of collagen types I, II and III in the embryonic chick eye. *Developmental Biology* **59**, 75–85.
- WALLS, G. L. (1942). *The Vertebrate Eye*. Bulletin, Cranbrook Institute of Science **19**, 1–785. Bloomfield Hills: The Cranbrook Press.