

THE GENITALIA OF TUPAIA. By FREDERIC WOOD JONES, *Professor of Anatomy in the University of London; The London School of Medicine for Women.*

MATERIAL.

THE species that I have dissected is *Tupaia ferruginea*; it is the one that is especially entitled to the native name "tupai tanch" in the Straits Settlements.

I have had the opportunity of dissecting two specimens, a male and a female, both of them fully adult. The condition of these two examples, which were preserved in spirit, is such that every confidence may be placed in the normal appearance of the parts described. The preservation rendered histological examination of the tissues quite satisfactory. For the use of this material I am indebted to the kindness of Dr Foster Cooper and Professor G. Elliot Smith. The specimens formed part of the collection of the Survey of the Vertebrate Fauna of the Malay Peninsula undertaken by the Federated Malay States Museum, and they were taken at Kuala Lumpur.

REPRODUCTION.

*Tupaia ferruginea* lives as a rule in pairs or as solitary individuals (Cantor); it does not associate in groups, a family party being the limit of community.

From one to three young are produced at a birth. Cantor describes the birth of a single offspring as the most usual occurrence with *T. ferruginea*; but Boden Kloss regards two as constituting a normal litter. Lyon gives a list of embryos examined in pregnant females, and in one case there were three present, but in others only one or two.

The birth of two young would seem to be the rule with *T. belangeri*, one with *T. nicobarica*, and as many as four with *T. chinensis* (Lyon).

The nesting habits of the Tupaiadæ have been described by a few observers. Boden Kloss has described the nest of *T. ferruginea*, which is placed in holes in trees or even in fallen stumps.

The nest of *T. chinensis* has been found in a hollow bamboo (Lyon).

Charles Hose has recorded the nesting of *T. minor* in Borneo: "It breeds in a nest in an old stump covered with creepers, but I am not sure

whether it makes the nest itself or occupies the nest of a bird. I have found two of these nests, but the material used was different."

I know of no observations upon the condition of the young at birth, nor upon the length of stay in the nest and the period of suckling. Breeding seems to take place throughout the year, but no observations appear to have been recorded upon the duration of gestation.

#### REPRODUCTIVE SYSTEM.

In a paper entitled "The Anatomy of *Tupaia*," Garrod made some slight notes upon the internal genitalia of the male *T. belangeri* in 1878.

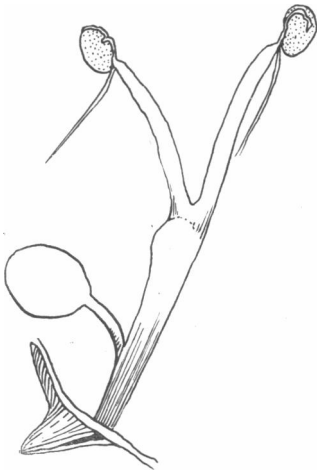


FIG. 1.—*Tupaia ferruginea*. Internal genitalia of adult female.

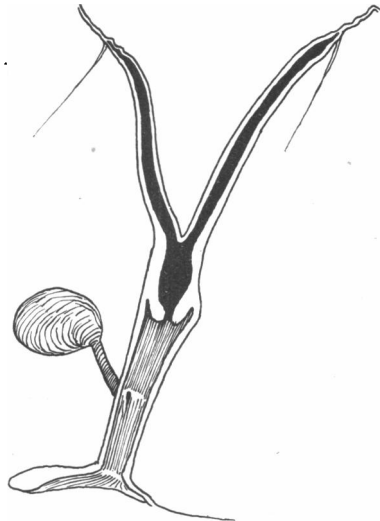


FIG. 2.—*Tupaia ferruginea*. Internal genitalia of adult female seen in section.

In 1914, Pehrson, in describing the ossicle in the clitoris of some Primates and Insectivores, makes brief mention of the condition of this structure in the female *T. javanica*. With the exception of these papers, I have, so far, encountered no published work upon the reproductive system of the Tupaias.

*Female* (see figs. 1 and 2).—The ovary was extremely small in my specimen; it was surrounded by a partial bursa. The cephalic ovarian ligament is but poorly developed; but the caudal ligament is well defined. The Fallopian tubes are narrow-bored and tortuous, and closely applied to the ovary, the ostium abdominale being within the ovarian capsule. The cornua of the uterus are elongated, and the body of the uterus is

comparatively small. Lyon, who records the number of embryos present in several pregnant females, does not state in what part of the uterus the pregnancy occurs, and it would be interesting to know if there is any specific variation in the site of foetal lodgment. A well-marked os uteri marks off the lower limits of the uterine cavity from the vagina. The vagina is a roomy thin-walled chamber, and measures 7 mmi. from os uteri to urogenital sinus. The urogenital sinus is longer than the vagina, and measures 9 mm.: it is distinctly marked off from the vagina above, but

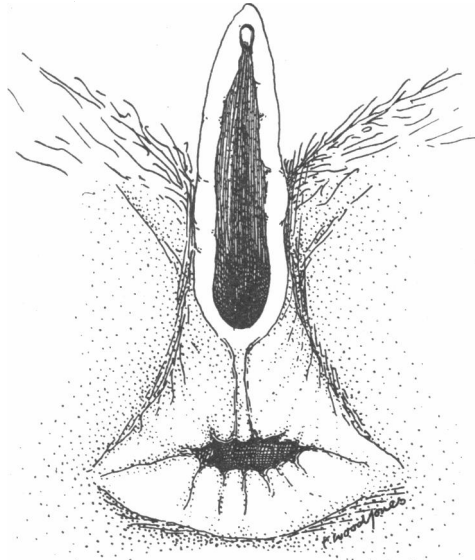


FIG. 3.—*Tupaia ferruginea*. External genitalia of adult female.

in my specimen no structure which can definitely be named a hymen is present below.

The whole urogenital sinus is smooth-walled, and covered with a shining mucous membrane. The urogenital sinus lies behind the elongated pubic symphysis.

The external genitalia of the female (see fig. 3) show several features which are worthy of note. The genital outlet is elongated in an antero-posterior direction, the total length of the orifice being 7 mm. The external genitalia can only be described as prominent. The very considerable extent of the vulval orifice is brought about by the prominence of the genital tubercle, and the structures embryologically associated with it.

The clitoris is free at its extremity, which is small and appears as a median elevation between the two prominent folds (inner genital folds) which, running from it, bound the sides of the vulval orifice and lead to the prominence of the part.

Behind the vulval orifice these inner genital folds meet in a definite commissure and thence proceed across the perineum as a median raphé (4 mm. in length) which terminates at the anal margin. Within the vulva, the mucous membrane is slightly folded in a radiating manner, the ridges upon the surface all converging upon the mouth of the urogenital sinus, which is situated at the extreme posterior limit of the vulva. The urogenital orifice is situated, therefore, very near to the anus, and the perineum is extremely short.

The region around the anus, and upon either side of the inner genital folds, is devoid of the general body hairs; there is, in the spirit specimen, no distinct trace of pigmentation, but sparse specialised sexual hairs are scattered over the whole region.

*Male.*—The general disposition of the internal genitalia of the male is shown in figs. 4 and 5, and but few points require further emphasis.

The entrance of the genital ducts into the urogenital tract is effected at the very considerable distance of 7 mm. from the site of opening of the ureters. For some considerable distance before they pierce the urethral wall, the genital ducts are in close contact with each other, but although their union is anatomically a very intimate one the tubes remain entirely separate until they open into the urethra.

In this part of their course they have placed upon either side of them, and behind them, bulky bilateral masses, which appear to the naked eye to be faintly subdivided into upper and lower portions. The line of demarcation is, however, but feebly delineated. Upon histological examination the upper portions of these masses prove to be complex vesiculæ seminales, while the lower portions compose the prostate. The prostate is strictly limited to these two postero-lateral masses, there being no gland tissue upon the anterior wall of the urethra, and none corresponding to the human third lobe. The common ejaculatory ducts open into the urethra, entirely separately, upon a slightly marked colliculus seminis, there being no common chamber, or uterus masculinus. The portion of urethra intervening between the site of opening of the genital ducts and the bulb is elongated: it runs behind the symphysis pubis, and measures 13 mm. in my specimen. It is wrapped round by an uninterrupted muscular coat (m. constrictor urethræ), and is enclosed in its entire extent between the two levator ani muscles, which form a muscle sheath common to it and to the lower part of the rectum.

The bulb of the urethra is prominent, the bulbar muscles constituting an exceptionally bulky mass. Two glandular bodies are placed upon either side of the bulbar muscles. The larger mass, situated cephalad, is 7 mm. in its long axis, and is dark yellow in colour. It presents all the histological features of the glandulæ bulbo-urethrales, its ducts open into the bulbar portion of the urethra, and these two bodies are therefore regarded as true Cowper's glands. The smaller mass measures 4 mm. in its long

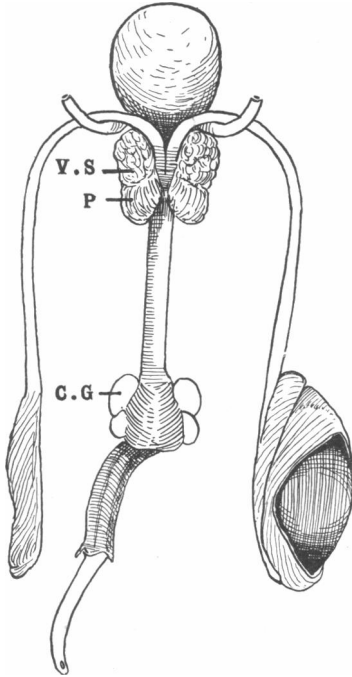


FIG. 4.—*Tupaia ferruginea*. Genitalia of the male viewed from behind.

V.S., vesiculæ seminales; P., prostate;  
C.G., Cowper's glands.

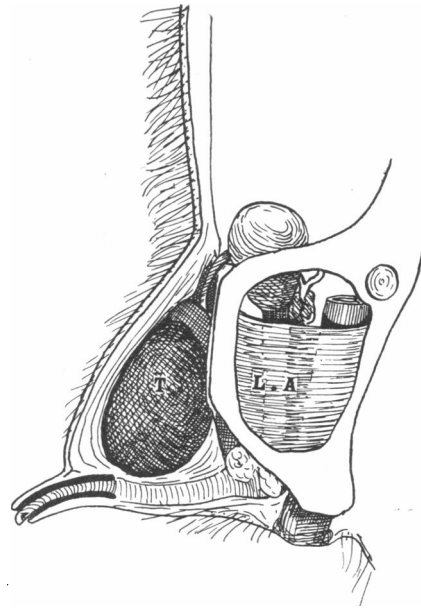


FIG. 5.—*Tupaia ferruginea*. Dissection of the male pelvis from the left side to show the relation of the scrotal pouch to the body of the penis.

T., right testes; L.A., levator ani.

axis; it is pale yellow, and is bound but loosely to the bulb, it being situated, in the undisturbed condition of the parts, in the interval between the rectum and the bulbar musculature. No duct opening of these glands into the urethra could be found in serial sections, and it is therefore most probable that they belong to the class of circumanal scent glands.

In my male specimen there was a very curious disproportion in the relative sizes of the two testes, for while that of the right side was large, measuring 15 mm. in its long axis and 9 mm. in breadth, the left one was

a mere fusiform mass of tissue. Histologically, the left testis appeared to be in a functionless condition, the testicular structure being extremely rudimentary; if this is a pathological feature, or merely a functional phase, I am unable to determine.

The epididymis is well developed. The total length of the right testis including the epididymis was 19 mm.

The tunica vaginalis extended no further than the upper pole of the testis, and no trace of a funicular process could be found, the isolation of the tunica vaginalis being as complete as in Man.

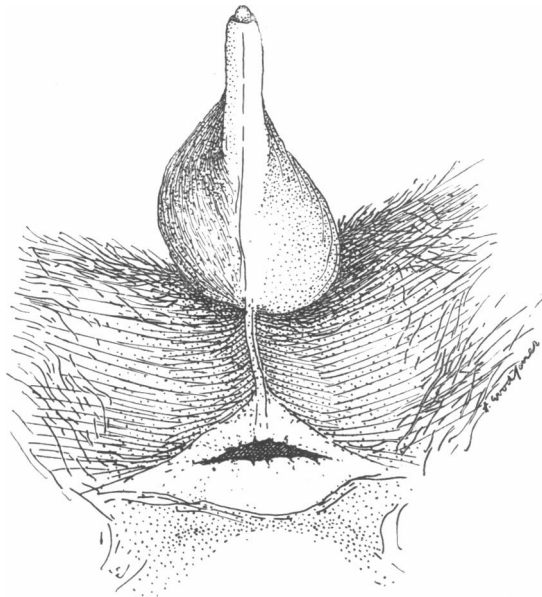


FIG. 6.—*Tupaia ferruginea*. Perineal view of the external genitalia of adult male.

The external genitalia of the male are of the greatest interest (see figs. 6 and 7). The penis is elongated, its total extra-pelvic course being 30 mm., and of this length 10 mm. consists of the fusiform glans. In the undisturbed condition of the parts, the tip of the glans protruded very slightly from the prepuce, the skin of which is finely wrinkled, and of a colour markedly lighter than the skin of the scrotal areas. A few fine down hairs arise from the base of the external surface of the prepuce. Owing to the curious disposition of the scrotal area, the penis, as it appears upon the external surface of the body, is abbreviated: the external surface of the prepuce measuring no more than 5 mm., whilst its internal surface is double that length.

The glans penis is thin and tapering; in the spirit-preserved specimen it is of a pale yellow colour, and is marked by fine transverse wrinkles. There are no projections from its surface, nor are there any visible glandular elevations or orifices. The opening of the urethra is sub-terminal and is situated upon the lower surface of the glans, presenting very much the appearance of the eyelet of a catheter. In my specimen no ossicle was present on the penis.

The most striking feature of the external genitalia of the male is the curious cephalic position of the scrotal pouches. Such a site of the scrotal area is unique among Eutherian Mammals. The testes are obviously

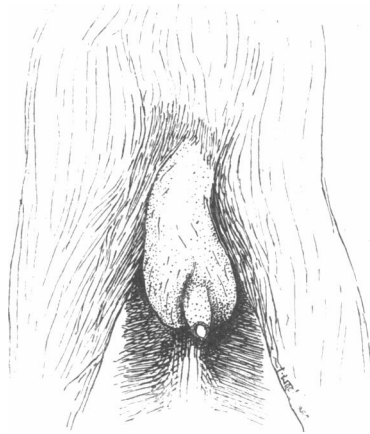


FIG. 7.—*Tupaia ferruginea*. Ventral view of external genitalia of adult male.

permanently descended, and they are lodged beneath skin pouches, having the well-defined characters of the area scroti, which are situated cephalic to the root of the penis. The site of testicular lodgment is not so far forward as it is in the Metatheria; but it occupies a strange position upon the cephalic aspect, and to the sides, of the body of the penis. Perhaps the best description of this peculiarity could be given by likening the scrotal area of the male to the position of the Mons Veneris in the female. In the Metatheria the testes are herniated into scrotal sacs situated cephalic to the site of the Mons Veneris area; in Eutheria, as a rule, into some site caudad of this area; but in *Tupaia* they have lodged within the area, and have depended slightly upon either side of the genital tubercle.

The skin of the scrotum is pigmented, and is considerably darker in colour than the skin of the surrounding districts. It gives rise to scattered hairs which are distinct from the body hair, and it is fine—almost shining—

in texture. There is a well-marked median raphé which extends along the body of the penis across the perineum and to the anal orifice.

#### MAMMARY GLANDS.

The female of *Tupaia ferruginea* possesses four nipples and mammary glands which, in my specimen, are all small and equal in development. They are situated upon the sides of the chest and abdomen as an anterior and a posterior pair. The anterior pair is separated by some 20 mm. from the axilla, and the posterior pair is 20 mm. behind the anterior pair, a slightly smaller interval separating the posterior pair from the region of the groin.

In *T. belangeri* there are three pairs, the additional pair being situated apparently between the thoracic and preinguinal pair of *T. ferruginea*. In *T. nicobarica* there is but one pair, which would appear to occupy the site of the thoracic pair of the other species. I have not examined these species, and I take the statements concerning the number of mammary glands from the paper by Lyon which has been quoted previously.

#### THE PELVIC SYMPHYSIS.

The ventral contact area between the two sides of the pelvis extends for a length of 7 mm., and so can only be described as long when the whole proportions of the pelvis are considered. This length of symphysis in so small an arboreal animal, at first sight, seems somewhat anomalous. But it must be remembered that *T. ferruginea* is best described as a bush animal rather than as a thoroughly arboreal one—and by this is implied that it is a haunter of undergrowth rather than of forest trees. The native name "tupai tanah" has regard to this habit, for it means ground squirrel, and is used to distinguish the animal from the true Squirrels, which live in the tree tops. There is a characteristic of this species which I observed in Singapore, that if Squirrels and Tupaia are met in undergrowth, the Squirrels take to the trees when alarmed, but the Tree Shrews make for the ground. Their arboreal activities are well developed, but the tree tops are not their home, nor even the retreat to which they betake themselves in danger. *Tupaia ferruginea* is an arboreal adventurer rather than an elaborated arboreal animal; but it appears, from written accounts, that other Tree Shrews, and especially *Ptilocercus*, have advanced further than this in arboreal life, and I should imagine that in them the area of symphysis would be shorter, and that corresponding differences would be present in the internal genitalia; but I know of no account by which to confirm, or disprove, this supposition.



## PLACENTATION.

I have not been able to find any description of the placentation of *Tupaia*, but it seems reasonable to assume, as apparently zoological authorities do, that it is of the type usual among the Insectivora. This assumption is the more justified since Lyon records the condition of several pregnant females without making any note upon the embryo, membranes, or placenta.

## SUMMARY AND CONCLUSIONS.

The genitalia of this animal exhibit an extraordinary blend of characters, since combined with features which are distinctly reminiscent of the Metatheria are conditions which find their exact parallels in the Primates.

In the internal genitalia, the length of the urogenital sinus in the female is correlated with the length of the wrongly-named "membranous portion of the urethra" in the male; and both features, I imagine, are the direct result of the length of the ventral pelvic symphysis.

Concerning the external genitalia, there can be no doubt that development has taken place by cloacal outfolding. The main features of the external genitalia may be summed up by saying that the female condition is singularly like that seen in many Primates, and that the male has several features which are found again in the higher Primates, combined with a scrotal disposition which seems obviously a transition phase from a Metatherian stage.

## REFERENCES.

- (1) CANTOR, THEODORE, "Catalogue of Mammalia inhabiting the Malayan Peninsula and Islands," *Jour. Asiatic Soc. Bengal*, vol. xv., 1846, p. 189.
- (2) GARROD, "The Anatomy of *Tupaia*," *Proc. Zool. Soc. Lond.*, 1879, p. 301. The account relates to *T. belangeri*.
- (3) GREGORY, W. K., "The Orders of Mammals," *Bull. American Mus. Nat. Hist.*, vol. xxvii., 1910.
- (4) HOSE, C., *A Descriptive Account of the Mammals of Borneo*, 1893.
- (5) LYON, MARCUS WARD, JR., "Tree Shrews: an Account of the Mammalian Family Tupaiadæ," *Smithsonian Institute, U.S., Nat. Mus. Proc.*, vol. xlv., 1913, pp. 1-188. Contains an exhaustive account of specific characters of the family.
- (6) PEHRSON, VON TORSTEN, "Beiträge zur Kenntniss der äuboren weiblichen Genitalien bei Affen, Halbaffen und Insectivoren," *Anat. Anzeig.*, April 20, 1914, p. 174.
- (7) THOMAS, O., and WROUGHTON, R. C., *Jour. Federated Malay States Mus.*, vol. iv, No. 1, p. 111, Dec. 1904. Contains descriptions of collections by Robinson, Seimund, and Boden Kloss.
- (8) BODEN KLOSS as above, p. 175.