

## The cellular response to nerve injury

### 1. The cellular outgrowth from the distal stump of transected nerve

By P. K. THOMAS

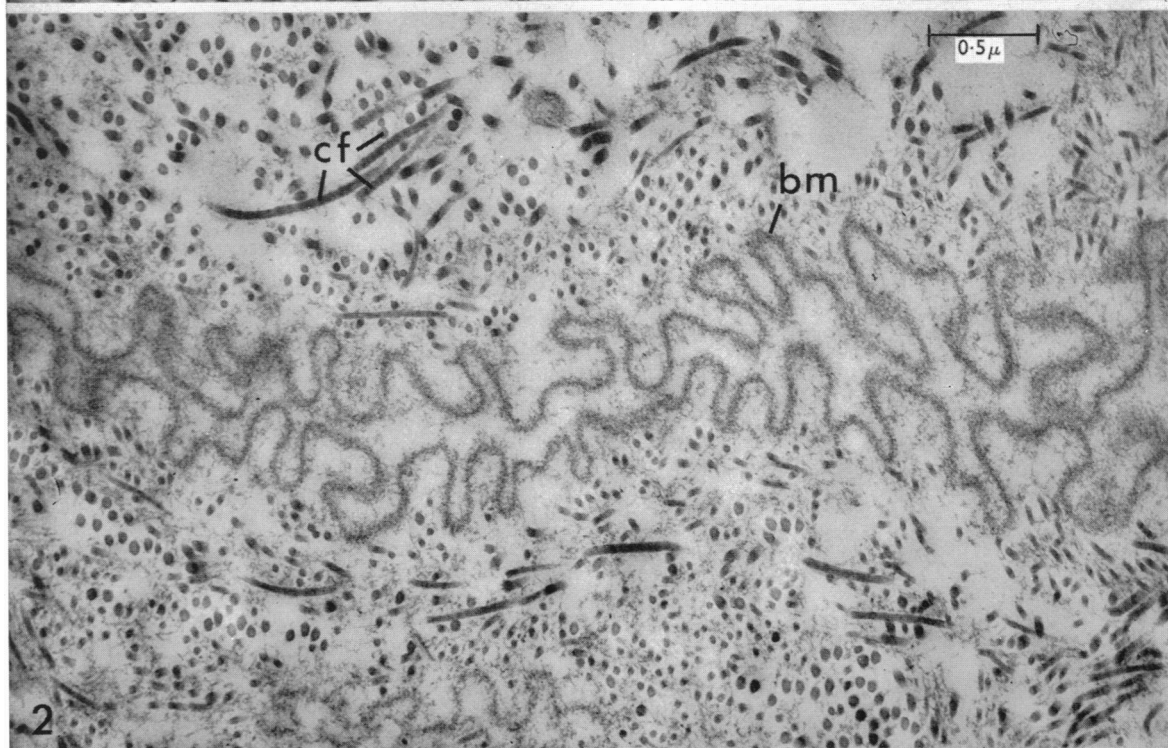
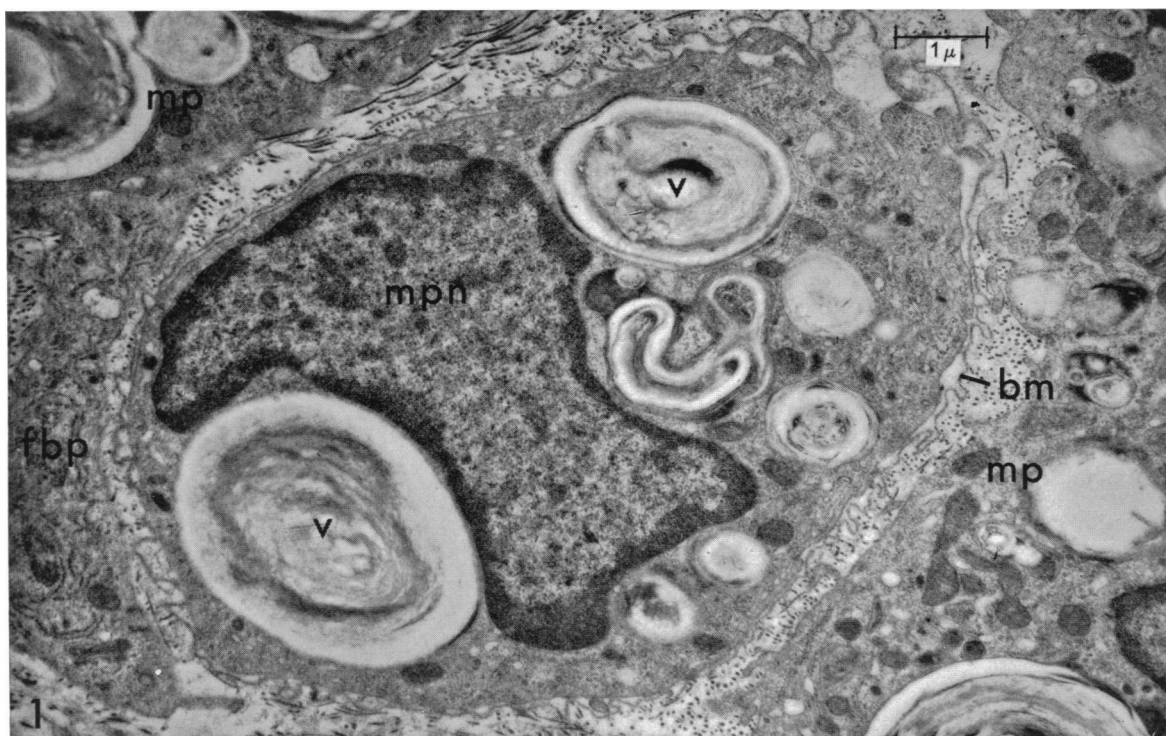*Institute of Neurology, Queen Square, and Department of Anatomy,  
University College London*

If a peripheral nerve is divided and the stumps are separated, outgrowths occur from both cut ends. That from the distal stump takes place more rapidly and constitutes an important part of the process by which the gap is bridged (Young, Holmes & Sanders, 1940). The nature of this outgrowth has been disputed. Nageotte considered that it is formed by Schwann cells, terming it a 'peripheral glioma' (Nageotte, 1922) and later a 'Schwannoma' (Nageotte, 1932). A similar view was taken by Masson (1932) and Young, *et al.* (1940). A detailed study of the process was undertaken by Rexed (1942), who cut the sciatic nerve of rats at two sites and examined the outgrowths from the divided portions of nerve. On the first and second days after operation, the gaps were found to be filled with an exudate containing erythrocytes, leucocytes and macrophages. Capillaries and fibroblasts grew into the exudate as early as the first day. Schwann cells began to emerge from the distal stump and from the isolated segment of the nerve on the third day in some specimens, and outgrowths of up to 0.6 mm in length were evident in all specimens on the fourth day. Holmes & Young (1942), although recognizing a Schwann cell outgrowth, noted that fibrous tissue from the epineurium and perineurium grows out even more vigorously and that at times an apparently large Schwannoma is found on microscopical examination to consist mainly of fibrous tissue. The question was further discussed by Young (1949).

A different conclusion was reached by Denny-Brown (1946), who stated that the cells that emerge from the distal stump are a specialized type of fibroblast which grow out from the endoneurium and perineurium. He believed that Schwann cells only appear in the outgrowth when it becomes invaded by axons and considered that they accompany the regenerating axons as they emerge from the proximal stump of the nerve.

It must be admitted that it is not always easy to distinguish between Schwann cells and fibroblasts in the outgrowth by light microscopy. Holmes & Young (1942) and Young (1949) based their conclusion on the mode of growth of the two cell types, Schwann cells being more elongated and tending to grow out in columns several cells thick. Similar features are shown by Schwann cells in tissue culture (Ingebrigtsen, 1916; Murray, Stout & Bradley, 1940; Abercrombie & Johnson, 1942; Weiss, 1944). Fibroblasts, on the other hand, were noted usually to be separated from one another by collagen, even when arranged in longitudinal rows. Denny-Brown relied particularly on differential nuclear staining.

The greater resolution of the electron microscope now offers the opportunity of re-investigating this question. The morphological features of the Schwann cell in



normal peripheral nerve as seen with the electron microscope are well documented (see, for example, Ross, 1964), and the appearances of the normal epineurial and endoneurial fibroblasts and of the perineurial cells have been studied (e.g. Röhlich & Knoop, 1961; Thomas, 1963; Shanthaveerappa, Hope & Bourne, 1963; Gamble, 1964). The details of the changes in these various cell types that occur after nerve injury have not yet been fully established, although a number of investigations have been made on the cellular changes occurring during Wallerian degeneration and subsequent regeneration (Terry & Harkin, 1957, 1959; Glimstedt & Wohlfart, 1959, 1960; Ohmi, 1961; Barton, 1962; Wechsler & Hager, 1962*a, b*; Lee, 1963; Nathaniel & Pease, 1963*a, b, c*; Satinsky, Pepe & Liu, 1964; Thomas, 1964*a, b*) and during diphtheritic neuritis (Webster, Spiro, Waksman & Adams, 1961). It was considered, therefore, that the examination of the outgrowth from the cut end of the distal stump of severed nerve might serve not only to define the nature of the cellular proliferation that takes place, but might also contribute to the more general problem of the cellular response to nerve injury. An electron microscope study on the Schwannoma resulting from peripheral nerve section has already been reported briefly by Palmer, Rees & Weddell (1961), but the results obtained differ in certain respects from those described here.

#### MATERIALS AND METHODS

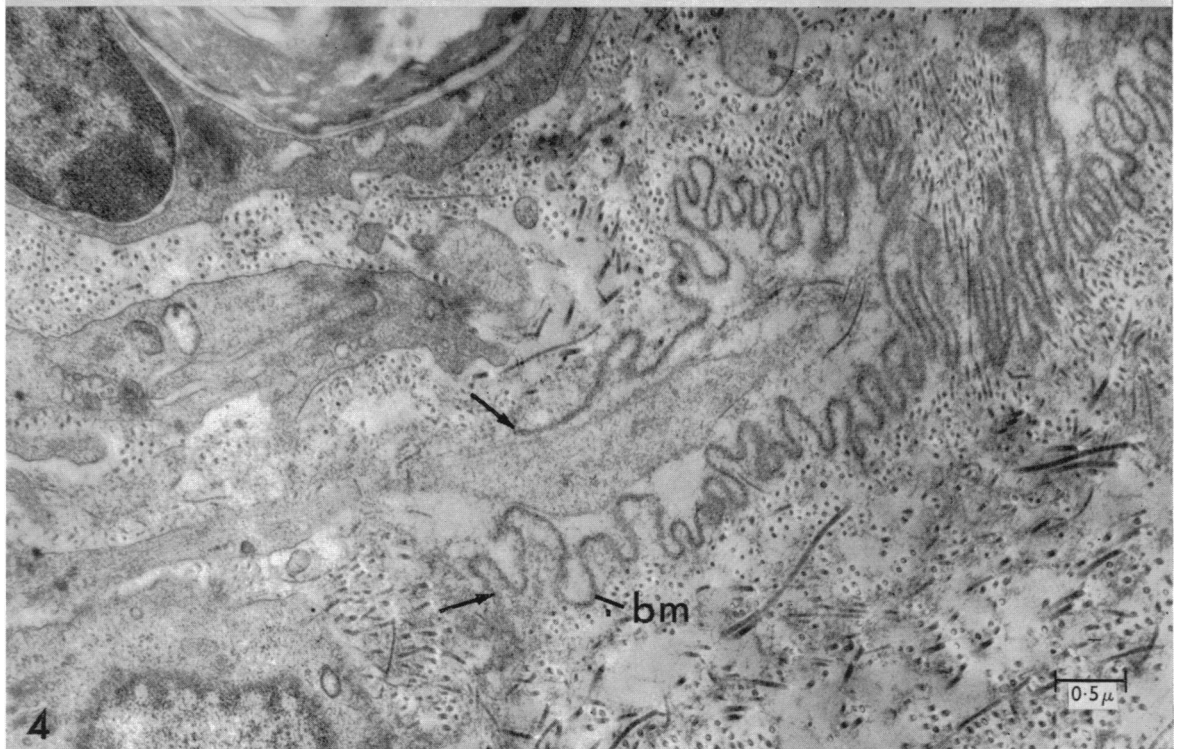
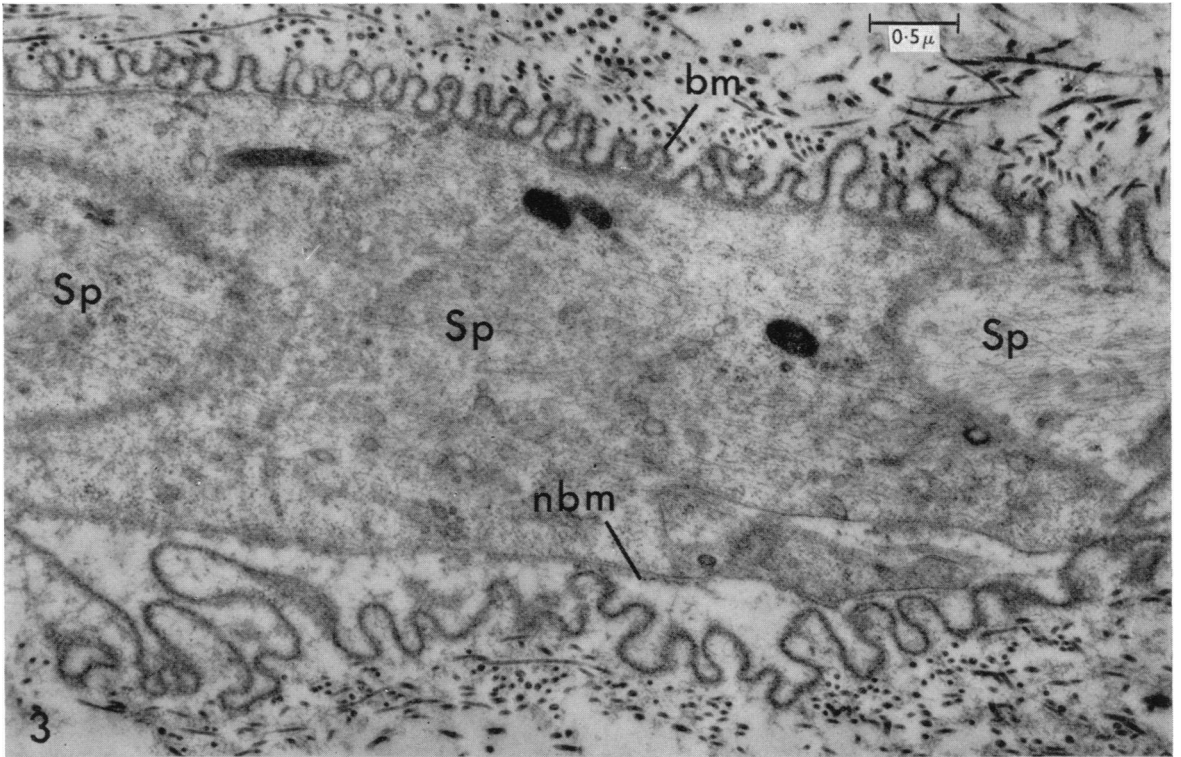
The investigation was performed on the sural nerve of two adult male New Zealand rabbits and two adult male albino rats. The nerves were exposed under pentobarbitone sodium (Nembutal) and ether anaesthesia, employing aseptic conditions throughout. The nerve was cut at mid-thigh level with scissors and the central portion dissected as far proximally as possible and avulsed. After closure of the wound, the rabbits were allowed to survive for 7 days and the rats for 6 and 7 days respectively. At biopsy, employing the same anaesthetic procedure, the distal stump of the nerve and the outgrowth from the cut end were partially freed from the adjacent tissues and fixed *in situ* for 5 min in 1% osmium tetroxide in

Fig. 1. Transverse section through distal stump of rat sural nerve, 6 days after nerve section, showing an intratubal macrophage with multiple vacuoles (v) containing myelin debris and surrounded by the basement membrane (bm) of the Schwann tube. Phosphotungstic acid stain.

Fig. 2. Longitudinal section through distal stump of rat sural nerve, 6 days after nerve section, showing a collapsed Schwann tube with marked folding of the basement membrane (bm). Phosphotungstic acid stain.

#### KEY TO LETTERING

|     |                          |     |                                |
|-----|--------------------------|-----|--------------------------------|
| bm  | basement membrane        | l   | lumen                          |
| cf  | collagen fibrils         | m   | mitochondrion                  |
| db  | dense body               | mln | mononuclear leucocyte nucleus  |
| en  | endothelial cell nucleus | mp  | macrophage                     |
| er  | endoplasmic reticulum    | mpn | macrophage nucleus             |
| f   | fibrin                   | mv  | microvilli                     |
| fb  | fibroblast               | nbm | newly formed basement membrane |
| fbn | fibroblast nucleus       | Sn  | Schwann cell nucleus           |
| fbp | fibroblast process       | Sp  | Schwann cell process           |
| g   | Golgi zone               | v   | vacuole                        |





mammalian Ringer solution buffered to pH 7.4 with Veronal-acetate. The nerve and the outgrowth were then removed, cut into lengths of about 2 mm and immersed in the above solution for 3 hr at 4 °C. After dehydration in graded concentrations of ethanol, some specimens were immersed in 1% phosphotungstic acid in absolute ethanol for 3 hr. The specimens were embedded in Araldite, sectioned with a Porter-Blum microtome and the sections collected on carbon-coated grids. The sections from the material not treated with phosphotungstic acid were stained on the grids with a 3% solution of uranyl acetate for 10 min and, after washing in distilled water, further stained with lead citrate (Reynolds, 1963) for 10–15 min. The material was examined with a Siemens Elmiskop 1 b.

#### RESULTS

The appearances were similar in both the rabbit and rat nerves, which will therefore be described together. All four nerves showed an irregular globular or conical outgrowth from the cut end of the distal stump, about 2–4 mm in length. Transverse and longitudinal sections were taken through the outgrowth and also through the distal stump for a distance of 4 mm from the level of transection.

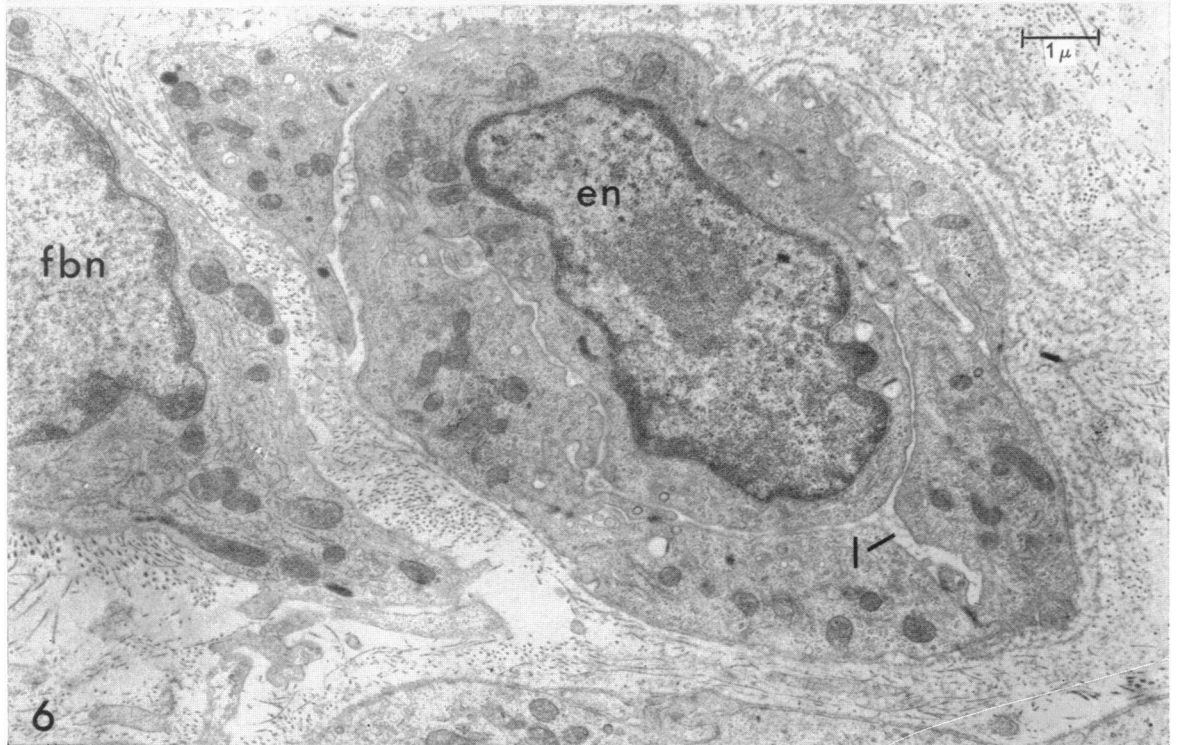
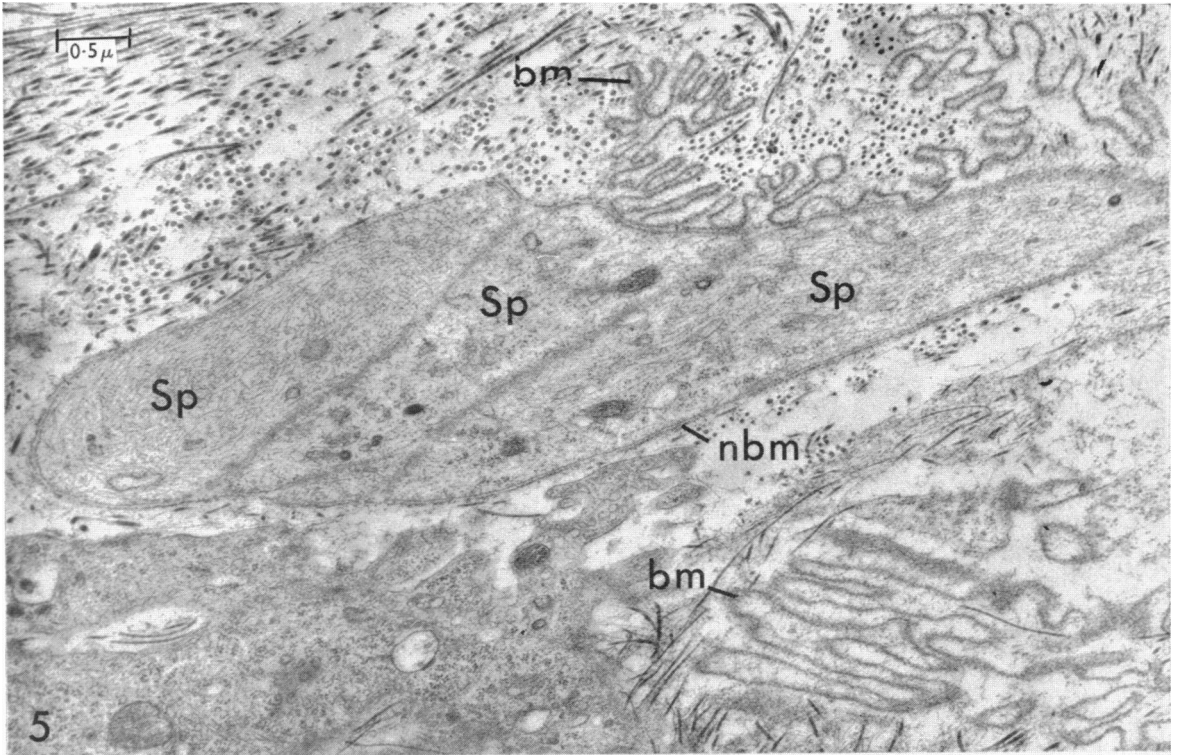
#### *The distal stump*

The basement membranes that had surrounded the Schwann cells in the uninjured nerve display prominent corrugations in longitudinal sections, as a result of retraction of the distal stump (Figs. 2–4). These persisting membranes are conveniently termed ‘Schwann tubes’ (Thomas, 1964*a*). Cells possessing multiple vacuoles containing myelin remains are frequently observed within the tubes (Fig. 1). They show similar morphological features to the macrophages that are seen in the endoneurial connective tissue and in the outgrowth (Fig. 10). Other Schwann tubes are apparently empty over long distances (Fig. 2). Many of the tubes, however, contain columns of Schwann cells (Fig. 3), recognized by the possession of a basement membrane and the presence of numerous fine longitudinal filaments within their cytoplasm, seen most readily after staining with phosphotungstic acid. These filaments are similar to those described for normal Schwann cells (Elfvin, 1961; Thomas, 1963), although they are more numerous, as was noted by Nathaniel & Pease (1963*a*) in ‘reactive’ Schwann cells during Wallerian degeneration. Some of the tubes contain collagen fibrils, which lie in the space between the newly formed basement membrane of the Schwann cells and the original basement membrane. The proliferating Schwann cells, therefore, often do not fill the Schwann tubes as they usually do more peripherally in the distal stump following nerve section (Thomas, 1964*a*). Holmes & Young (1942) noted that collagen formation around

---

Fig. 3. Longitudinal section through distal stump of rat sural nerve, 6 days after nerve section. The folded basement membrane (bm) of the Schwann tube encloses a column of Schwann cells (Sp). These show multiple fine longitudinal filaments and possess an incomplete basement membrane (nbm). Phosphotungstic acid stain.

Fig. 4. Longitudinal section through the region of transection of rat sural nerve, 6 days after nerve section. The folded basement membrane (bm) of a Schwann tube is seen to the right of the figure. A cell process of uncertain nature projects through the mouth of the tube, the cut ends of which are indicated by the arrows. Phosphotungstic acid stain.



the columns of Schwann cells is more extensive immediately adjacent to the cut end than elsewhere in the distal stump.

The endoneurial connective tissue between the Schwann tubes contains cells resembling monocytes, together with macrophages, fibroblasts and, in the rat but not the rabbit nerves, occasional mast cells. The changes in the cellular population of degenerating nerve are to be described separately (Thomas, 1965) and will therefore not be discussed further.

At the region of the cut end of the distal stump, the open ends of the divided Schwann tubes are visible. In Fig. 4, a cell process of uncertain nature is seen lying in the mouth of a transected Schwann tube, within which a few collagen fibrils have formed. Other tubes are seen to contain columns of Schwann cells which extend out from the mouths of the tubes (Fig. 5). A feature shown by these Schwann cells is the tendency for several cells or their processes to lie side by side within a common basement membrane.

#### *The outgrowth from the distal stump*

Sections taken through the tip of the outgrowth reveal that it is composed of a loose, irregular meshwork of collagen fibrils through which run blood vessels mainly of capillary size. Some of these resemble the 'vascular sprouts' described in healing tissue by Cliff (1963), consisting of a cord of closely apposed endothelial cells with a narrow lumen into which an endothelial cell often projects, as in Fig. 6. Specialized areas of contact between adjacent endothelial cells are seen, corresponding to those previously described for capillaries (Muir & Peters, 1962), where a quintuple-layered 'zonula occludens' (Farquhar & Palade, 1963) is associated, in the material stained with phosphotungstic acid, with a region of increased density of the cytoplasm on either side of the junction.

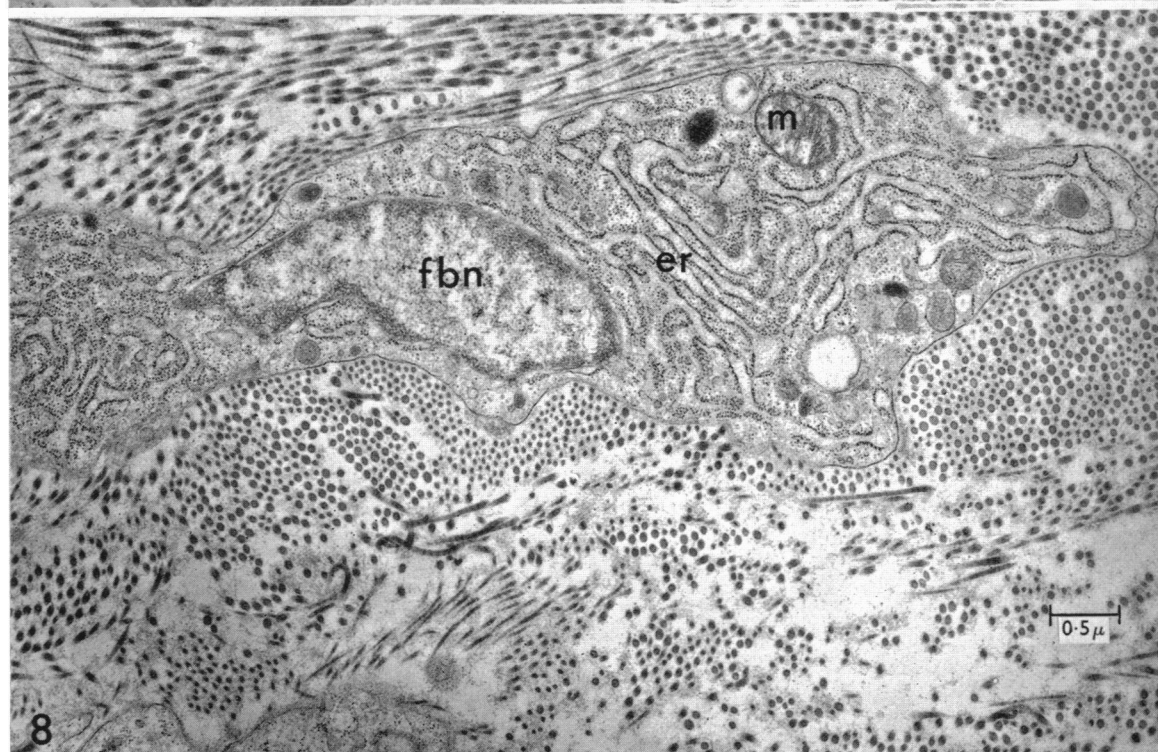
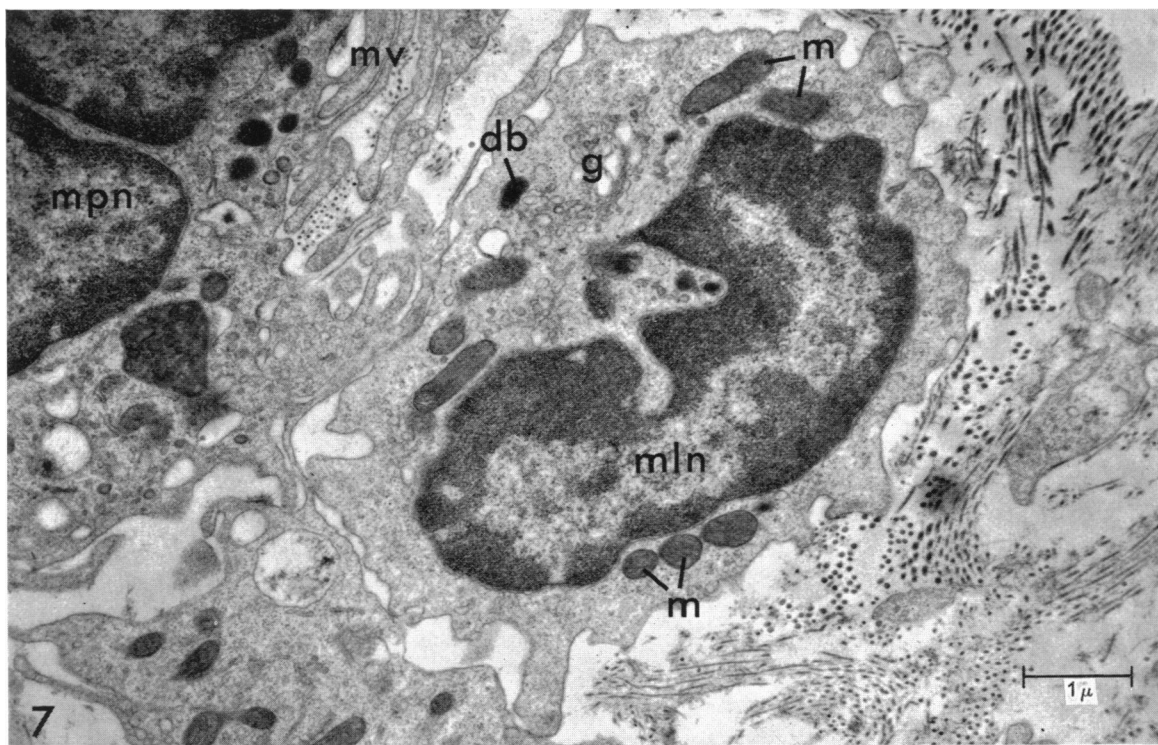
Occasional masses of fibrin are seen (Fig. 9), particularly adjacent to blood vessels. Erythrocytes and granular and agranular leucocytes are present within the outgrowth, medium and large agranular leucocytes being encountered most frequently (Fig. 7). Leucocytes are sometimes observed in the process of migration through a vessel wall in the manner reported by Marchesi & Florey (1960).

Most of the cells present in the apex and peripheral portions of the outgrowth are fibroblasts, an example of which is shown in Fig. 8. Such cells are elongated, with long, narrow processes. They are distinguished by the absence of a basement membrane and by the possession of an abundant endoplasmic reticulum which is often arranged in parallel arrays. Bundles of fine intracytoplasmic filaments are also present, seen most frequently just deep to the surface membrane. The morphological features of fibroblasts have been discussed by Peach, Williams & Chapman (1961), Ross & Benditt (1961) and others.

---

Fig. 5. Longitudinal section through the region of transection of rat sural nerve, 6 days after nerve section. A group of Schwann cell processes (Sp) extends out of the mouth of a Schwann tube, the folded basement membrane of which (bm) is seen to the right of the figure. Phosphotungstic acid stain.

Fig. 6. Transverse section through outgrowth from distal stump of rat sural nerve, 6 days after nerve section. A vascular 'sprout' is seen, showing a narrow lumen (l) into which an endothelial cell projects. Phosphotungstic acid stain.



Macrophages are also commonly seen, examples being shown in Figs. 9–11. Their appearances are in accordance with those previously described as characterizing such cells (Palade & Porter, 1954; Ross & Benditt, 1961; Cliff, 1963). They do not possess a basement membrane and show characteristic ‘ruffled’ microvilli. The endoplasmic reticulum is poorly developed, but the cytoplasm contains numerous oval mitochondria and dense bodies of varying size. The dense bodies resemble those seen in neutrophil polymorphonuclear leucocytes, where they have been thought to be lysosomes (Cohn & Hirsch, 1960). Vacuoles containing myelin forms and cellular debris may be seen, within which dense bodies are sometimes included (Fig. 10), vacuoles being present particularly in cells near the cut end of the distal stump. Tracts of fine filaments, most numerous in the perinuclear region (de Petris, Karlsbad & Pernis, 1962), are also present.

Cells intermediate in appearance between mononuclear leucocytes and macrophages are not infrequently encountered (Fig. 11). It is difficult to be certain whether this indicates the transition of the one cell type into the other, or whether it represents an overlap in the morphological features shown by the two cell types. However, from radioautographic studies of muscle injury (Bintliff & Walker, 1960) and stab wounds of the brain (Konigsmark & Sidman, 1963), there is evidence that in these situations, the majority of the macrophages are derived from blood leucocytes. It is possible that macrophages appearing after peripheral nerve injury may also be derived from blood leucocytes, as was suggested by Cajal (1928), although the relative importance of a haematogenous and a local origin has yet to be assessed.

Prominent in the central portion of the outgrowth are columns of cells considered to be Schwann cells in view of their close similarity to those seen within the Schwann tubes of the distal stump and also found extending out of the cut ends of these tubes. The columns usually consist of closely packed bundles of cells and their processes contained within a single investing basement membrane (Figs. 12, 13). As in the Schwann cells seen within the Schwann tubes of the distal stump, the endoplasmic reticulum is sparse, but the cytoplasm contains a profusion of fine filaments orientated in the direction of the cell columns (Fig. 13). Numerous free ribosomes are also seen, as has been described in actively dividing cells in other situations (Porter, 1954), including Schwann cells during Wallerian degeneration (Nathaniel & Pease, 1963*a*). Only very occasionally are myelin remnants observed within these cells.

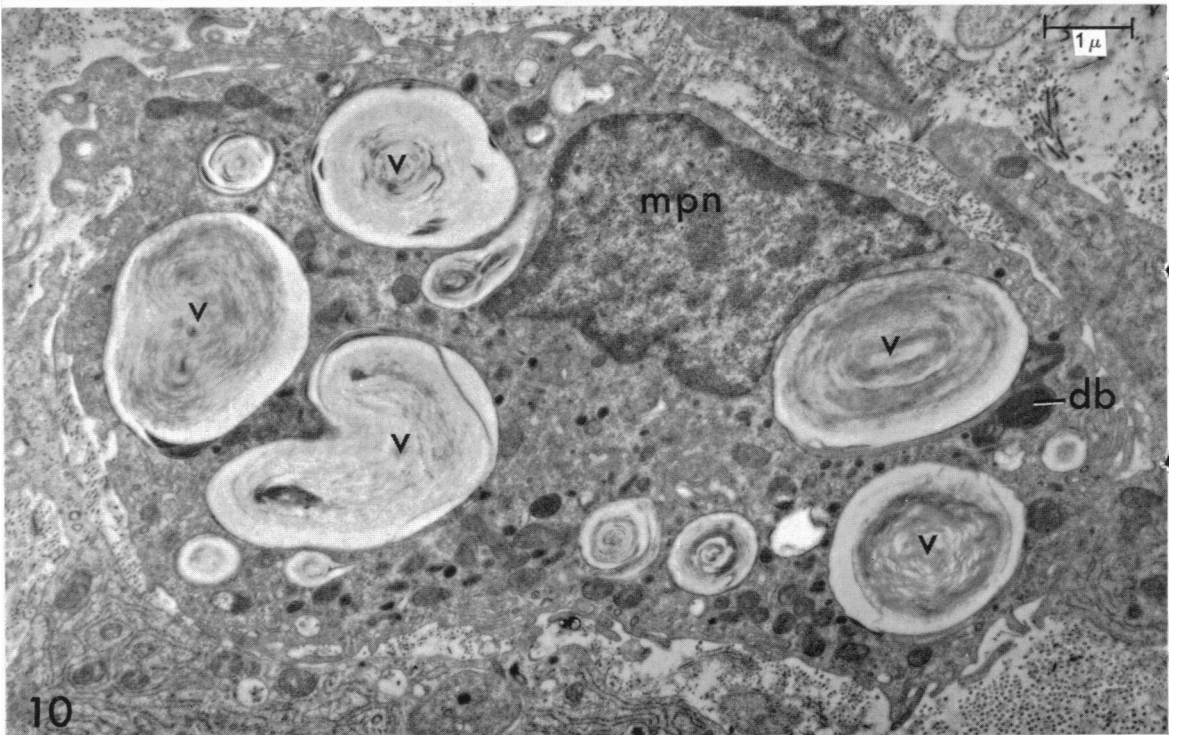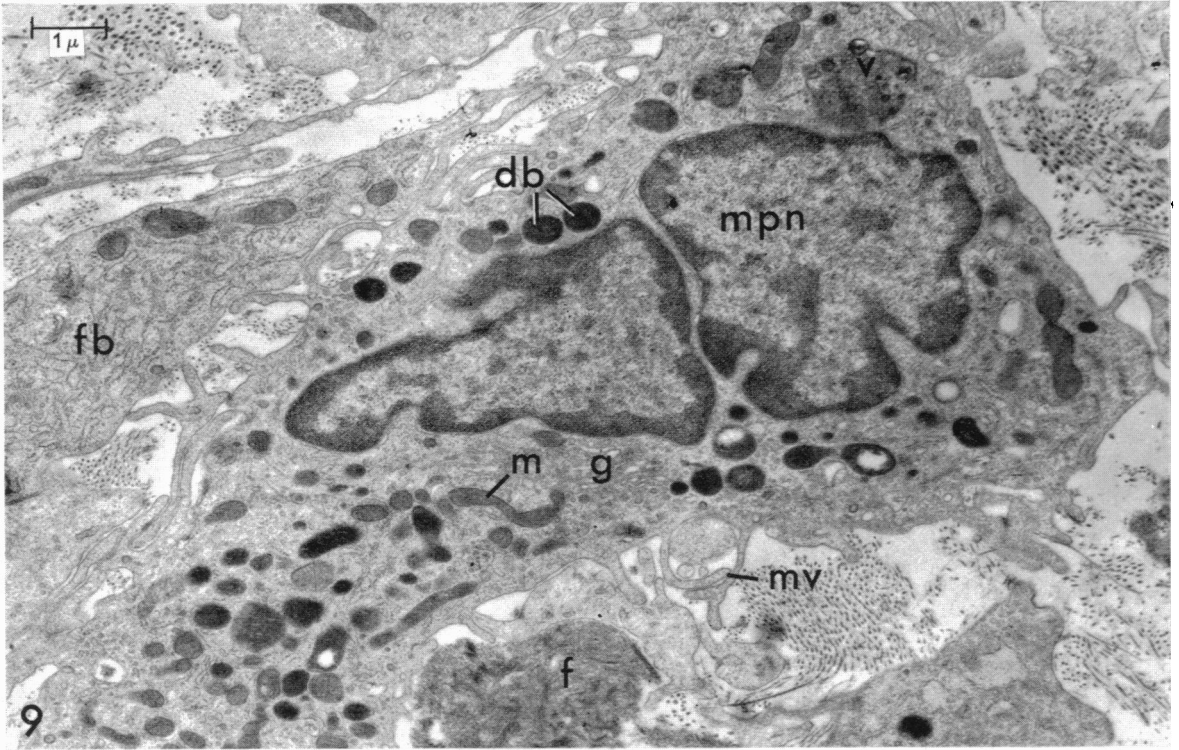
The Schwann cell columns have to be distinguished from vascular sprouts (Fig. 6). In the early stages of their development, such sprouts consist of cords of endothelial cells closely apposed to one another and surrounded by basement membrane (Cliff, 1963). There is thus a superficial resemblance to the columns of Schwann cells. At a later stage, spaces develop between the endothelial cells and enlarge to form the lumen. Distinction between the two is possible as the capillary sprouts show specialized cell contacts between the endothelial cells which are not seen between Schwann cells.

---

Fig. 7. Agranular mononuclear leucocyte from section through outgrowth from rat sural nerve, 6 days after nerve section. Phosphotungstic acid stain.

Fig. 8. Fibroblast from section through outgrowth from rat sural nerve, 7 days after nerve section. Uranyl acetate and lead citrate stain.





The peripheral part of the base of the outgrowth is in direct continuity with the epineurial connective tissue, this differing from the endoneurial connective tissue in that the collagen fibrils are of larger size, and in the presence of elastin fibres (Thomas, 1963). Elsewhere the outgrowth appears to resemble the endoneurial connective tissue more closely, the collagen fibrils being of smaller diameter.

## DISCUSSION

Palmer *et al.* (1961) reported the results of experiments in which they severed rat peripheral nerve and injected carbon particles into the gap between the cut ends. With phase-contrast microscopy, they recognized an outgrowth of Schwann cells, arranged in rows, from the distal stump of specimens examined 5 days after nerve section. These, however, were identified in the electron microscope with cells possessing numerous processes and devoid of basement membrane. Many contained neural debris and carbon particles. The nature of these cells is therefore uncertain. Cells possessing the characteristics of Schwann cells were observed at the tip of the distal stump. Although they were surrounded by basement membrane and did not contain neural debris, they were not directly apposed to one another.

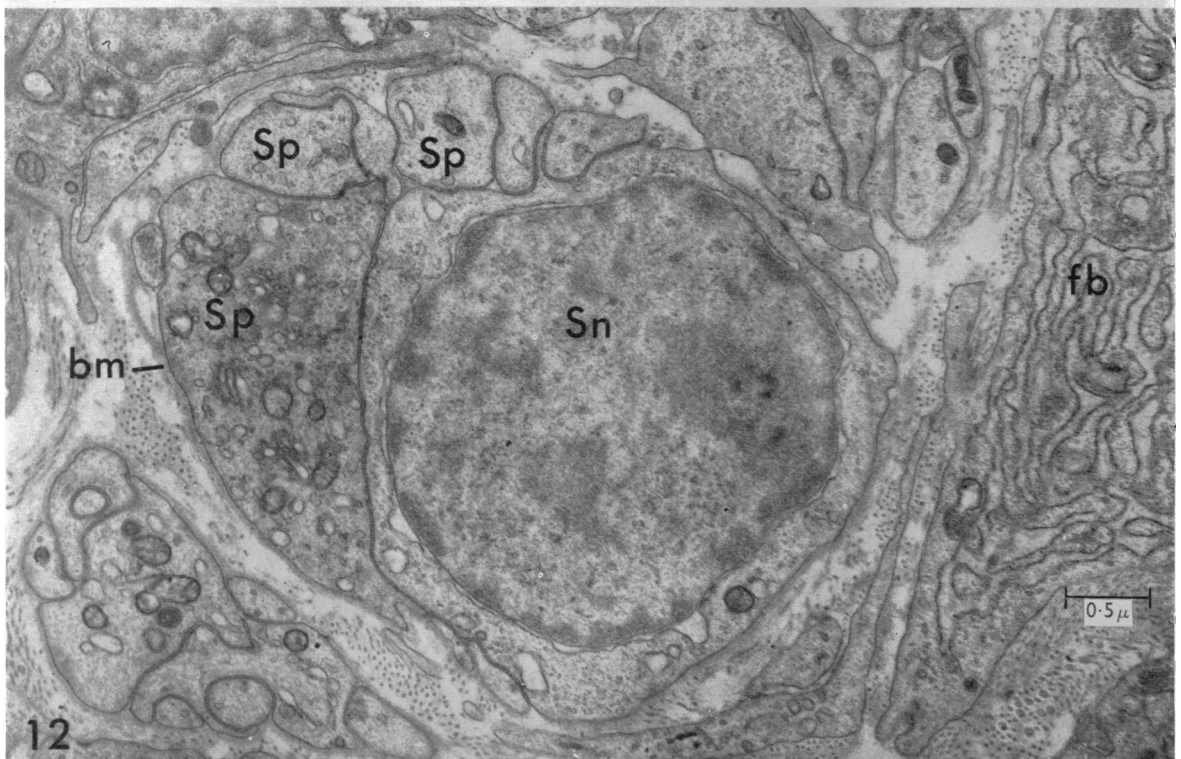
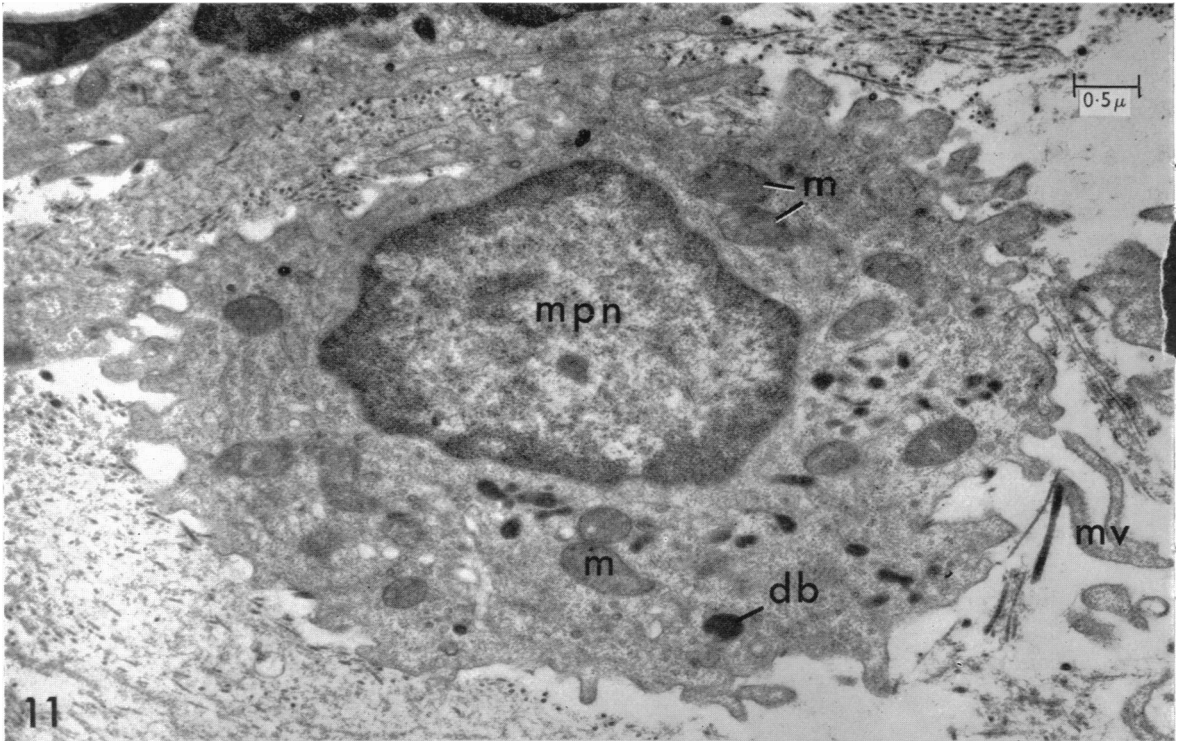
In the present investigation, the observations were made at approximately one week after nerve section, previous light microscope investigations (Rexed, 1942) having suggested that this was the stage most likely to be profitable for electron microscope study. The Schwann cells in the outgrowth were characteristically seen as columns, often several cells thick, surrounded by a common basement membrane. They are thus somewhat similar in appearance to the 'bands of Büngner' in the distal stump of a transected nerve (Nathaniel & Pease, 1963*b*; Thomas, 1964*a*) and of which they are an extension. This description corresponds closely to that given by Nageotte (1932), Masson (1932) and Holmes & Young (1942). The manner of outgrowth shows clear similarities to the outwandering of Schwann cells from degenerating nerve *in vitro*. Abercrombie, Evans & Murray (1959) observed that for explanted, degenerating, rabbit abdominal vagus nerves, the elongated, outwandering Schwann cells commonly associated end to end, and when numerous, also tended to associate side by side.

The manner of growth of the Schwann cells is presumably of significance in relation to their role during regeneration. As the outgrowth from the distal stump is an important part of the mechanism by which severed nerves become united, the presence of these cell columns in the outgrowth means that when contact with the outgrowth from the proximal stump is achieved, pathways will exist directing the axons to the Schwann tubes in the distal stump. The Schwann cell columns in the outgrowth not infrequently subdivide or anastomose, and Young (1949) observed

---

Fig. 9. Macrophage from section through outgrowth from rat sural nerve, 6 days after nerve section, showing multiple mitochondria (m), dense bodies (db) and microvilli (mv). Phosphotungstic acid stain.

Fig. 10. Macrophage with multiple vacuoles (v) containing myelin debris from section through outgrowth from rat sural nerve, 6 days after nerve section, taken close to region of transection. The upper vacuole on the right of the figure also contains a dense body (db). Phosphotungstic acid stain.



that regenerating axons may branch repeatedly in the scar between the cut ends of a severed nerve. Although this will increase the chances of axon branches reaching a functional termination at the periphery, it will also contribute to the cross-innervation that occurs during regeneration after neurotmesis.

The connective tissue of the outgrowth is in direct continuity with that of the distal stump and it seems likely that it is derived from the local proliferation of fibroblasts from the endoneurium, perineurium and epineurium, although the present results provide no direct evidence on this question. It has been suggested by a number of observers that monocytes from the blood are capable of conversion into fibroblasts in the tissues. The evidence for this is inconclusive and has recently been reviewed by Grillo (1964). He tentatively concluded that there is little indication of a vascular origin for the majority of fibroblasts involved in wound repair, but that there is strong evidence to suggest an origin by local cellular proliferation. Palmer, *et al.* (1961) have suggested that the transformation of Schwann cells into fibroblasts occurs during Wallerian degeneration, but transitional forms were not encountered in the present study.

Denny-Brown (1946) was of the opinion that the fibroblastic outgrowth from the distal stump was derived from cells in the endoneurium and perineurium. They were considered to differ from epineurial fibroblasts with respect to the type of collagen produced and in nuclear staining properties. Although the present study has shown that the connective tissue at the periphery of the base of the outgrowth is of epineurial type, the nature of the connective tissue in the outgrowth supports Denny-Brown's view that the majority of the proliferation is of endoneurial or perineurial origin. The perineurial collagen fibrils are of similar diameter to those of the endoneurium. However, no distinguishing features between epineurial, perineurial and endoneurial fibroblasts could be recognized.

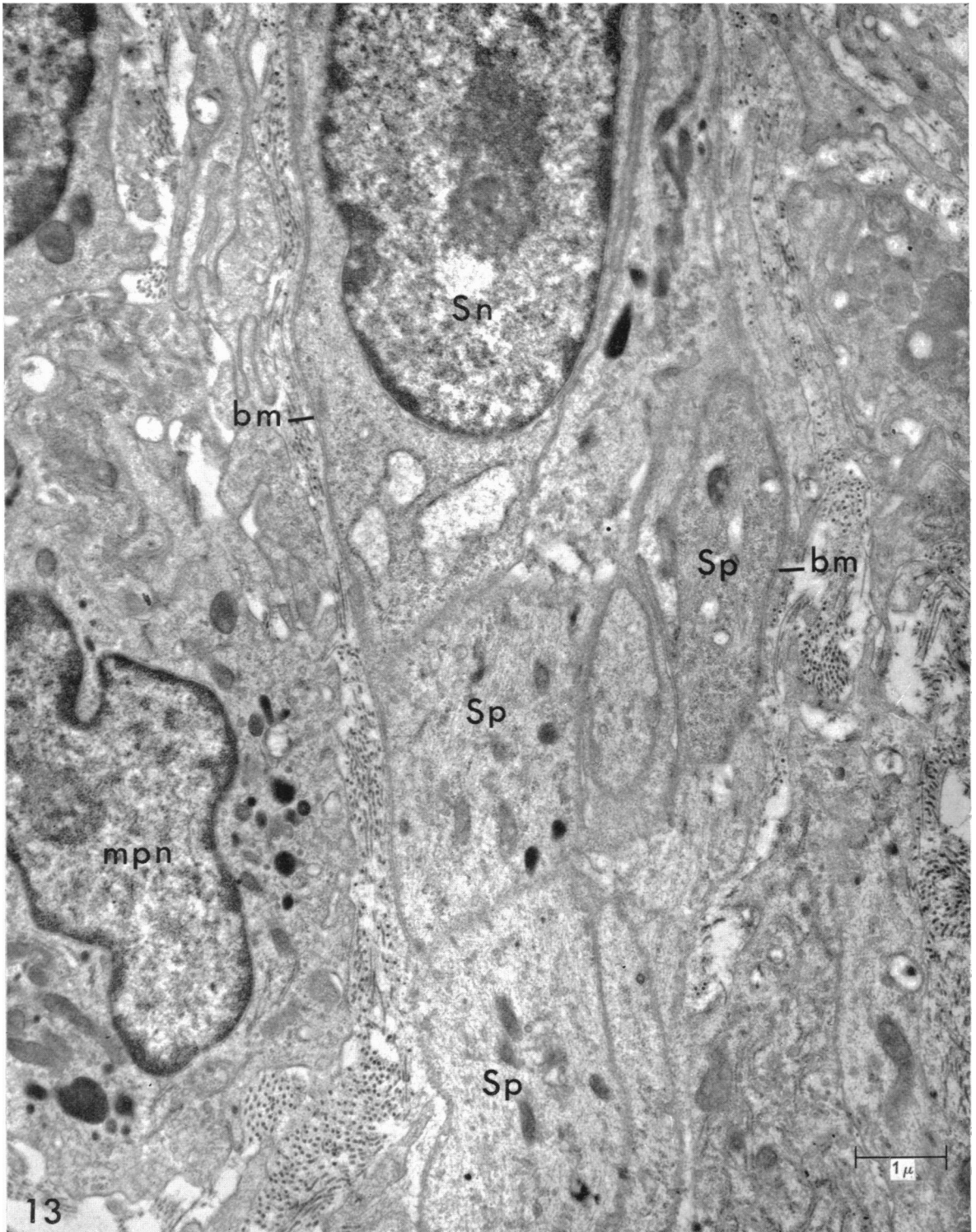
Denny-Brown pointed out that the perineurium consists of layers of flattened cells of mesothelial type, between which are bundles of collagen, together with fibroblasts. Electron microscope studies in recent years have confirmed that the perineurium is mainly composed of laminae of flattened cells closely attached to each other at their lateral margins and possessing basement membrane on both inner and outer aspects (Röhlich & Knoop, 1961; Thomas, 1963; Shanthaveerappa *et al.* 1963; Gamble, 1964). These correspond to the mesothelial cells described by Denny-Brown and to the 'perineurial epithelium' of Shanthaveerappa & Bourne (1962). Layers of collagen intervene between the cellular laminae, within which occasional fibroblasts are seen (Thomas & Jones, 1965). Following nerve section, Denny-Brown noted extensive cellular proliferation from the perineurium, which contributed to the outgrowth from the cut end. So far it has not proved possible to identify perineurial cells in the outgrowth with certainty under the electron microscope.

---

Fig. 11. Small macrophage from section through outgrowth from rat sural nerve, 6 days after nerve section. Phosphotungstic acid stain.

Fig. 12. Transverse section through outgrowth from rat sural nerve, 7 days after nerve section, showing Schwann cell and Schwann cell processes (Sp) surrounded by basement membrane (bm). Uranyl acetate and lead citrate stain.







## SUMMARY

An electron microscope study was made on the cellular outgrowth from the distal stump of transected rabbit and rat sural nerves, examined one week after nerve section. Cords of Schwann cells, often several cells thick and surrounded by a common basement membrane, were seen extending from the distal stump into the outgrowth. They were embedded in a connective tissue framework, probably mainly of endoneurial and perineurial origin, consisting of blood vessels, fibroblasts, and irregular bundles of collagen fibrils, together with macrophages and other connective tissue cells.

I wish to thank Miss Jean Slatford for technical assistance and Professor. W. H. McMenemy and Dr M. Kidd for laboratory facilities at Maida Vale Hospital. A personal grant from the Polio Research Fund is gratefully acknowledged. I also wish to thank Dr E. G. Gray, Dr D. W. James and Professor J. Z. Young, F.R.S., for helpful discussion.

## REFERENCES

- ABERCROMBIE, M., EVANS, D. H. L. & MURRAY, J. G. (1959). Nuclear multiplication and cell migration in degenerating unmyelinated nerves. *J. Anat.* **93**, 9-14.
- ABERCROMBIE, M. & JOHNSON, M. L. (1942). The outwandering of cells in tissue cultures of nerves undergoing Wallerian degeneration. *J. exp. Biol.* **19**, 266-283.
- BARTON, A. A. (1962). An electron microscope study of degeneration and regeneration of nerve. *Brain*, **85**, 799-808.
- BINTLIFF, S. & WALKER, B. E. (1960). Radioautographic study of skeletal muscle regeneration. *Am. J. Anat.* **106**, 233-245.
- CAJAL, S. RAMÓN Y (1928). *Degeneration and Regeneration of the Nervous System*. London: Oxford University Press.
- CLIFF, W. J. (1963). Observations on healing tissue: a combined light and electron microscopic investigation. *Phil. Trans. R. Soc. B*, **246**, 305-325.
- COHN, Z. A. & HIRSCH, J. G. (1960). The isolation and properties of the specific cytoplasmic granules of rabbit polymorphonuclear leucocytes. *J. exp. Med.* **112**, 983-1004.
- DENNY-BROWN, D. (1946). Importance of neural fibroblasts in the regeneration of nerve. *Archs Neurol. Psychiat., Chicago*, **55**, 171-215.
- ELFVIN, L.-G. (1961). Electron-microscopic investigation of filament structures in unmyelinated fibers of cat splenic nerve. *J. Ultrastruct. Res.* **5**, 51-64.
- FARQUHAR, M. G. & PALADE, G. E. (1963). Junctional complexes in various epithelia. *J. Cell Biol.* **17**, 375-412.
- GAMBLE, H. J. (1964). Comparative electron-microscopic observations on the connective tissues of a peripheral nerve and a spinal nerve root in the rat. *J. Anat.* **98**, 17-25.
- GLIMSTEDT, G. & WOHLFART, G. (1959). Electron microscopic observations on Wallerian degeneration in peripheral nerves. *Acta morph. neerl.-scand.* **3**, 135-146.
- GLIMSTEDT, G. & WOHLFART, G. (1960). Electron microscope studies of peripheral nerve regeneration. *Lunds Univ. Arsskr., N.F., Avd. 2*, **56**, nr 16.
- GRILLO, H. C. (1964). Derivation of fibroblasts in the healing wound. *Archs Surg., Chicago*, **88**, 218-224.
- HOLMES, W. & YOUNG, J. Z. (1942). Nerve regeneration after immediate and delayed suture. *J. Anat.* **77**, 63-96.
- INGEBRIGTSEN, R. (1916). Contribution to the biology of the peripheral nerves in transplantation. *J. exp. Med.* **23**, 251-264.

---

Fig. 13. Longitudinal section through outgrowth from rat sural nerve, 6 days after nerve section, showing column of Schwann cells (Sp). A nucleated Schwann cell and several Schwann cell processes are surrounded by basement membrane (bm). Phosphotungstic acid stain.

- KONIGSMARK, B. W. & SIDMAN, R. L. (1963). Origin of brain macrophages in the mouse. *J. Neuro-path. exp. Neurol.* **22**, 643-676.
- LEE, J. C.-Y. (1963). Electron microscopy of Wallerian degeneration. *J. comp. Neurol.* **120**, 65-79.
- MARCHESI, V. T. & FLOREY, H. W. (1960). Electron micrographic observations on the emigration of leucocytes. *Q. Jl exp. Physiol.* **45**, 343-348.
- MASSON, P. (1932). Experimental and spontaneous Schwannomas (peripheral gliomas). Part I. Experimental Schwannomas. *Am. J. Path.* **8**, 367-388.
- MUIR, A. R. & PETERS, A. (1962). Quintuple-layered membrane junctions at terminal bars between endothelial cells. *J. Cell Biol.* **12**, 443-448.
- MURRAY, M. R., STOUT, A. P. & BRADLEY, C. F. (1940). Schwann cell versus fibroblast as the origin of the specific nerve sheath tumour. Observations upon normal nerve sheaths and neurilemmomas *in vitro*. *Am. J. Path.* **16**, 41-60.
- NAGEOTTE, J. (1922). *L'organisation de la matière dans ses rapports avec la vie. Etudes d'anatomie générale et de morphologie expérimentale sur le tissu conjonctif et le nerf*. Paris: Alcan.
- NAGEOTTE, J. (1932). Sheaths of the peripheral nerves. Nerve degeneration and regeneration. In *Cytology and Cellular Pathology of the Nervous System*, pp. 189-239. Ed. W. Penfield. New York: Hoeber.
- NATHANIEL, E. J. H. & PEASE, D. C. (1963a). Degenerative changes in rat dorsal roots during Wallerian degeneration. *J. Ultrastruct. Res.* **9**, 511-532.
- NATHANIEL, E. J. H. & PEASE, D. C. (1963b). Regenerative changes in rat dorsal roots following Wallerian degeneration. *J. Ultrastruct. Res.* **9**, 533-549.
- NATHANIEL, E. J. H. & PEASE, D. C. (1963c). Collagen and basement membrane formation by Schwann cells during nerve regeneration. *J. Ultrastruct. Res.* **9**, 550-560.
- OHMI, S. (1961). Electron microscopic study on Wallerian degeneration of the peripheral nerve. *Z. Zellforsch. mikrosk. Anat.* **54**, 39-67.
- PALADE, G. E. & PORTER, K. R. (1954). Studies on the endoplasmic reticulum. I. Its identification in cells *in situ*. *J. exp. Med.* **100**, 641-656.
- PALMER, E., REES, R. J. W. & WEDDELL, G. (1961). The phagocytic activity of Schwann cells. In *Cytology of Nervous Tissue*. Proceedings of the Anatomical Society of Great Britain and Ireland, November, 1961. London: Taylor and Francis.
- PEACH, R., WILLIAMS, G. & CHAPMAN, J. A. (1961). A light and electron optical study of regenerating tendon. *Am. J. Path.* **38**, 495-513.
- DE PETRIS, S., KARLSBAD, G. & PERNIS, B. (1962). Filamentous structures in the cytoplasm of normal mononuclear phagocytes. *J. Ultrastruct. Res.* **7**, 39-55.
- PORTER, K. R. (1954). Electron microscopy of basophilic components of cytoplasm. *J. Histochem. Cytochem.* **2**, 346-355.
- REXED, B. (1942). Über die Aktivität der Schwannschen Zellen bei der Nerven-regeneration. I. Die Überbrückung neuritloser Nervenlücken. *Z. mikr.-anat. Forsch.* **51**, 177-205.
- REYNOLDS, E. S. (1963). The use of lead citrate at high pH as an electron-opaque stain in electron microscopy. *J. Cell Biol.* **17**, 208-213.
- RÖHLICH, P. & KNOOP, A. (1961). Elektronenmikroskopische Untersuchungen an den Hüllen des N. Ischiadicus der Ratte. *Z. Zellforsch. mikrosk. Anat.* **53**, 299-312.
- ROSS, L. L. (1964). Peripheral nervous tissue. In *Electron Microscopic Anatomy*. Ed. S. M. Kurtz. New York: Academic Press.
- ROSS, R. & BENDITT, E. P. (1961). Wound healing and collagen formation. I. Sequential changes in components of guinea pig skin wounds observed in the electron microscope. *J. biophys. biochem. Cytol.* **11**, 677-700.
- SATINSKY, D., PEPE, F. A. & LIU, C. N. (1964). The neurilemma cell in peripheral nerve degeneration and regeneration. *Expl. Neurol.* **9**, 441-451.
- SHANTHAVERAPPA, T. R. & BOURNE, G. H. (1962). The 'perineurial epithelium', a metabolically active, continuous, protoplasmic cell barrier surrounding peripheral nerve fasciculi. *J. Anat.* **96**, 527-537.
- SHANTHAVERAPPA, T. R., HOPE, J. & BOURNE, G. H. (1963). Electron microscopic demonstration of the perineurial epithelium in rat peripheral nerve. *Acta anat.* **52**, 193-201.
- TERRY, R. D. & HARKIN, J. C. (1957). Regenerating peripheral nerve sheaths following Wallerian degeneration. *Expl. Cell Res.* **13**, 193-197.
- TERRY, R. D. & HARKIN, J. C. (1959). Wallerian degeneration and regeneration of peripheral nerves. I. *The Biology of Myelin*. Ed. S. A. Korey. New York: Hoeber.
- THOMAS, P. K. (1963). The connective tissue of peripheral nerve: an electron microscope study. *J. Anat.* **97**, 35-44.
- THOMAS, P. K. (1964a). Changes in the endoneurial sheaths of peripheral myelinated nerve fibres during Wallerian degeneration. *J. Anat.* **98**, 175-182.

- THOMAS, P. K. (1964*b*). The deposition of collagen in relation to Schwann cell basement membrane during Wallerian degeneration. *J. Cell Biol.* **23**, 375-382.
- THOMAS, P. K. (1965). The cellular response to nerve injury. 3. The cellular population of peripheral nerve during Wallerian degeneration. To be published.
- THOMAS, P. K. & JONES, G. (1965). The cellular response to nerve injury. 2. The role of the perineurium in regeneration following nerve section. To be published.
- WEBSTER, H. DE F., SPIRO, D., WAKSMAN, B. & ADAMS, R. D. (1961). Phase and electron microscopic studies of experimental demyelination. II. Schwann cell changes in guinea pig sciatic nerves during experimental diphtheritic neuritis. *J. Neuropath. exp. Neurol.* **20**, 5-34.
- WECHSLER, W. & HAGER, H. (1962*a*). Elektronenmikroskopische Untersuchung der Wallerschen Degeneration des peripheren Säugetiernerven. *Beitr. path. Anat.* **126**, 352-380.
- WECHSLER, W. & HAGER, H. (1962*b*). Elektronenmikroskopische Befunde zur Feinstruktur von Axonveränderungen in regenerierenden Nervenfasern des Nervus Ischiadicus der weissen Ratte. *Acta Neuropath.* **1**, 489-506.
- WEISS, P. (1944). *In vitro* transformation of spindle cells of neural origin into macrophages. *Anat. Rec.* **88**, 205-221
- YOUNG, J. Z. (1949). Factors influencing the regeneration of nerve. *Adv. Surg.* **1**, 165-220.
- YOUNG, J. Z., HOLMES, W. & SANDERS, F. K. (1940). Nerve regeneration. Importance of the peripheral stump and the value of nerve grafts. *Lancet*, ii, 128-130.