

Myoepithelium in the prelactating and lactating mammary glands of the rat

CAROLYN J. P. RADNOR*

Department of Pathology, University of Manchester

(Accepted 19 May 1972)

INTRODUCTION

The ultrastructure of the mammary gland has been described both in pregnancy (Wellings, de Ome & Pitelka, 1960; Feldman, 1961; Waugh & Van der Hoeven, 1962; Sekhri, Pitelka & de Ome, 1967; Toker, 1967) and during lactation (Bargmann & Knoop, 1959; Hollman, 1959; Wellings *et al.* 1960; Feldman, 1961; Sekhri *et al.* 1967; Helminen & Ericsson, 1968; Kurosumi, Kobayashi & Baba, 1968; Pitelka *et al.* 1969), but although the myoepithelial cell is known to play an important contractile role during lactation (Richardson, 1949; Linzell, 1955; Bässler, Schafer & Paek, 1967) no reports have been made of any alteration in its morphology after changing from the prelactating to the lactating state.

In this study, material was taken from the mammary glands of pregnant and lactating rats in order to determine whether any structural change occurs in the myoepithelium.

MATERIALS AND METHODS

Female Sprague–Dawley rats, two, seven and nineteen days pregnant and on the twenty-third day of lactation were anaesthetized with an intraperitoneal injection of pentobarbitone sodium (veterinary Nembutal) and then the ventral skin was cut down the mid-line and peeled back to reveal the mammary glands on the underside of the dermis. A wedge of tissue was excised from each of the first and fourth pairs of glands and immediately placed in separate aliquots of 2.5% glutaraldehyde buffered with 0.1 M sodium cacodylate to pH 7.4. Each of the four samples was separately diced into small cubes. After 4 hours fixation at room temperature the solution was decanted and replaced with 0.1 M sodium cacodylate buffer wash containing 3 mM calcium chloride. Three changes of buffer wash were given over a period of 24 hours.

The tissues were post-fixed for 1 hour in 1% osmium tetroxide in a phosphate buffer at pH 7.4 and subsequently dehydrated in ascending concentrations of ethyl alcohol. After soaking in propylene oxide they were embedded in Araldite resin which was polymerized at 60 °C for two days. Thick sections were cut on a Huxley ultramicrotome using glass knives, mounted on slides and stained with 1% toluidine blue in 1% borax. Suitable areas were selected for ultrathin sectioning and silver and pale gold sections were mounted on uncoated copper grids, doubly stained with uranyl acetate (Watson, 1958) and lead citrate (Reynolds, 1963) and examined with an EM 6B electron microscope.

* Present address and address for reprints: Department of Pharmacology and Therapeutics, Makerere University, Medical School, P.O. Box 7072, Kampala, Uganda.

OBSERVATIONS

Pregnancy

At two days gestation, myoepithelial cells were distinct around the edges of ducts and alveoli and both pale and dark cells were seen in the epithelium.

Occasionally a cell in mitosis was found. Fat droplets could be identified both in the lumen and epithelial cells of ductules and alveoli and many lumina were filled with a homogeneous secretion. Blood vessels ramified between the ductules, which were separated by connective tissue into lobules (Fig. 1).

In many places the myoepithelial cells were well differentiated with pronounced cell processes full of myofilaments. A number of early stages were also seen, with myofilament systems hardly organized (Fig. 2), suggesting that this was a period of growth of the mammary gland.

The nucleus was usually strongly osmiophilic and oval, though occasionally bilobed or irregular in outline. Mitochondria were numerous, with distinct cristae and occasional mitochondrial granules. Immature myoepithelial cells were characterized by extensive rough endoplasmic reticulum with dilated cisternae and ribosomes in rosette-like clusters; Golgi dictyosomes with associated smooth and coated vesicles were also frequently seen. The more differentiated cells had narrow profiles of rough endoplasmic reticulum with free ribosomes in random formation, packed between filaments and other organelles.

Pinocytotic vesicles were present even in the very early stages of differentiation, though hemi-desmosomes appeared to be variable in their distribution (Fig. 2). Dense filament attachment areas on the plasma membrane and dense bodies were seen only in those cells with well-formed myofilaments. A feltwork of fine fibrils was visible beneath, and attached to, the basement membrane, external to which were frequently found fibroblastic processes and collagen and elastin fibres.

Intracytoplasmic filaments measured between 5 and 7 nm and, in the undifferentiated cells, were often irregularly clumped into coarse bundles so that distinction between actin and tonofilaments was not possible (Fig. 2).

Complex interdigitations occurred between microvillous cell processes around the basal areas of cells, especially in the larger ducts. Desmosomes were common and occasionally a nexus, or close junction, was found.

Lipid droplet formation was not entirely restricted to epithelial cells and on one occasion a myoepithelial cell was seen to contain several fat droplets as well as masses of filaments and pinocytotic vesicles (Fig. 3). Other inclusions found in myoepithelial cells were membrane-bound dense bodies, multivesicular bodies and microtubules.

Around large ducts, myoepithelial cell processes were directed out radially from the duct lumen (Fig. 4), with abundant hemi-desmosomes and a distinctive lamina densa on the basement membrane. The sparsely distributed myofilaments were cut transversely in a cross-section of the duct as the cell processes around it travelled mainly in a longitudinal direction.

By seven days gestation, spindle-shaped myoepithelial cell processes formed two or three closely apposed layers around the ducts and contained bundles of myofilaments (Fig. 5). In the smaller ducts and alveoli the period of alveolar growth was not yet complete and new myoepithelial cells were still differentiating. The myo-

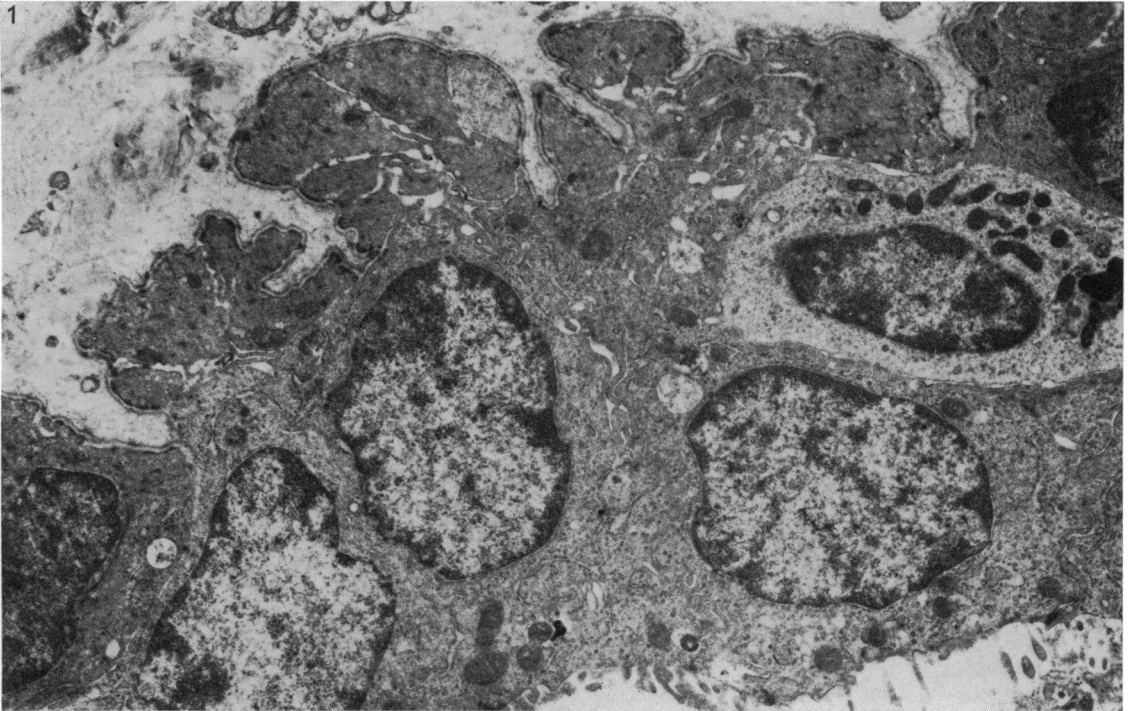


Fig. 1. Two days pregnant rat. Duct with surrounding myoepithelial cell processes. $\times 8750$.

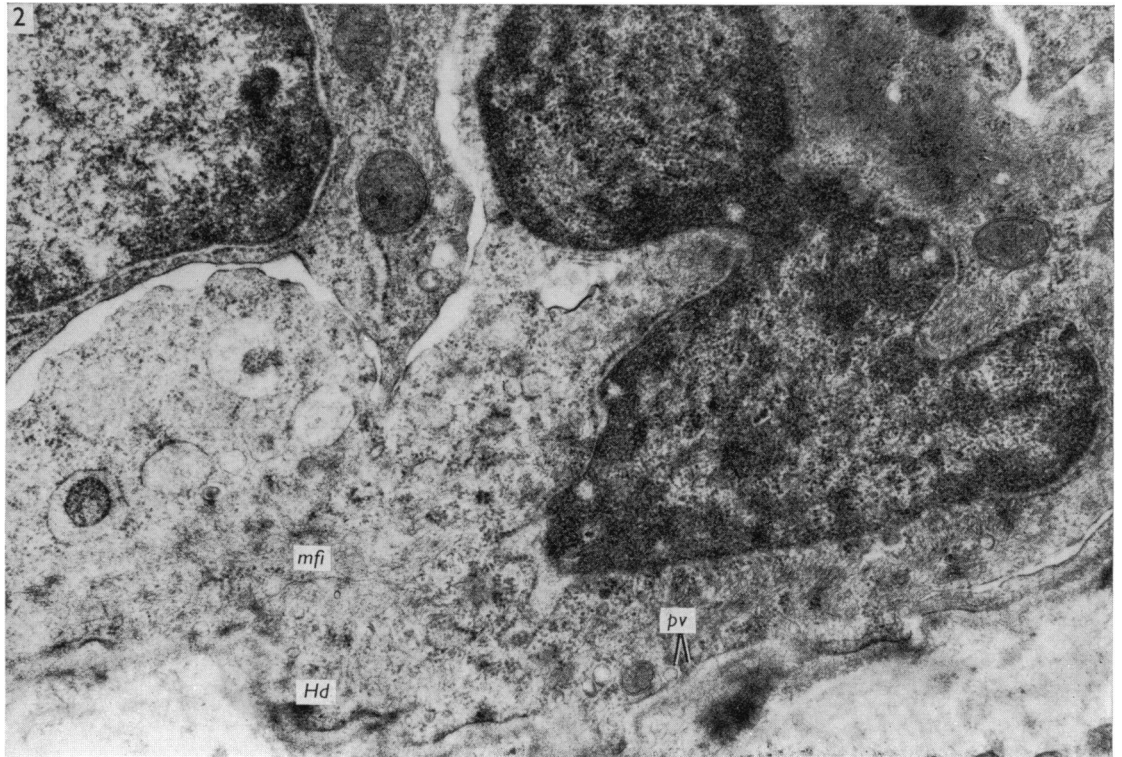


Fig. 2. Two days pregnant rat. A developing myoepithelial cell with few myofilaments (*mfi*) and occasional pinocytotic vesicles (*pv*). Hemi-desmosomes (*Hd*) are not yet well developed. $\times 22500$.

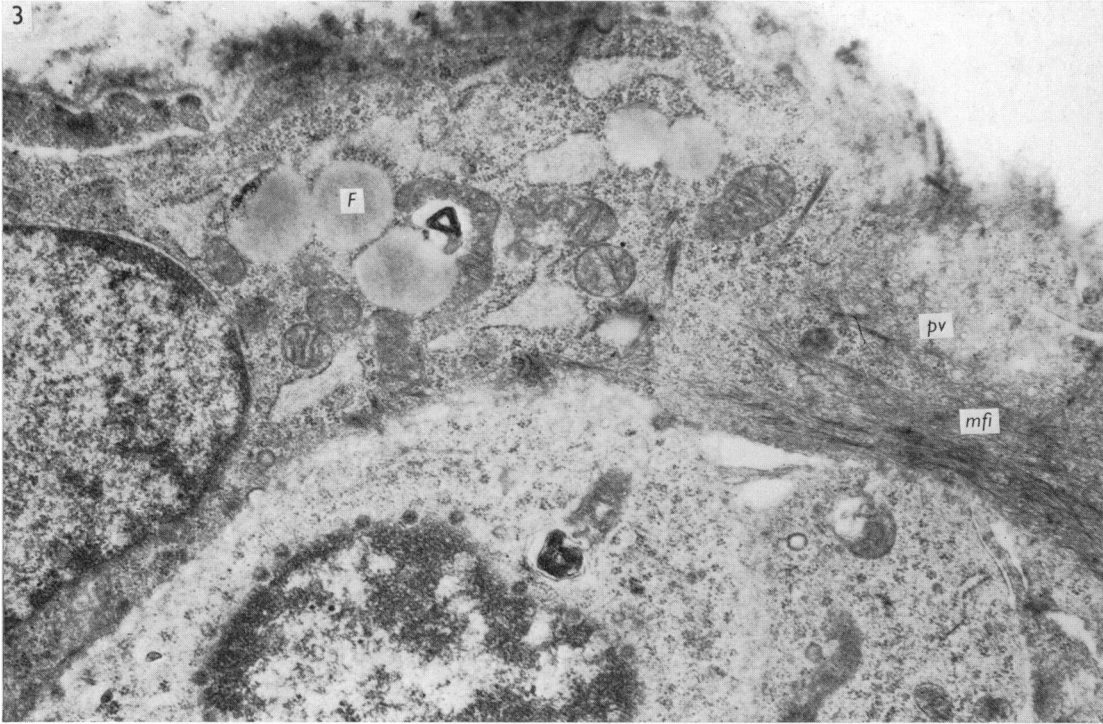


Fig. 3. Two days pregnant rat. A myoepithelial cell containing both myofilaments (*mfi*) and fat droplets (*F*) is shown. Many pinocytotic vesicles (*pv*) can be seen. $\times 18750$.

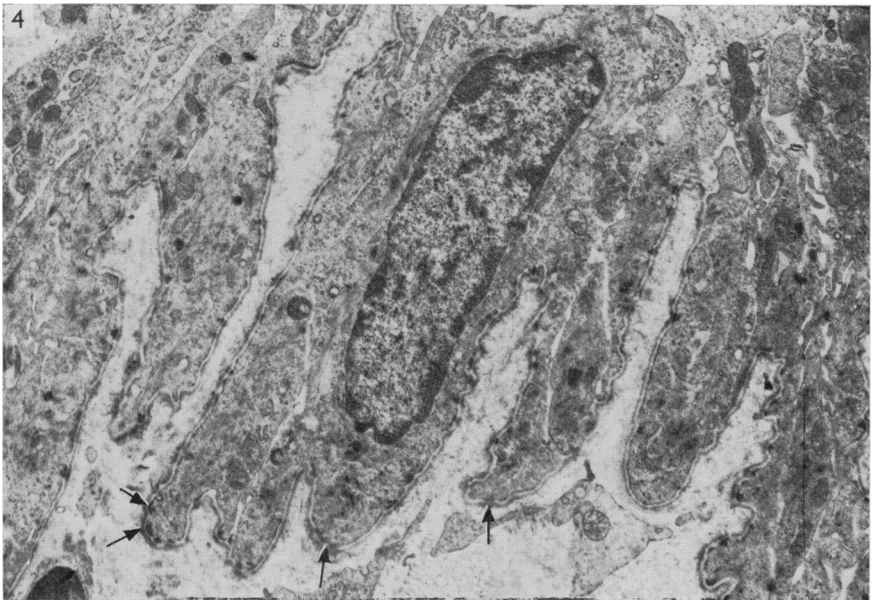


Fig. 4. Two days pregnant rat. Radial processes around a large duct, with hemi-desmosomes (arrows). Myofilaments are aggregated into bundles. $\times 8750$.

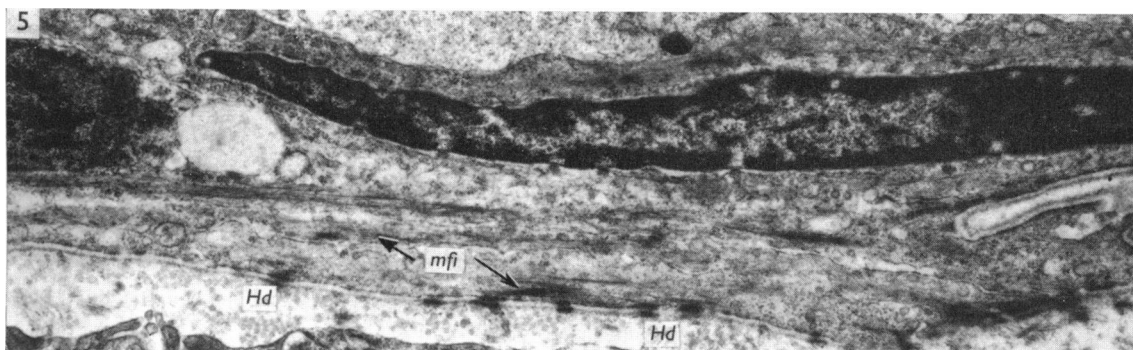


Fig. 5. Seven days pregnant rat. Elongated duct cells with overlying processes containing bundles of myofilaments (*mfi*) with organelles in between them. Hemi-desmosomes (*Hd*) are pronounced. $\times 15000$.

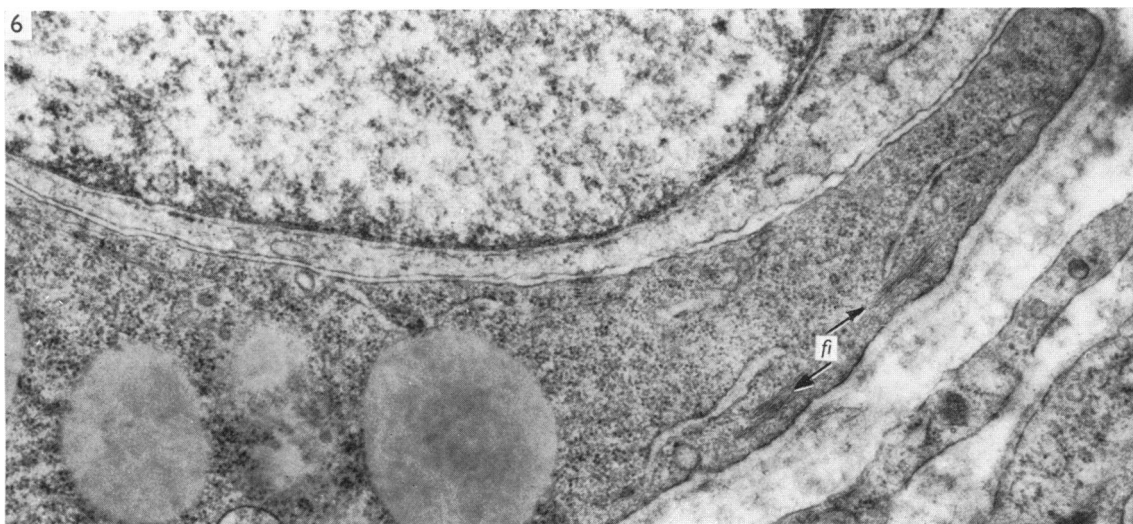


Fig. 6. Seven days pregnant rat. Part of a secretory epithelial cell with bundles of cytoplasmic filaments (*fi*) near the basal plasma membrane. $\times 25000$.

epithelium around large ducts appeared unchanged from that of two days gestation, processes being directed radially and having a highly irregular outline. The epithelium of large collecting ducts contained no secretory droplets.

Occasionally, fat droplets were found in myoepithelial cells and, conversely, several secretory cells were seen with bundles of cytoplasmic filaments arranged down their longitudinal axes near the basement membrane (Fig. 6), together with small dense regions on the basal plasma membrane and associated fine filaments, similar to the attachment areas of myoepithelial cells.

The arrangement of myofilaments varied with their position. In the cell processes along the ducts the myofilaments were very long and straight, usually arranged in bundles with cell cytoplasm containing endoplasmic reticulum, ribosomes, mito-

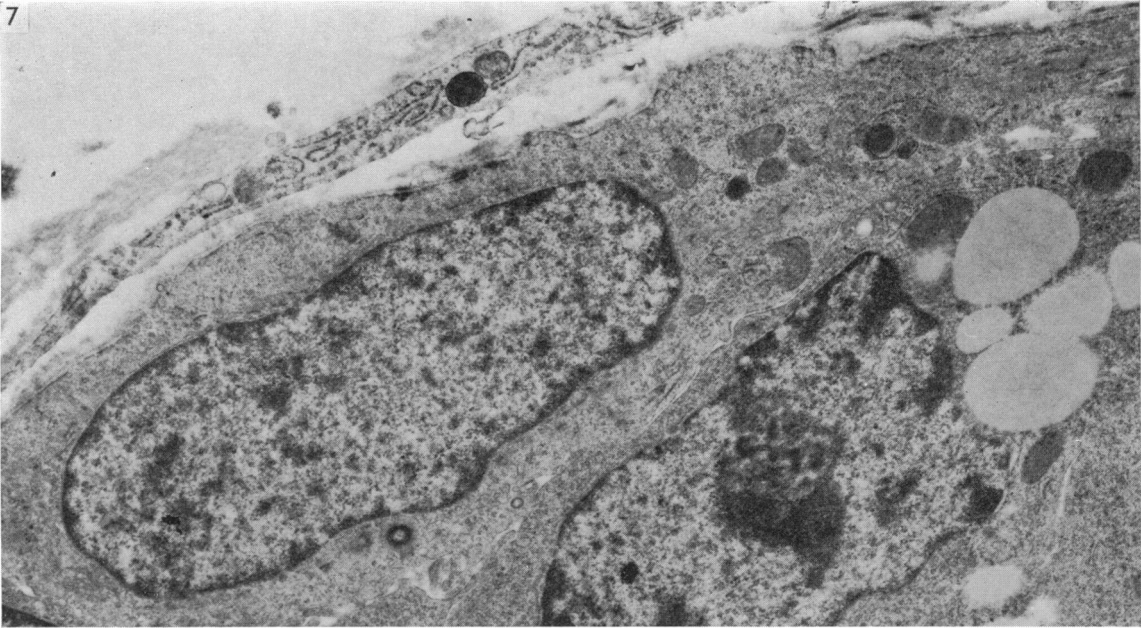


Fig. 7. Seven days pregnant rat. An alveolar myoepithelial cell with dispersed myofilaments. $\times 12500$.

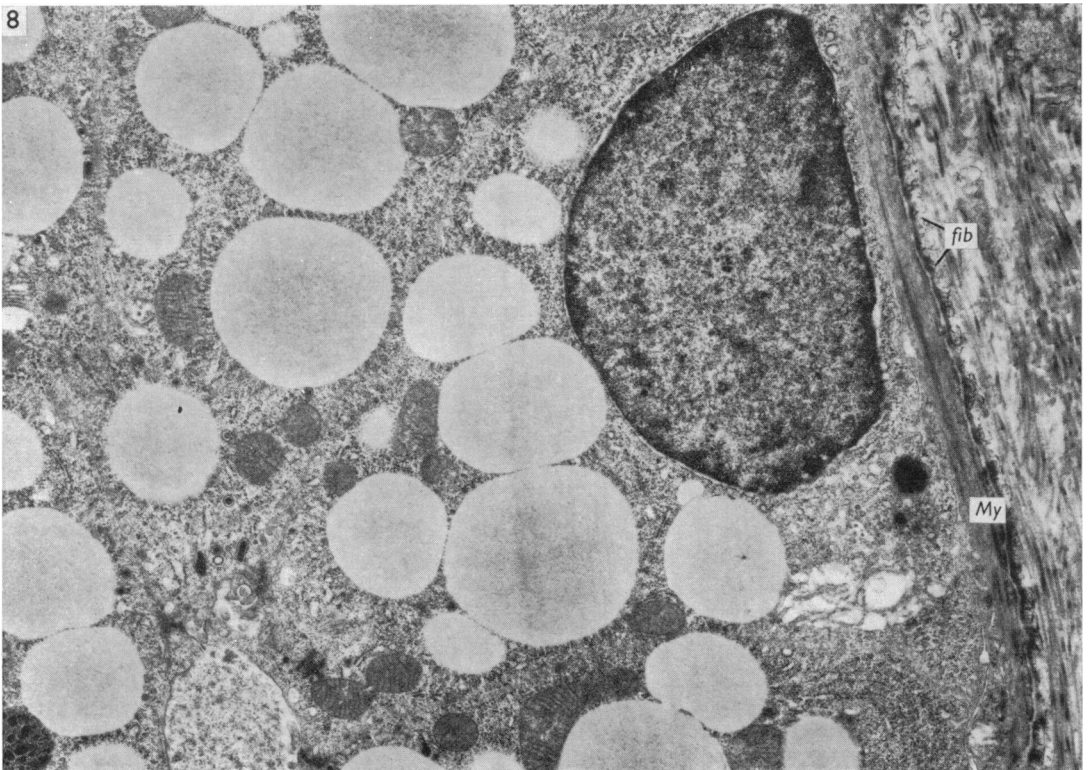


Fig. 8. Nineteen days pregnant rat. A myoepithelial cell process (*My*) is stretched around secretory epithelium. Note the wavy fibrils (*fib*) attached to the basement membrane. $\times 10000$.

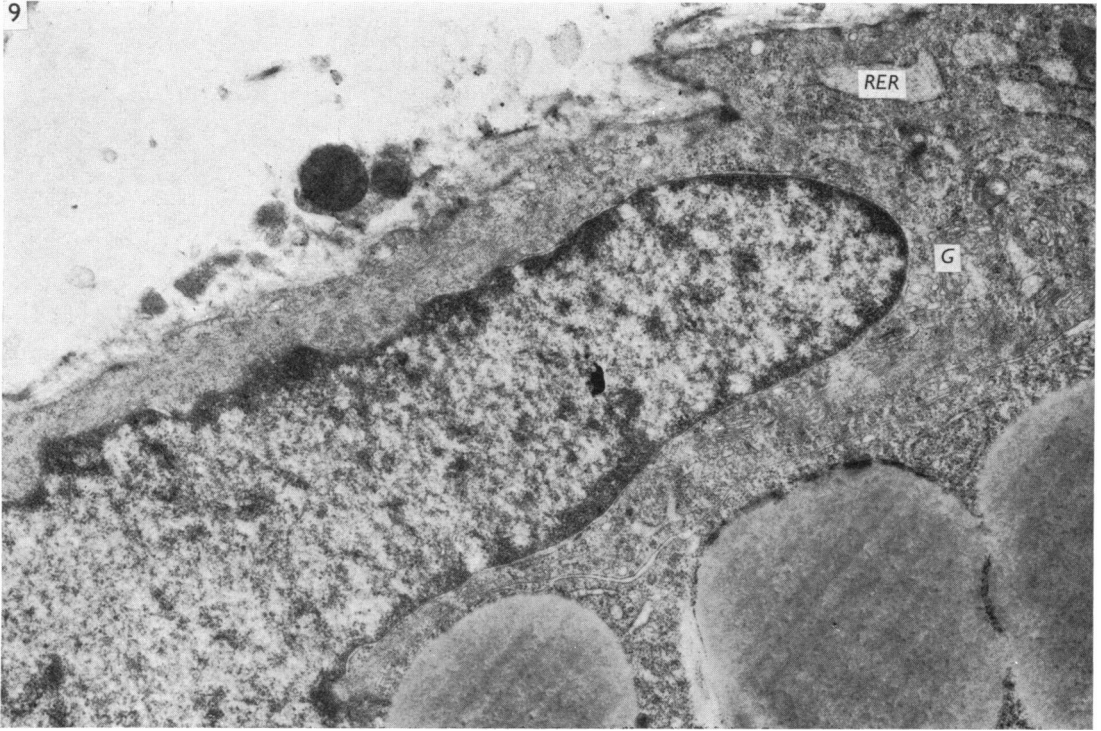


Fig. 9. Nineteen days pregnant rat. Nuclear region of a myoepithelial cell with rough endoplasmic reticulum (*RER*) and Golgi apparatus (*G*). $\times 15000$.

chondria and vesicles between them (Fig. 5). Attachment areas and hemi-desmosomes were prominent. Myofilaments in the alveolar processes were not so distinctive, being more closely packed together with less tendency to form discrete bundles (Fig. 7). Attachment areas alternating with sites of pinocytotic activity were situated along the basal edge of the cells and hemi-desmosomes were found where myofilaments did not approach the cell border.

At nineteen days gestation, two days before parturition, epithelial cells were enlarged due to their accumulation of secretions, and the stretched myoepithelial cells formed thin, tenuous processes around them (Fig. 8), their organelles mainly restricted to the perinuclear area (Fig. 9). Rough endoplasmic reticulum was found, with cisternae dilated by their homogeneous contents of medium electron density. Golgi apparatus was also evident, while ribosomes filled the spaces between organelles. Mitochondria were small, with a dense matrix. Occasionally multivesicular bodies and fat droplets were found.

Around the larger ducts, radial finger-like processes with well developed desmosomes were found, the tonofilaments being especially prominent on the side of the epithelial cells (Fig. 10). Overlapping myoepithelial cell processes were also connected to each other by desmosomal junctions. Attached and exterior to the basement

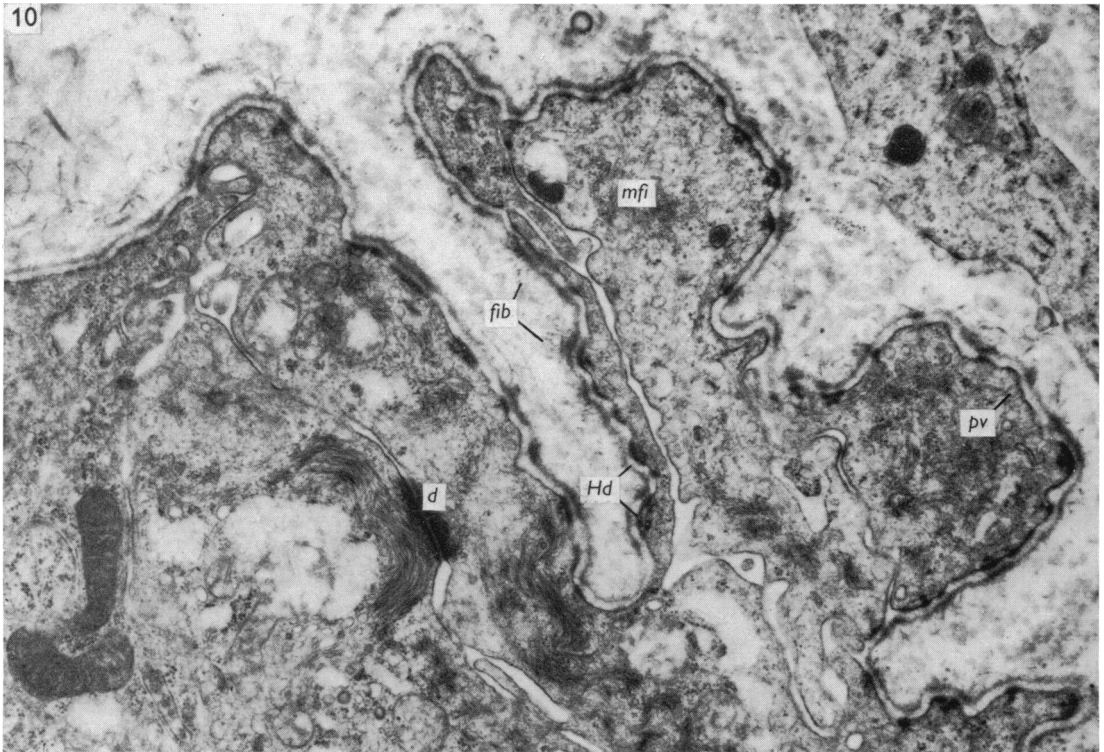


Fig. 10. Nineteen days pregnant rat. Radial processes with well-developed desmosomes (*d*) and clumped myofilaments (*mfi*). Hemi-desmosomes (*Hd*) and pinocytotic vesicles (*pv*) are numerous and wavy fibrils (*fib*) can be seen around the basement membrane. $\times 18750$.

membrane of several regions were small, wavy, fibrillar complexes, 20–40 nm in diameter and having a distinctive banding pattern with no apparent repeating unit.

Lactation

During this phase of development, the appearance of the myoepithelial cell was transformed, the cell cytoplasm being packed with myofilaments as its contractile function was realized (Fig. 11).

The elongated and generally lobed nucleus was often displaced into the apical part of the cell and had electron-dense chromatin aggregated beneath the nuclear membrane and dispersed irregularly throughout the rest of the nuclear body. Electron-lucent areas were found beneath 75 nm wide nuclear pores. A distinct nucleolus was only occasionally found.

The increase in the number of myofilaments pushed most of the other organelles into the perinuclear areas and basal and apical 'feet', which were irregular processes found on the basal, and occasionally on the apical, surfaces of the cell (Fig. 12). Golgi dictyosomes with associated vesicles were sometimes seen in the apical region of the cells and rough endoplasmic reticulum cisternae were few and narrow in profile. Several multivesicular bodies were seen, especially in the apical regions of

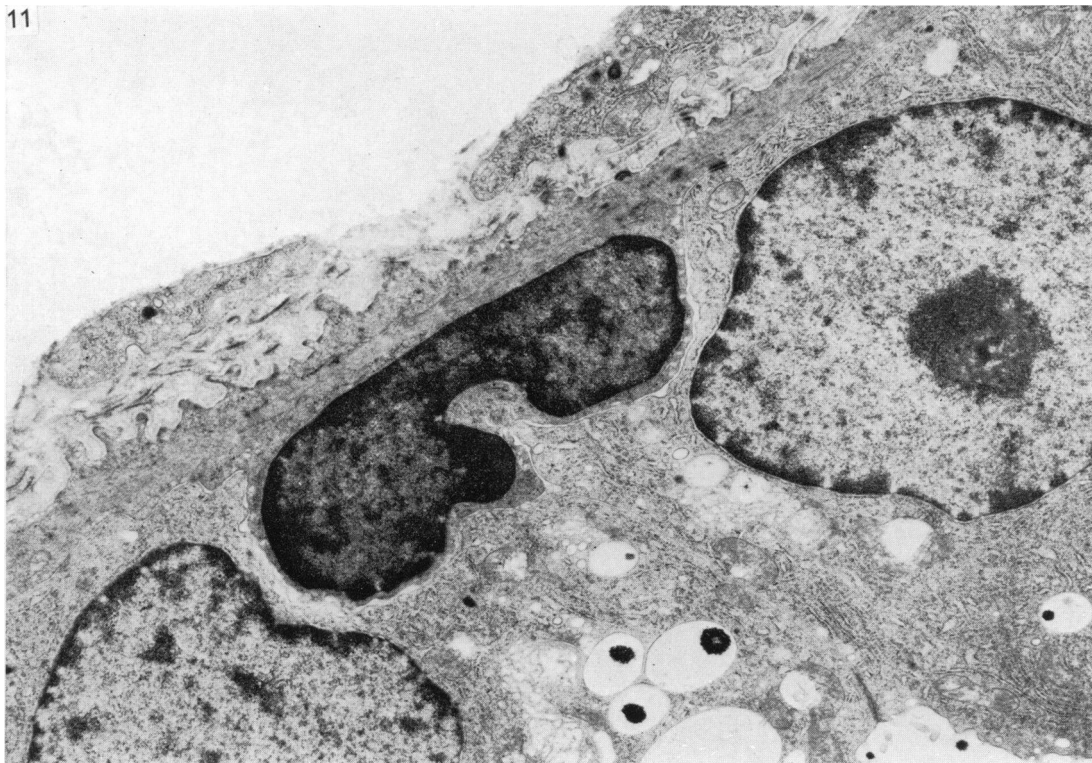

Fig. 11. Lactating rat. A typical myoepithelial cell is shown. Note the increased number of myofilaments compared with that seen in cells of the prelactating gland. $\times 10000$.

the cell. Ribosomes were found clustered together between other organelles and sometimes between arrays of myofilaments. Mitochondria were not conspicuous, as their density was similar to that of the myofilaments. They were rather narrow, and situated around the nucleus or within the basal or apical feet if these were present. Sometimes they were seen lying within cell processes, their longitudinal axes parallel to that of the process.

The myofilaments had an average diameter of 5 nm. Dense bodies were conspicuous, although high magnification failed to reveal details of their ultrastructure. Thicker filaments, 8 nm in diameter, were occasionally found (Fig. 13). Microtubules 18–21 nm wide were also seen lying parallel to the longitudinal axis of the cell.

Alternating with sites of pinocytotic activity on the plasma membrane were dense areas to which myofilaments attached (Fig. 12). Pinocytotic vesicles, 45–85 nm in diameter, were abundant on all cell surfaces, and though some appeared to fuse together inside the cell (Fig. 12) this may have been a false impression due to the plane of section. They did not seem to be associated with the multivesicular bodies.

Occasional hemi-desmosomes were seen on the basal surfaces of the cells and desmosomes formed attachments between myoepithelial and epithelial cells and adjacent myoepithelial cells. The nexus, or close junction, was rarely seen.

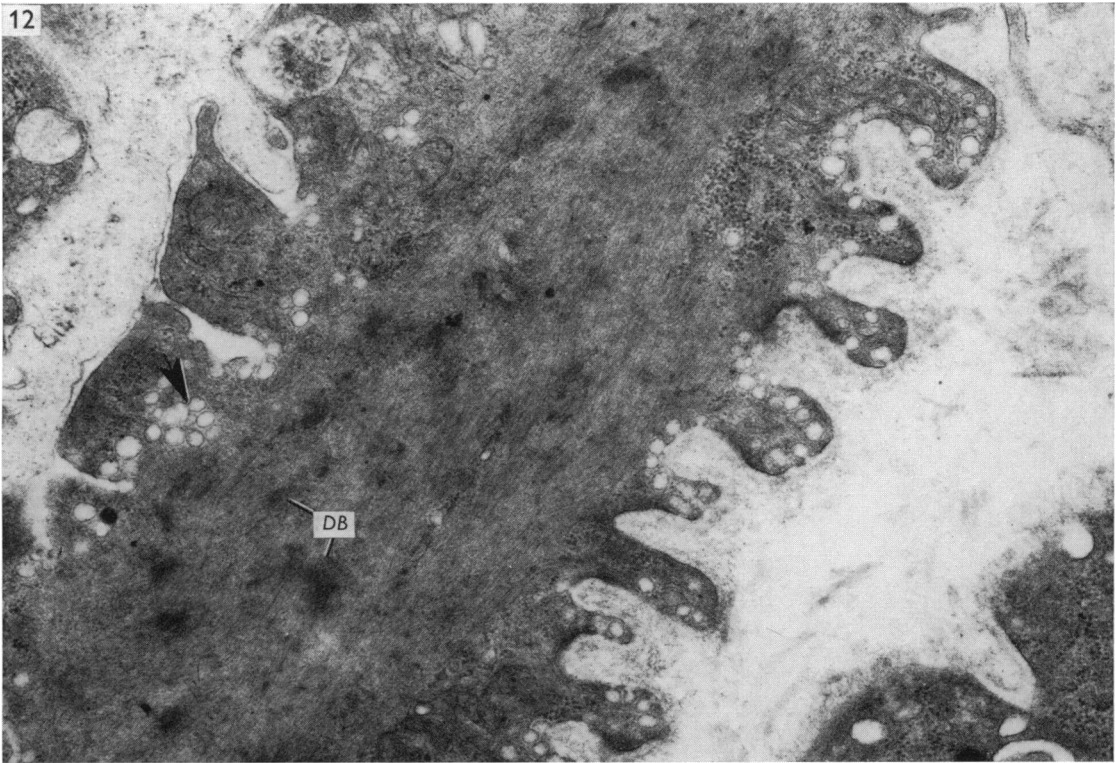


Fig. 12. Lactating rat. A myoepithelial cell showing organelles pushed into basal and apical 'feet' and apparent fusion of pinocytotic vesicles (arrow). Dense bodies (*DB*) are prominent. $\times 30000$.

When alveoli were cut across, in-tucking myoepithelial cells could often be seen with epithelial cells ballooning out around them so that the sides of neighbouring cells almost met under the basal surface of the myoepithelium (Fig. 14). Occasionally, myoepithelial cell processes splayed out to cover two apparently neighbouring alveoli. It is more likely, however, that they were both part of one large, bilobed alveolus (Fig. 15).

Around the large ducts, irregular radial processes were again found, although at this stage they were packed full of myofilaments and made complex interdigitations with epithelial cells (Fig. 16). Hemi-desmosomes were prominent features and the basement membrane had a thick lamina densa. The banded fibrillar complexes described earlier were now well developed around the ducts and measured up to 50 nm in diameter, breaking up into small component fibrils 2 nm wide, which fanned out just before making contact with the basement membrane (Fig. 17). They tended to loop round and attach to the membrane at more than one point.

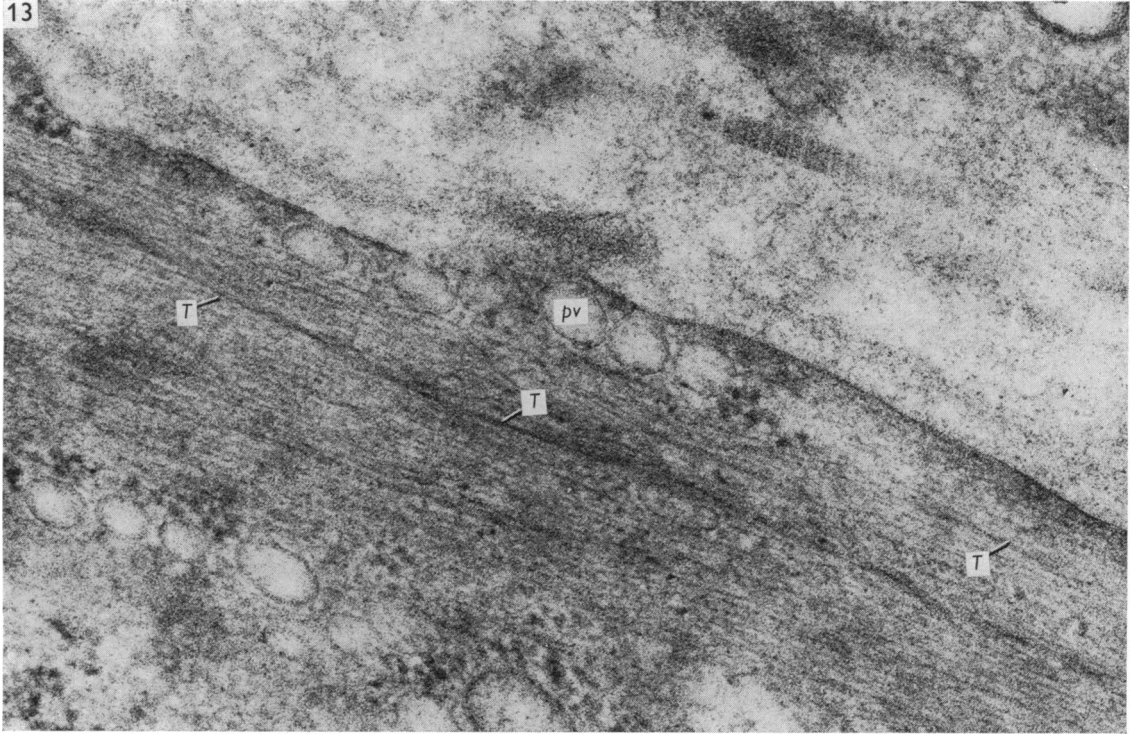


Fig. 13. Lactating rat. High-power view of a myoepithelial cell process showing thick filaments (*T*) and pinocytotic vesicles (*pv*). $\times 90000$.

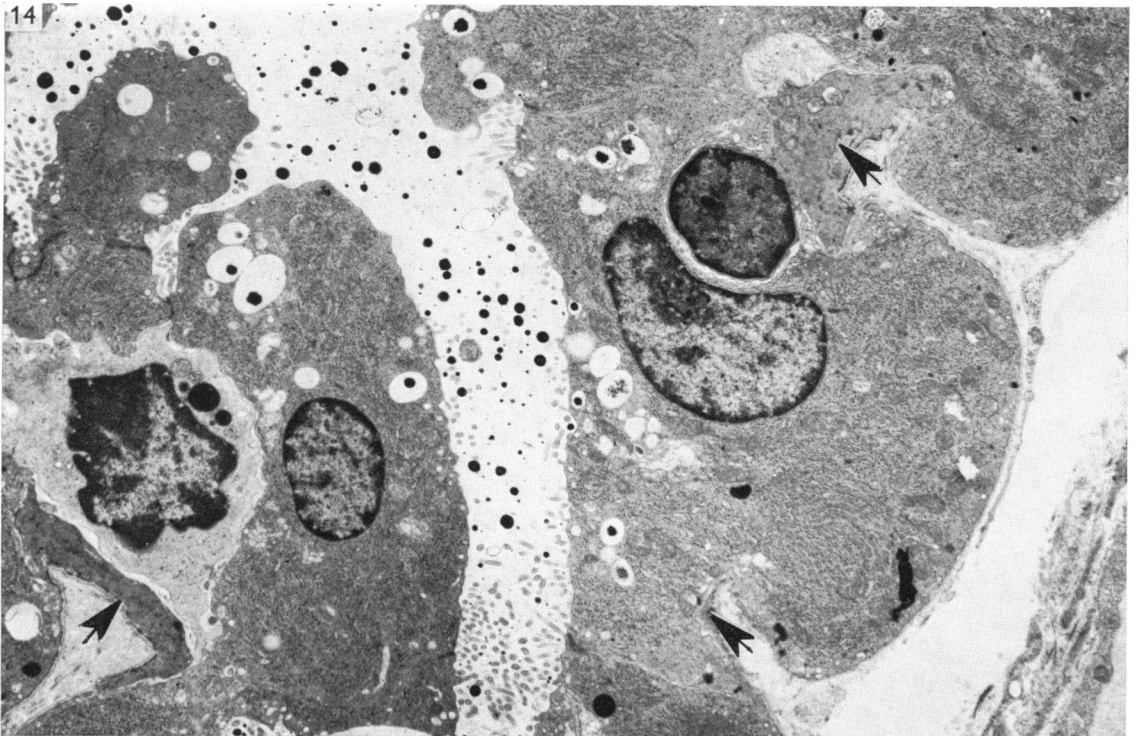


Fig. 14. Lactating rat. Part of an alveolus showing in-tucking myoepithelial cells (arrows). $\times 6250$.

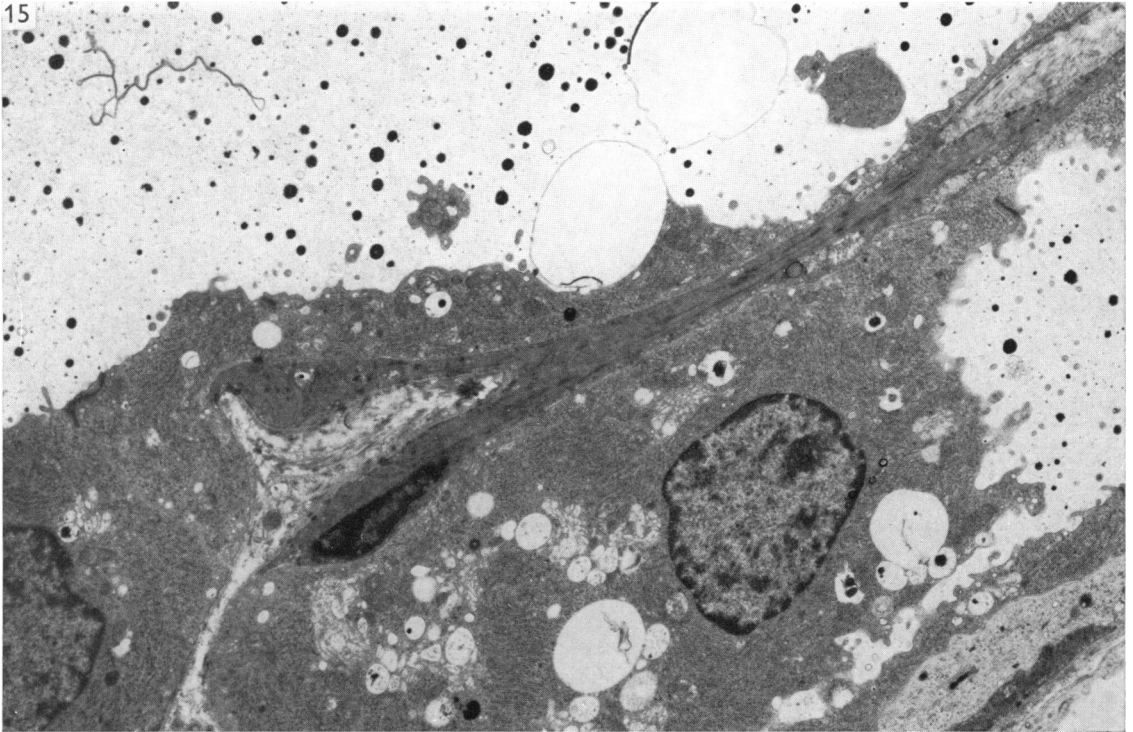


Fig. 15. Lactating rat. A myoepithelial cell is shown spanning two alveoli or one bilobed alveolus. $\times 6250$.

DISCUSSION

It is apparent from this study that the myoepithelium does not become fully developed until the lactation period. This observation, therefore, adds support to the earlier suggestions of Richardson (1949) and Linzell (1955), based on histological and physiological findings, that the main function of myoepithelial cells is that of contraction; the outward bulging of epithelial cells around them, seen during lactation in the present investigation, is added evidence of this. Contraction of the myoepithelium would move secretions from the alveolar lumina into ducts and thence to the cisternae beneath the nipple.

Devine & Somlyo (1971) found that stretching the tissue was important for the visualization of myosin filaments in smooth muscle. Although it was not possible to fix the myoepithelium under mechanical tension, it was presumed that the outward pressure of milk in an alveolus would produce some tension in the cells. Material taken during the lactation period was therefore carefully examined for the presence of thick myosin filaments which have previously been described in smooth muscle (Choi, 1962; Rhodin, 1963; Lane, 1965; Fawcett, 1966; Nonomura, 1968; Pease, 1968; Bennett & Cobb, 1969; Yamauchi & Burnstock, 1969; Cooke, Chase & Cortes, 1970; Lowy, Poulson & Vibert, 1970; Lowy & Small, 1970; Devine & Somlyo, 1971; Garamvolgyi, Visi & Knoll, 1971). Thick filaments were found, but

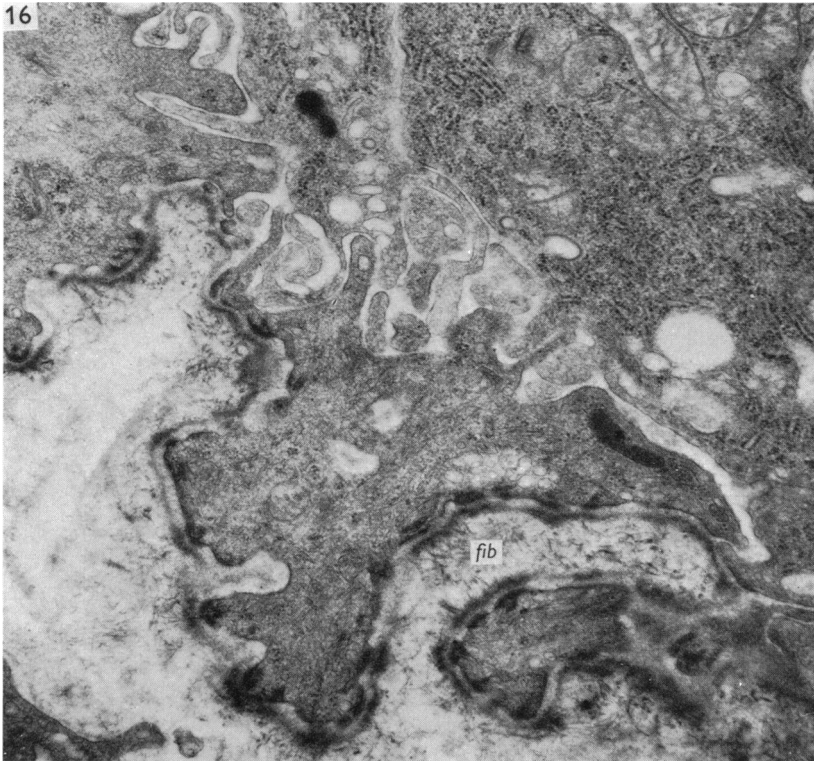


Fig. 16. Lactating rat. Radial processes showing the high density of myofilaments and interdigitation with the epithelium. Note the numerous banded fibrils (*fib*), hemi-desmosomes, and the thick lamina densa on the basement membrane. $\times 20000$.

their appearance was not consistent and often, when followed for a short distance, the 'myosin' filament could be seen to divide into two actin-sized filaments. A glycerination procedure may be required to remove extraneous matter before true myosin filaments are visualized in these cells.

A comparison between ductular and alveolar myoepithelium shows that the distribution of myofilaments varies with the location of the cells. Except during lactation, the radial processes show a sparse population of myofilaments with numerous hemi-desmosomes and few attachment areas in contrast with their homogeneous distribution in the alveolar cells. When the duct is cut in cross-section, myofilaments run through the plane of the micrograph, presumably in order to exert a longitudinal force on the duct, and therefore attachment areas are not frequently visualized. The interdigitations, seen especially in the lactation period, increase the grip of these cells on the epithelium as, being spindle-shaped, they lack the stellate structure of the alveolar myoepithelium. During lactation the radial processes contain masses of myofilaments although hemi-desmosomes are still numerous; the hemi-desmosomes provide support and attachment to the stroma, which is further strengthened by the presence of looping, banded fibrillar complexes. Brody (1960) described 'reticular

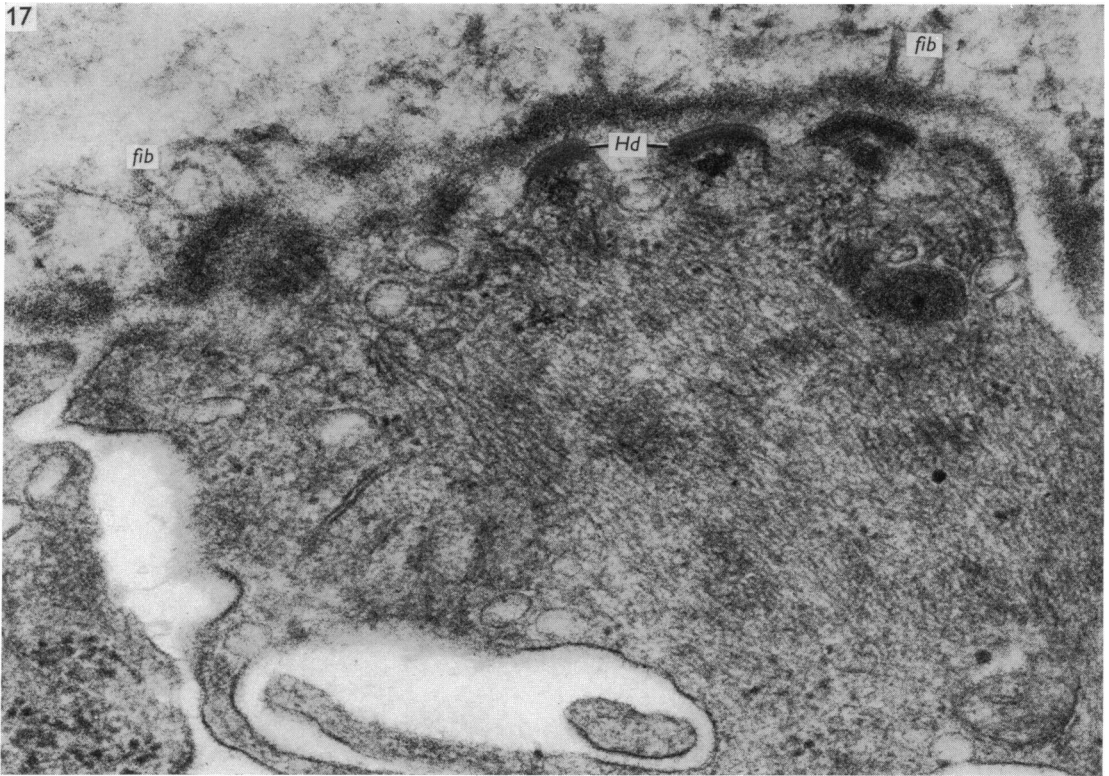


Fig. 17. Lactating rat. Part of the duct myoepithelium showing banded fibrils (*fib*) and hemi-desmosomes (*Hd*) associated with the basement membrane. $\times 62\,500$.

filaments', smaller than collagen and with periodic banding, under the normal human epidermis, and similar fibrils, but with irregular banding, have also been found in human oral mucosa (Susi, Belt & Kelly, 1967), in the dermis of *Bufo marinus*, *Rana pipiens* and *Amblystoma punctatus*, and comparable, though less frequent, fibrils have been seen in the skin, lingual mucosa and mucosa of the gastric fundus of the rat (Palade & Farquhar, 1965). In all cases they were associated with the basement membrane, as in this study. Their interdigitations with connective tissue fibrils may add support to tissues that are frequently deformed, for they are most numerous during the lactation period. The increase in the number of tonofilaments towards the end of pregnancy, and the large desmosomes found in the ducts, also play a part in ensuring firm adhesion between cells. The nexus, or close junction, is considered to be a site of electronic coupling rather than a mechanical union between cells (Dewey & Barr, 1964; Fawcett, 1966) and is only rarely seen between adjacent myoepithelial cells, possibly because their contraction is under hormonal control.

In this study, pinocytotic vesicles were found to increase in both size and number during lactation. However, their function has not yet been elucidated either in myoepithelial or smooth muscle cells, and it is not known whether they are involved in contraction mechanisms or in transport of materials. In the lactating mammary

gland, both contractile and metabolic requirements are at their greatest, and so it is not possible to say which particular requirement is being met. Gansler (1961) noted an increase in their size and number upon muscle contraction in the guinea-pig colon, and Kurosumi, Kitamura & Iijima (1959) and Lane (1967) also suggested that they function in the contraction mechanism. Rostgaard & Barnett (1964), Ellis (1965), Bässler *et al.* (1967), Girardie (1967) and other workers have considered them to be concerned with uptake or transport of materials.

The ability of myoepithelial cells to supplement the secretory activity of the epithelium has been the subject of debate. In all the material examined only one cell was seen to exhibit significant secretory activity together with numerous myofilaments, on the second day of gestation. Several secretory epithelial cells resting on the basement membrane had a few filaments in them, and traces of dark attachment areas on the basal plasma membrane.

During lactation, when secretory processes were most active, very little fat was found in the myoepithelial cells. Girardie (1967), however, accorded myoepithelial cells a feeble secretory activity, whereas Murad & von Haam (1967) suggested that not only were they responsible for early ductular proliferation during pregnancy but that later they also secreted fat and transformed into epithelial cells. If they were capable of secretion, the mode of release of the fat and protein would present difficulties as either a cytoplasmic extension would have to insinuate itself through the epithelial cells to the lumen, or the fat would be released into the intercellular spaces. The fat droplets produced at other times are presumably related to metabolic processes within the cell.

Whether, as Murad & von Haam (1967) suggested, their ability to secrete is connected with a transformation from myoepithelium to secretory epithelium, is not known. Until the movements of cells are followed over a period of time, it will not be possible to reach a definite conclusion regarding the relationship of myoepithelium to secretory epithelial cells during lactation.

SUMMARY

1. The myoepithelium of the mammary glands of rats 2, 7 and 19 days pregnant and on the twenty-third day of lactation was examined using the electron microscope.
2. Hyperplasia of the myoepithelium was seen in the first half of the gestational period, although there were no detectable ultrastructural changes in the cells.
3. By nineteen days gestation there was an increase in the size of desmosomes and associated tonofilaments in adjoining cells of the ducts. Alveolar myoepithelial cells were stretched by the enlarged epithelial cells to form thin, tenuous processes.
4. In the lactating mammary gland, the myoepithelium exhibited a great increase in the number of myofilaments which then filled most of the cytoplasm of the cell processes, displacing many other organelles to the perinuclear area of the cell. There was an increase in the size and number of pinocytotic vesicles and also pronounced development of banded fibrillar complexes exterior to the basement membrane and attached to it.
5. There was no evidence of the myoepithelium supplementing the secretory activity of the epithelial cells during lactation.

I am indebted to Dr George Williams for his interest in this project and also to Dr A. W. Jones and Dr A. J. Barson for their advice and encouragement. I would also like to thank Mr H. Hutton for his care of the laboratory animals, and Mrs A. Nuraney for typing the manuscript.

REFERENCES

- BARGMANN, W. & KNOOP, A. (1959). Über die Morphologie der Milchsekretion. Licht und elektronenmikroskopische Studien an der Milchdrüse der Ratte. *Zeitschrift für Zellforschung und mikroskopische Anatomie* **49**, 344–388.
- BÄSSLER, R., SCHAFER, A. & PAEK, S. (1967). Elektronenmikroskopische und histochemische Untersuchungen zur Morphologie und Function myoepithelialer Zellen. *Verhandlungen der Deutschen Gesellschaft für Pathologie (Stuttgart)* **51**, 301–308.
- BENNETT, T. & COBB, J. L. S. (1969). Studies on the avian gizzard: morphology and innervation of the smooth muscle. *Zeitschrift für Zellforschung und mikroskopische Anatomie* **96**, 173–185.
- BRODY, I. (1960). The ultrastructure of the tonofibrils in the keratinization process of normal human epidermis. *Journal of Ultrastructure Research* **4**, 264–297.
- CHOI, J. K. (1962). The fine structure of the smooth muscle of the chicken's gizzard. *5th International Congress on Electron Microscopy in Philadelphia 2*. New York: Academic Press.
- COOKE, P. H., CHASE, R. H. & CORTES, J. M. (1970). Thick filaments resembling myosin in electrophoretically extracted vertebrate smooth muscle. *Experimental Cell Research* **60**, 237–246.
- DEVINE, C. E. & SOMLYO, A. P. (1971). Thick filaments in vascular smooth muscle. *Journal of Cell Biology* **49**, 636–649.
- DEWEY, M. M. & BARR, L. (1964). A study of the structure and distribution of the nexus. *Journal of Cell Biology* **23**, 553–586.
- ELLIS, R. A. (1965). Fine structure of the myoepithelium of the eccrine sweat glands of man. *Journal of Cell Biology* **27**, 551–563.
- FAWCETT, D. W. (1966). *The Cell: Its Organelles and Inclusions*. Philadelphia: Saunders.
- FELDMAN, J. D. (1961). Fine structure of the cow's udder during gestation and lactation. *Laboratory Investigations* **10**, 238–255.
- GANSLER, H. (1961). Struktur und Funktion der glatten Muskulatur. II. Licht- und elektronenmikroskopische Befunde an Hohlorganen von Ratte, Meerschweinchen und Mensch. *Zeitschrift für Zellforschung und mikroskopische Anatomie* **55**, 724–762.
- GARAMVOLGYI, N., VISI, E. S. & KNOLL, J. (1971). The regular occurrence of thick filaments in stretched mammalian smooth muscle. *Journal of Ultrastructure Research* **34**, 135–143.
- GIRARDIE, J. (1967). Fonction catabolique de l'épithélium mammaire. Etude histochemique et ultrastructurale. *Zeitschrift für Zellforschung und mikroskopische Anatomie* **80**, 385–412.
- HELMINEN, H. J. & ERICSSON, J. L. E. (1968). Studies on mammary gland involution. 1. On the ultrastructure of the lactating mammary gland. *Journal of Ultrastructure Research* **25**, 193–213.
- HOLLMAN, K. H. (1959). L'ultrastructure de la glande mammaire normale de la souris en lactation. Etude au microscope électronique. *Journal of Ultrastructure Research* **2**, 423–443.
- KUROSUMI, K., KITAMURA, T. & IJIMA, T. (1959). Electron microscope studies on the human axillary apocrine sweat gland. *Archivum histologicum japonicum* **16**, 523–566.
- KUROSUMI, K., KOBAYASHI, Y. & BABA, N. (1968). The fine structure of mammary glands of lactating rats, with special reference to the apocrine secretion. *Experimental Cell Research* **50**, 177–192.
- LANE, B. P. (1965). Alterations in the cytologic detail of intestinal smooth muscle cells in various stages of contraction. *Journal of Cell Biology* **27**, 199–213.
- LANE, B. P. (1967). Localization of products of A.T.P. hydrolysis in mammalian smooth muscle. *Journal of Cell Biology* **34**, 713–720.
- LINZELL, J. L. (1955). Some observations on the contractile tissue of mammary glands. *Journal of Physiology, London* **130**, 257–266.
- LOWY, J., POULSON, F. R. & VIBERT, P. J. (1970). Myosin filaments in vertebrate smooth muscle. *Nature, London* **225**, 1053–1054.
- LOWY, J. & SMALL, J. V. (1970). The organisation of myosin and actin in vertebrate smooth muscle. *Nature, London* **227**, 46–51.
- MURAD, T. M. & VON HAAM, E. (1967). Transformation of myoepithelial cells into epithelial cells in pregnancy. *Proceedings of the 25th Annual Meeting of the Electron Microscopy Society of America*, pp. 62–63.
- NONOMURA, Y. (1968). Myofilaments in smooth muscle of guinea pig's taenia coli. *Journal of Cell Biology* **39**, 741–745.

- PALADE, G. E. & FARQUHAR, M. G. (1965). A special fibril of the dermis. *Journal of Cell Biology* **27**, 215–224.
- PEASE, D. C. (1968). Structural features of unfixed mammalian smooth and striated muscle prepared by glycol dehydration. *Journal of Ultrastructure Research* **23**, 280–303.
- PITELKA, D. R., KERKOF, P. R., GAGNE, H. T., SMITH, S. & ABRAHAM, S. (1969). Characteristics of cells dissociated from mouse mammary glands. 1. Method of separation and morphology of parenchymal cells from lactating glands. *Experimental Cell Research* **57**, 43–62.
- REYNOLDS, E. S. (1963). The use of lead citrate at high pH as an electron-opaque stain in electron microscopy. *Journal of Cell Biology* **17**, 208–212.
- RHODIN, J. A. G. (1963). *An Atlas of Ultrastructure*. Philadelphia: Saunders.
- RICHARDSON, K. C. (1949). Contractile tissues in the mammary gland, with special reference to myoepithelium in the goat. *Proceedings of the Royal Society, Series B* **136**, 30–45.
- ROSTGAARD, J. & BARNETT, R. J. (1964). Fine structure localisation of nucleoside phosphatases in relation to smooth muscle cells and unmyelinated nerves in the small intestine of the rat. *Journal of Ultrastructure Research* **11**, 193–207.
- SEKHRI, K. K., PITELKA, D. R. & DE OME, K. B. (1967). Studies of mouse mammary glands. 1. Cyto-morphology of the normal mammary gland. *Journal of the National Cancer Institute* **39**, 459–490.
- SUSI, F. R., BELT, W. D. & KELLY, J. W. (1967). Fine structure of fibrillar complexes associated with the basement membrane in human oral mucosa. *Journal of Cell Biology* **34**, 686–690.
- TOKER, C. (1967). Observations on the ultrastructure of a mammary ductule. *Journal of Ultrastructure Research* **21**, 9–25.
- WATSON, M. L. (1958). Staining of tissue sections for electron microscopy with heavy metals. *Journal of Biophysical and Biochemical Cytology* **4**, 475–478.
- WAUGH, D. & VAN DER HOEVEN, E. (1962). Fine structure of the human adult female breast. *Laboratory Investigations* **11**, 220–228.
- WELLINGS, S. R., DE OME, K. B. & PITELKA, D. R. (1960). Electron microscopy of milk secretion in mammary gland of C3H/Crgl mouse. 1. Cytomorphology of prelactating and lactating gland. *Journal of the National Cancer Institute* **25**, 393–421.
- YAMAUCHI, A. & BURNSTOCK, G. (1969). Post-natal development of smooth muscle cells in the mouse vas deferens. A fine structural study. *Journal of Anatomy* **104**, 1–15.