

Normal development of the jaws and teeth in pigs, and the delay and malocclusion produced by calorie deficiencies

C. H. TONGE AND R. A. McCANCE

*University of Newcastle-upon-Tyne Dental School, Newcastle-upon-Tyne and
Sidney Sussex College, Cambridge*

(Accepted 30 January 1973)

INTRODUCTION

The occlusion of the teeth, at maturity, depends upon the integrated growth of the dental, skeletal and soft tissues of both jaws. Genes determine the maximum growth of which each individual and organ is capable, but all growth is liable to environmental limitations.

Therefore, in considering the causes of dental irregularities and malocclusions, genetic direction, growth potential, the developmental time scale, and dietary variations must all be considered. Lundström (1951), for instance, put forward evidence that the size of the jaw and the size of the teeth were under separate genetic direction, so that malocclusions and irregularities might result from the fusion of two ethnic groups. By comparing the permanent dentitions of Anglo-Saxons with their modern British representatives Lavelle (1968) has shown that the incisors, premolars and canines have become smaller during the last 12-14 centuries, and so have the dimensions of the jaw; the size of the molars, on the other hand, has increased. Jeffreys (1969) claimed that in Wistar rats environmental influences on the pattern of growth were small compared to those operating on the rate of growth, but that tooth size was subject to environmental influence, and that the degree of 'catch up' growth varied according to the time and extent of the period of retardation.

Tonge & McCance (1965) depressed the overall growth of pigs by giving them a calorie-deficient diet until they were a year old. This retarded the development of the jaw more than that of the teeth and resulted in overcrowding, displacement and malocclusion. The rehabilitation of similarly undernourished pigs (McCance, Owens & Tonge, 1968) led to considerable 'catch up' growth but abnormal siting, impaction and malalignment of the teeth remained and, with them, faulty occlusion. An alteration in the environment at the appropriate age had, therefore, upset the harmonious development of the jaws and teeth, and left permanent stigmata behind it. Further work on this subject seemed highly desirable, notably (1) to work out the time course of normal dental development in 'Large White' pigs, and (2) to set against this the delays and abnormalities caused by undernutrition and to study quantitatively the immediate and subsequent effects.

There are two ways of considering the effects of undernutrition on the jaws and teeth. The first is the way in which normal dental development is often set out, showing in a table the chronological time from conception at which each tooth can

Table 1. *The numbers of animals killed at each age, their characteristic weight at this time and their treatment during life*

Age at death, all animals (months)	Normal animals always well-fed		Experimental animals calorie-deficient for 12 months, then well-fed		
	Number killed at each age	Characteristic weights kg	Months rehabilitated	Number killed at each age	Characteristic weights kg
0.7-1	6	5.4	0	—	—
4	2	55.0	0	—	—
8	3	130.0	0	—	—
12	5	180.0	0	13	5.5
16	5	230.0	4	2	75.0
20	4	250.0	8	2	135.0
24	2	270.0	12	2	178.0
30	4	295.0	18	2	220.0
36 or over	6	300.0	24 or over	12	240.0

first be detected and the course of its calcification and eruption. This is satisfactory enough for normal development, when everything else may be assumed to be going according to the genetic plan, and has been employed in Tables 2 and 3. The effects of undernutrition, however, cannot be represented satisfactorily by this method alone, for undernutrition produces relative and absolute changes in the spatial arrangements of the teeth in the jaws. The only way to present this data is by diagrams and this has accordingly been done in Figs. 1-15.

MATERIALS AND METHODS

Seventy normal 'Large White' pigs ranging in age from the 80th day of gestation to the 5th year of life were used to establish the growth rate of normal pigs in the colony. Thirty-seven of these were used for the study of normal dental development (Table 1). Forty other 'Large White' pigs were subjected to severe caloric restriction from early in life till they were a year old. Thirteen of these were then killed, and twenty-two others were rehabilitated by being given an excellent diet *ad lib.*, and killed for examination at appropriate intervals afterwards. Thus the number of undernourished animals used to establish their growth curves also exceeded those used for the dental work (see Table 1).

The pigs were reared on the same food and very much on the lines described by McCance (1960) and Cabak, Gresham & McCance (1962). These diets provide plenty of protein for young growing pigs and a sufficiency of vitamins and minerals. Minor modifications, however, were made in the light of experience, and the standardized procedure in the present investigation was as follows. (1) The piglets were taken from the sow when they weighed 3.2 to 3.4 kg and were about 10 days old. (2) They were weighed every day. (3) Their food intake was measured accurately every day. The amount required was usually about 45 g of the 'pellets' and 45 g of the meal mixture. (4) The piglets were allowed to gain about 50 g each week by varying the food intake a little according to their health and progress. The number

of animals killed as controls for the undernourished ones and the characteristic weights of all of them at the various age intervals are shown in Table 1. As already stated, the numbers of animals weighed exceeded the numbers used for the dental work. When the animals, normal or abnormal, were killed, the head was removed and the jaws were dissected out, cleaned, photographed, and measured. The details of their articulation and occlusion were then studied by placing the head of the mandibular condyle in the glenoid fossa and examining the patterns of attrition found on the teeth. The upper and lower jaws were then bisected longitudinally, and X-ray photographs were obtained by standardized methods. Abnormalities found in the experimental group were compared with the findings in the normal group. Tracings were made from the radiographs, and by reference to the jaws themselves and their occlusal relationships these tracings were then superimposed in 'centric' occlusion. A further overall tracing was made in this position.

The teeth were classified according to the formula given by Peyer (1968), and not as they were classified by Bodegom (1969). The latter has investigated in some detail the dental development of the miniature pig during life till the animals were a little over a year old. Unfortunately, his approach and techniques were so different from ours, that it is very difficult to compare the two sets of results.

Normal animals

The early stages

Birth takes place at about 115 days gestation in 'Large White' pigs, and the course of development of the deciduous teeth is given in Table 2. Minor differences between timings in the upper and lower jaws were noted but are not included in the table. Histologically, calcification was observed in all the deciduous teeth except the third molar by the 80th day of gestation. The first permanent premolars had calcified most of their crowns by the end of gestation, but there was no radiological evidence of calcification in any of the other permanent teeth at this time.

Four weeks after birth

Fig. 1 shows a tracing of the jaws of an animal 4 weeks old in occlusion. Further information about such jaws was given by Tonge & McCance (1965). There were again minor differences between the two jaws which are not noted in Tables 2 and 3. There was only contact between two teeth on each side in the molar segment, but these animals were still being wholly breast-fed, and inspection showed that, if the eruption of the other teeth went as it should, an interdigitating pattern of the cusps would be established. There was adequate space for the eruption and proper occlusion of the deciduous dentition, and the evidence suggested that this would also be so for the permanent teeth, for histological examination demonstrated the presence of the germs of the uncalcified ones in the expected positions.

Four months after birth

Fig. 2 shows the dental development of a normal animal 4 months old, and the stages reached by the various teeth are given in Tables 2 and 3. The deciduous ones were well advanced and occluded normally. The first premolar had erupted in the

Table 2. *The development of the deciduous teeth in normal animals and in those subjected to undernutrition for 12 months*

Stages of development Normal animals	Deciduous teeth						
	i1	i2	i3	C	m1	m2	m3
1. Calcification visible radiologically	—	90 day f	—	—	93 day f	90 day f	90 day f
2. Crown complete, roots being formed	90 day f	Birth	90 day f	90 day f	Birth	93 day f	93 day f
3. Eruption beginning	93 day f	4 weeks	93 day f	93 day f	4 weeks	Birth	Birth
4. Occlusal level attained	4 weeks	—	Birth	Birth	—	±4 weeks	±4 weeks
5. Apices of roots closed	4 months	4 months	4 weeks	4 weeks	±4 months	±4 months	4 months
6. Roots being resorbed	8-12 months	8-12 months	4-8 months	4-8 months	8-12 months	8-12 months	8-12 months

In the experimental animals the development of the deciduous teeth was normal up to the age of about 4 weeks. Subsequent development would almost certainly have been somewhat delayed, but, in animals that died suddenly at 5 months and 6 months, the apices of the roots were all closed so that only the third incisor and the canine can have been much delayed. The state of the teeth at 12 months is described on pp. 11-12. The second deciduous incisors and the first and third molars were still in position after the first four months of rehabilitation, and there were sometimes still relics of the second deciduous molar but the other deciduous teeth had all been shed by that age.

Key: i = incisor. C = canine. m = molar. f = fetus.

Table 3. The development of the permanent teeth in normal animals and in those subjected to undernutrition for 12 months

Stages of development	Permanent teeth											
	I1 U, L	I2 U, L	I3 U, L	C U, L	PM1* U, L	PM2 U, L	PM3 U, L	PM4 U, L	M1 U, L	M2 U, L	M3 U, L	
Normal animals												
1. Calcification visible radiologically	4 m	8 m	8 m	4 m	90 d.f.	4-5 m	4-5 m	5 m	93 d.f.	4 m	8 m	
2. Crown complete, roots being formed	5-8 m	12 m	5-8 m	4 m	4-8 m	±8 m	8-12 m	—	—	8 m	12 m	
3. Eruption beginning	8 m	16 m	±12 m	8-12 m	4-6 m	±12 m	8-12 m	8-12 m	4 m	16 m	16 m	
4. Occlusal level attained	12 m	20 m	±12 m	12-16 m	5-8 m	12-16 m	12 m	8-12 m	4 m	24 m	24 m	
5. Apices of roots closed	16 m	24 m	12-16 m	16 m	12 m	16 m	16 m	12-16 m	8 m	30 m	30 m	
Experimental animals												
1. Calcification visible in the germ	—	12-16 m	—	—	—	12 m	12 m	12 m	—	—	12 m	
2. Crown complete, roots being formed	12 m	16-20 m	12-16 m	12 m	—	16 m	12-16 m	12-16 m	—	12 m	16-20 m	
3. Eruption beginning	—	24 m	20-24 m	12-16 m	—	16-20 m	16 m	16-20 m	±12 m	12-16 m	24 m	
4. Occlusal level attained	16 m	—	20-24 m	16-24 m	12 m	20-24 m	16-20 m	16-20 m	12-16 m	16 m	24-30 m	
5. Apices of roots closed	20 m	30 m	24 m	30 m	16-20 m	30 m	20-24 m	20 m	16 m	20 m	30-36 m	

* The first premolar is an inconstant tooth in pigs and more frequently found in the maxilla than the mandible. N.B. Owing to the way in which the investigation was made the experimental animals were first examined when they were 12 months old and had been undernourished for almost the whole of that time.

Key: I = incisor. C = canine. PM = premolar. M = molar. U = upper. L = lower. m = months. d.f = days of fetal gestation.

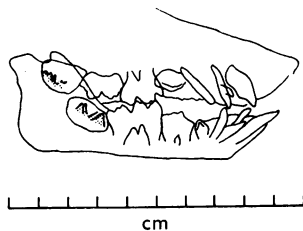


Fig. 1. Normal jaws 4 weeks after birth. In all the figures the outlines of the deciduous teeth are unshaded and those of the permanent teeth shaded.

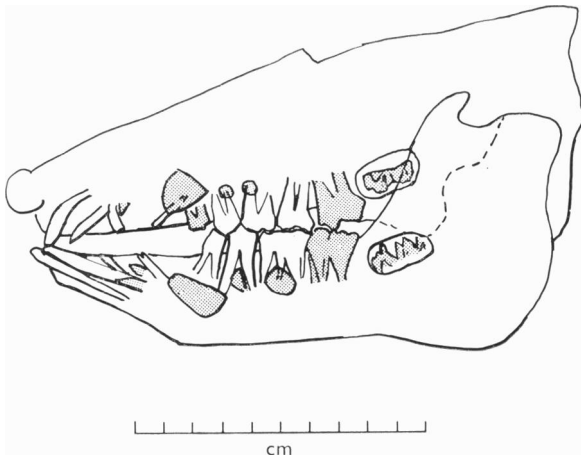


Fig. 2. Normal jaws 4 months after birth.

maxilla, but the roots were not completely calcified, and the corresponding tooth (Table 3) was not visible in the mandible. The first permanent molar was just emerging in its correct position and alignment in both jaws. The cusps of the second permanent molars were beginning to calcify in both jaws. In the upper one the crown lay in a good position to emerge as the maxilla grew in the posterior direction and in the lower one a space was beginning to form for its eruption between the first permanent molar and the base of the coronoid process of the mandible.

Eight months after birth

The position reached by each tooth is shown spatially in Fig. 3, and all the individual stages of development in Tables 2 and 3. The deciduous dentition occluded normally. The permanent canines had not yet erupted, and were lying more horizontally than would be expected at eruption, but there was adequate room for this to take place. The mental foramen was situated below and between the third and fourth premolars in the mandible. The crowns of the second and third molars in both jaws were calcifying and lying in good positions to erupt, and the permanent dentition promised to reach normal centric occlusion.

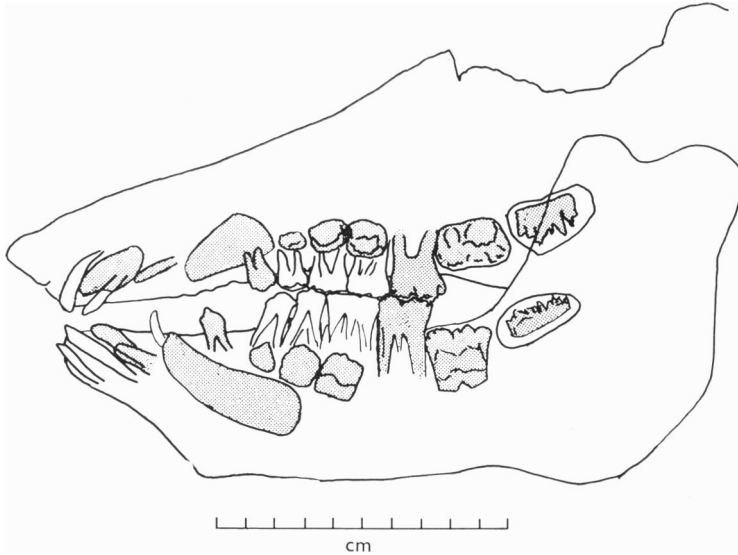


Fig. 3. Normal jaws 8 months after birth.

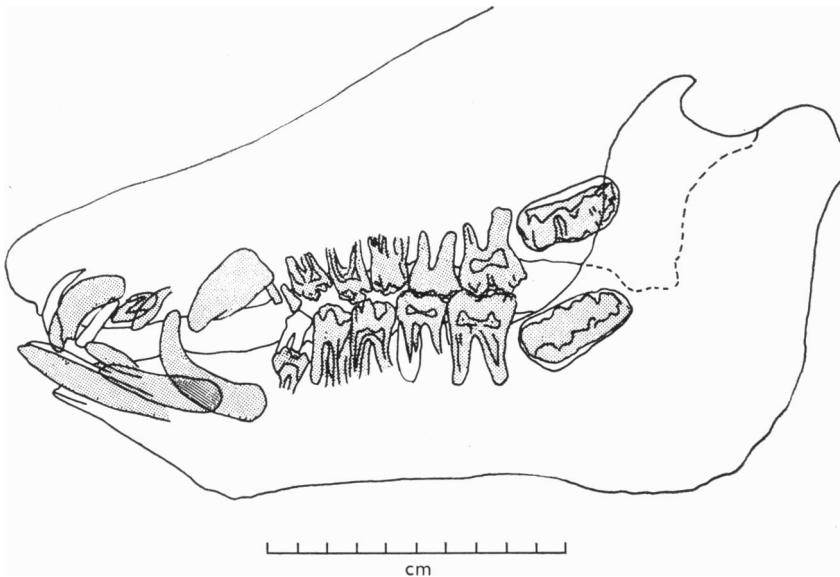


Fig. 4. Normal jaws 12 months after birth.

Twelve months after birth

Fig. 4 shows the dental development of one of the five normal animals killed at this age. The jaws had grown considerably in the last 4 months, and the deciduous incisors were being replaced by the permanent ones. The lower canine had erupted, but only part of the upper one. Diastemata were opening up in each jaw between

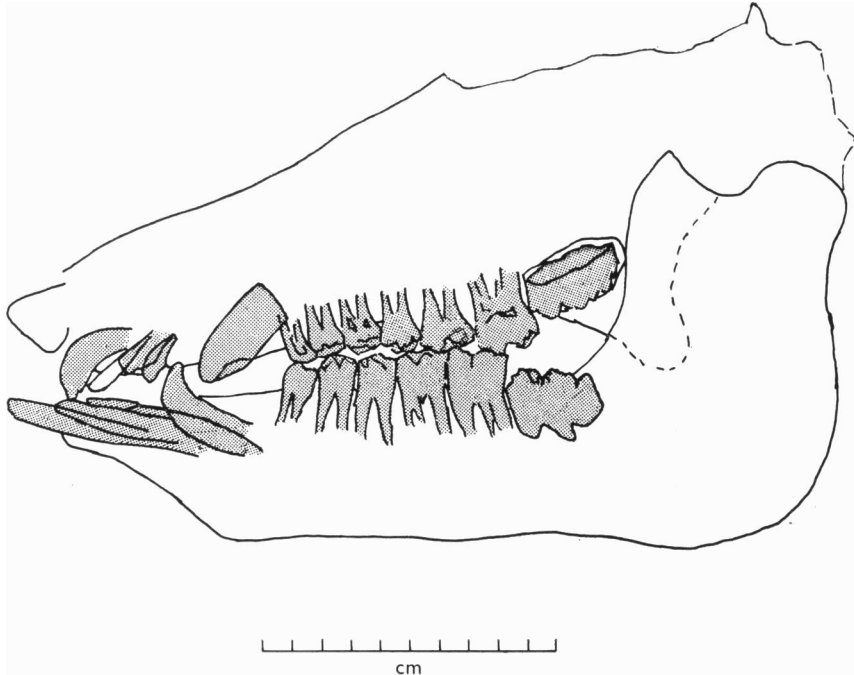


Fig. 5. Normal jaws 16 months after birth.

the incisor segment and the canines, and also between the latter and the premolars. There was a first premolar in every maxilla examined at this age, but this tooth was found in only one of the mandibles. The deciduous molars were giving place to the second, third and fourth premolars, and in all the specimens the first and second permanent molars had erupted and established good occlusion, while the third molars were still lying, partially calcified, in their crypts in good mesiodistal alignment. The occlusion was therefore good in the premolar-molar region and the teeth in both arches lay in a straight line mesiodistally. The contact area between the first and second upper molars lay beneath the zygomatic process of the maxilla.

Sixteen months after birth

In Fig. 5 the state of the jaws and teeth in one of the five animals killed when they were 16 months old is illustrated, and should be studied in association with Tables 2 and 3. In one of these animals the maxillary canine had a forked root. Several others were found in pigs during this investigation but it is certainly unusual in teeth with continuous growth. There was generally plenty of room for all the teeth to occlude normally, but in two of the specimens there were slight signs of premolar over-crowding. This may have resulted from the forked root of the canine in one of them.

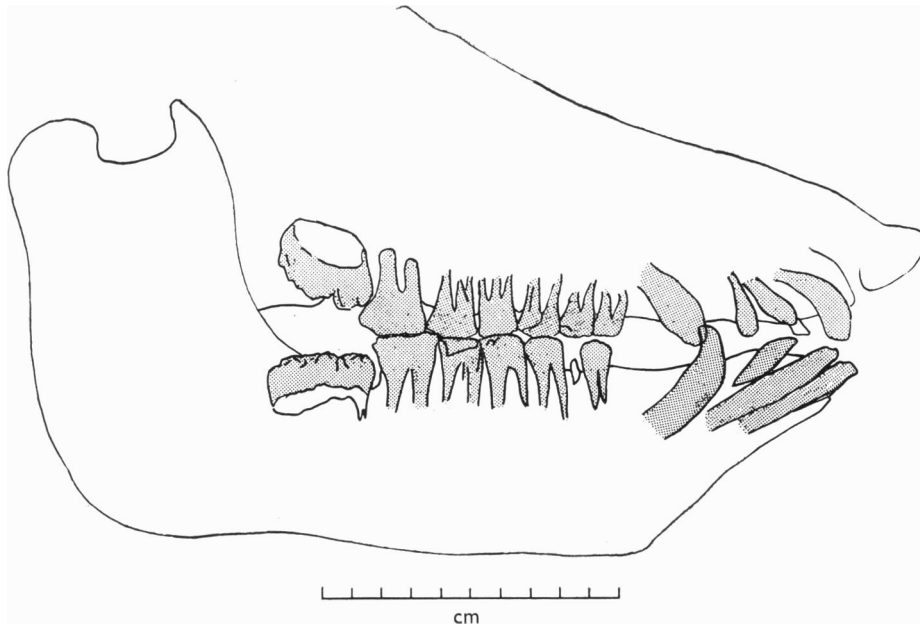


Fig. 6. Normal jaws 20 months after birth.

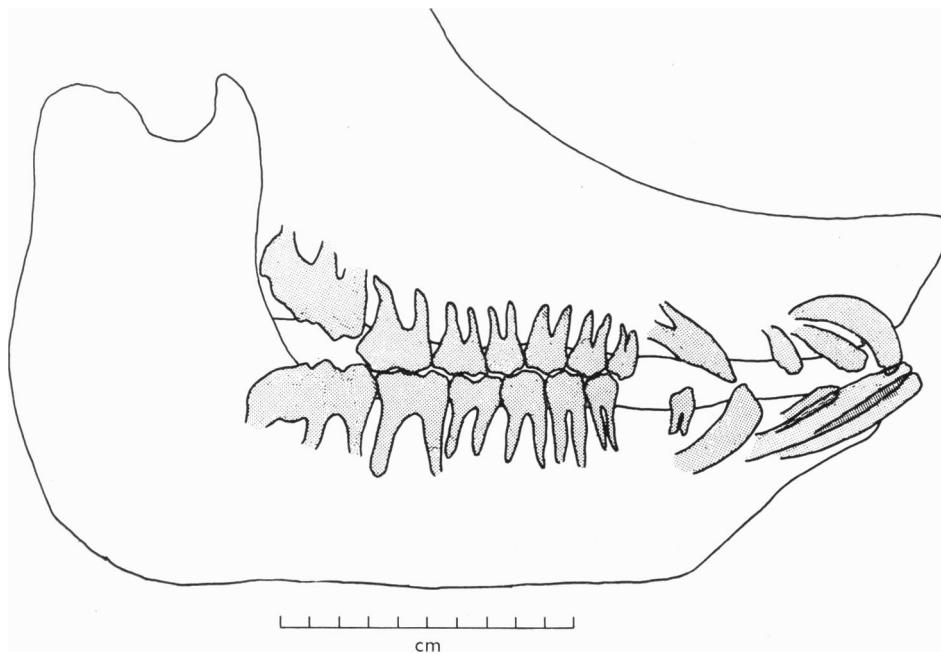


Fig. 7. Normal sow's jaws 24 months after birth. Note the bifurcation of the root of the maxillary canine, probably genetic in origin.

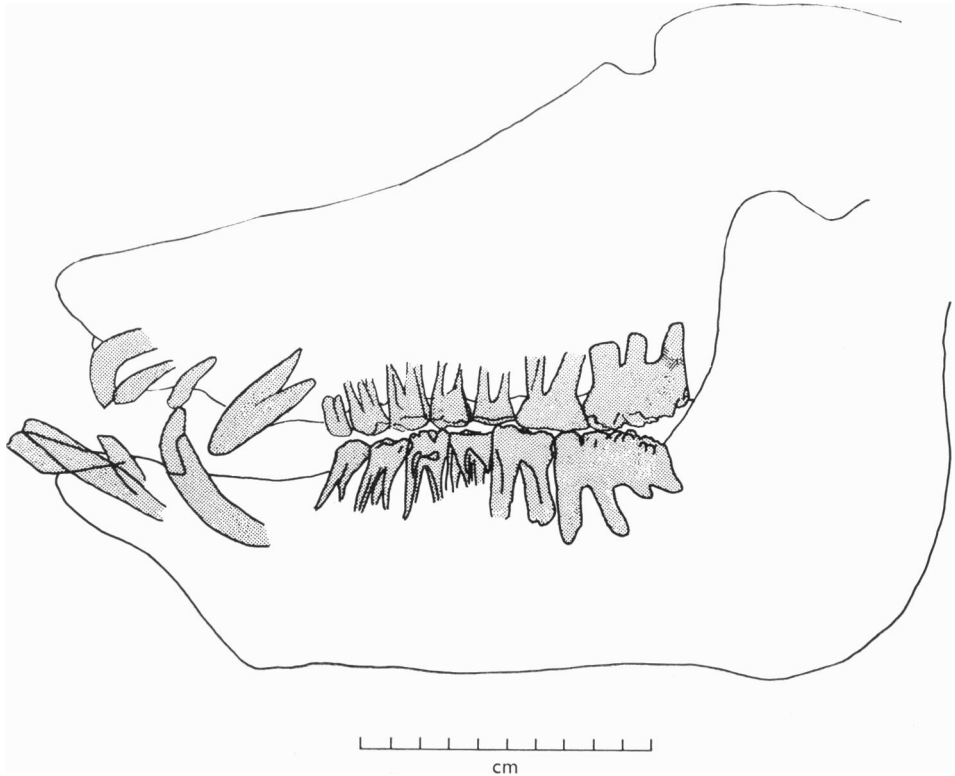


Fig. 8. Normal hog's jaws (right side) 30 months after birth. Note again the bifurcation of the root of the upper canine.

Twenty months after birth

By this age the permanent dentition, with the exception of the distal parts of the crowns of the 3rd molars, had fully erupted and was in normal occlusion. As shown in Fig. 6, some remnants of the second deciduous incisors and first molars might remain, but there was no sign of overcrowding in any of the jaws studied, and the diastemata were roomy.

Later stages

At 24 months the occlusion and alignment of the teeth was always good and the diastemata in the anterior segments were satisfactory. The second molars, fully erupted, were by now lying beneath the zygomatic process of the maxilla. The distal parts of the third molars had only partially erupted. In one of the jaws examined at this age and shown in Fig. 7 the maxillary canine had a forked root, and another such tooth was found in the maxilla of a pig aged 30 months (Fig. 8). By this time all the permanent dentition had fully erupted, and there was always some attrition of the first molar teeth in both jaws. The roots of the premolars and first and second molars were complete, but not always those of the third (Table 2).

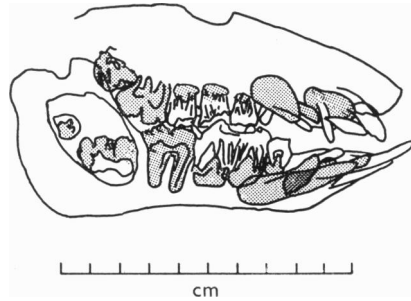


Fig. 9. The state of the jaws after 12 months of calorie deficiency.

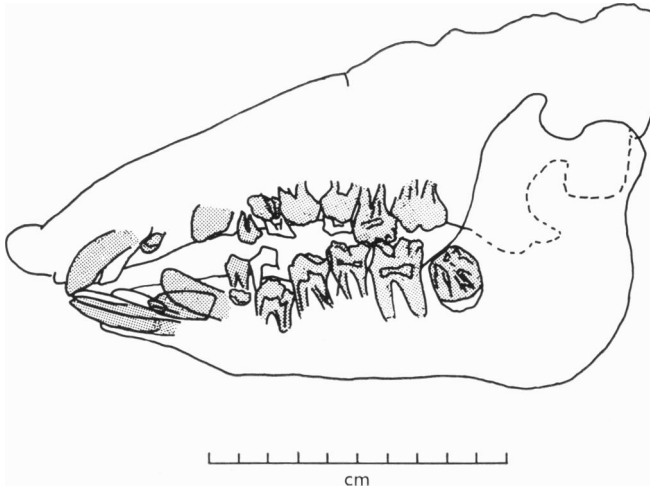


Fig. 10. The jaws on the right-hand side of an animal after calorie deficiency for 12 months and rehabilitation for 4 months.

At 36 months of age occlusion, alignment and diastemata were satisfactory, but attrition of all the molars was becoming conspicuous. By this age the third maxillary molar was lying in its permanent position below the zygomatic process.

Effects of undernutrition for the first twelve months of life

Fig. 9 is representative of the condition of the jaws of animals which had been undernourished till the age of one year, and weighed about 5.5 kg. It should be compared with Fig. 1, which shows the jaws of a normal animal of about the same weight, but much younger, and with Fig. 4, which shows the jaws of a normal animal of the same age, but much larger (see Table 1). As the scales on the three figures show, the jaws of the undernourished pig were larger than those of the younger pig, which had the same body weight, but much smaller than those of the normal pig of the same age.

The dental development of these pigs requires examination in detail. The deciduous incisors and canines were still present, although the crowns of most of their per-

manent successors had begun to calcify. In the majority the first upper premolar had erupted, and its roots lay close to the permanent canine, which was just developing. There was no corresponding tooth in the lower jaw. The three deciduous molars in each arch were still present, and showing signs of heavy attrition. There was radiological evidence of the crypts for the succeeding premolars having formed, and in the lower jaw some of these teeth had begun to calcify at the extremities of their cusps. The first lower permanent molars had completely erupted, but the upper ones only partially. The second permanent molars had not, but their crowns were approaching complete calcification. These teeth, therefore, were in a much more forward state than the weight of the animal or the size of the jaw would have led one to expect. Compared with those shown in Fig. 4, however, they were not far enough forwards in the jaws. Worse still was the condition of the third molars, for the lower ones, which in this specimen were just beginning to calcify, were lying high up in the ramus of the mandible, and the upper ones were only separated from the pterygo-palatine fossa by a thin plate of bone. Further details of the chronological delays in dental development at this age brought about by the undernutrition are given in Tables 2 and 3, together with the effects of rehabilitation and catch up growth.

The diastemata between the incisors and the canines, and between the latter and the deciduous molars, were very much smaller than those in normal pigs of the same age or at the same stage of dental development.

In radiographs, lines of arrested growth were usually conspicuous on the posterior border of the ramus of the mandible. The radio-opacity of the jaws was slight compared with that of normal animals of the same age, and the angle at menton was more obtuse (Figs. 1 to 4; Tonge & McCance, 1965).

In occlusion, the lower first deciduous molar was unopposed and the whole of the molar segment in the lower jaw seemed to be too far forward relative to the upper one. All this evidence of overcrowding can be explained by the fact that the dental development of these pigs corresponded to that of a normal animal about 4 months old, whereas the jaws had not yet attained the same size (Figure 2; Owens, 1968).

The effects of rehabilitation for:

Four months

Fig. 10 shows the state of the jaws and teeth after 4 months rehabilitation, when the animals weighed about 75 kg, and it should be compared with the jaws shown in Figs. 2 and 3. Small diastemata were only beginning to appear between the incisors and the canines, and between the latter and the first premolars. There was gross overcrowding in both jaws, and, on X-ray examination, the third molar in the right maxilla of the specimen illustrated (Fig. 10) appeared to be absent; this was confirmed by dissection. In the specimen illustrated both the third mandibular molars and the left maxillary one appeared smaller than those of normal animals, for they lay in a bucco-lingual plane at right angles to the normal one. Owing to this abnormal siting of the teeth, their occlusion was bad. The maxillary incisors occluded with the internal aspect of the mandibular ones, but the teeth were not in contact. The canines did not occlude, the lower one in fact being anterior to the third incisor. The

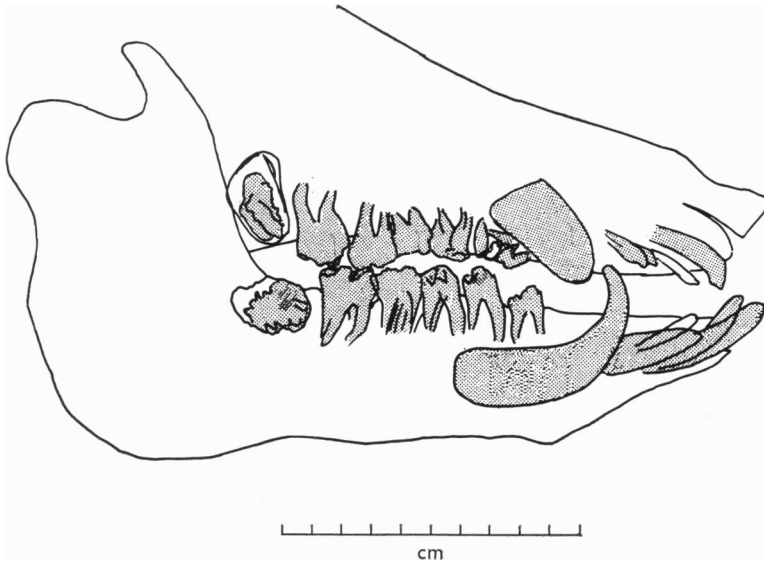


Fig. 11. The effect of calorie deficiency for 12 months followed by rehabilitation for 8 months.

maxillary first and second premolars articulated with the deciduous third molar and the first permanent molar on the left side but not on the right. The second maxillary molars were not in occlusion with any teeth in the lower jaw.

The teeth of the other animal killed at this stage of rehabilitation were in an equally disorganized state. The first and third permanent incisors had erupted, but the second maxillary one was lying horizontally, in a position which would have made eruption nearly impossible. The second upper premolar was wedged between the apex of the root of the canine, which had erupted, and the distal border of the first premolar. The second permanent molar in the upper jaw was equally wedged, and the calcifying crown of the third was lying with its occlusal surface directed vertically upwards towards the pterygoid region. In the mandible of this animal the mental foramen was situated between the third and fourth premolars, and the third molar present in both jaws was calcifying in a crypt at the base of the coronoid process.

Eight months

After eight months rehabilitation the mandibular teeth of one of the two animals examined were not so crowded as the ones shown in Fig. 11, but radiographs showed that the third permanent molars had not erupted, and that they were lying buccolingually, with their crowns rotated distally to the normal plane. There was, moreover, still gross overcrowding and tooth rotation in the premolar region of the maxilla. The teeth of the other animal, illustrated in Fig. 11, were most irregular, with overcrowding of the premolars in both jaws and impaction of the second permanent mandibular molars. The third molars in the jaws were less developed and equally displaced. The occlusion was poor and stability depended upon the occlusal contact of the molar area. Thus the teeth were misplaced, very crowded, and still develop-

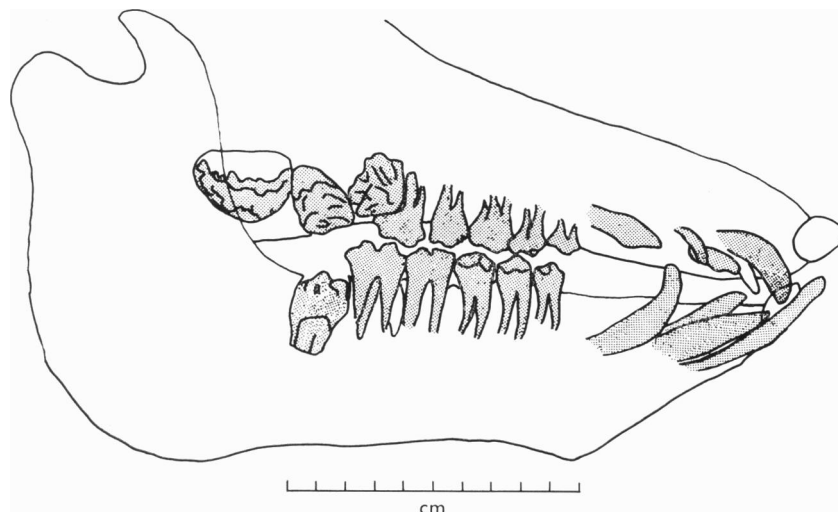


Fig. 12. The left side of the jaws after calorie deficiency for 12 months and rehabilitation for 12 months. Note the angle of growth of the upper third incisor and canine and the twinning of the third maxillary molar.

mentally backward compared with those of the normal animal illustrated in Fig. 6, and the premolars and molars were occupying less space in a smaller jaw.

Twelve months

After rehabilitation for 12 months, the animals were now two years old and all the erupted and unerupted teeth were permanent ones except the second permanent incisors, which had not yet replaced their deciduous predecessors. In Fig. 12 the upper third incisor and canine appear not to have erupted. This was because the angle at which these teeth were growing was such that their lowest edges lay above the level of the bone of the hard palate. The four upper premolars were partially rotated, with the third one overlapping the second distally. There was no first lower premolar, and though the other three were in good arch alignment, their occlusal relationships with the upper teeth were not normal, for the high centre cusps were occluding with those of the upper teeth instead of interdigitating with them. Moreover, the upper first and lower second premolar did not appear to be in occlusion, although, since their roots were not yet complete, occlusion might still have occurred.

In the molar region, the first upper molar was in post normal relationship with its lower counterpart. The second molar was partially erupted, but impacted between the first molar and the more mesial of *two* unerupted third left molars. The second molar showed signs of decay, and its roots were not visible. The two third molars, found only on the left side, were impacted, the more mesial presenting its root surface to the oral cavity and lying in a rotated position. The distal one was in more correct antero-posterior alignment, but was impacted mesially against its twin. Both teeth had their crowns calcified. This was one of only two animals in which two third maxillary molars were found. The other had been undernourished for one year and rehabilitated for 18 months (Fig. 14). The lower first and second molars

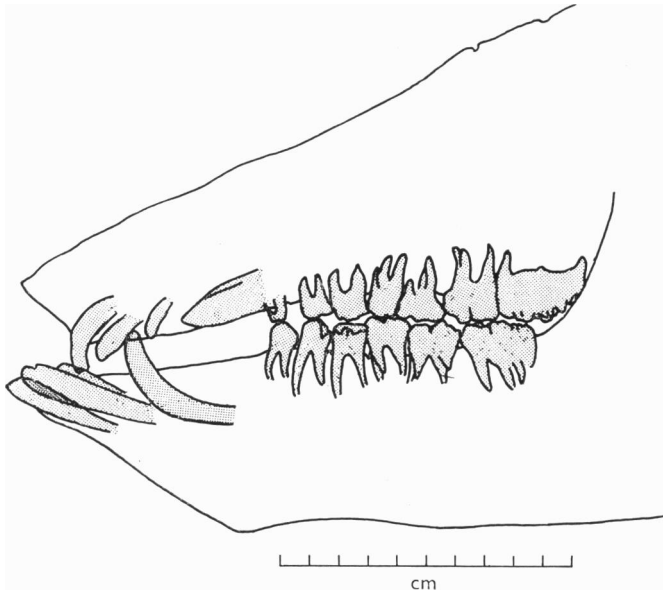


Fig. 13. Jaws showing a comparatively good recovery after calorie deficiency for 12 months and rehabilitation for 18 months.

had erupted in good alignment with the premolars, but the third one was rotated through 90° and impacted, its mesial surface facing lingually.

Spaces were present in the anterior segments, indicating very near normality in the incisor area, but the lower canine had drifted mesially and did not make contact with the upper one. In normal jaws, the canines were always in contact either in occlusion or during the movement of the jaws. The overcrowding therefore had been overcome to a great extent, except in the third molar area.

Eighteen months

After 18 months rehabilitation, when the pigs were 30 months old, the two available specimens showed rather different effects of rehabilitation. In one (Fig. 13), the rehabilitation had resulted in a fair recovery with the exception of (a) the persistence of a rather greater anterior proclination of the mandible in the incisor region, (b) a shorter maxilla as compared with the normal control at the age of 30 months (Fig. 8), (c) some overcrowding and malocclusion in the molar area of the upper jaw, and small anterior diastemata.

In the other specimen (Fig. 14), the degree of overcrowding before rehabilitation had been such that, during rehabilitation, considerable tooth displacement had remained. The relative relocation of the teeth, accompanied by wear on occlusal surfaces and loss of teeth, had left serious overcrowding and a malocclusion associated with inadequate cusp fissure relationships between the teeth of the two jaws. In the left maxilla (not shown), the first premolar was worn down to its roots, the fourth premolar had been lost, the second molar had its mesial cusps impacted against the distal area of the first molar, and the third molar was not fully erupted

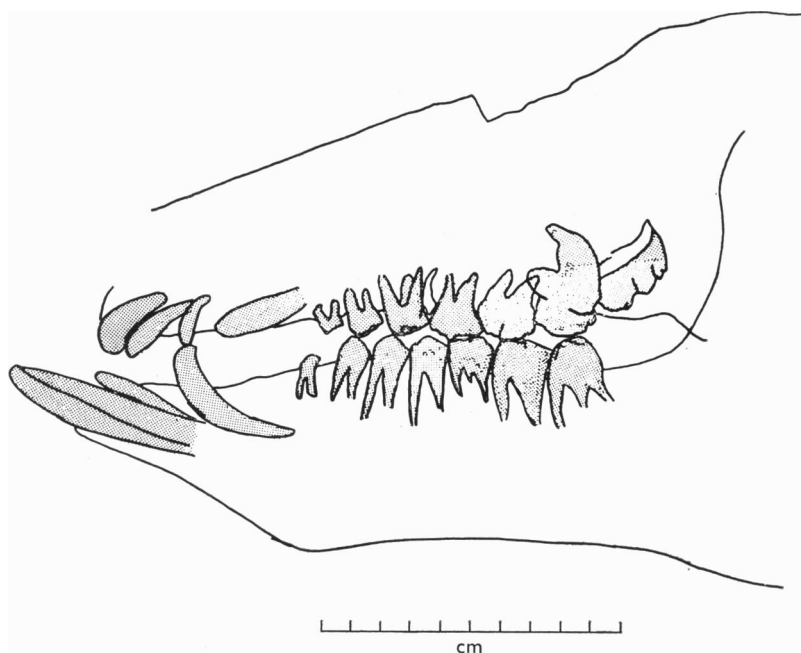


Fig. 14. Jaws on the right hand side after calorie deficiency for 12 months and rehabilitation for 18 months. Note the multiple permanent abnormalities that remained, among them twin third molars in the maxilla.

distally. This tooth had attenuated roots, and it was unlikely to develop further. The right maxilla, which is the one illustrated in Fig. 14, was even worse, although there was rather less attrition of the first premolar. The fourth premolar, however, was firmly wedged between the third premolar and first molar teeth. There were also twin third molars. Overall, the mandible had done better than the maxilla. On the left side, the first premolar was impacted against the canine; on the right side (Fig. 14) the first premolar was in a more normal position, but on both sides the third molars had rotated buccolingually, with resulting impaction and malocclusion.

Thirty-six months

In all the animals examined after being rehabilitated for two years there were still considerable but variable degrees of malocclusion. The more common forms were: (1) reductions in the mesiodistal lengths of the upper and lower third molars. (2) Rotation and/or impaction of the third molars. (3) Tilting and/or rotation of the premolars. (4) Variable antero-posterior siting of the canine. (5) Absence of the third lower or upper incisor (this was never observed in normal adult pigs). There were other less noteworthy differences between the two sides of the same jaw and between the two jaws.

In the tracing shown in Fig. 15, the most notable feature in the anterior segments is that the first lower premolar, which is not invariably present, had been transposed mesial to the canine. The transposition had been bilateral in this pig, as also in

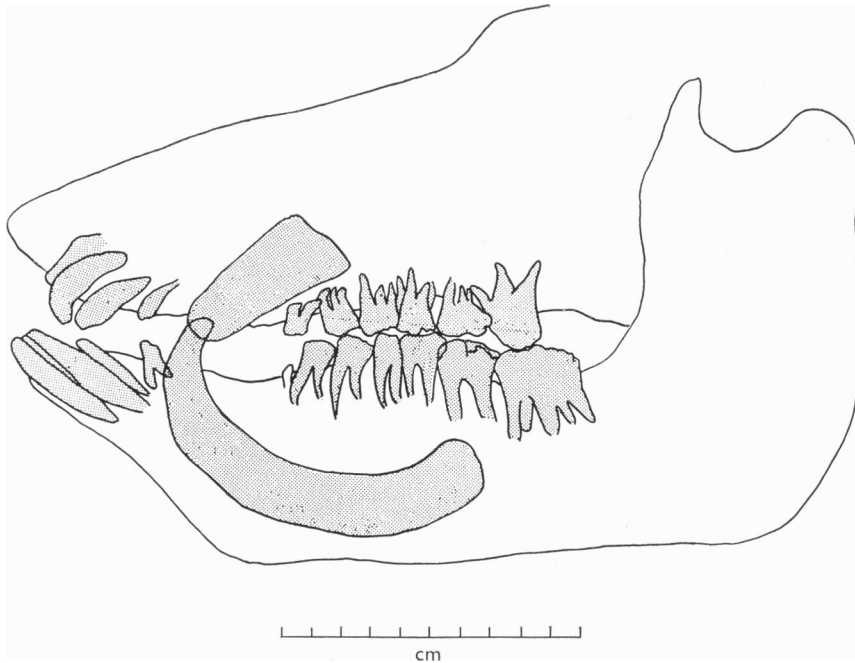


Fig. 15. The jaws of a pig after a calorie deficiency for 12 months followed by rehabilitation for 24 months. Note the transposition of the first lower premolar and the canine and the absence of any visible third molars

others, but this was not always so. The lower canines were in contact with the palatal mucosa at the gingival margin of the upper ones and had produced crater-like depressions in the bone. The second, third and fourth lower premolars were tilted distally and the fourth was rotated through approximately 90° . Just mesial to the second was a retained fragment of the root of the first deciduous molar. The three lower molars had all erupted and completed their roots, but they were overcrowded. The third molar was characteristically foreshortened mesiodistally and rotated a little lingually. In the upper arch all four premolars were present, but the first three showed some degree of tilting. The crowns of the second molars were both compressed, and the pattern of their cusps differed from that observed in normal adult pigs. Only the first and second permanent molars were present, and there was no evidence of the third one ever having developed or been present.

This was the only animal in which both third molars were absent although there were crypts and space for them. In one animal at this stage the first and second lower molars were absent, but there were retained root fragments indicating that the teeth had formed. The occlusion of all the undernourished animals, even after full rehabilitation, was always worse than that of any of the normal animals.

DISCUSSION

The word occlusion means more than the static relationship of teeth in apposition to one another. While, therefore, the present work may seem only to have compared

this static picture in two series of animals which had been differently reared, centric occlusion can be normal only if the growth and development of the jaws and teeth have also been normal – both separately and as an integrated unit. An attempt has therefore been made, first, to work out the steps of development that lead to normal occlusion in normal pigs, and secondly to find out why malocclusion develops in undernourished pigs. The first was necessary because the criteria of normality have not yet been so well established in the pig as they have been in man, but fortunately the task was simplified by the finding that, after making allowances for the differences in morphology and numbers of the teeth, many of the accepted criteria of normality in man were found to be applicable to pigs. Thus the upper teeth occluded with the lower ones so that (1) their buccal surfaces were in apposition, (2) their cusps fitted into the fissures of, or between, opposing teeth, and thus presented an orderly pattern of interdigitation. Particular attention on this point was paid to the first permanent molars, since in man the relationship of these teeth to each other is an important index of normality, and it is agreed that the angular ridge of the mesio-buccal cusps of the upper tooth should bite into the buccal groove of the lower one. It is not possible to give such a fine definition in the pig but Figs. 2, 3, 4, 6 and 7 show that the relationship of these two teeth in pigs bears a close resemblance to their relationship in man. Figs. 5 and 8, however, show that marginally less good alignments must be considered as falling within the range of normality. Attrition in the pig is much more conspicuous than in man, and loss of the cusps on the crowns of the third deciduous molar and the first permanent molar becomes pronounced, since these teeth are mainly responsible for maintaining the stability of the dentition during mastication as the deciduous teeth are replaced by the permanent set.

In occlusion (3) the distal surfaces of both the deciduous and permanent third molars lay in the same or parallel vertical planes (Fig. 3); (4) apart from the first upper premolar and the last deciduous and permanent molars, each upper tooth was opposed by its counterpart in the lower jaw or the tooth immediately distal to it; (5) the lower canines always lay mesial to the upper ones in both dentitions (Figs. 2 and 5).

In the animals which had been undernourished till they were a year old, dental development was delayed, but not to the same extent as the growth of the jaw. Fig. 9 shows clearly that there was considerable overcrowding of the standing and unerupted teeth, and malocclusion. The natural diastemata were obliterated at that time in both jaws, the developing molar teeth were displaced backwards, and the shape of the jaws was altered anteriorly to make room for the teeth (McCance, Owens & Tonge, 1968). Rehabilitation did not make good these defects because, although moderately normal diastemata appeared anteriorly, the jaws never attained their normal size. The teeth, on the other hand, did, certainly in the anterior segments. The roots of the molar teeth tended to be small but the crowns did not, except sometimes those of the third and occasionally those of the second molars. This made a difference to the weights of the molars, particularly in the mandible (Owens, 1968), but not to the impaction and overcrowding.

The experimental creation of malocclusion by varying the plane of nutrition can be explained as a particular example of one of the great general principles of biological growth, and the effect of undernutrition upon it. It was well recognized by

anatomists in the first half of this century (Donaldson, 1908; Jackson, 1909; Lowrey, 1911; Jackson & Lowrey, 1912) that the various parts of the body seldom grew at the same rate at the same time, and that some had completed their development almost before others had begun. The normal adult is the outcome of this highly integrated system, which Widdowson (1970) described as the harmony of growth, and which is, as it were, programmed from conception both in time and space.

Growth can proceed as it should only in a favourable environment, and one of the essentials in this environment is a good plane of nutrition. Calorie deficiency delays all the processes of development but it does not delay them all to the same extent. It delays the time from conception at which the various parts should develop less than anything else, and at the right time (or a little late) these parts begin to develop. If there are not enough nutrients available for all parts of the body to grow to capacity at the same time, those parts scheduled for rapid development at that time continue to develop, even if more slowly than they should, and sometimes actually at the expense of the others. There is, moreover, a further point. There comes a time in the chronological life of every animal when further growth, let us say in height, becomes impossible. This is well known, but it has not been so well recognized until recently that this applies also to important parts of the body, such as the brain. Unless, therefore, an organ, or the body as a whole, can complete its development within a specified chronological time from conception it may never be able to do so. It follows from all this that undernutrition upsets the biological programme, leads to discordant growth and sometimes to incomplete development (McCance, 1962).

The growth of the teeth is closely linked to chronological age, more so than that of the bones, and, even when undernutrition has been as severe and prolonged as in the present experiments, the teeth develop before the jaws have grown large enough to accommodate them. Moreover, they continue to do so regardless of the development of the jaws, and this results in the state of affairs illustrated in Figs. 9, 10 and 11. The position is not fully corrected by rehabilitation because (1) during rehabilitation the jaws do not become large enough to accommodate the teeth; (2) during the period of undernutrition the siting of the teeth had already become permanently disorganized; (3) some of the molar teeth, and particularly their roots, do not all grow to their full size, possibly for the same reason as the jaws and possibly for purely local ones. For example, their abnormal siting may not allow enough space in which to do so, and may also diminish the necessary supply of nutrients (McCance, 1968; Owens, 1968).

The general principles of growth and development apply to man as much as they do to pigs, but to what extent undernutrition can be held responsible for malocclusion, or indeed maldevelopment, in man is at present uncertain (Brash, McKeag & Scott, 1956), except for the possible significance of linear hypoplasia (Jelliffe & Jelliffe, 1971; Sweeney & Saffir, 1971). Garn, Lewis & Kerewsky (1965) attributed 90% of the variations in the size of the teeth, the timing of their calcification, their movement, and their attainment of occlusal level to genetic factors. Garn, Lewis & Blizzard (1965), however, showed that in 19 human growth failures the teeth averaged 91% of their chronological expectancy, and skeletal development only 68%. In cretins the figures were 93% and 38% respectively. Garn, Lewis & Blizzard (1965) showed, furthermore, that if hormonal reasons made skeletal growth precocious it

became more advanced than that of the teeth, which remained closely linked to the individual's chronological age.

Infantile undernutrition has been shown to lead to a degree of dental development greater than that to be expected from a child's size, but malocclusion has rarely if ever been shown to follow (Trowell, Davies & Dean, 1964). This is understandable owing to (1) the periods of undernutrition, from which children have usually suffered, being so short relative to their long period of growth, (2) failure to maintain contact with the children afterwards. Careful observation may well bring cases to light.

Garn & Russell (1971), whilst admitting that the bearing of nutrition on dental development in man is an unsolved problem, and one which has not been much studied, suggested that in making nutritional surveys the inclusion or exclusion of data on tooth formation and eruption should depend upon the known response of the teeth to nutritional deficiency or excess. This implies limiting by preselection the range of the observations to be made. In the present state of our knowledge about such matters, however, it does not seem to us that such a procedure is wise or justifiable.

Tables 2, 3 and 4 showed that a severe but carefully controlled calorie deficiency led to the experimental animals taking 12 months to attain a dental status comparable to that of a normal pig at 4-8 months. Rehabilitation on an excellent diet did not enable them to make good this initial delay and by the time they were aged 30 months they were only at a stage of dental development which would have been normal in an animal about 6 months younger. There was, moreover, a degree of malocclusion, impaction and attrition quite in excess of anything so far observed in normal pigs, because, even after the most successful rehabilitation, the diastemata between the incisors and canines, and between the latter and the premolar/molar elements, were always smaller than they should have been.

Among the variations in the teeth found in the normal and experimental animals, the absence of the first mandibular premolar and the presence of double rooted canines are almost certainly genetic in origin. The two third molar teeth in the left maxilla in an animal (Fig. 12) rehabilitated for 12 months, and the two on the right side in an animal rehabilitated for eighteen months (Fig. 14), were probably experimental in origin. This explanation is also thought to apply to the absence of any third upper molars in another pig (Fig. 15) which had been rehabilitated for two years. At any rate no previous record has been found of absent third molars in pigs. Undernutrition certainly explains the fact that the third molars were often too small even after full rehabilitation. At the age when the calorie restrictions were imposed the third molars were at a very early bud stage of development. This in itself will go a long way towards explaining their small size, and even the failure of some of the third molars to develop at all. Abnormal pressure or movement of a tooth germ might result in its bisection and duplicate development, for Glasstone (1952) grew two teeth *in vitro* from halved tooth germs, and Kollar & Baird (1970) showed that the dominant factor concerned with the morphology of a tooth was the inductive capacity of the dental papilla. In the experimental pigs the third molar tooth germs must have split in the long axis of the tooth, leaving each of the two portions of odontogenic epithelium in contact with some of the mesenchyme of the dental papilla.

Since the third molars were never found to be absent or duplicated in the normal animals an explanation along these lines seems the only one possible at present.

CONCLUSIONS

The normal development of the teeth and jaws has been studied in 'Large White' pigs. Many of the accepted standards of normal occlusion in man can be applied to these animals but it is not possible to define the criteria so exactly, and attrition becomes much more conspicuous as pigs mature.

Severe undernutrition at the appropriate period of development has been shown to produce:

- (1) a delay in the formation and eruption of the whole dentition, but
- (2) a greater delay in the development and growth of the jaws, consequently
- (3) overcrowding of the developing and standing teeth and particularly of the permanent molars, hence
- (4) malocclusion between the opposing teeth and malalignment of the whole dentition
- (5) partial or complete elimination of the diastemata proper to the jaw of the pig.

Rehabilitation led to:

- (1) rapid growth and development of both the jaws and the dental complex but
- (2) persistent malocclusion and disorder among all the permanent teeth and frequently small, misshapen or foreshortened third molars,
- (3) small roots in the molars,
- (4) occasional failure of a tooth to form, sometimes the transposition of two teeth or the duplication of third molars.

These effects have not hitherto been demonstrated experimentally.

It is a pleasure to acknowledge the contribution made to this work by P. D. A. Owens, particularly while he was at Queen's University, Belfast. We owe much also to the technical skill of Mr D. Reid, and more recently to the support Mr K. White-law has given him. The secretarial work has been carried out by Mrs L. Goodwin and one of us (C. H. Tonge) acknowledges the support of the Medical Research Council in the earlier phases of the work.

The animals have all been cared for morning, noon and night, seven days a week, by Terry Cowen. The work would have been utterly impossible without him.

REFERENCES

- BODEGOM, J. C. (1969). Thesis *Experiments on Tooth Eruption in Miniature Pigs*, pp. 1-78. Nijmegen: Drukkerij Gebr. Janssen N.V.
- BRASH, J. C., McKEAG, H. T. A. & SCOTT, J. H. (1956). *The Aetiology of Irregularity and Malocclusion of the Teeth*, 2nd ed. London: Dental Board of U.K.
- CABAK, V., GRESHAM, G. A. & MCCANCE, R. A. (1962). Severe undernutrition in growing and adult animals: 10 The skin and hair of pigs. *British Journal of Nutrition* **16**, 635-640.
- DONALDSON, H. H. (1908). A comparison of the albino rat with man in respect to the growth of the brain and of the spinal cord. *Journal of Comparative Neurology* **18**, 345-389.
- GARN, S. M., LEWIS, A. B. & BLIZZARD, R. M. (1965). Endocrine factors in dental development. *Journal of Dental Research* **44**, Suppl. 243-258.

- GARN, S. M., LEWIS, A. B. & KERESKY, R. S. (1965). Genetic, nutritional and maturational correlates of dental development. *Journal of Dental Research* **44**, Suppl. 228-242.
- GARN, S. M. & RUSSELL, A. L. (1971). Effect of nutritional extremes on dental development. *American Journal of Clinical Nutrition* **24**, 285-286.
- GLASSTONE, S. (1952). The development of halved tooth germs: a study of experimental embryology. *Journal of Anatomy* **86**, 12-15.
- JACKSON, C. M. (1909). On the prenatal growth of the human body and the relative growth of its various parts. *American Journal of Anatomy* **9**, 119-167.
- JACKSON, C. M. & LOWREY, L. G. (1912). On the relative growth of the component parts (head, trunk and extremities) and systems (skin, skeleton, musculature and viscera) of the albino rat. *Anatomical Record* **6**, 449-472.
- JEFFREYS, J. F. (1969). Thesis *Growth Pattern and Environment* pp. 1-108. Nijmegen: Drukkerij Gebr. Janssen N.V.
- JELLIFFE, D. B. & JELLIFFE, E. F. P. (1971). Linear hypoplasia of deciduous teeth in malnourished children. *American Journal of Clinical Nutrition* **24**, 893.
- KOLLAR, E. J. & BAIRD, G. R. (1970). Tissue interactions in embryonic mouse tooth germs. 1. Reorganisation of the dental epithelium during tooth-germ reconstruction. *Journal of Embryology and Experimental Morphology* **24**, 159-171.
- LAVELLE, C. L. B. (1968). Anglo-Saxon and modern British teeth. *Journal of Dental Research* **47**, 811-815.
- LOWREY, L. G. (1911). Prenatal growth of the pig. *American Journal of Anatomy* **12**, 107-138.
- LUNDSTRÖM, A. (1951). The etiology of crowding of the teeth (based on studies of twins and on morphological investigations) and its bearing on orthodontic treatment (expansion or extraction). *Transactions of the European Orthodontic Society*, pp. 176-191.
- MCCANCE, R. A. (1960). Severe undernutrition in growing and adult animals: 1. Production and general effects. *British Journal of Nutrition* **14**, 59-73.
- MCCANCE, R. A. (1962). Food, growth and time. *Lancet* **2**, 621-626, 671-676.
- MCCANCE, R. A. (1968). See *Calorie Deficiencies and Protein Deficiencies*. Proceedings of Glaxo Conference. London: Churchill.
- MCCANCE, R. A., OWENS, P. D. A. & TONGE, C. H. (1968). Severe undernutrition in growing and adult animals. 18. The effects of rehabilitation on the teeth and jaws of pigs. *British Journal of Nutrition* **22**, 357-368.
- OWENS, P. D. A. (1968). The effect of undernutrition and rehabilitation on the jaws and teeth in pigs. See *Calorie Deficiencies and Protein Deficiencies*. Proceedings of Glaxo Conference. London: Churchill.
- PEYER, B. (1968). *Comparative Odontology*. Chicago: Chicago University Press.
- SWEENEY, E. A., SAFFIR, A. J. & DE LEON, R. (1971). Linear hypoplasia of deciduous incisor teeth in malnourished children. *American Journal of Clinical Nutrition* **24**, 29-31.
- TONGE, C. H. & McCANCE, R. A. (1965). Severe undernutrition in growing and adult animals. 15. The mouth, jaws and teeth of pigs. *British Journal of Nutrition* **19**, 361-372.
- TROWELL, H. C., DAVIES, J. N. P. & DEAN, R. F. A. (1964). *Kwashiorkor*. London: Arnold.
- WIDDOWSON, E. M. (1970). The harmony of growth. *Lancet* **1**, 901-905.