

Anatomical variations of the cervical portion of the thoracic duct in man

P. KINNAERT

Department of Surgery, Hôpital Brugmann, Place A. Van Gehuchten 4, Brussels, Belgium

(Accepted 23 February 1973)

INTRODUCTION

Surgical procedures involving the terminal portion of the thoracic duct have recently been described. Thoracic duct drainage has been used in intractable ascites (Dumont & Mulholland, 1962) or as an immunosuppressive therapy in kidney transplantation (Franksson & Blomstrand, 1967; Fish *et al.* 1970; Tilney, Atkinson & Murray, 1970). Disconnexion of the lymphovenous junction and reinsertion in the jugular vein has also been proposed for the treatment of some types of ascites (Bhalerao, Trivedi & Sen, 1971). The performance of such operations is only possible if certain local anatomical conditions are present. Unfortunately descriptions in the classical textbooks are rather schematic and do not necessarily correspond to the situation in living human beings. The present paper deals with anatomical data collected from 49 patients during a surgical procedure performed to drain the thoracic duct.

MATERIAL AND METHODS

Forty-nine patients in chronic terminal renal insufficiency were submitted to thoracic duct drainage. The thoracic duct was approached through an incision 6–7 cm long above the medial end of the left clavicle. In the first 17 cases the clavicular head of the sternocleidomastoid muscle was divided to expose the internal jugular vein. In the succeeding operations the sternal and clavicular heads of the muscle were retracted medially and laterally respectively. The internal jugular vein was then dissected through the opening thus created in the sternocleidomastoid muscle, and followed down to its junction with the subclavian vein. Tissues in the space between both veins were carefully dissected, and the upper border of the subclavian vein was freed as far as the external jugular vein. The descriptions given will be limited to the terminal portion of the duct as it was observed in the operative site.

RESULTS

In two instances the thoracic duct was not found on the left side. In the majority of the patients the duct lay behind the internal jugular vein and adhered closely to the posterior wall of its sheath. The classical arch of the duct was absent in some cases but its height was 4 cm in one patient, and usually measured between 0.5 and 1.5 cm. In one subject the only important lymphatic vessel found was situated in front of the

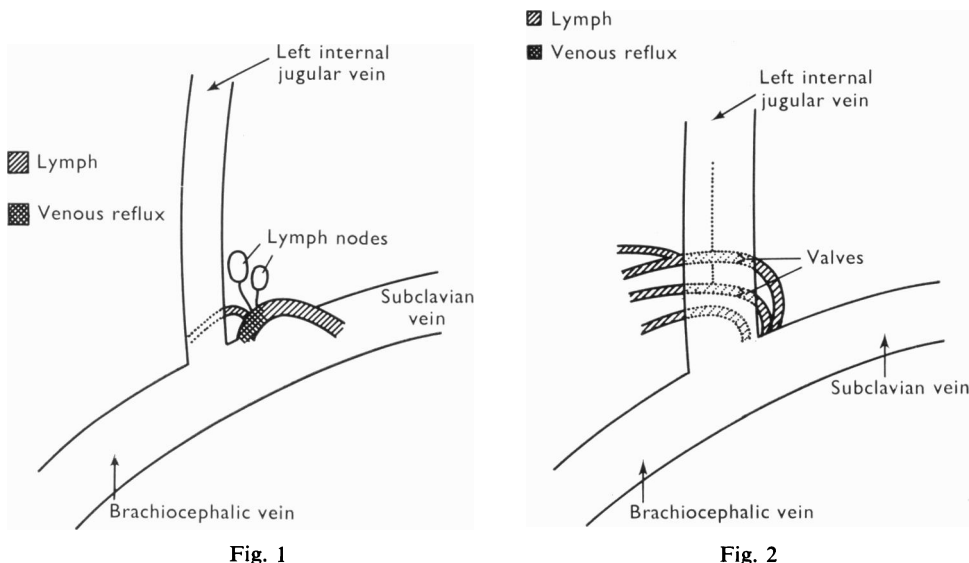


Fig. 1

Fig. 2

Fig. 1. Thoracic duct crossing the subclavian vein anteriorly. The lymphatic vessel comes from the lateral margin of the dissected area and ends a few millimetres from the jugulosubclavian angle.

Fig. 2. Multiple lymphatic channels ending separately in the venous system.

Table 1. Site of the lymphovenous junction for 47 thoracic ducts ending on the left side

Site of the lymphovenous junction	Single channel	Two or more lymphatic vessels ending in a common trunk	Multiple endings	Total
Jugulosubclavian angle	3	13	—	16
Internal jugular vein	1	13	3	17
Jugulosubclavian angle + internal jugular vein	—	—	1	1
Subclavian vein	2	5	1	8
Jugulosubclavian angle + subclavian vein	—	—	4	4
Transverse cervical vein	—	—	1	1

subclavian vein, in which it ended a few millimetres from its confluence with the internal jugular vein (Fig. 1).

In ten patients the thoracic duct had several terminal openings into the venous system; in nine multiple lymphatic vessels ended separately in the venous system (Fig. 2); and in one a voluminous single duct divided, a few millimetres from the lymphovenous junction into two channels, which opened into the subclavian vein and the jugulosubclavian angle (Fig. 3).

Thirty-seven ducts terminated with a single opening into the venous system. Six were single ducts, whose diameter ranged from 2 to 5 mm (Figs. 1, 4). In 13 cases two lymphatic vessels joined in a common trunk (Fig. 5). The two component vessels were

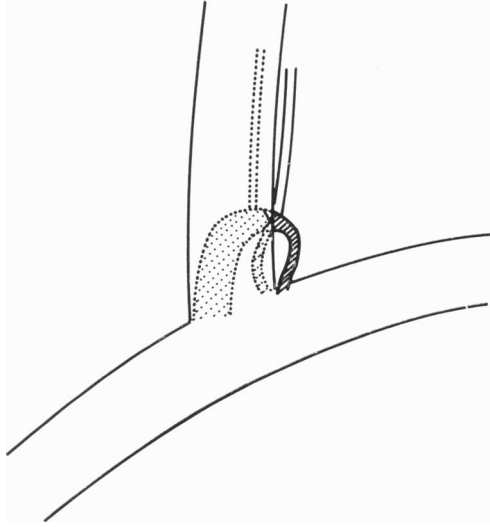


Fig. 3

Fig. 3. Single vessel dividing into two channels before emptying in the venous system.

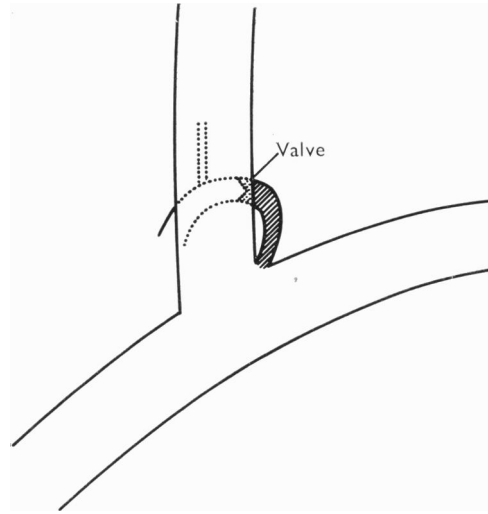


Fig. 4

Fig. 4. Thoracic duct corresponding to the classical description.

in most instances joined together by fibrous tissue, and could be distinguished only by careful dissection or after catheterization. In 18 instances numerous lymphatic channels ended in a short common duct. The diameter of each individual lymphatic vessel ranged from 0.5 to 3 mm (Fig. 6).

Table 1 shows the exact location of the lymphatic opening in the venous system. In this series 34 of the 47 thoracic ducts observed on the left side ended either in the internal jugular vein or in its confluence with the subclavian vein. In 13 cases the lymphovenous junction lay more laterally, in the subclavian vein or a transverse cervical vein. However, the opening of the duct was always found within a distance of 2 cm from the angle of union of the internal jugular and subclavian veins.

A typical ampulla was observed in ten patients at the extremity of the thoracic duct, but no dilatation was noted in the remaining cases. On two occasions the duct opened into a localized bulging of the subclavian vein (Fig. 5).

Blood reflux was found in about half of the 41 cases where this information could be obtained (Table 2). This phenomenon was not influenced by the structure of the terminal portion of the thoracic duct, and its frequency was the same in each of the anatomical categories. In four cases there were no data on venous reflux in the protocol of the operative procedure. Two patients had a very bloody lymph, and in these instances reflux could not be ascertained. When reflux was present, blood ebbed to and fro with respiration in the terminal centimetre or so of the thoracic duct.

The cervical lymphatic channels usually joined the thoracic duct near its end. However, in five patients a separate lymphatic trunk ended in the jugulosubclavian angle, the internal jugular vein, the subclavian vein, or a transverse cervical vein. In one female patient the cervical lymphatic channel joined a horizontal lymphatic vessel

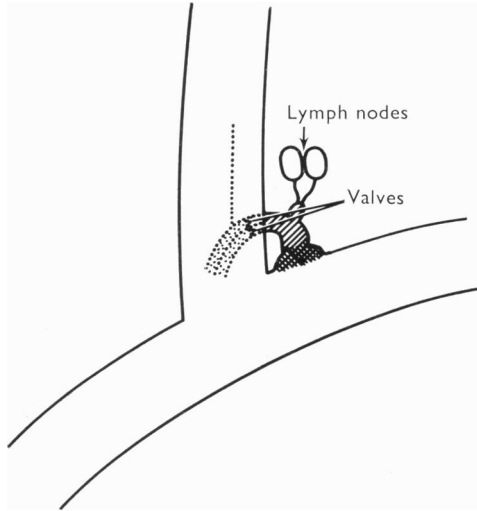


Fig. 5

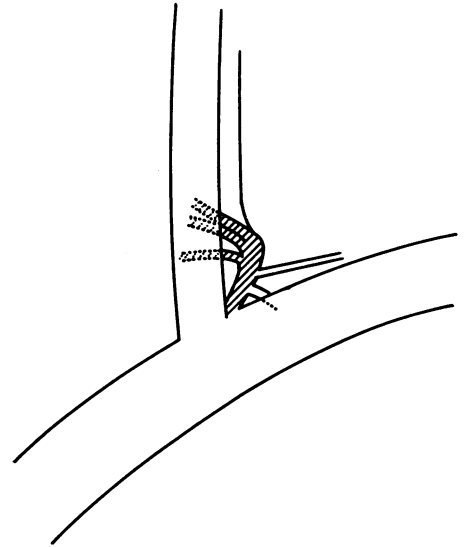


Fig. 6

Fig. 5. Two lymphatic channels joining in a common trunk. Note the bulging of the vein at the site of the lymphovenous junction.

Fig. 6. Multiple lymphatic trunks terminating in a common channel which empties into the venous system.

Table 2. *Frequency of blood reflux in the terminal portion of the thoracic duct*

Structure of terminal portion of thoracic duct	Blood reflux	No blood reflux	No information
Single opening			
Single channel	1	2	3
Two or more lymphatics ending in a common trunk	15	14	2
Multiple lymphatic channels	5	4	1
Total	21	20	6

Table 3. *Frequency of failure to detect the thoracic duct on the left side*

Authors	Subjects	Total no. of dissections	% of thoracic ducts not ending on the left side	
Parsons <i>et al.</i> (1909)	} Cadavers	{ 40	0	
Davis (1915)			22	4.5
Correia, M. (1926)			32	0
Greenfield <i>et al.</i> (1956)			75	1.3
Kausel <i>et al.</i> (1957)			50	2.0
Shafiroff <i>et al.</i> (1959)			30	0
Jdanov (1959)			100	0
Rocca Rosetti <i>et al.</i> (1961)	} Living	{ 14	0	
Werner (1965)			79	2.5
Archimbaud <i>et al.</i> (1969)			38	5.3
Present series			49	4.1

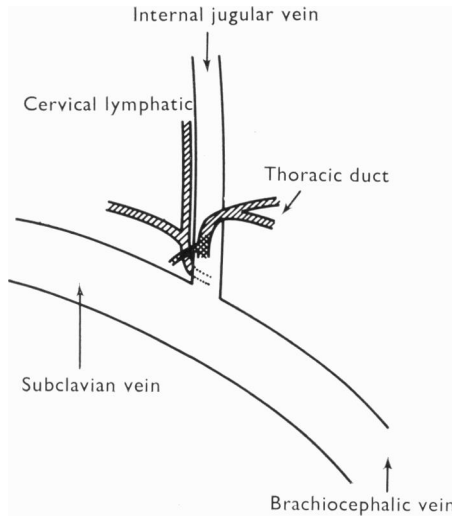


Fig. 7. Posterior view showing the thoracic duct ending in the jugular vein separately from the lymphatic vessels draining the head and neck and the upper left extremity.

Table 4. Comparison of data from the literature concerning the termination of the thoracic duct (the figures are percentages)

Authors	Single opening		
	Single duct	Multiple channels ending in a common trunk	Multiple channels ending separately
Parsons <i>et al.</i> (1909)	55.0	—	22.5
Davis (1915)	—	81.0	—
Correia (1926)	40.6	—	18.8
Greenfield <i>et al.</i> (1956)	—	89.4	—
Shafiroff <i>et al.</i> (1959)	—	90.0	—
Jdanov (1959)	27.0	—	?
Rocca Rosetti <i>et al.</i> (1961)	78.6	—	7.1
Werner (1965)	—	68.5	—
Archimbaud <i>et al.</i> (1969)	47.2	—	25.0
Present series	12.8	—	65.9

to form a common trunk which opened into the front of the jugular vein (Fig. 7). Thus in this case there were separate drainage openings for the thoracic duct lymph and for the lymph drained from the left upper extremity and left side of the head and neck.

DISCUSSION

Tables 3–5 show comparisons between the present observations and anatomical data obtained in the literature.

On a few occasions the thoracic duct was not found on the left side of the neck (Table 3), and when this occurred in cadavers it was always found that the thoracic

Table 5. Comparison of data from the literature concerning the site of the lymphovenous junction (the figures are percentages)

(Figures in parentheses correspond to the number of thoracic ducts found on the left side.)

Localization of the lymphovenous junction	Parsons <i>et al.</i> (40)	Davis (21)	Shafiroff <i>et al.</i> (30)	Rocca Rosetti <i>et al.</i> (14)	Jdanov (100)	Archim-baud <i>et al.</i> (36)	Present series (47)
1. Internal jugular vein	85.0	4.8	60.0	35.8	47.7	16.7	36.2
2. Jugulosubclavian angle	7.5	23.8	10.0	50.0	35.4	27.8	34.1
3. Subclavian vein	—	57.1	23.3	7.1	9.2	50.0	17.0
4. Innominate vein	—	4.8	6.7	—	7.7	—	—
5. (1)+(2)	—	4.8	—	—	—	—	2.1
6. (1)+(3)	7.5	—	—	—	—	—	—
7. (2)+(3)	—	—	—	—	—	—	8.5
8. (1)+(3)+external jugular vein	—	—	—	—	—	5.5	—
9. (1)+vertebral vein	—	4.8	—	—	—	—	—
10. (1)+(2)+(3)	—	—	—	7.1	—	—	—
11. Transverse cervical vein	—	—	—	—	—	—	2.1

duct ended in the right internal jugular vein (Davis, 1915; Greenfield & Gottlieb, 1956; Kausel *et al.* 1957). It can be seen from Table 3 that failure to detect the thoracic duct on the left side of the neck was more frequent in living patients than in cadavers. This is probably due to the limited area explored during the operative procedure. The fact that no thoracic duct was found in this zone does not allow us to conclude that its point of emptying into the venous system was on the right side of the neck. Indeed, thoracic ducts opening into the left innominate vein have been described (Davis, 1915; Rouvière, 1932; Greenfield & Gottlieb, 1956; Jdanov, 1959; Shafiroff & Kau, 1959).

In the present series 21.3% of thoracic ducts ended in multiple channels opening separately into the veins, and this figure is in agreement with data obtained from the literature (Table 4). Only Correia (1926) obtained a much higher percentage (40.6%) of multiple terminations. The figures given by other workers indicate that 67.5–90% of the dissected ducts had a single opening into the main veins, but the present findings differ from the others in having a low percentage of single ducts (12.8%). Radiological studies have also yielded higher frequencies, ranging from 43.7% (Pomerantz, Herdt, Rockoff & Ketchum, 1963) to 75% (Lowman, Hoogerhyde, Waters & Grant, 1951). As far as the anatomical studies are concerned the discrepancy can be explained by more careful dissection. As already mentioned, the separate lymphatic vessels were literally glued together and could easily be mistaken for a single duct. As for the radiological studies, the lipiodol used in these examinations does not necessarily visualize all the lymphatic channels, and the results can also depend on the technique used.

In the majority of the published series 70–92.5% of the thoracic ducts discovered on the left side ended in the internal jugular vein or the jugulosubclavian angle

(Table 5). However, Davis (1915) and Archimbaud *et al.* (1969) reported respectively 57.1% and 50% of ducts emptying into the subclavian vein. Archimbaud and his colleagues noted that the lymphovenous junction was always within 15 mm of the jugulosubclavian angle.

Finally, a dilatation of the terminal portion of the thoracic duct is usually described, and Correia (1926) states that it is almost always present. In the present study only ten typical ampullas were found. The thickness of the wall of the proximal segment of the thoracic duct decreases, mainly because of a reduction in the number of muscular fibres (Kausel *et al.* 1957). On the other hand, the opening of the thoracic duct into the main veins and the adjacent portion of the duct seems to be rather constricted. Classical anatomical descriptions are obtained from study of cadavers in which the thoracic duct has previously been injected with coloured material. It is possible that in many such cases the terminal dilatation of the duct is an artefact resulting from the injection procedure. It may be postulated that the presence of an ampulla in living patients depends on the rate of lymph flow, the pressure in the thoracic duct, and the structure of the lymphovenous junction.

SUMMARY

The anatomical variations of 47 thoracic ducts discovered during 49 dissections in living patients are described.

The results are compared with data from the literature.

Differences between cadavers and living anatomy are discussed.

REFERENCES

- ARCHIMBAUD, J. P., BANSILLON, V., BERNHARDT, J., BONNET, P. & SAUBIER, E. C. (1969). Quarante dissections du canal thoracique. Sa terminaison chez l'homme vivant. *Lyon médical* **30**, 211–214.
- BHALERAO, R. A., TRIVEDI, D. R. & SEN, P. K. (1971). Lymphovenous anastomosis in the management of portal hypertension. *Surgery* **69**, 569–576.
- CORREIA, M. (1926). Le canal thoracique chez l'homme. *Folia Anatomica Universitatis Conimbrigensis* **1**, 1–20.
- DAVIS, H. K. (1915). Statistical study of thoracic duct in man. *American Journal of Anatomy* **17**, 211–244.
- DUMONT, A. E. & MULHOLLAND, J. H. (1962). Alteration in thoracic duct lymph flow in hepatic cirrhosis: significance in portal hypertension. *Annals of Surgery* **156**, 668–677.
- FISH, J. C., TYSON, K. R. T., BEATHARD, G. A., SARLES, H. E., REMMERS, A. R. & RITZMANN, S. E. (1970). Circulating lymphocyte depletion: effect on renal allograft survival in calves. *Surgery* **67**, 969–975.
- FRANKSSON, C. & BLOMSTRAND, R. (1967). Drainage of the thoracic lymph duct during homologous kidney transplantation in man. *Scandinavian Journal of Urology and Nephrology* **1**, 123–131.
- GREENFIELD, J. & GOTTLIEB, M. I. (1956). Variations in the terminal portion of the human thoracic duct. *Archives of Surgery* **73**, 955–959.
- JĐANOV, D. A. (1959). Anatomie du canal thoracique et des principaux collecteurs lymphatiques du tronc chez l'homme. *Acta anatomica* **37**, 20–47.
- KAUSEL, H. W., REEVE, T. S., STEIN, A. A., ALLEY, R. D. & STRANAHAN, A. (1957). Anatomic and pathologic studies of the thoracic duct. *Journal of Thoracic Surgery* **34**, 631–642.
- LOWMAN, R. M., HOOGERHYDE, J., WATERS, R. L. & GRANT, C. (1951). Traumatic chylothorax: roentgen aspects of this problem. *American Journal of Roentgenology* **65**, 529–546.
- PARSONS, F. G. & SARGENT, P. W. G. (1909). On the termination of the thoracic duct. *Lancet* **1**, 1173–1174.
- POMERANTZ, M., HERDT, J. R. L., ROCKOFF, S. D. & KETCHAM, A. S. (1963). Evaluation of the functional anatomy of the thoracic duct by lymphography. *Journal of Thoracic and Cardiovascular Surgery* **46**, 568–575.
- ROCCA ROSSETTI, S., ARESU, R., LIGUORI, G. (1961). Ricerchesulla composizione della linfa umana. I. Anatomia chirurgica del dotto toracico al collo e tecnica del cateterismo. *Rassegna medica sarda* **63**, 651–656.

ROUVIÈRE, H. (1932). *Anatomie des Lymphatiques de l'Homme*. Paris: Masson.

SHAFIROFF, B. G. D. & KAU, Q. Y. (1959). Cannulation of the human thoracic lymph duct. *Surgery* **45**, 814–819.

TILNEY, N. L., ATKINSON, J. C. & MURRAY, J. E. (1970). The immunosuppressive effect of thoracic duct drainage in human kidney transplantation. *Annals of Internal Medicine* **72**, 59–64.

WERNER, B. (1965). Thoracic duct cannulation in man. I. Surgical technique and a clinical study on 79 patients. *Acta chirurgica scandinavica* Suppl. 353, 1–32.