

OBSERVATIONS ON THE ELASTIC TISSUE OF THE SKIN WITH A NOTE ON THE RETICULAR LAYER AT THE JUNCTION OF THE DERMIS AND EPIDERMIS

By JOHN C. DICK

Department of Pathology, University and Royal Infirmary, Glasgow

INTRODUCTION

Sternberg (1925) called attention to the fact that there were other tissues besides the skin that showed elastic properties, though not showing any yellow fibres, and conversely, elastic staining tissue did not always show elastic properties. He therefore suggested that the term 'yellow elastic tissue' should be abandoned and replaced by 'yellow connective tissue'. Hass (1939) emphasized that elastic fibres were always associated with collagen fibres, and considered that inferences as to the separate properties of each might be unjustly drawn.

Geiger (1927), studying the development of elastic tissue in the skin, recognized it first in the plantar skin of a foetus 20 cm. long. The elastic tissue of the skin varies in character and amount, both with age and in different parts of the body. Lindholm (1931) found that elastic fibres were finer and more numerous in infants than in adults, and that there was often more elastic tissue in the skin of women than of men. Schmidt (1891) and Kissmeyer & With (1922) described the changes in the skin in old age and after exposure to the weather, and Ohno (1925) in various pathological conditions.

All these workers studied only limited areas, and the present paper describes the character and arrangement of the elastic tissue in skin over almost the whole body. Its appearance will be described as seen in the following areas:

Foot: various parts of the sole, and centre of the dorsum.

Limbs: midway along the legs, thighs, forearms and arms, from the medial and lateral sides.

Abdomen: midline, 2-3 in. above the umbilicus.

Chest: over the junction of the manubrium and body of the sternum.

In addition, skin was examined from subjects with oedema of various types in order to investigate the characteristics of the yellow elastic fibres compared with those of normal skin.

Small elastic fibres were found to approach close to the bases of the deepest layer of epidermal cells. In order to find out whether the elastic tissue takes part in the junction between the dermis and epidermis, investigation of the reticular layer between these tissues was also undertaken.

MATERIALS AND METHOD

The age groups chosen and the number of cases in each group in which all the above sites were examined were as follows:

	Males	Females	Total
(1) 0- 5 years	4	3	7
(2) 15-23 years	4	5	9
(3) 30-40 years	5	3	8
(4) Over 65 years	4	4	8
Totals	17	15	32

Skin from other situations, e.g. scalp, eyelids and eyebrows, back, elbow, knee and scrotum, was examined in some of these cases and from numerous other subjects where suitable material was available.

Small, rectangular portions of skin and subcutaneous tissue were excised, transversely and parallel to the long axis of the body, from the situations mentioned above. These were fixed in a saturated aqueous solution of corrosive sublimate, embedded in paraffin and cut at right angles to the skin surface, in the long axis of the rectangular strip. All sections were stained with haemalum and eosin, and by Weigert's method for elastic tissue, using carmalum or safranin as counterstain. To study the reticular fibres, Foot's (1929) silver impregnation method was also used on sections from many of the blocks; in order to get reasonable impregnation of the subepithelial fibres, it was found necessary to leave the sections rather longer in the silver bath than was required to show the reticular fibres elsewhere (e.g. kidney, aorta, glands), with the result that there was slight over-impregnation, so that the connective fibres in the rest of the dermis were stained deeply; various counterstains were used, safranin proving the best.

In a few cases small blocks from various situations were cut in serial sections, parallel to the surface.

Since the skin contracted when incised, the following experiment was carried out to prevent this. On a thin cork, a circle 1 cm. in diameter was drawn and eight fine needles were pushed through the cork round this circle so that their sharp points projected about $\frac{1}{2}$ cm. on the other side. These were pushed well into the intact skin which was then excised with at least 1 cm. around the points and, with the needles still in position, the specimen was then fixed in corrosive sublimate. On histological examination thereafter, the part within the needle points showed no obvious difference in the elastic tissue from sections prepared in the ordinary way.

RESULTS

A. NORMAL SKIN

The elastic tissue in the normal skin consists of a superficial subepidermal layer of fine fibres forming a plexus, and of a deeper layer of much larger fibres (Figs. 5, 9*). The latter seem to be the more important in connexion with the

* Plates 1-4 contain Figs. 1-28.

gross physical property of elasticity in the skin. The quantity and arrangement of the elastic tissue was very similar in the same area of different individuals in the first and last age groups, but showed considerable individual variation in the middle age groups (15–40 years).

Deeper layer of main elastic fibres

This consists of large fibres of considerable length, arranged nearly parallel to the surface of the skin: the fibres are slightly tortuous, but lengths of 200μ or more are seen in sections 8μ in thickness (Figs. 1, 5 and 8). They run between the white collagen fibres, either transversely or parallel to the long axis of the body but not obliquely. In some areas (e.g. lateral side of the thigh, Fig. 3), they are distributed evenly throughout the thickness of the dermis, in others (e.g. medial side of the forearm, Fig. 5) they are more numerous or larger in the superficial part, or in the deeper (medial side of the leg, Fig. 1), or they may be arranged in bundles (lateral side of the leg, Fig. 2). The majority of fibres may run in one direction superficially and at right angles more deeply (abdomen, Fig. 7). They sweep round hair follicles and sweat glands (Figs. 1, 5, 10 and 11), leaving the immediate vicinity of these structures free from elastic tissue.

In some areas, most of the fibres are arranged in a definite pattern. Thus, on the medial sides of the limbs, most of them run transversely to the axis of the limb (Figs. 1, 5 and 9). On the lateral side (Figs. 2, 3) there are equal numbers running transversely and longitudinally. These features were constant for these areas in all subjects examined, though Cox (1941), in his study of the cleavage lines of the skin, found that for the most part the connective and elastic tissue fibres ran parallel to the main axis of the trunk and limbs. In most areas, the direction of the fibres varies in different subjects. A few areas show distinctive arrangements of the fibres and these are described later.

Between the skin and deep tissues, over most of the trunk and limbs, there run, through the subcutaneous fat, bands of connective tissue consisting of collagen and elastic fibres (Fig. 2). They allow of considerable range of movement of the skin in the living subject. In the palm and sole, however, the subcutaneous fat is largely replaced by dense connective tissue, composed chiefly of white fibres, which binds the skin firmly to the deep tissues. This alteration in the deep connexions is of importance in preventing the development of oedema in the sole or palm, any oedematous fluid being transferred to the dorsum of the foot or hand respectively, as is found in septic conditions.

Lindholm (1931) found slightly more elastic tissue in the skin of women than in that of men, but in the present series there was little evidence of sexual difference.

(a) Variations for age and site

(1) *First age group (0–5 years)*. In this age group, the elastic fibres are always numerous, well formed and large (Figs. 1–4 and 11). The skin of the leg, though much thinner than that of the thigh, contains as much elastic tissue, and the lateral side of the limbs shows thicker skin than the medial, but the same

proportion of elastic fibres. On the lateral side of the leg (Fig. 2) there is a tendency for the elastic tissue to be arranged in alternating bands of longitudinal and transverse fibres. The skin from the lateral side of the thigh (Fig. 3) is as thick as that from the abdomen (Fig. 4), but contains a very much greater proportion of elastic fibres. On the abdomen and chest the skin is thick, but the elastic fibres are fewer, smaller and finer than in the limbs.

(2) *Second age group (15–23 years)*. The skin in all areas is very much thicker than in the children, but the relative variation in thickness of the different sites is maintained. The elastic fibres are large and well formed but fewer than in earlier life (Figs. 5, 6), though the same relative proportions in the different sites are found.

(3) *Third age group (30–40 years)*. The elastic fibres (Figs. 7, 8) are fairly numerous but show slight irregularity in size compared to the previous groups. They may be evenly distributed or arranged in irregular bundles, leaving small areas bare of elastic tissue. Otherwise, for the different sites, variations in thickness of the skin and in the proportion of elastic fibres are the same as for the previous age group.

(4) *Fourth age group (over 65 years)*. The relative variation in thickness of the skin from the different parts remains the same. In the elastic fibres, degenerative changes are prominent (Figs. 9, 10); these consist of rough thickenings on the fibres, irregular fragmentation of the ends and variety in length of the fibres. Also, in contrast with the even distribution of elastic fibres of younger subjects, there is condensation and aggregation of the fibres into irregular masses.

In skin which is wrinkled and pigmented, as is most commonly found in parts exposed to the weather, such as the face and back of the hand and forearm (Fig. 10), the elastic tissue is increased in amount and irregularly distributed, being condensed into large, solid masses superficially, though the fibres remain separate in the deeper parts (vide eyebrow, Fig. 12).

(b) *Variations in special areas*

The number, size and arrangement of the elastic fibres in certain regions of the body merit special consideration, as there are some peculiarities in their pattern.

On the plantar surface of the toes, on the sole and on the palm, there is almost complete absence of the main elastic fibres, only a few running parallel to the surface between the bundles of white fibres. A few fibres are present alongside blood vessels or ducts of sweat glands, i.e. obliquely or perpendicularly to the surface. In the subcutaneous tissue there are larger collections of elastic fibres, arranged in bands.

The greatest number of large elastic fibres is found in the perineum, around the anus, being particularly abundant in the young (Fig. 11). The scrotum possesses practically no elastic tissue—even the fine subepidermal plexus is very poorly developed. Numerous rather short fibres are present in the skin of the penis, running chiefly transversely.

The skin of the back is very thick and contains numerous, large, elastic fibres; the deep surface of the dermis here shows a serrated edge, but the parts projecting into the subcutaneous adipose tissue do not contain so much elastic tissue as do the superficial parts.

Though the skin in the forearm and upper arm is thinner than in the leg and thigh, there is a corresponding proportion of elastic tissue in both limbs.

Although there is a great increase in the number of hair follicles in the scalp, breaking up the bands of connective tissue, yet elastic fibres are present in large numbers, especially in the more superficial part of the dermis.

The eyelids and eyebrows provide a curious contrast in their elastic tissue content. The eyebrows (Fig. 12) are similar to other parts of the face, as described by Ohno (1925), in that there are large collections of elastic tissue alternating with areas in which no elastic fibres are seen; the tissue is condensed into masses, staining deeply with Weigert's stain and situated immediately below the epidermis. The elastic tissue of the eyebrows is subject to excessive degenerative changes occurring with advancing age and exposure. In the eyelids (Fig. 13), however, there are only traces of elastic tissue in relation to hair follicles, glands and blood vessels.

Subepidermal plexus of fine elastic fibres

(a) Age changes

In the skin of children under 5 years (Figs. 1-4 and 11), in contrast to the abundance of main elastic fibres, there is almost complete absence of any fibres or fibrils immediately under the epidermis. A few small fibres may be seen about the age of 1 year, but there is nothing comparable to the appearances seen in the next age group.

At about 20 years of age (Figs. 5, 20), a very different picture is seen. There is a well-developed plexus consisting of a few small fibres running horizontally, obliquely and sometimes vertically a short distance below the epidermis, and from these finer fibrils spread out towards the epidermis, their number and arrangement varying in different parts of the body. In subjects of 30-40 years (Figs. 7, 15) the plexus is again well developed. In those over 65 years the small fibres are thicker than in younger subjects and the fine fibrils also, as was found by Lindholm (1931). In other cases they do not show these age changes, and occasionally they are completely absent (cf. Figs. 10, 16 and 19).

Around the hair follicles in their course through the dermis the fine plexus follows the indentations of the epidermis which surrounds the hair sheaths. The plexus in this situation shows the same changes for the different ages as elsewhere (Figs. 1, 5 and 10).

(b) Different sites

The plexus of fine elastic fibres and fibrils varies considerably even in the same section, especially in relation to the dermal papillae. Thus, between the papillae, only a narrow line of small fibres runs parallel to, and a little deeper

than, the bases of the epithelial cells, with a few fine fibrils running at right angles towards these cells (Figs. 5, 15). In the papillae, however, the plexus opens out and characteristic forms for skin from different parts of the body can be determined.

In skin from the sole of the foot, that covering the arch shows practically no fine plexus, whereas that of the ball of the great toe and of the heel shows a very well-developed elastic plexus with closely packed fibres and fibrils in the papillae and at their bases (Figs. 14, 16); this variation is probably due to the varying stress put on the parts in walking. On the dorsum of the foot, in the skin papillae, which occur in groups of two or three separated by stretches of level epithelium, a digitate appearance is found in the fine plexus, with a line of small fibres forming a regular arc of a circle parallel to the epidermis, and from this a few single, long, thin fibrils run out towards the epidermis; between the papillae there is little fine plexus.

In the plexus on the medial and lateral sides of the leg, the fibres on the former are thinner and situated farther from the epidermis than those on the latter; the fibrils on both sides are few and short. On the medial side of the thigh the papillae are large, numerous and rectangular; the small fibres of the plexus are grouped at the bases of the papillae, and the fine fibrils run out in long wavy bundles towards the superficial angles and apex. The fibres on the lateral side of the thigh (Fig. 19) are thicker and form a basal layer some distance from the epidermis with loops of varying length from which a few long, thin fibrils run towards the epidermis.

The structure of the fine elastic plexus in skin from the hand, forearm (Fig. 15) and upper arm corresponds closely with that from the foot, leg and thigh respectively. The few fibres and fibrils found in the skin from the abdomen are shown in Figs. 6 and 7.

Parts of the skin of the back are drawn into a large number of small folds with crushed papillae and epidermal cells. In these papillae (Fig. 17) there is a large amount of fine plexus in which small fibres run up and seem to end by branching into several long, thin fibrils stretching towards the epidermal cells. In other parts of the back (Fig. 18) the fine plexus appears as in the lateral side of the thigh.

The fine elastic plexus becomes greatly enlarged, and the fibres more numerous in connexion with the origin of the *arrectores pilorum* (Fig. 20). The fibrils extend close up to the epidermal cells and are spread out over a considerable area in relation to each muscle, thus accounting for the dimpling or 'gooseflesh' appearance when the muscles contract to erect the hair on exposure to cold.

Although this fine plexus of elastic tissue is present in the papillary layer of the dermis, neither the small fibres nor the fine fibrils ever come into direct contact with the epidermal cells. In a careful study of over one thousand thin sections of skin taken from different parts of normal subjects, I never found these fine elastic fibrils actually entering the epidermis, confirming the findings

of Schmidt (1891) and Kissmeyer & With (1922), although they did seem to do so in thick sections from the sole of the foot. There is always a distinct space separating the epidermis from the fine elastic plexus. Yet, if an attempt is made to separate the epidermis from the dermis, the usual result is that the epidermis comes away along with the superficial layer of the dermis, containing the fine plexus. Thus, the fine plexus would appear to play some part in binding firmly together the epidermis and dermis.

B. SKIN IN OEDEMA

The histological changes in the skin were studied in cases of general oedema associated with cardiac and renal disease as well as in localized types due to chronic inflammatory conditions. Changes in the amount and character of the elastic tissue depend on the duration of the oedema rather than on its type. In recent oedema, even though there is a considerable amount of oedematous change throughout the cutis vera (as seen in haemalum and eosin sections), the main fibres conform to the general appearance for a normal subject of corresponding age, except for slight separation of the fibres. In long-standing oedema, however, the large fibres are shortened and broken up, often to a marked degree (Fig. 21). The fine plexus is usually little altered in character but lies much deeper to the epidermis than in a normal case (Fig. 22). This finding is constant for all areas of the body and suggests that the loose areolar tissue immediately below the epidermis collects more fluid in oedema than the denser part with the main white and yellow fibres.

C. JUNCTION BETWEEN DERMIS AND EPIDERMIS: RETICULAR FIBRES

It was believed at one time (Herxheimer, 1916; Born, 1921; Cowdry, 1934) that there was a definite, continuous, eosinophil basement membrane on which the epidermis rested and which separated it completely from the dermis. With the introduction of the silver impregnation methods of staining, however, a network of reticular fibres was found (Frieboes, 1920; Pautrier & Woringer, 1930), forming a close connexion between the basal cells of the epidermis and the superficial part of the dermis. This subject has been reviewed by Mangnotti (1930) who concluded that the reticular layer, i.e. the outermost part of the dermic mesenchyme, did not constitute a formed membrane between the epidermis and dermis but was probably a morphological appearance which the intercellular colloids assumed in relation to the epidermal cells. Szodoray (1931) has described this reticular network in different parts of the skin and shown how the 'lattice fibrils' interweave with the flabelliform processes at the bases of the epithelial cells.

It has already been shown in this communication how the fine elastic plexus forms a network in the papillary layer of the dermis and yet never comes into actual contact with the epidermal cells; there is always a distinct space separating them. The layer of reticular fibres must occupy part or all of this space, and was studied in sections from all the different sites on the body stained by the silver impregnation method.

The most distinctive appearances of this reticular layer were found in the sole of the foot. At the bases of the papillae the reticular tissue consists of numerous very small fibrils, varying in shape and size, set close up to the bases of the epithelial cells and occupying the areas between the downwardly projecting processes of these cells. At the apices of the papillae, however, the reticular fibres are much more distinctive and are often seen very clearly in oblique sections of the tips (Figs. 23-25); here, long wavy fibrils are found just below the epidermis, with short, blunt ends (the so-called 'Homma's bodies'; cf. Homma, 1922) reaching towards the basal cells. Whether the fibrils form an open meshwork spread round the tips of the papillae, into the spaces of which the bases of the epithelial cells fit, or whether they form a series of fibrils running up to the cells and fixing them, either by entering them or by filling the spaces between their basal processes, is difficult to determine. In the lower power view (Fig. 23), bundles of distinct fibrils are seen to spread out slightly at the tips in a palisade arrangement.

A striking 'hedgehog' appearance (Fig. 27) was obtained on the medial side of the leg from a section parallel to the surface, cutting hair follicles transversely; the reticular fibres are arranged in a radiate fashion around the follicles, as if holding them in place. The skin of the posterior surface of the elbow shows little fine elastic plexus; with reticulum staining, however, an impressive arrangement of tall, cylindrical rods was found, in pairs or small clumps, fitting closely into spaces between the epidermal cells at the tips of the papillae with few reticular fibres at the bases of the papillae (Fig. 28). In other parts of the body the reticular layer shows similar evidence of fibril formation in the papillae, and elsewhere appears as an irregular line between the dermis and epidermis (Fig. 26).

Thus, comparison of the photographs of skin stained for reticular fibres with those stained for elastic tissue demonstrates that these kinds of tissue have very different arrangements and distribution and are quite distinct from each other. There is, as far as these staining methods show, no continuation of the fine elastic fibres as reticular fibrils up to the bases of the epithelial cells. Although the fine elastic tissue develops such characteristic forms as have been shown, close under the epidermis, it does not take part in the ultimate junction between dermis and epidermis and can play the part only of a reserve force in preventing separation. The elements concerned in the actual binding together of dermis and epidermis are the reticular layer and the bases of the epithelial cells. In agreement with Manganotti (1930), the results show that the reticular layer is probably a disposition of the intercellular colloids, but, in addition, there is possibly a more definite formation of fibrils in the parts where the reticular network is as well developed as in the tips of the papillae in the sole of the foot.

SUMMARY

The distribution of yellow elastic tissue in the skin is described and illustrated from an investigation of thirty-two normal subjects with additional observations from other subjects.

The elastic tissue consists of two parts:

- (i) large fibres in the deeper part of the dermis,
- (ii) a fine network of small fibres lying close under the epidermis.

Variations in the quantity and characteristics of these two parts are described and illustrated in:

- (i) skin from different situations of the body,
- (ii) skin from subjects of different ages.

A brief description is given of the changes in the elastic tissue in subjects with oedema.

The reticular fibres of the skin at the junction of dermis and epidermis have been shown to be distinct from the elastic tissue.

This work was carried out during the author's tenure of the Hutchison Research Scholarship, 1934-5 and thereafter under the kindly guidance of the late Prof. J. Shaw Dunn.

REFERENCES

- BORN, S. (1921). Zur Frage der epidermalen Basalmembran. *Derm. Z.* **34**, 324-331.
- COWDRY, E. V. (1934). *Textbook of Histology*, p. 443. London: Henry Kimpton.
- COX, H. T. (1941). The cleavage lines of the skin. *Brit. J. Surg.* **29**, 234-240.
- FOOT, N. C. (1929). Notes on rapid impregnation of reticular tissue with silver. *J. tech. Meth.* **12**, 117-119.
- FRIEBOES, W. (1920). Beiträge zur Anatomie und Biologie der Haut. II. Basalmembran; Bau des Deckepithels (I. Physiologische und Pathologische Ausblicke). *Derm. Z.* **31**, 57-83.
- GEIGER, R. (1927). Zur Frage der Entwicklung der elastischen Fasern in der Haut. *Arch. Derm. Syph., Wien*, **154**, 108-120.
- HASS, G. M. (1939). Elastic tissue. *Arch. Path. Lab. Med.* **27**, 334-365, 583-613.
- HERXHEIMER, K. (1916). Ueber die epidermidale Basalmembran. *Derm. Z.* **23**, 129-134.
- HOMMA, H. (1922). Gitterfasern in normaler menschlicher Haut. *Wien. klin. Wschr.* **35**, 149-150.
- KISSMEYER, A. & WITTH, C. (1922). Clinical and histological studies on pathological changes in elastic tissue of the skin. *Brit. J. Derm.* **34**, 175-194.
- LINDHOLM, E. (1931). Ueber die Schwankungen in der Verteilung der elastischen Fasern in der menschlichen Haut als Beitrag zur Konstitutionspathologie. *Frankfurt. Z. Path.* **42**, 394-414.
- MANGANOTTI, G. (1930). Osservazioni sulla così detta membrana basale e sul tessuto reticolare del derma nella cute normale ed in alcune dermatosi. Ricerche sui rapporti dermo-epidermici. *G. ital. Derm. Sif.* **71**, 1901-1916.
- OHNO, T. (1925). Pathologisch-histologische Studien über die elastischen Fasern der menschlichen Haut. *Arch. Derm. Syph., Wien*, **149**, 486-492.
- PAUTRIER, L. M. & WORINGER, F. (1930). Contribution à l'étude de l'histo-physiologie cutanée; les rapports morphologiques entre l'épiderme et le derme. *Ann. Derm. Syph., Paris*, **1**, 985-1005.
- SCHMIDT, M. B. (1891). Ueber die Altersveränderungen der elastischen Fasern in der Haut. *Virchows Arch.* **125**, 239-251.
- STERNBERG, C. (1925). Ueber die elastischen Fasern. *Virchows Arch.* **254**, 656-661.
- SZODORAY, L. (1931). The structure of the junction of the epidermis and the corium. *Arch. Derm. Syph., N.Y.*, **23**, 920-925.

EXPLANATION OF PLATES

PLATE 1

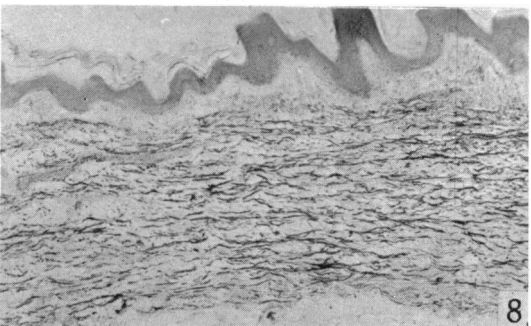
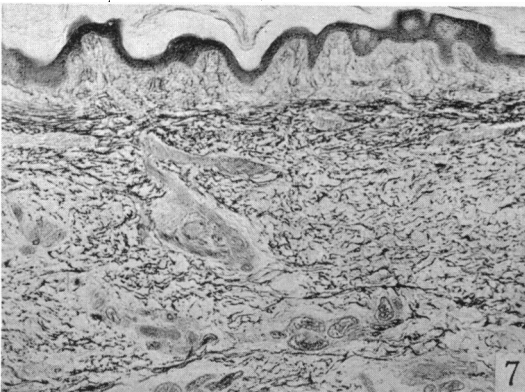
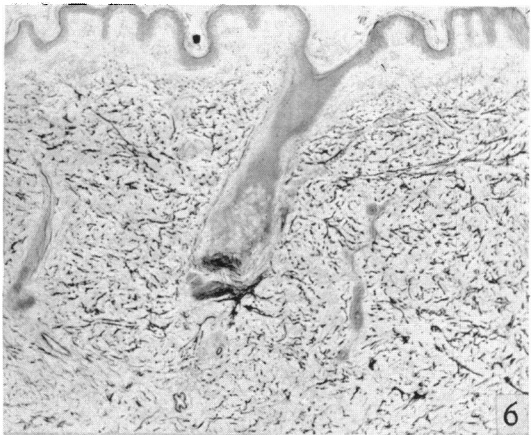
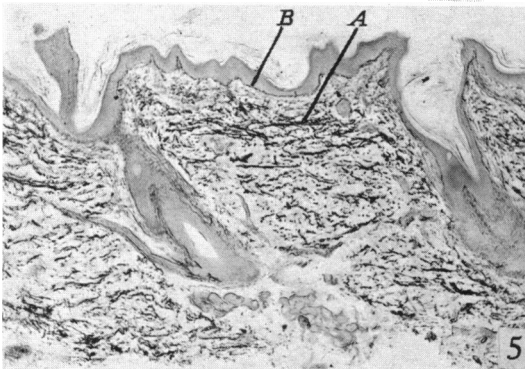
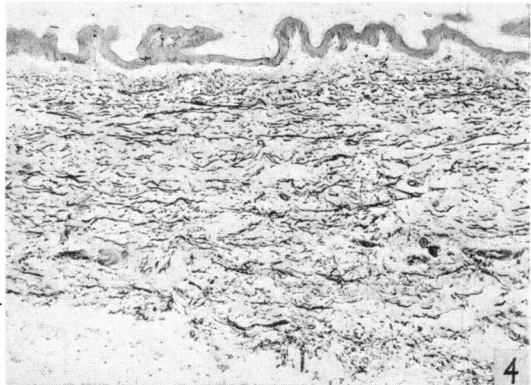
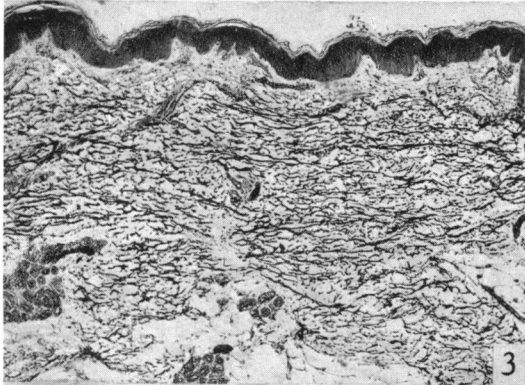
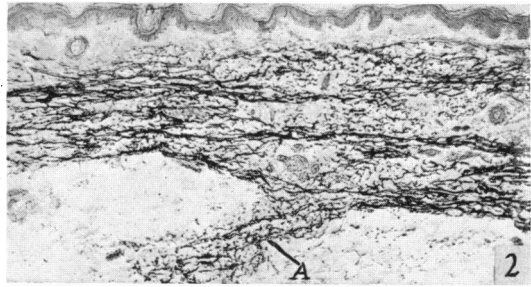
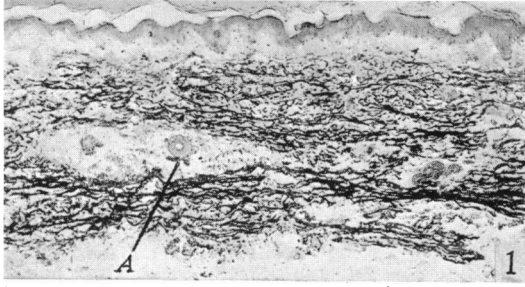
- Fig. 1. Skin of leg, medial side, transverse. Main elastic fibres large, well formed and distributed fairly evenly, though larger in the deeper parts and absent round hair follicles (*A*). 15843, male, 1 year. Weigert's elastic tissue stain, $\times 40$.
- Fig. 2. Skin of leg, lateral side, transverse. Main elastic fibres arranged mostly in bands. *A*, subcutaneous band of connective and elastic tissue. 15843, male, 1 year. Weigert, $\times 40$.
- Fig. 3. Skin of thigh, lateral side, transverse. Main elastic fibres numerous and evenly distributed. 4188, male, $1\frac{1}{2}$ years. Weigert, $\times 40$.
- Fig. 4. Skin of abdomen, transverse. Main elastic fibres shorter and fewer than in thigh (Fig. 3). 4188, male, $1\frac{1}{2}$ years. Weigert, $\times 40$.
- Fig. 5. Skin of forearm, medial side, transverse. *A*, main elastic fibres, most numerous towards the superficial part of the cutis vera, and mostly running in line of section. *B*, fine elastic plexus. 15665, female, 17 years. Weigert, $\times 40$.
- Fig. 6. Skin of abdomen, longitudinal. Main fibres few and short, distributed evenly through skin 16088, male, 15 years. Weigert, $\times 40$.
- Fig. 7. Skin of abdomen, longitudinal. Main fibres relatively short and thin, arranged parallel to line of section near the surface, transversely deeper. 16110, female, 35 years. Weigert, $\times 40$.
- Fig. 8. Skin of thigh, medial side, transverse. Main fibres large, but slightly irregular in shape and distribution. 16110, female, 35 years. Weigert, $\times 40$.

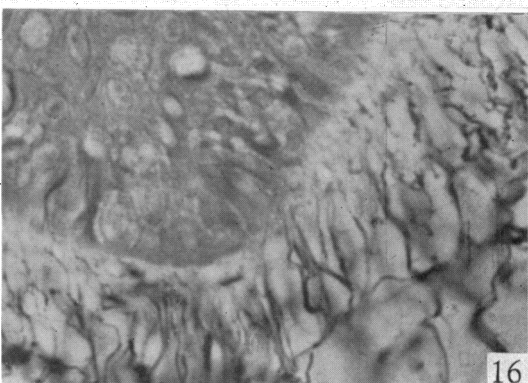
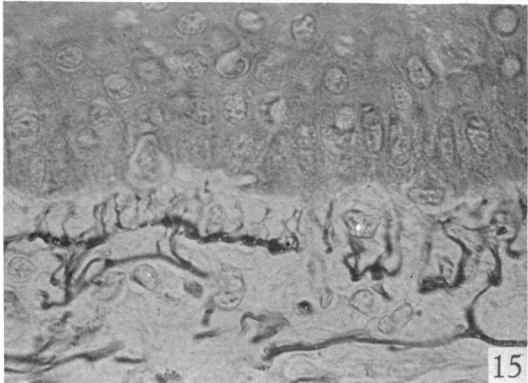
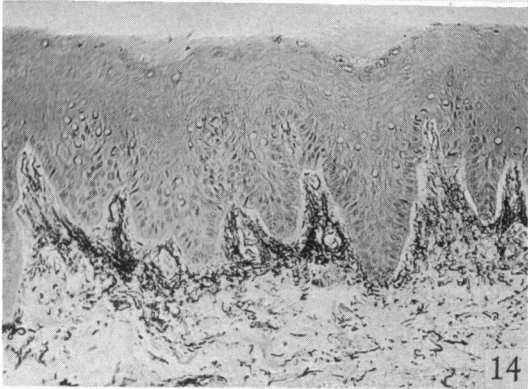
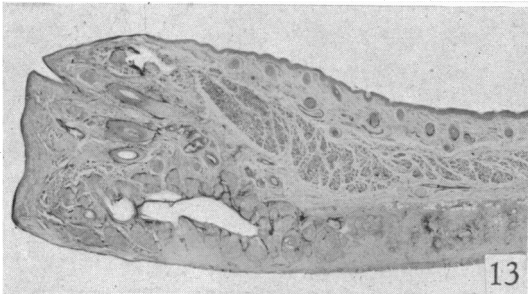
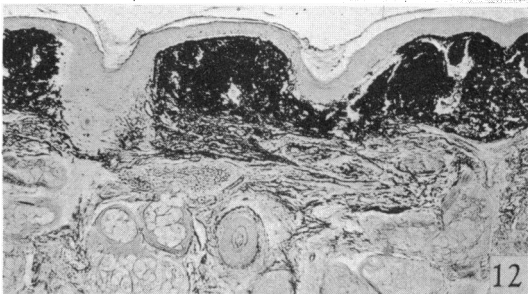
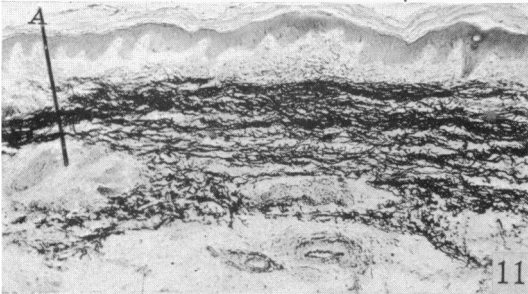
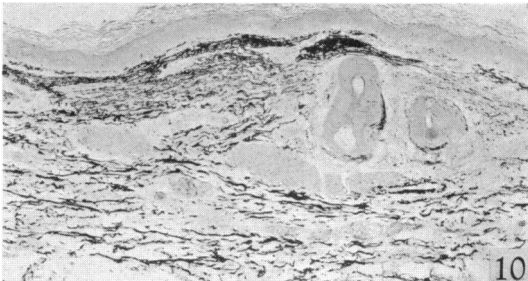
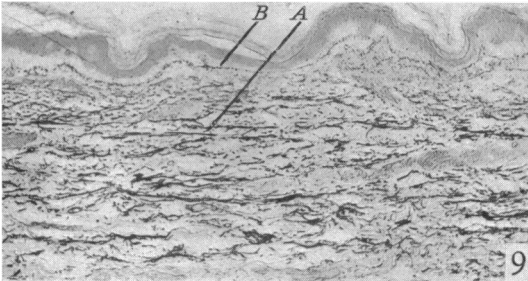
PLATE 2

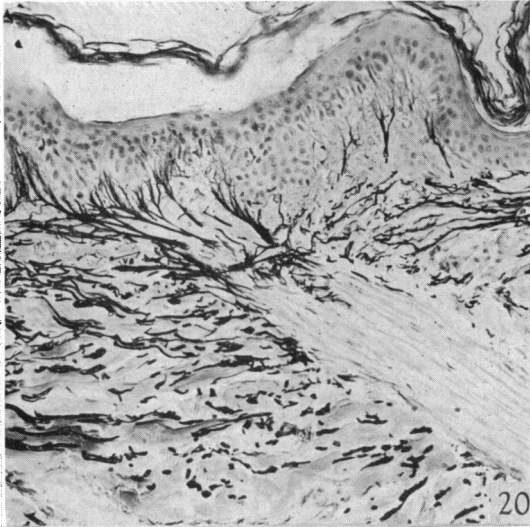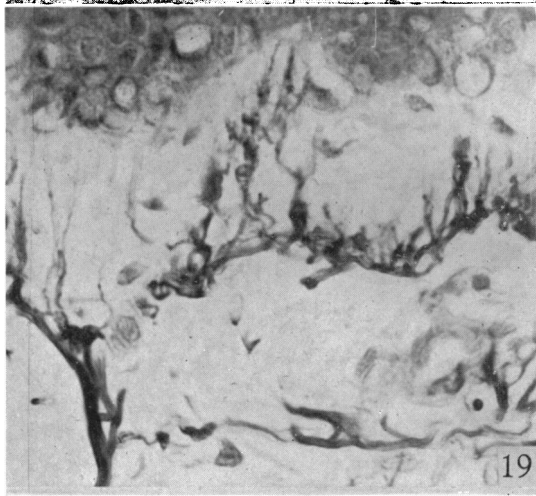
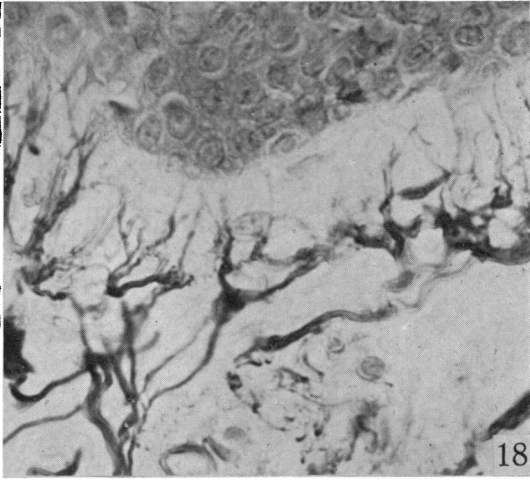
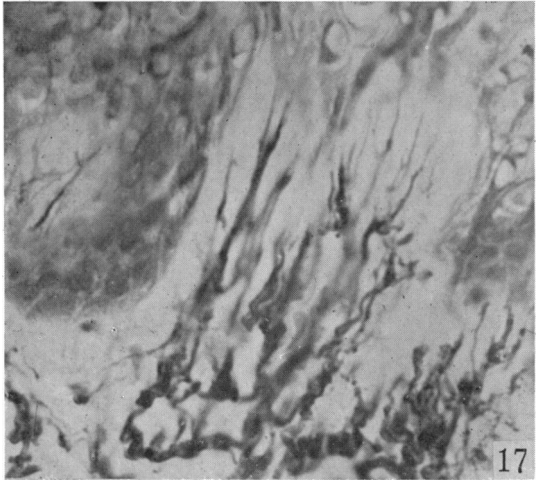
- Fig. 9. Skin of thigh, medial side, transverse. *A*, main fibres, more irregular in size and distribution than in Fig. 8. *B*, fine elastic plexus. 15785, male, over 65 years. Weigert, $\times 40$.
- Fig. 10. Skin of forearm, lateral, side, transverse. Elastic tissue irregularly thickened and condensed—degenerative changes due to old age and exposure. 15795, female, 77 years. Weigert, $\times 40$.
- Fig. 11. Skin of perineum. Main elastic fibres are very numerous, except round sweat gland (*A*). 15843, male, 1 year. Weigert, $\times 40$.
- Fig. 12. Skin from eyebrow. Note large quantity of dense elastic tissue under the epidermis. Accident case, male, about 35 years. Weigert, $\times 40$.
- Fig. 13. Eyelid—skin surface above, conjunctival surface below. No elastic tissue present except round hair follicles and in vessel walls. Same case as Fig. 12. Weigert, $\times 10$.
- Fig. 14. Skin of sole of foot, transverse. Dense plexus of fine elastic fibres in several papillae. A6, male, 70 years. Weigert, $\times 150$.
- Fig. 15. Skin of forearm, lateral side, transverse. Small elastic fibres very distinct. 16110, female, 35 years. Weigert, $\times 600$.
- Fig. 16. Skin of sole of foot, transverse. Typical appearance of fine elastic plexus in this site. 15834, female, 64 years. Weigert, $\times 600$.

PLATE 3

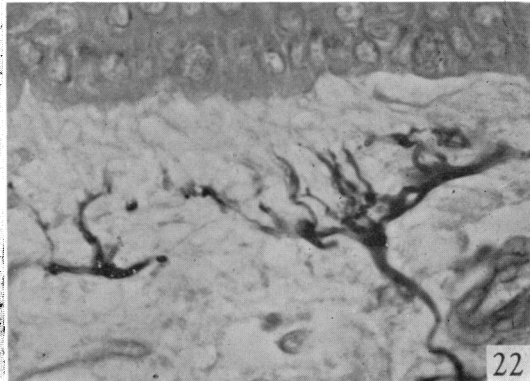
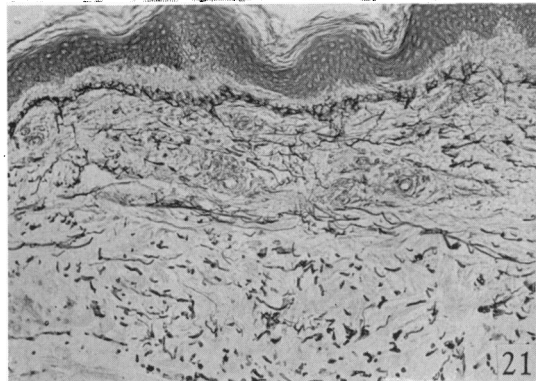
- Fig. 17. Skin of back. Folded part of skin with fine elastic plexus of small fibres crushed together. 15834, female, 64 years. Weigert, $\times 600$.
- Fig. 18. Skin of back (cf. Fig. 17). Part of skin with no fold: fine elastic plexus spread out. 15834, female, 64 years. Weigert, $\times 600$.
- Fig. 19. Skin of thigh, lateral side, longitudinal. Small elastic fibres and fibrils under epidermis. 15834, female, 64 years. Weigert, $\times 600$.
- Fig. 20. Skin of arm, lateral side, transverse. Elastic tissue well developed at origin of *arrector pili* (*A*). 16073, female, 23 years. Weigert, $\times 150$.
- Fig. 21. Skin of abdomen, longitudinal. Oedema. Main fibres slightly separated. Fine plexus some distance from epidermis. 16140, male, 70 years. Weigert, $\times 150$.
- Fig. 22. Skin of abdomen, longitudinal. Oedema. Fine elastic plexus set well below epidermis. 16140, male, 70 years. Weigert, $\times 600$.







} 4



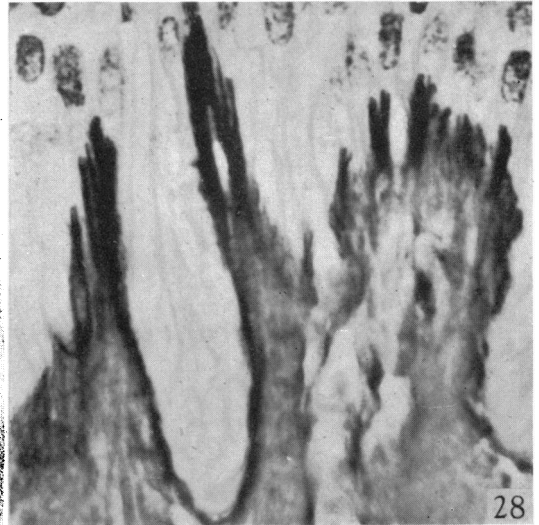
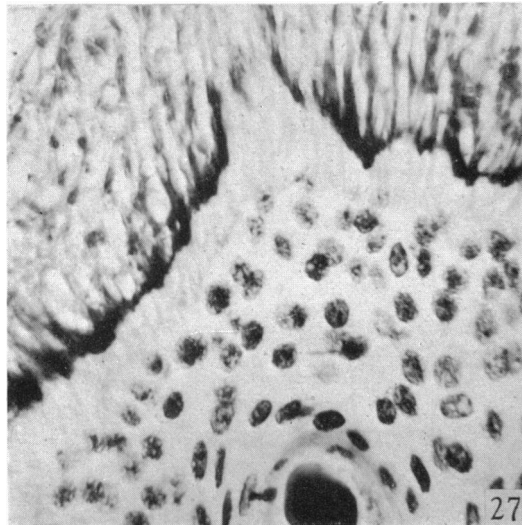
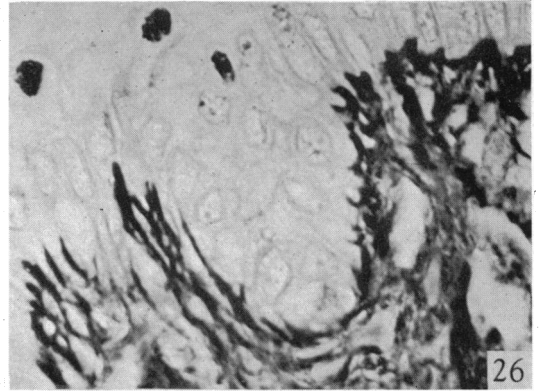
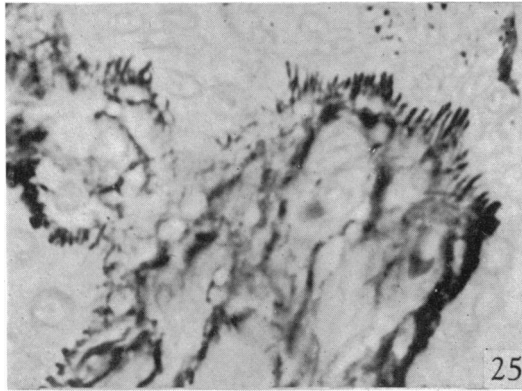
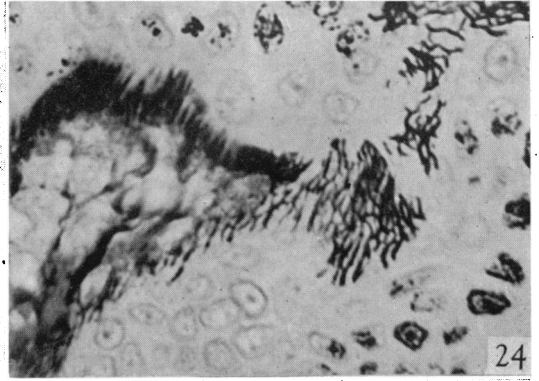
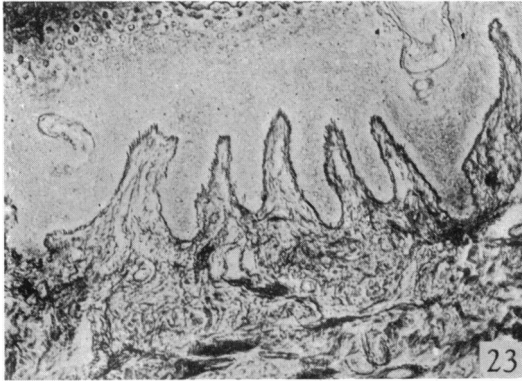


PLATE 4

- Fig. 23. Skin of sole of foot. Several papillae with reticular fibres at their tips. A 6, male, 70 years. Foot's silver impregnation method, $\times 150$.
- Fig. 24. Skin of sole of foot. Reticular fibrils long and wavy, forming a loose network, in oblique section, near the tip of a papilla. A 2, male, 31 years. Foot, $\times 600$.
- Fig. 25. Skin of sole of foot. Reticular fibrils forming definite rods (Homma's bodies) at tip of papilla. A 2, male, 31 years. Foot, $\times 600$.
- Fig. 26. Skin of dorsum of foot. Reticular tissue indefinite at bases of papillae, more definitely rod-shaped at tips. A 2, male, 31 years. Foot, $\times 600$.
- Fig. 27. Skin of leg, medial side, cut parallel to the surface. Note distribution of reticular fibrils round hair follicle. A 2, male, 31 years. Foot, $\times 600$.
- Fig. 28. Skin of elbow, posterior surface. Formation of definite reticular fibrils at tips of papillae. 15682, male, 17 years. Foot, $\times 600$.