

# Clinical review

## Shoulder pain: diagnosis and management in primary care

Caroline Mitchell, Ade Adebajo, Elaine Hay, Andrew Carr

Institute of General Practice and Primary Care, School of Health and Related Research (SchARR), University of Sheffield, Northern General Hospital, Sheffield S5 7AU  
Caroline Mitchell  
*senior clinical lecturer*

Academic Rheumatology Group, Division of Genomic Medicine, University of Sheffield Medical School, Sheffield S10 2RX

Ade Adebajo  
*honorary senior lecturer*

Primary Care Sciences Research Centre, Keele University, Keele ST5 5BG

Elaine Hay  
*professor of community rheumatology*

Nuffield Department of Orthopaedic Surgery, University of Oxford, Oxford OX3 7LD

Andrew Carr  
*Nuffield professor of orthopaedic surgery*

Correspondence to: C Mitchell  
c.mitchell@sheffield.ac.uk

BMJ 2005;331:1124-8

Compromised shoulder movement due to pain, stiffness, or weakness can cause substantial disability and affect a person's ability to carry out daily activities (eating, dressing, personal hygiene) and work.<sup>w1</sup> Self reported prevalence of shoulder pain is estimated to be between 16% and 26%; it is the third most common cause of musculoskeletal consultation in primary care, and approximately 1% of adults consult a general practitioner with new shoulder pain annually.<sup>1</sup> Occupations as diverse as construction work and hairdressing are associated with a higher risk of shoulder disorders. Physical factors such as lifting heavy loads, repetitive movements in awkward positions, and vibrations influence the level of symptoms and disability, and psychosocial factors are also important.<sup>w1</sup> Recent studies suggest that chronicity and recurrence are common.<sup>2-3</sup>

Common shoulder disorders exhibit similar clinical features, and the lack of consensus on diagnostic criteria and concordance in clinical assessment complicates treatment choices.<sup>3 w2-w5</sup> This review proposes an evidence based approach using a simplified classification of shoulder problems, incorporating diagnostic techniques applicable to a primary care consultation and a "red flag" system to identify potentially serious disease.

### Sources and selection criteria

We incorporated the latest consensus from systematic reviews and publications identified by a literature search through Medline, CINAHL, AMED, the Cochrane Library (Central, CDSR, HTA, DARE), Clinical Evidence, Best Evidence, Embase, British Nursing Index, PEDro,<sup>w6</sup> Web of Science (social science and science citation indexes), and bmj.com. The search strategy included the terms "shoulder pain", "rotator cuff disorder", "rotator cuff tear", "frozen shoulder", and "primary care".

We found six published systematic reviews of interventions for shoulder disorders and one health technology assessment systematic review of diagnostic tests for the assessment of shoulder pain.<sup>4-10</sup> A topic search within Clinical Evidence identified the section "Shoulder pain."<sup>11</sup> We identified and critically appraised other key publications in peer reviewed journals that were relevant to primary care or published since the latest systematic reviews.<sup>w7</sup>

### Summary points

Mixed shoulder disorders are common, and overdifferentiation of diagnostic categories does not alter largely conservative management in primary care

Self help advice, including relative rest and attention to occupational, sporting, or other physical contributory factors, should be offered as well as analgesics

The evidence for common interventions such as steroids and physiotherapy is relatively weak

Physiotherapy may reduce repeat primary care consultations for rotator cuff disorders, and steroid injections have a marginal short term effect on pain

Poorer prognosis is associated with increasing age, female sex, severe or recurrent symptoms at presentation, and associated neck pain

Surgery should be considered when conservative measures fail

### Assessment of the painful shoulder

Diagnosis should be pragmatic and based on a clinical assessment (box 1) that groups patients according to the most common presentations in primary care (figure). An overcomplicated approach to diagnosis is unlikely to alter early conservative management in primary care.<sup>12</sup>

The four most common causes of shoulder pain and disability in primary care are rotator cuff disorders, glenohumeral disorders, acromioclavicular joint disease, and referred neck pain (box 2).

One primary care study that used standardised clinical tests for shoulder disorders found rotator cuff tendinopathy in 85% of patients, but in 77% of patients a clinical diagnosis of more than one shoulder problem was made—for example, tendinosis and



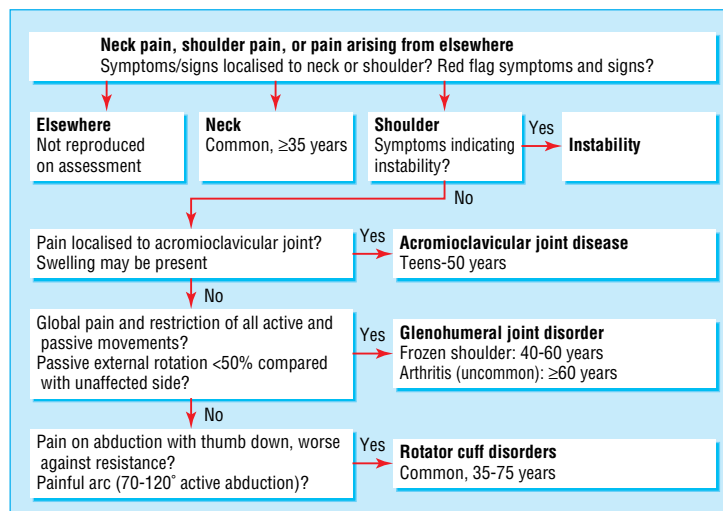
Extra references w1-12 are on bmj.com

impingement (57%); tendinosis, impingement, acromioclavicular disease, and adhesive capsulitis (6%).<sup>13</sup> Blood tests and radiography are indicated only if there are “red flag” indicators such as symptoms and signs of systemic disease (weight loss, generalised joint pains, fever, lymphadenopathy, new respiratory symptoms); history of cancer; or concerning local features such as a mass lesion or bony tenderness or swelling (box 3).

### Rotator cuff disorders (age 35-75)

Rotator cuff tendinopathy is the most common cause of shoulder pain. An occupational history may reveal heavy lifting or repetitive movements, especially above shoulder level.<sup>w1</sup> Although related to activity, it often occurs in the non-dominant arm and in non-manual workers. Evidence suggests genetic susceptibility in some families.<sup>ws</sup> Wasting may be present on examination; active and resisted movements are painful and may be partially restricted, whereas passive movements are full, albeit painful. Although a painful arc is neither specific nor sensitive as a clinical sign, its presence reinforces the diagnosis of a rotator cuff disorder.<sup>14</sup>

A rotator cuff tear is usually strongly indicated by the history: traumatic in young people and atraumatic in elderly people (related to attrition from bony spurs on the undersurface of the acromion or intrinsic degeneration of the cuff). Partial tears may be difficult



Diagnosis of shoulder problems. Adapted with permission from shoulder pain algorithm: [www.oxfordshoulderandelbowclinic.org.uk](http://www.oxfordshoulderandelbowclinic.org.uk)

to differentiate from rotator cuff tendinopathy on examination; weakness in resisted movement may occur in either condition. Several studies have suggested that no correlation exists between symptoms and loss of function in the presence of full thickness supraspinatus tears, that tears of the lower rotator cuff may lead to inability to rotate beyond 20°, and that partial and full thickness tears are commonly found during imaging of asymptomatic people.<sup>15-17</sup> The “drop arm test” may be used to detect a large or complete tear (a high specificity and low sensitivity for this test was reported in a secondary care population).<sup>14</sup>

### Box 1: History and examination of the shoulder joint

#### History

- Onset, characteristics, and functional impact of shoulder pain?
- Dominant/non-dominant hand?
- Is pain at rest, on movement, or both?
- Is pain present at night?
- Does the pain affect sleeping position?
- Any neck, thoracic, or other upper limb pain?
- History of acute trauma, shoulder pain, or instability (joint dislocates or concern that might dislocate during certain movements)?
- Occupation and sporting activities?
- Other joints affected?
- Systemic symptoms of illness (fever, weight loss, rash, respiratory symptoms)?
- Significant comorbidity (diabetes; stroke; cancer; respiratory, gastrointestinal, or renal disease; ischaemic heart disease; psoriasis)?
- Current drug treatment and adverse drug reactions?

#### Examination

- Examine neck, axilla, and chest wall
- Assess range of movement of cervical spine
- Inspect shoulders for swelling, wasting, and deformity
- Palpate sternoclavicular, acromioclavicular, and glenohumeral joints for tenderness, swelling, warmth, and crepitus
- Compare power, stability, and range of movement (active, passive, resisted) of both shoulders
- Look for painful arc (70-120° active abduction)
- Test passive external rotation
- “Drop arm test”: patient lowers abducted arm slowly to waist

### Box 2: Causes of shoulder pain

#### Pain arising from the shoulder

- Rotator cuff disorders: rotator cuff tendinopathy, impingement, subacromial bursitis, rotator cuff tears
- Glenohumeral disorders: capsulitis (“frozen shoulder”), arthritis
- Acromioclavicular disease
- Infection (rare)
- Traumatic dislocation

#### Pain arising from elsewhere

- Referred pain: neck pain, myocardial ischaemia, referred diaphragmatic pain
- Polymyalgia rheumatica
- Malignancy: apical lung cancers, metastases

### Box 3: Red flag indicators

- History of cancer; symptoms and signs of cancer; unexplained deformity, mass, or swelling: ? tumour
- Red skin, fever, systemically unwell: ? infection
- Trauma, epileptic fit, electric shock; loss of rotation and normal shape: ? unreduced dislocation
- Trauma, acute disabling pain and significant weakness, positive drop arm test: ? acute rotator cuff tear
- Unexplained significant sensory or motor deficit: ? neurological lesion

**Glenohumeral disorders (adhesive capsulitis: age 40-65, median 50-55; osteoarthritis:  $\geq 60$ )**

Adhesive capsulitis (“frozen shoulder”) and true glenohumeral arthritis are often preceded by a history of non-adhesive capsulitis symptoms, are characterised by deep joint pain, and restrict activities such as putting on a jacket (impaired external rotation). Adhesive capsulitis is more common in people with diabetes and may also occur after prolonged immobilisation. On examination global pain is present, along with restriction of all movements, both active and passive.

**Acromioclavicular disease (teenage to 50)**

Acromioclavicular disease is usually secondary to trauma or osteoarthritis; dramatic joint dislocation can occur after injury (teenage to 30 years). Pain, tenderness, and occasionally swelling are localised to this joint, and there is restriction of passive, horizontal adduction (flexion) of the shoulder, with the elbow extended, across the body. Acromioclavicular osteoarthritis may also cause subacromial impingement.

**Referred mechanical neck pain (common)**

Typically there is pain and tenderness of the lower neck and suprascapular area, referred to the shoulder and upper limb area; shoulder movement may be restricted. Movement of the cervical spine and shoulder may reproduce more generalised upper back, neck, and shoulder pain. Upper limb paraesthesia may occur.<sup>18</sup> Treatment is with relative rest and analgesia, and return to normal activities should be encouraged. Physiotherapy may be helpful.

**Treatment**

A functional holistic approach to shoulder pain, including adequate analgesia, is important to motivate patients and encourage rehabilitation. However, the evidence for common primary care interventions, including steroid injections, is relatively weak.<sup>6</sup> The general practitioner should decide whether the pain is arising from the shoulder; if it is from elsewhere, the patient should be treated and referred appropriately.

If the pain is arising from the shoulder, is it due to a rotator cuff disorder or a glenohumeral joint problem? For both these shoulder disorders, analgesics should be recommended (ideally paracetamol; non-steroidal anti-inflammatory drugs should be used intermittently as second line if no contraindications exist), activity should be encouraged, and written information provided (for example, the Arthritis Research Campaign’s patient leaflet).

**Rotator cuff disorders (including possible minor tears)**

Rotator cuff disorders should be treated initially with relative rest of the shoulder. The patient should return to normal activity or temporarily modified work as soon as possible,<sup>11</sup> within the limits of the disability and pain. Overall, systematic reviews and more recent studies suggest equivalent short term benefit for physiotherapy (incorporating supervised exercise) and steroid injections in the management of shoulder disorders.<sup>6, 7, 10</sup> In a primary care population with undifferentiated shoulder disorders, participants allocated to a physiotherapy treatment group were less likely to

re-consult with a general practitioner than were those receiving steroid injections alone.<sup>12</sup>

A single recent study reported that a subacromial injection of xylocaine was as effective as steroid plus xylocaine in all disease specific outcome measures at two weeks, with follow-up of participants at six, 12, and 24 weeks.<sup>9</sup> Some practitioners recommend larger volumes of injection of up to 10 ml, as a theoretical benefit of hydrodilatation of the subacromial bursa exists. However, inadequate evidence is available on evaluating outcomes with variation in volume injected.<sup>19</sup> Therefore, subacromial corticosteroid injections, up to 10 ml in volume, should be considered for short term pain relief and to facilitate rehabilitation. If the initial response is good, the injections should be repeated up to three times, at six weekly intervals. No evidence exists to show that steroid injections are either harmful or beneficial in the presence of a rotator cuff tear, so they should be avoided if the drop arm test is positive.<sup>5, 10</sup>

**Glenohumeral disorders**

Traditional teaching is that the natural history of a frozen shoulder is recovery by two years; however, symptoms may persist for three years or more in some cases, particularly in patients with diabetes mellitus. Corticosteroid injections (intra-articular, anterior approach) may be of benefit in reducing pain in the early phase.<sup>10</sup> No evidence exists to show that

**Additional educational resources****Professional resources**

- Arthritis Research Campaign. In Practice Series 4. Hazleman B. *Shoulder problems in general practice* (available by post and at [www.arc.org.uk/about\\_arth/med\\_reports/series4/ip/6502/6502.htm](http://www.arc.org.uk/about_arth/med_reports/series4/ip/6502/6502.htm))—one of a comprehensive series of musculoskeletal educational leaflets for general practitioners; well written and consistent with patient information
- Nuffield Orthopaedic Centre, Oxford ([www.oxfordshoulderandelbowclinic.org.uk](http://www.oxfordshoulderandelbowclinic.org.uk))—has a clinical algorithm for assessment linked to a management plan, physiotherapy guidelines for perioperative treatment for surgical interventions, and information for patients
- Carr AJ, Hamilton WH, eds. *Orthopaedics in primary care*. 2nd ed. Butterworth Heinemann, 2005—includes instructions for, and free downloadable video clips of, shoulder injection techniques and case study diagnosis and management; each draft chapter was reviewed and revised by the authors with a group of general practitioners
- *Frozen shoulder (adhesive capsulitis)*. BMJ Learning ([www.bmjlearning.com](http://www.bmjlearning.com))—an online learning module, including a short test and a certificate to include in a personal development plan

**Resources for patients**

- Arthritis Research Campaign. *The painful shoulder* (patient leaflet available by post and at [www.arc.org.uk](http://www.arc.org.uk))—helpful for self management before going to a general practitioner; also mentions neck pain as a possible cause of shoulder pain
- NHS Direct ([www.nhsdirect.nhs.uk](http://www.nhsdirect.nhs.uk))—most informative for “frozen shoulder;” no separate information on rotator cuff disorders or surgical interventions

physiotherapy alone is of benefit for adhesive capsulitis; when the joint is very painful, movement is distressing and may well be counterproductive.<sup>7</sup> Intra-articular corticosteroid injections and physiotherapy, starting one week after the injection, may be of short term benefit.<sup>20</sup> However, in this study, intra-articular injection was done as a guided technique using fluoroscopy, limiting the generalisability of these findings to primary care.

### Acromioclavicular disorders

Acromioclavicular disorders usually resolve with rest and simple analgesia, unless significant traumatic dislocation is present. If symptoms persist, a local steroid injection may help.

### Biopsychosocial and complementary interventions

Individual psychosocial factors such as a passive coping style, fear of movement, and general psychological distress influence the risk of chronicity of symptoms in low back and neck pain. Therefore, targeted interventions to alter these and any occupational factors have also been suggested for shoulder disorders.<sup>11</sup> A systematic review, however, concluded from the little evidence available that no evidence showed that multidisciplinary biopsychosocial rehabilitation is better than "usual care" in the management of shoulder problems in adults of working age.<sup>9</sup>

The only complementary therapy widely reported on is acupuncture. The studies identified by systematic review were small and methodologically diverse and provided little evidence to either support or refute the use of acupuncture for shoulder disorders.<sup>5, 8</sup> The authors concluded that acupuncture may improve pain and function in the short term (two to four weeks).<sup>8</sup>

### Further investigation

Ultrasound examination and magnetic resonance imaging have been reported as useful diagnostic tools in secondary care and may increase the specificity of diagnosis.<sup>3, 21, 22, w2</sup> However, early access to these investigations is unlikely to improve management of a heterogeneous group of shoulder disorders that should usually be managed conservatively and for which surgical intervention (informed by sophisticated imaging techniques) is rarely indicated. Structural abnormalities may be present in asymptomatic patients,<sup>15</sup> and thus early investigation may paradoxically increase referral rates to specialists.<sup>w11</sup>

### Referral criteria

The patient should be referred to an orthopaedic specialist if there is

- Pain and significant disability lasting more than six months, despite attention to occupation or sporting factors and, if indicated, physiotherapy and steroid injections
- History of instability ("Has your shoulder ever partly or completely come out of joint?" "Are you worried that your shoulder might slip on certain

### Patient's perspective

My (right) shoulder problem started about six months ago; I think it was after I had been in a really awkward position while helping to care for my father. It became gradually more painful and was affecting my sleep; then I could not lift my arm up, nor could I put it behind my back. I could wear only clothes with front fastenings, and not if I had to use pressure, as it was painful to turn my arm inwards. When I needed to go to the toilet, I could not unfasten my trousers or pull clothes down quickly.

I am right handed, and everyday activities such as brushing my teeth or eating are still difficult and painful and take longer. When I am driving, it is painful to look over my right shoulder and to put the seat belt on. I was wary of going out if the paths were icy, because if I slipped I automatically put my right hand out, which was excruciating. Work is affected because I use computers; using the mouse becomes uncomfortable and makes my hand ache. I had had a frozen shoulder before, three years ago (the other arm); it was less painful and righted itself in about 18 months. This time I decided to go to a physiotherapist. I have been four times now; he has used acupuncture and lots of soft tissue and joint mobilising techniques, and I have exercises to do. The pain around my shoulder has gradually lessened, and although the movement is unchanged, I am confident it will come back.

F, a 50 year old woman with shoulder pain

movements?") or acute, severe post-traumatic acromioclavicular pain

- Diagnostic uncertainty or red flag criteria summarised in box 3.

### Future developments and surgical interventions

Surgery has a place in the management of emergencies such as unreduced dislocation, infection, and traumatic acute rotator cuff tear. Its role is less clear in frozen shoulder, for which some surgeons advocate manipulation under anaesthesia and arthroscopic release.<sup>23</sup> A recent study found equivalent results for graduated supervised physiotherapy programmes and arthroscopic decompression for patients with rotator cuff disease.<sup>24</sup> For significant persistent disability associated with impingement and rotator cuff tear, surgery may be effective at relieving pain and restoring function in patients who have failed conservative treatment. However, published studies typically involve small numbers of participants with limited long term follow-up.<sup>5</sup> Controversy exists regarding the management of mildly symptomatic small rotator cuff tears. Arguably, small tears should be repaired to relieve symptoms and to prevent progression to larger tears, which are associated with high levels of disability, but little evidence exists to support this view. For resistant acromioclavicular joint pain, an arthroscopic excision of the distal clavicle is an effective low risk procedure. Surgery remains the mainstay of management for most cases of recurrent shoulder instability; those cases that do not need surgery will need specialist physiotherapy and can be difficult and resistant problems. The management of osteoarthritis and



rheumatoid arthritis has improved considerably in recent years, and joint replacement surgery, as with other joints, provides relief of pain for end stage disease.

## Conclusions

Shoulder pain is a common and important musculo-skeletal problem. Management should be multi-disciplinary and include self help advice, analgesics, relative rest, and access to physiotherapy. Steroid injections have a marginal short term effect on pain.

Poorer prognosis is associated with increasing age, female sex, severe or recurrent symptoms at presentation, and associated neck pain. Mild trauma or overuse before onset of pain, early presentation, and acute onset have a more favourable prognosis.<sup>3 25 w12</sup> No evidence exists to show that early orthopaedic intervention improves the prognosis for most rotator cuff or glenohumeral disorders. Surgery should be considered when conservative measures fail.

Contributors: CM, AA, and EH conceived the idea for the article. CM reviewed the literature. All authors contributed to writing the article. CM is the guarantor.

Competing interests: None declared.

- 1 Urwin M, Symmons D, Allison T, Brammah T, Busby H, Roxby M, et al. Estimating the burden of musculoskeletal disorders in the community: the comparative prevalence of symptoms at different anatomical sites, and the relation to social deprivation. *Ann Rheum Dis* 1998;57:649-55.
- 2 Winters JC, Sobel JS, Groenier KH, Arendzen JH, Meyboom-de Jong B. The long-term course of shoulder complaints: a prospective study in general practice. *Rheumatology* 1999;38:160-3.
- 3 Van der Windt DA, Koes BW, Boeke AJ, Deville W, De Jong BA, Bouter LM. Shoulder disorders in general practice: prognostic indicators of outcome. *Br J Gen Pract* 1996;46:519-23.
- 4 Dinnes J, Loveman E, McIntyre L, Waugh N. The effectiveness of diagnostic tests for assessment of shoulder pain due to soft tissue disorders: a systematic review. *Health Technol Assess* 2003;7(29):iii, 1-166.
- 5 Ejnisman B, Andreoli CV, Soares BG, Fallopa F, Peccin MS, Abdalla RJ, et al. Interventions for tears of the rotator cuff in adults. *Cochrane Database Syst Rev* 2003;(4):CD002758.
- 6 Green S, Buchbinder R, Glazier R, Forbes A. Interventions for shoulder pain. *Cochrane Database Syst Rev* 1999;(2):CD001156.

- 7 Green S, Buchbinder R, Hetrick S. Physiotherapy interventions for shoulder pain. *Cochrane Database Syst Rev* 2003;(2):CD004258.
- 8 Green S, Buchbinder R, Hetrick S. Acupuncture for shoulder pain. *Cochrane Database Syst Rev* 2005;(2):CD005319.
- 9 Karjalainen K, Malmivaara A, van Tulder M, Roine R, Jauhiainen M, Hurri H, et al. Multidisciplinary biopsychosocial rehabilitation for neck and shoulder pain amongst working age adults. *Cochrane Database Syst Rev* 2001(3):CD002193.
- 10 Buchbinder R, Green S, Youd JM. Corticosteroid injections for shoulder pain. *Cochrane Database Syst Rev* 2003(1):CD004016.
- 11 Speed C, Hazleman B. Shoulder pain. *Clin Evid* 2004;(12):1735-54.
- 12 Hay EM, Thomas E, Paterson SM, Dziedzic K, Croft PR. A pragmatic randomised controlled trial of local corticosteroid injection and physiotherapy for the treatment of new episodes of unilateral shoulder pain in primary care. *Ann Rheum Dis* 2003;62:394-9.
- 13 Ostor AJ, Richards CA, Prevost AT, Speed CA, Hazleman BL. Diagnosis and relation to general health of shoulder disorders presenting to primary care. *Rheumatology* 2005;44:800-5.
- 14 Calis M, Akgun K, Birtane M, Karacan I, Calis H, Tuzun F. Diagnostic values of clinical diagnostic tests in subacromial impingement syndrome. *Ann Rheum Dis* 2000;59:44-7.
- 15 Sher JS, Uribe JW, Posada A, Murphy BJ, Zlatkin MB. Abnormal findings on magnetic resonance images of asymptomatic shoulders. *J Bone Joint Surg Am* 1995;77:10-5.
- 16 Miniaci A, Mascia AT, Salonen DC, Becker EJ. Magnetic resonance imaging of the shoulder in asymptomatic professional pitchers. *Am J Sports Med* 2002;30:66-73.
- 17 Milgrom C, Schaffler M, Gilbert S, van Holsbeeck M. Rotator-cuff changes in asymptomatic adults: the effect of age, hand dominance and gender. *J Bone Joint Surg Br* 1995;77:296-8.
- 18 Daigneault J, Cooney LM Jr. Shoulder pain in older people. *J Am Geriatr Soc* 1998;46:1144-51.
- 19 Green S, Buchbinder R, Glazier R, Forbes A. Systematic review of randomised controlled trials of interventions for painful shoulder: selection criteria, outcome assessment, and efficacy. *BMJ* 1998;316:354-60.
- 20 Carette S, Moffet H, Tardif J, Bessette L, Morin F, Fremont P, et al. Intra-articular corticosteroids, supervised physiotherapy, or a combination of the two in the treatment of adhesive capsulitis of the shoulder: a placebo-controlled trial. *Arthritis Rheum* 2003;48:829-38.
- 21 Alasaarela E, Takalo R, Tervonen O, Hakala M, Suramo I. Sonography and MRI in the evaluation of painful arthritic shoulder. *Br J Rheumatol* 1997;36:996-1000.
- 22 Ostor AJ, Richards CA, Prevost AT, Hazleman BL, Speed CA. Interrater reproducibility of clinical tests for rotator cuff lesions. *Ann Rheum Dis* 2004;63:1288-92.
- 23 Chamberlain AF, Carr AJ. The role of surgery in frozen shoulder. *J Bone Joint Surg Br* 2003;85:789-95.
- 24 Haahr JP, Ostergaard S, Dalsgaard J, Norup K, Frost P, Lausen S, et al. Exercise versus arthroscopic decompression in patients with subacromial impingement: a randomised, controlled study in 90 cases with a one year follow up. *Ann Rheum Dis* 2005;64:760-4.
- 25 Thomas E, van der Windt DA, Hay EM, Smidt N, Dziedzic K, Bouter LM, et al. Two pragmatic trials of treatment for shoulder disorders in primary care: generalisability, course, and prognostic indicators. *Ann Rheum Dis* 2005;64:1056-61.

(Accepted 22 September 2005)

## A memorable patient

### Dukes's patient

The computerised patient record is now accepted as a more efficient way of recording and recalling general practice activity than a mass of notes crammed into a Lloyd George packet. But even the most sophisticated archiving and retrieval system could not generate the thrill of discovering a historic document in a patient's notes.

In the late 1970s one of my elderly woman patients, whom I was visiting, casually asked if I could prescribe a roll of cotton wool for her. She had never made such a request before, and from my memory of her medical record I could think of no reason why she should need cotton wool. She then remarked that she had not mentioned it to me before, but she needed it to cover her colostomy. This was the first I had heard about her colostomy, or even about major abdominal surgery, so I unpacked her notes and letters as she told the story.

She had lived all her life in the same rural market town, and in 1944 my predecessor had diagnosed a rectal carcinoma. In those days, the county hospitals had one general surgeon and a few GP surgeons helping out and would have been unable to cope with such a tumour. Her general practitioner had written in the notes

"Referred to Harley Street, London." It must have been hard for her to leave rural Gloucestershire and travel to war-torn London and face a major operation.

She underwent a procto-sigmoidectomy with formation of a colostomy, which she then proceeded to learn to empty when she was ready to deal with the outcome—but, as a precaution, she strapped a bundle of cotton wool over the stoma. She had coped with this for 30 years without colostomy bags, specialist clinics, or nursing advice.

There was a letter from the surgeon informing her general practitioner that this operation had been performed, and that the specimen had been sent to the laboratory of Dr Dukes in Wimpole Street. To my delight, there was also a letter from Dr Dukes stating in his own handwriting that in his opinion this was indeed a carcinoma of the rectum "which I would define under my class C classification."

The patient died without any suggestion of a recurrence in her early 90s.

Andrew Crowther *general practitioner, Tewkesbury*