

CASE REPORT

A Chicken bone in the rectum

D. H. DAVIES

Department of Accident and Emergency Medicine, Royal Infirmary, Cardiff, United Kingdom

SUMMARY

A case of an ingested chicken bone lodging in the anal canal is described which presented as severe rectal pain. Certain people are at increased risk of foreign body ingestion, in particular denture wearers. The foreign body is usually obvious and easily removed and although the risks of perforation are not high it is important to exclude it by proctosigmoidoscopy following removal of the foreign body.

CASE REPORT

A 31-year-old Caucasian male presented to the A&E Department of the Cardiff Royal Infirmary with a 9 h history of severe rectal pain. The pain had been of sudden onset while the subject was attempting to pass a stool.

On examination he was in obvious distress, being unable to sit without experiencing excruciating rectal pain. Abdominal examination was unremarkable but per rectum he was found to have a hard, sharp object lodged horizontally just above the anal margin.

A plain abdominal X-ray (Fig. 1) confirmed the presence of a foreign body and after the subject had been sedated with intravenous Midazolam, a 4 cm long bone fragment was digitally removed (Fig. 2). Proctosigmoidoscopy showed no evidence of a perforation and the subject was allowed home when he had fully recovered from the Midazolam.

On further questioning he recalled eating chicken 48 h prior to the onset of the pain. He denied being under the influence of alcohol at the time but had a habit of not chewing food thoroughly.

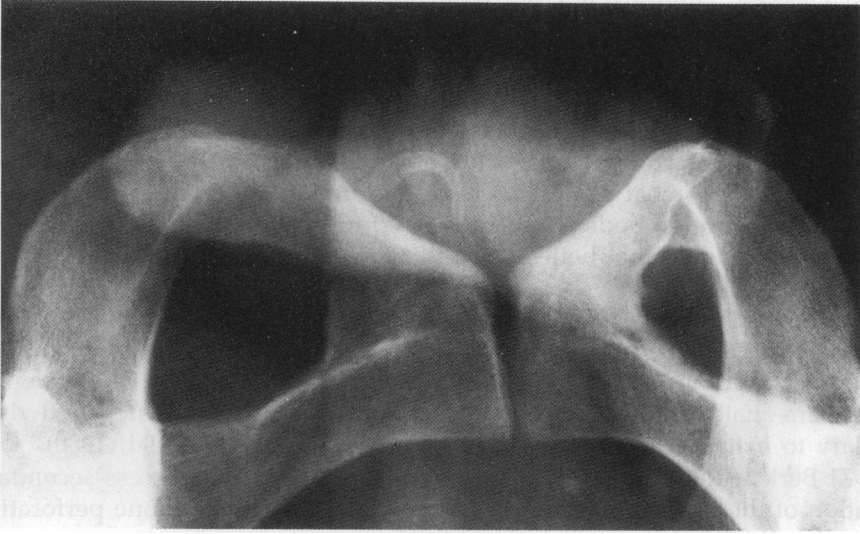


Fig. 1 Plain abdominal radiograph of patient.



Fig. 2 4 cm bone fragment.

COMMENT

Reviewing the literature it becomes apparent that most foreign bodies in the rectum are inserted via the anal canal, but occasionally some objects become arrested in the ano-rectal region following ingestion, most commonly animal bones associated with ingestion of food.

Persons at increased risk of foreign body ingestion include those with dementia,

denture wearers, children and the mentally impaired. Up to 80% of accidental foreign body ingestion occurs in individuals with dentures (Hacker & Cattau, 1986) apparently due to loss of tactile sensitivity of the palatal surface.

Although 10–20% of ingested foreign bodies fail to pass through the entire gastro-intestinal tract, less than 1% cause perforation (McPherson *et al.*, 1957). Once past the stomach, potential sites of impediment include the pylorus, the ileocaecal valve (the most common site of perforation), and the anus.

The common foreign bodies that cause perforation are toothpicks, pins, wires, wood splinters and animal bones, the latter being responsible for 46% of perforation (McManus, 1941).

When the foreign body lodges in the anal canal, the patient gets severe anal pain suggesting a fissure-in-ano but if the foreign body is higher then the pain is much less marked and the patient may go on to develop sepsis. The patient may have a para-anal abscess and not infrequently urinary frequency and dysuria secondary to irritation of the prostate and bladder base (Schofield, 1980).

In 1971 Berk & Reit reported two cases of intra-abdominal abscess secondary to perforation of the gastro-intestinal tract by chicken bones, one bone perforating at the site of a diverticulum in the sigmoid colon.

Moreira *et al.*, in 1975, reported an ingested chicken bone lodged in the lateral rectal wall causing an extensive peri-rectal abscess extending to the scrotum and anterior abdominal wall. The patient recalled chewing chicken bones one week prior to admission.

Once a foreign body has reached the stomach it has an 80–90% chance of traversing the gut without problems, usually in 7 to 10 days. When a foreign body becomes arrested in the anorectal area it is usually obvious and easily removed, and although perforation is rare it is important to exclude it by proctosigmoidoscopy.

REFERENCES

- Hacker J. F. & Carrau E. L. (1986) Management of gastro-intestinal foreign bodies. *American Family Physician* **34**, (2) 101–8.
- McPherson R. C. Karlan, M., Williams, R. D. *et al.* (1957) Foreign body perforation of the intestinal tract. *American Journal of Surgery* **94**, 564–8.
- McManus J. E. (1941) Perforation of the intestine by ingested foreign bodies. *American Journal of Surgery* **53**, 393–7.
- Schofield P. F. (1980) Foreign bodies in the rectum: a review. *Journal of the Royal Society of Medicine* **73**, 510–3.
- Berk R. N. & Reit R. J. (1971) Intra-abdominal chicken bone abscess. *Radiology* **101**, 311–3.
- Moreira C. A., Wongpakdee S. & Gennaro A. R. (1975) A foreign body (chicken bone) in the rectum causing extensive perirectal and scrotal abscess. *Diseases of the Colon and Rectum* **18**, (5), 407–9.