

## LETTERS TO THE EDITOR

### Intraosseus needles

Sir,

Pediatric Resuscitation can be difficult with the differences in anatomy and drug dosages, and time spent in obtaining vascular access. Early intubation allows for provision of naloxone, valium, adrenaline and atropine. Fluids and other drugs still require the intravenous route. Intraosseous infusion provides an easy alternative, especially with the latest equipment available.

Intraosseous infusion has been used intermittently for decades. Many early advocates including Drinker (1922), Josefson (1934) and Henning (1945) used the sternum successfully. In the 1940s Tocantins developed the procedure using the tibial bone marrow (1940 a, b; 1941; 1943; 1945). The technique fell into disuse until the late 1970s (Valdes, 1977), and was popularized again in pediatric resuscitation in the mid 1980's (Berg, 1984). It is now a recognized technique taught in both Advanced Cardiac Life Support and Advanced Trauma Life Support courses.

The area commonly used is two fingerbreadths below the tibial tubercle. An aseptic technique is used. After cleansing the skin with iodine, the needle is inserted at an angle between 60° and 90° to the skin, away from the epiphyseal plate, and advanced with a boring motion until a pop is felt and there is decreased resistance. (Fig. 1) The trocar is removed and marrow is aspirated into syringe containing saline. A large syringe with saline is then used to infuse the fluid with gentle pressure, clearing the needle of clots and ensuring vascular access.

Access is demonstrated by lack of resistance to the needle on penetration of the narrow cavity, aspiration of bone marrow, infusion of fluid without significant edema, and the needle staying upright.

Problems occur if the needle fails to penetrate bone, signifying lack of vascular access and increased subcutaneous swelling. Indurated areas at the site of injection are common due to leakage from the narrow cavity around the needle (Ocantins *et al.*, 1945).

Dense bone with a small narrow cavity or containing fat or fibrotic tissue can result in inability to aspirate marrow.

In 1949 Meola reported one serious complication out of 326 infusions. Ischemic necrosis of two toes occurred, possibly due to strapping being too tight at the ankle or knee or an arterial thrombus.

Osteomyelitis occurs in about 0.6% of cases. This has been more common with hypertonic or strongly alkaline substances, suggesting these substances should be diluted.

A number of studies report a failure rate for each try between 0 and 18% (Rosetti *et al.*, 1985).

Finally, *in vitro* studies show a flow rate under pressure up to 264ml/min.

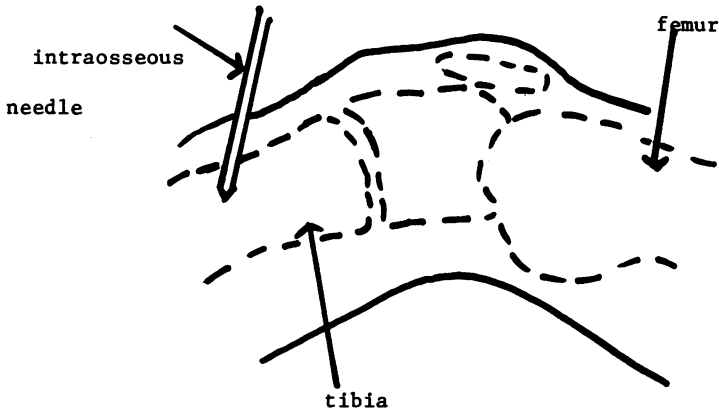


Fig. 1. Technique for intraosseous infusion.

*In vivo* studies however show a rate under pressure up to 29 ml/min only (Hodge *et al.*, 1987; Shoor *et al.*, 1979). Thus, the technique serves as an adjunct in shock management until other vascular access is available.

Various types of sizes of needles have been used, including spinal needles and bone marrow biopsy needles. Spinal needles are readily available from lumbal puncture trays, either 18- or 20- gauge. They are useful because the trocar prevents obstruction as the needle enters the bony cortex. Bone marrow biopsy needles from 12- to 18- gauge also allow for easy penetration of the bone.

One of the more popular needles used recently has been the Disposable Intraosseous Infusion Needle (Cook Inc., Bloomington, IN). This includes a needle of varying gauge (14, 16 or 18 gauge), length and trocar tip. The tip can be pencil point, 35° angle or 45° angle. The needle also has a positioning mark indicating probable depth placement required for ideal fluid flow into the bone marrow cavity. (Fig. 2) Finally, the trocar includes a handle used to provide increasing pressure to push the needle into the bone. Once this has occurred, the trocar is unscrewed and the syringe is attached to the needle, as described above.

Intraosseous infusion is a safe and rapid technique to gain access in children under 3-years old. It is useful in cases of trauma, cardiac arrest or where there is a delay in obtaining other vascular access.

#### ACKNOWLEDGEMENTS

I would like to thank Bruce Rowat, M D and Susan Hanafy for assistance in preparing this communication.




Fig. 2. Disposable Intraosseous Needles (Photographs courtesy of Cook Critical Care Inc.).

Dr C.M.B. FERNANDES  
Department of Emergency Medicine  
The Toronto Hospital  
Toronto, Canada

## REFERENCES

- American Heart Association (1987) *Textbook of Advanced Cardiac Life Support: Instructor Manual*, 263.
- Berg R. A. (1984) Emergency Infusion of Catecholamines into Bone Marrow. *American Journal of Cardiology* **138**, 810-1.
- Committee on Trauma, American College of Surgeons (1989) *Advanced Trauma Life Support Course: Instructor Manual*. ACS pp. 222-223.
- Drinker D. K., Drinker K. R. & Lund CC (1922). The circulation in the mammalian bone marrow. *American Journal of Physiology* **62**, 1-92.
- Henning N. (1945) Intrastemal injections and transfusions *Journal of the American Medical Association* **128**, 240.

- Hodge D., Delgado-Paredes C. & Fleisher G. (1987) Intraosseous infusion Flow Rates in Hypodermic 'Pediatric' Dogs. *Annals of Emergency Medicine* **16**, 305–7.
- Josefson A. (1934) A new method of treatment— intraossal injections. *Acta Medica Scandinavica* **81**, 550–564.
- Meola F. (1949) Bone marrow infusions as a routine procedure in children. *Journal of Paediatrics* **25**, 13–6.
- Rosetti V. A., Thompson B. M., Miller S., Mateer J. A. & Aprahamian C. (1985) Intraosseous Infusion: An Alternative Route of Pediatric Intravascular Access. *Annals of Emergency Medicine* **14**, 885–8.
- Shoor P. M., Berryhill R. E. & Benumof J. L. (1979) Intraosseous Infusion: Pressure- flow relationship and Pharmacokinetics. *Journal of Trauma* **19**, 772–4.
- Tocantins L. M. (1940) Rapid absorption of substances injected into the bone marrow. *Proceedings of the Society of Experimental and Biological Medicine* **45**, 292–6.
- Tocantins L. M. & O'Neill J. F. (1940) Infusion of Blood and other fluids into the circulation via the bone marrow. *Proceedings of the Society of Experimental and Biological Medicine* **45**, 282–3.
- Tocantins L. M., O'Neill J. F. & Jones H. W. (1941) Infusions of Blood and other fluids via the bone marrow. Application in pediatrics. *Journal of the American Medical Association* **17**, 1229–34.
- Tocantins L. M., Price A. H. & O'Neill J. F. (1943) Infusions via the bone marrow in children. *Pennsylvania Medical Journal* **46**, 1267–73.
- Tocantins L. M. & O'Neill J. F. (1945) Complications of intraosseous therapy. *Annals of Surgery* **122**, 266–77.
- Valdes M. M. (1977) Intraosseous fluid administration in emergencies. *Lancet* **ii**, 1235–6.

### The hanging head method for the treatment of acute wry neck

Sir,

I read the above letter to The Editor (*Archives of Emergency Medicine*, 7, p. 125) with interest. The method described by Mr Banerjee involves the use of an assistant who 'supports the pelvis to prevent the patient from sliding down', he also concedes that supplementary manual traction to the head and neck may need to be applied, although not usually necessary. The standard method of manual traction with the patient lying flat on a couch and the operator sitting at the head end of the patient applying gentle but continuous traction for 5 to 10 min, for a selected group of patients, is effective and does not require the help of an assistant. As we need to maximize the use of staff in the Accident and Emergency Department, any method of treatment which requires the assistance of additional staff may be interesting but probably not an efficient use of resources.

On critical analysis therefore the hanging head method may not have a very useful place for the treatment of acute wry neck.

A. K. MAITRA  
 Consultant in Charge  
 Accident and Emergency Department  
 The Royal Victoria Infirmary  
 Newcastle upon Tyne