

## CASE REPORT

### Bee sting brachial block

S. M. HAY\*, F. A. HAY<sup>†</sup> & D. H. AUSTWICK<sup>‡</sup>

*\*Department of Orthopaedics, King Edward VII Hospital, Sheffield, †Department of Accident and Emergency Medicine, Sheffield Children's Hospital and ‡Consultant Orthopaedic Surgeon, Luton and Dunstable Hospital, Luton*

#### SUMMARY

A case of brachial plexus block is presented, following a bee sting in the posterior triangle of the neck. The onset of neurological symptoms was rapid as was their subsequent resolution. Delayed peripheral neurological symptoms believed to have an immunological basis have been reported in response to stings from bees and other Hymenoptera both in the central and peripheral nervous systems (Goldstein *et al.*, 1960; Means *et al.*, 1973; Bachman *et al.*, 1982; Weatherall *et al.*, 1987; Van Antwerpen *et al.*, 1988), but to the authors' knowledge no similar case of immediate peripheral block has been reported.

#### CASE REPORT

A 26-year-old builder's labourer presented to the A&E Department of the Luton and Dunstable Hospital having been stung approximately 30 min previously by a bee in the posterior triangle of the right side of the neck. He complained of weakness and tingling sensations in the right upper limb but no other neurological symptoms. He was otherwise fit and well.

On examination there was an obvious weal with a central punctum situated approximately 1.5 cm posteromedial to the midpoint of the right clavicle. Altered sensation ranging from paraesthesiae to complete numbness in both light touch and pinprick modalities was noted. Weakness was also noted from MRC grade 0 to 4 in various muscle groups of the same limb. Reflexes were present but reduced compared to the left side. Altered neurology was strictly limited to the right upper limb. There was no vascular deficit.

Empirically he was given 100 mg hydrocortisone and 10 mg of chlorpheniramine

intravenously. Approximately 30 min after presentation the neurological deficit had completely resolved.

## DISCUSSION

Bee and wasp stings are common presenting problems to British A&E departments in summer and autumn, with effects generally ranging from local inflammation to full blown anaphylaxis and death. (Sixty-one deaths due to anaphylaxis secondary to insect stings are reported in England and Wales between 1959 and 1972. It is accepted however that this may be an underestimate as deaths caused by anaphylaxis may be attributed to secondary phenomena such as myocardial infarction [Weatherall *et al.*, 1987].)

Neurological sequelae, however, are considerably less common and, where previously reported, are of a delayed nature and believed to have an autoimmune or allergic basis (Goldstein *et al.*, 1960; Means *et al.*, 1973; Bachman *et al.*, 1982; Weatherall *et al.*, 1987; Van Antwerpen *et al.*, 1988). Guillain-Barre syndrome, neuralgic amyotrophy and optic neuritis have all been described in association with bee stings, although the exact mechanisms of action are unclear.

Honeybee (*Apis mellifera*) venom consists of a cocktail of pharmacologically active components (Habermann, 1972; Hider, 1988) including a range of small protein and peptide toxins, see Table 1. Apamin and Mast Cell Degranulating Peptide

**Table 1.** Components of Honeybee venom. Table reproduced courtesy of Dr R. Hider

Molecule type	Component	% venom
Proteins	Hyaluronidase	1-3
	Phospholipase A2	10-12
Peptides	Melittin	50
	Secapin	0.5-2.0
	MCD peptide	1-2
	Tertiapin	0.1
	Apamin	1-3
	Procamine	1-2
	Small peptides (less than 5 a.a)	13-15
	Physiologically active amines	Histamine
	Dopamine	0.2-1.0
	Noradrenaline	0.1-0.5
	a-aminobutyric acid	0.5
Sugars	Glucose	
	Fructose	2
Phospholipids		5
a-amino acids		1
Volatile compounds (pheromones)		4-8

(MCDP), both of a similar structure are known to be neurotoxic in mammals. Apamin is an 18-amino acid peptide. In binding to a specific receptor on some post-synaptic membranes in both the central and peripheral nervous systems, it can block the propagation of certain action potentials, by its inhibitory effect on calcium-dependent potassium channels. It is described as particularly affecting those pathways associated with repetitive activities (Hider, 1988). In addition to its main effect on mast cells, MCDP is believed to have a similar neurological action to apamin (Ziai *et al.*, 1990).

The authors can only surmise that a peripheral neurotoxic effect is demonstrated in this case, and this is supported by the fact that the surface anatomical site for supraclavicular brachial plexus block is the site of entry of the sting in this instance (see Fig. 1).

#### ACKNOWLEDGEMENTS

We gratefully acknowledge the permission granted by Dr R. Hider to use Table 1 entitled 'The components of Honeybee venom', and that granted by Oxford University Press to print Fig. 1.

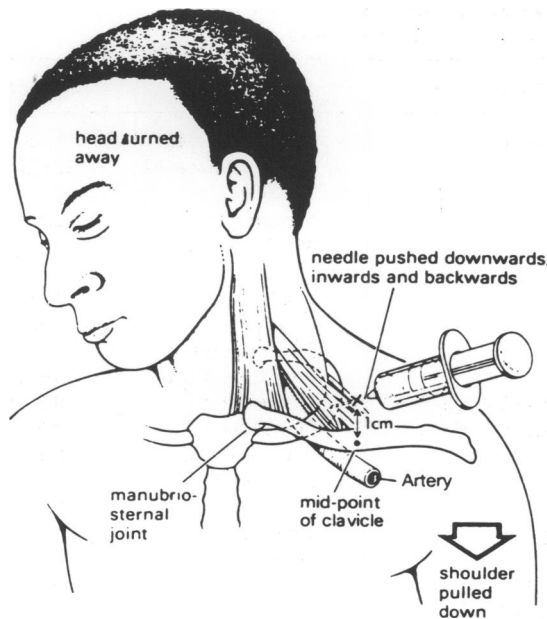


Fig. 1 The supraclavicular brachial plexus block (reproduced by kind permission of Oxford University Press).

## REFERENCES

- Bachman D. S., Paulson G. W. & Mendell J. R. (1982) Acute inflammatory polyradiculoneuropathy following Hymenoptera stings. *Journal of the American Medical Association* **247**(10), 1443–1445.
- Goldstein N. P., Rucker C. W. & Woltman H. W. (1960) Neuritis occurring after insect stings. *Journal of the American Medical Association* **173**, 1727–1730.
- Habermann E. (1972) Bee and wasp venoms. *Science* **177**, 315–321.
- Hider R. C. (1988) Honeybee venom: A rich source of pharmacologically active peptides. *Endeavour* **12**(2), 60–65.
- Means E. D., Barron K. D. & Van Dyne B. J. (1973) Nervous system lesions after sting by yellow jacket. *Neurology* **23**, 881–890.
- Van Antwerpen C. L., Gospe S.M. & Wade N. A. (1988) Myeloradiculopathy associated with wasp sting. *Pediatric Neurology* **4**(6), 379–380.
- Weatherall D. J., Ledingham J. G. G. & Warrell D. A. (1987) (Eds) *Oxford Textbook of Medicine*, second edition, vol. 1, pp. 6.80–6.81, Oxford University Press, Oxford.
- Ziai M. R., Russek S., Wang H. C., Beer B. & Blume A. J. (1990) Mast cell degranulating peptide: a multi-functional neurotoxin. *Journal of Pharmacy and Pharmacology* **42**(7), 457–460.