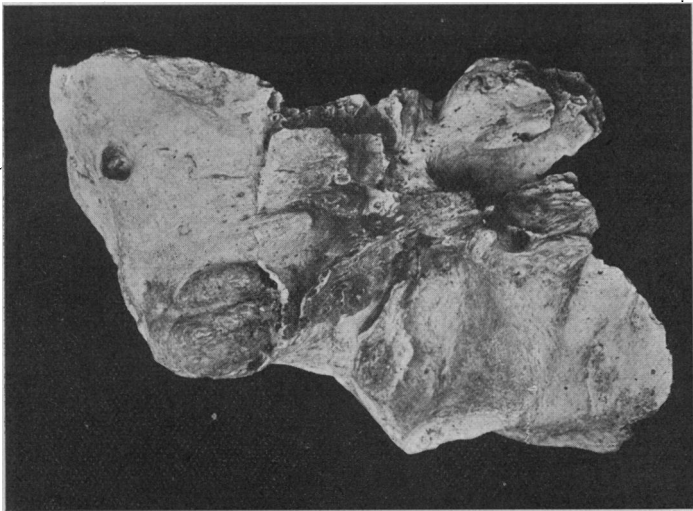


SOME PECULIAR FEATURES IN A TEMPORAL BONE.

By P. P. LAIDLAW, *St John's College, Cambridge.*

A TEMPORAL bone presenting several unusual characteristics has been found in the collection of Egyptian bones in Cambridge University Museum.

The bone is of Egyptian origin in a good state of preservation, and has small portions of the sphenoid and occipital synostosed with it but the rest of the skull is lost. The part of the sphenoid in question includes the spine and foramen spinosum,



View of specimen from below.—(i) Absence of stylo-mastoid foramen, large size of mastoid foramen. Styloid and zygomatic processes are broken. Note the shallowness of the digastric groove.

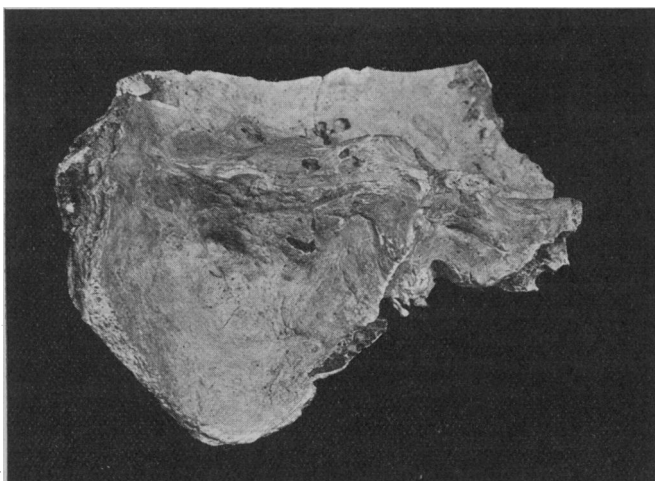
while the occipital portion, though larger, presents no feature worthy of notice: its extent and shape may be seen in the accompanying drawing. It belongs to the left side.

The peculiar features are:—

- (1) Absence of the internal auditory meatus and of the stylo-mastoid foramen.
- (2) Absence of the jugular fossa, and partial absence of the

lateral sinus-groove in the interior, with presence of a large mastoid foramen.

On the posterior intracranial face of the petrous bone the internal auditory meatus is absent, a minute hole being observable in the place where the large canal usually opens. This, on probing with a bristle, seemed to be occluded, and might be due to imperfect preservation of the inner table, as there are one or two other such imperfections in other parts, a rather more prominent set of holes being found on the surface of the *tegmen tympani*. Correlated with the absence of the internal



View of specimen from behind and above.

meatus is the absence of a stylo-mastoid foramen, and I was unable to find any foramen in the vicinity through which the facial nerve could have made its exit from the skull. As far as I know, absence of the internal meatus has not been met with hitherto.

The second peculiar feature is that the groove for the lateral sinus ends at the mastoid foramen, all the blood being evidently drained by this canal. The sigmoid groove of the lateral sinus is somewhat smaller than usual, and the foramen larger than normal. The superior petrosal sinus-groove is present in its normal form, but the inferior is absent.

One would expect that the absence of any internal auditory meatus, and therefore presumably absence of the VIII. and VII. nerves, would have so affected the development of the internal ear as to render it obviously imperfect. Such, however, is not the case in this instance, as the bony parts were well developed and, compared with a European bone taken at random, of large size.

Thus, such points as hiatus Fallopii, canal of Eustachian tube, and tensor tympani were apparently the same as usual, while the aqueductus cochleæ and aqueductus vestibuli were both easily identified.

Also such points as the *fenestræ rotunda et ovalis* of the internal wall of the tympanum could be identified by reflecting light down the external auditory meatus. In short, it otherwise presented perfectly normal features.

I append some measurements to compare with an ordinary well-developed temporal bone.

	Egyptian bone.	European.
From the tip of petrous bone to internal surface of skull-wall along the line of the superior petrosal sinus,	61 mm.	60 mm.
From the same point in the interior of the skull to the apex of the angle occupied by the spine of the sphenoid,	49 mm.	46 mm.
From the apex of angle in last measurement to the tip of the petrous bone,	26 mm.	25 mm.

These give an anterior triangle, which expresses to a certain extent the development of the petrous bone and internal ear.

	Egyptian bone.	European.
From tip of petrous bone to the angle occupied by the jugular process of the occipital,	30 mm.	34 mm.
From internal surface of skull to where superior petrosal sinus meets it,	46 mm.	35 mm.

Lastly, the vertical depth from the surface of the eminence of the superior semicircular canal to the base of the styloid process was 23 mm. in the Egyptian and 25 mm. in the European.

These figures do not indicate any imperfect development of the Egyptian specimen.

The specimen, on being sawn open, was seen to present a completely developed bony labyrinth, as all parts were present

as far as could be seen—vestibule, semicircular canals, and cochlea.

The cribriform area at the fovea hemispherica was easily made out with the aid of a lens. The small aperture mentioned above, which existed in the place of the internal auditory meatus, proved to be a very imperfect aqueduct of Fallopius, which, however, could not be traced far; moreover, the arrangement of the cancelli and lamellæ of the bone occupying the area usually taken up by the meatus showed that the condition could not be regarded as pathological.