

NOTE ON THE PRESENCE OF CILIATED CELLS IN THE  
HUMAN ADULT KIDNEY. By E. WACE CARLIER, M.D.,  
B.Sc., *Professor of Physiology in the Mason College, Bir-*  
*mingham.*

THAT the cells lining the convoluted tubules bear cilia in most mammals has been recognised for a considerable time by continental writers, and has been recently reinvestigated by me. My results will be found published in *The Veterinarian*, vol. lxxii. p. 466. In that paper I pointed out the occurrence of ciliated cells throughout the convoluted and spiral tubules of the kidney in most of the domestic animals.

Quite recently I was fortunate enough to obtain a perfectly healthy adult human kidney from the post-mortem room of the Edinburgh Royal Infirmary, and am now in a position to state that the human kidney forms no exception to the rule that obtains in the case of the lower mammals.

Cilia have indeed been observed in the human adult kidney by Lebedeff (1), Marchand (2), Langhans (3), Werner (4), and Oértel (5), who studied the organ from a pathological point of view, and all of them consider the ciliated appearance to be due to some pathological change, and not at all referable to the normal condition.

*Method.*—The kidney, which was quite fresh when obtained, was cut into small pieces and placed in Müller's fluid and spirit to harden. This fluid is unfortunately not a very good fixative, as the tissues tend, if not very carefully handled, to shrink somewhat in the subsequent process of embedding in paraffin.

Sections of the thickness of  $4\ \mu$  were cut on the Cambridge rocking microtome, fixed to albumin-coated slides after spreading on water, and on removal of the paraffin with xylol and alcohol were stained in Heidenhain's iron-alum hæmatoxylin (long method), or in hæmatoxylin, rubin, and orange, or in methyl-blue eosine mixture, Mann's formula. They were examined with the aid of a Leitz  $\frac{1}{2}$  oil immersion objective

and No. 3 eyepiece, and the drawings and measurements made with the aid of Zeiss' camera lucida and eyepiece screw micrometer respectively.

In these specimens, which are quite normal, there can be no doubt whatever of the presence of cilia projecting from the free surface of all the cells lining the convoluted tubules, both proximal and distal, and the spiral tubule throughout their entire length, but no cilia are present within the capsule of Bowman, though they do occur in this situation also in some of the smaller mammals.

*Convoluted tubules.*—Cell outlines, quite indistinguishable latterly, and cells all of the same height, cytoplasm rodded vertically as described by Heidenhain, but the rods consist of granules arranged in vertical rows and united together by fine threads; the rods have therefore a beaded appearance. The

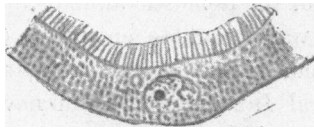


FIG. 1.—Convoluted Tubule, Human.

cilia are planted upon very small basal pieces, and do not appear to be prolonged into the cytoplasm; no connection could be made out between them and Heidenhain's rods. The cilia, including the basal pieces, measure  $3\ \mu$  in length. They

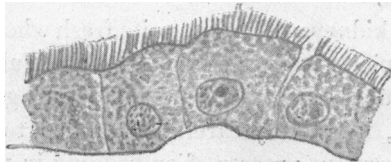


FIG. 2.—Spiral Tubule, Human.

are broad for their length, and not very closely packed together. They are all of the same length and thickness quite round the tubule. The nucleus is situated about midway between the basal pieces and the basement membrane.

*Spiral tubule.*—As in most mammals the cells lining the spiral

tubule are dome-shaped and of comparatively large size; their lateral outlines are well marked, as can be seen in the figure, but Heidenhain's rods are absent, the cytoplasmic granules being quite irregularly arranged throughout the cell, though joined together by fine threads. The cilia, including the thin basal pieces, measure  $3.1 \mu$  in length. The nuclei are situated close to the basement membrane.

The human kidney, therefore, comes in the series alongside that of the mouse, as far as regards the length of the cilia, and, as in the mouse, the cilia do not differ appreciably in length in the convoluted and spiral tubules.

---

#### REFERENCES.

- (1) LEBEDOFF, *Virchow's Archiv*, Bd. 91, 1883, p. 267.
- (2) MARCHAND, *Tageblatt der Versammlung der Naturforscher in Strasburg*, 1885, p. 422.
- (3) LANGHANS, *Virchow's Archiv*, Bd. 99, 1885, p. 227.
- (4) WERNER, *Archiv f. experimentelle Pathologie und Pharmakologie*, Bd. 31, 1887.
- (5) OÉRTEL, *Archiv f. Mikro. Anat.*, Bd. xxix, p. 525.