

# JOURNAL OF ANATOMY AND PHYSIOLOGY

THE TOPOGRAPHY AND MORPHOLOGY OF THE HUMAN HYOID BONE. By F. G. PARSONS, F.R.C.S., *Lecturer on Anatomy at St Thomas's Hospital and the London School of Medicine for Women.*<sup>1</sup>

A CAREFUL revision of a large number of specimens of any part of the body often brings to light new facts and suggests new theories.

I think, however, that its most valuable result is that, if it is conducted patiently enough, it enables us to build up the normal form of the part. Even if this tallies in every way with existing descriptions, it is of value; while, if it differs, it should be accepted, unless the existing descriptions have been founded on a detailed examination of a larger number of specimens.

The following paper is the result of the examination of 108 hyoid bones in St Thomas's Medical School. Fifty-three of these were from males over 20; 28 from females over 20; while 27 were from children under 20.

## THE BODY (BASIHyal).

This has superior, inferior, and two lateral borders, and anterior and posterior surfaces. The superior border is sharp, and usually has a slight notch in the mid-line, on each side of which it is slightly convex upward.

The inferior border is somewhat thicker and rougher, and is situated in a plane from .5 to 1 cm. anterior to that of the upper border. In most cases it is slightly concave downward, so that when the bone is laid on a flat surface it only rests on the lateral parts of the inferior border. It is just here that the sterno- and omo-hyoids are attached, and at these places the border is markedly thickened.

The lateral borders articulate or are synostosed with the great cornua in their upper part; below they slope downward and inward to meet the lower border.

The anterior surface is quadrilateral or, to be more precise, hexagonal, on account of the slope of the lateral borders. The average transverse width of 51 adult male bones is 2.6 cm., and of 28 adult female bones 2.2 cm.

<sup>1</sup> *Proceedings Anatomical Society*, November 1908.

The widest and narrowest male bones were 3.0 cm. and 2.1 cm. respectively, while the widest and narrowest female bones were respectively 2.6 cm. and 1.7 cm.

The average height of the body of the male bones from the superior to the inferior border was 1.2 cm., while that of the female was 1.0 cm. (highest and lowest male bodies, 1.6 and 1.0 cm.; highest and lowest female bodies, 1.2 and .9 cm.). There is often, however, a marked want of symmetry between the two sides of the body. I give these measurements because it will be seen that by using them it is generally possible to tell the sex of a hyoid bone.

The lesser cornua are attached by fibrous tissue to the lateral margins of the anterior surface, 4 or 5 mm. below the upper border, while between

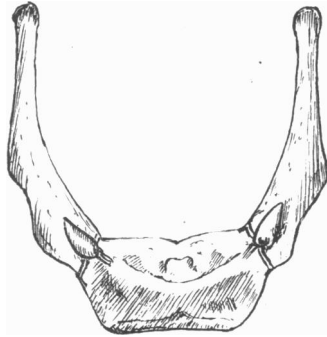


FIG. 1.—Normal male hyoid (actual size) constructed from measurements of 50 specimens.

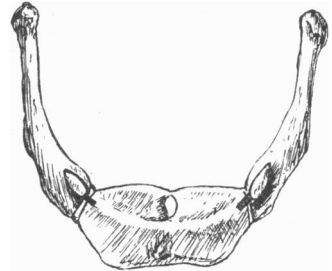


FIG. 2.—Normal female hyoid (actual size) constructed from measurements of 28 specimens.

their attachments a definite bar or ridge of compact bone stretches. This I propose to speak of as the "curved bar," because it has a distinct downward convexity.

It is important to realise that the ends of this bar never failed to be continuous with the lesser cornua where these could be made out. The part of the anterior surface which is above the bar looks upward and forward, while that below looks more directly forward.

Anatomists, as a rule, recognise in this bar nothing more than a border separating these two slightly differently directed surfaces. That it is something more is evidenced by its compact structure as well as by the fact that in 5 out of the 108 specimens a thread could be passed between it and the rest of the hyoid, while in many more cases it was deeply undercut above or below.

In 6 of the 108 specimens two small knobs were found in this bar, one

on each side of the middle line, and from 2 to 5 mm. away from it. They were apparently outgrowths into the genio-hyoid muscles.

Above the curved bar in the middle line is the glosso-hyal or entoglossal process so well marked in reptiles and in the horse among mammals. It is described as an occasional structure in our text-books, and its exact position is not realised. I found it in 72 of my 108 specimens, *i.e.* in nearly three-quarters (adult males,  $\frac{41}{53} = 77$  per cent.; adult females,  $\frac{19}{28} = 68$  per cent.; children under 20,  $\frac{12}{27} = 44$  per cent.). In some of these it was a mere vestige, but in the greater number a knob projecting some 3 mm. beyond the surface of the bone. Occasionally it appeared as a vertical median ridge running up from the curved bar and at right angles to it. This ridge is described in some of our text-books, but it is not realised that it is the glosso-hyal process.

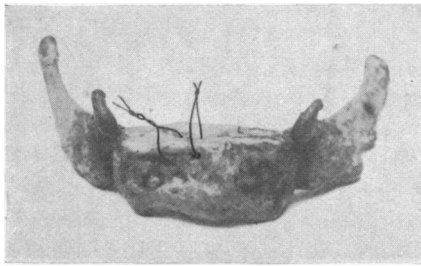


FIG. 3.—Photograph of a hyoid with threads passed through gaps between the curved bar and the rest of the body.

Sometimes the knob forms a little crater which I believe is formed by and contains the remains of the thyro-glossal duct; at all events this is the exact spot to which I traced the duct in one specimen in which it persisted.

Below the curved bar on the anterior surface there is sometimes, though not very often, a median vertical ridge running downward, so that in those comparatively rare cases in which it is present and the glosso-hyal is a ridge running upward from the curved bar, a cruciform pattern is formed. The mylo-hyoid muscle usually forms a slight ridge on the lower part of the anterior surface of the basihyal; it is horizontal except near the middle line, where it turns up a little. In bones of extra depth the mylo-hyoid ridge may be as much as 7 mm. above the lower border, though usually the space is only 2 or 3 mm. The posterior surface of the basihyal is concave in both directions; near the mid-line are usually some vascular foramina the vessels of which pass into the fibro-fatty tissue which separates the hyoid from the epiglottis.

## LESSER CORNUA (CERATOHYALS).

These are small, pyramidal bones, slightly flattened from before backward, with their apices directed upward and outward. Their average length in the adult male is 7 mm., in the female 5 mm., and I found no difference in the average length on the right and left sides in either sex. The longest cornu was 19 mm., but it is quite possible that these very long ones consist of fused ceratohyal and epihyal elements.

In seven cases I found one of the lesser cornua absent, while in four others there was absolutely no sign of either. In dissecting each specimen, I always looked for and isolated the lesser cornua first, so that I do not think that they were accidentally cut away; indeed, in many cases the stylo-hyoid ligament was traced to the body of the bone. The attachment of the lesser cornu to the body is by fibrous tissue which is probably a degraded stage of the cartilage which in the embryo is continuous from the body into the lesser cornu (see fig. 8).

I have never seen a synovial joint between the body and the lesser cornu, though such a joint is quite common between the greater and lesser cornua. When this is the case the great cornu sends up a little process or apophysis from its base against which the lesser plays and ultimately a synovial joint is formed between them. I found such an articulation in 35 out of 77 adult bones on the right side (45 per cent.) and in 34 out of 80 on the left (43 per cent.).

In a few cases the articulation between the great and small cornua becomes synostosed; as a rule this fusion is limited to the cornua, but very rarely the lesser cornu may fuse with the body of the hyoid as well as with the great cornu. I have met with only one instance of the lesser cornu fusing with the body without at the same time fusing with the great cornu.

The right lesser cornu was fused with the greater in 6 out of 77 adult specimens (8 per cent.), and the left in 5 out of 80 (6 per cent.). In three of these cases the fusion was bilateral. In only three did the process extend to the basihyal as well.

When the lesser cornu becomes synostosed with any other part of the hyoid, it occurs in the later years of life and is commoner in males than in females. Of the 8 cases in which fusion was found out of the 108 examined, the youngest was 36 years old and all the rest over 49; while, of these eight, 7 were males and 1 female.

One lesser cornu especially interested me because it showed undoubted signs of being formed by two centres of ossification. Its basal part (2 mm.) was separate from the apical portion on the right side, while on the left there were feebler indications of a double ossification.

It is possible, of course, that the basal part may be the true ceratohyal, while the rest of the cornu represents an epihyal element; but I do not think this is so, because I came across four other specimens in which the lesser cornu was separated from the body of the bone by 2 or 3 mm. of ligament corresponding in position to the basal part of the lesser cornu with two centres.

GREATER CORNUA (THYROHYALS).

These are flattened bars which are attached to the lateral border of the body of the hyoid, and pass backward and a little outward. As they pass back they become narrower until within about 5 mm. of their free end, when they begin to widen once more and end in a knob.

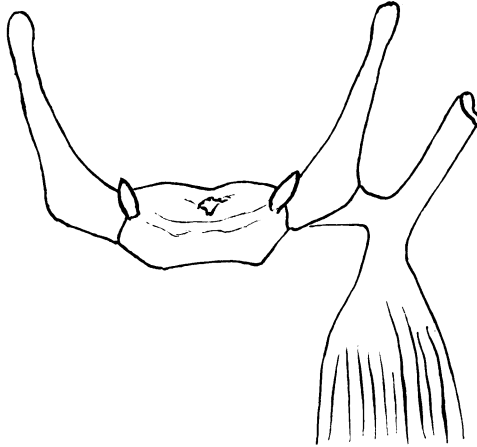


FIG. 4.—The point of attachment of the digastric to the great cornu.

They are sometimes described as being flattened from above down, sometimes from side to side, and in a large collection of bones many examples of each of these arrangements may, no doubt, be found. I have no hesitation in saying, however, that the normal arrangement is that in which the flattening is from above downward, since I found it so in 42 out of 81 adult bones, while in only 5 was there a distinctly side-to-side flattening. In the rest the surfaces were either intermediate in direction (at a slope of about 45 degrees) or else one cornu had this intermediate position while the other was either vertically or laterally flattened. I should therefore describe a superior and inferior surface and an external and internal border to the great cornu. The superior surface in muscular male subjects sometimes has a ridge near the tip for the middle constrictor. The inferior surface is smooth and, as far as I can see, featureless. The

inner border is sharp for the attachment of the thyro-hyoid membrane, while the outer border is usually thicker and rougher since close to it the muscles are attached. Near the basihyal this outer border is always specially thick for the attachment of the strongest part of the thyro-hyoid muscle, while nearer the tip the border is modified for some 5 to 8 mm. by the attachments of the digastric and stylo-hyoid muscles. The upward traction of these muscles leads sometimes to a slight eversion or upturning of the border, and at others to the formation of a slight though usually quite appreciable notch or bay (see figs. 1, 2, 3, and 4).

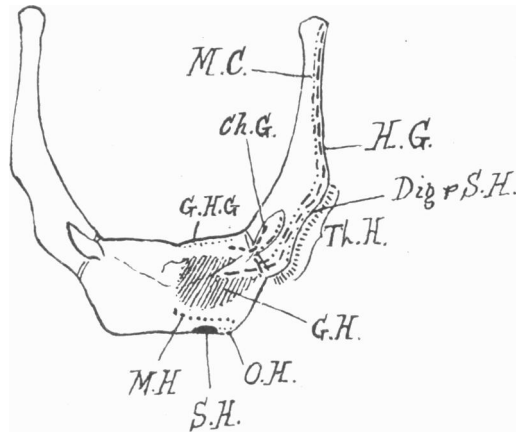


FIG. 5.—Attachment of muscles to the hyoid.

G.H.G., genio-hyo-glossus (by membrane); Ch.G., chondro-glossus; M.C., middle constrictor; G.H., genio-hyoid; H.G., hyo-glossus; M.H., mylo-hyoid; Dig. and S.H., digastric and stylo-hyoid; S.H., sterno-hyoid; O.H., omo-hyoid; Th.H., thyro-hyoid.

The length of the great cornu varies in different adult specimens by as much as 1.5 cm. In 50 males I found it averaged 3.2 cm., the longest being 3.9 and the shortest 2.4 cm. In 28 females the average was 2.8 cm. (longest 3.0, shortest 2.5 cm.).

#### MUSCULAR ATTACHMENTS.

In cleaning the 108 specimens I noticed the muscular attachments, but in order to preserve an exact record I took seven bones and cleaned the left side of each. I then dissected the muscles away from the right side and, as I did so, painted a counterpart of their area of attachment on the left. These seven bones I can now lay before the Society, and it will be evident that the attachment of the muscles is pretty constant and differs only in a few details from the diagrams which are to be found in our more modern text-books.

The *genio-hyo-glossus* is only attached to the upper border of the basihyal, and that not by any muscular fibres but by a very thin membrane. It probably exerts no action at all upon the hyoid bone but only upon the tongue.

The *chondro-glossus* rises from the inner margin of the lesser cornu near its base, and also from the contiguous part of the basihyal in front of the attachment of the *genio-hyo-glossus*. It is a very constant though delicate, cylindrical muscle, which runs deep to the inferior lingualis, by which it is separated from the *hyo-glossus*. It lies close to the mucous

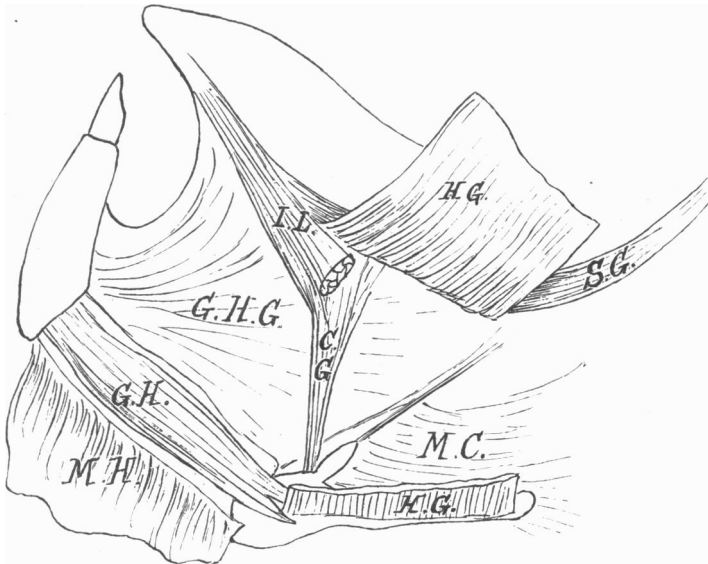


FIG. 6.—Dissection of the side of the tongue to show the relations of the chondro-glossus (C.G.). I.L., inferior lingualis (cut); G.H.G., genio-hyo-glossus (by membrane); C.G., chondro-glossus; M.C., middle constrictor; G.H., genio-hyoid; H.G., hyo-glossus; M.H., mylo-hyoid; S.G., stylo-glossus.

membrane of the pharyngeal surface of the tongue, and when traced into the substance of that organ some of its fibres blend with those of the inferior lingualis, though most of them turn inward toward the middle line (see figs. 5, 6, and 7).

The inferior lingualis is usually described as rising from the hyoid, though I have not met with any account of its exact point of origin. I have never been able to trace it to the bone, and believe that it has been confounded with the chondro-glossus, with which it is slightly connected.

The genio-hyoid is the largest muscular attachment to the hyoid, and is inserted into its own half of the anterior surface of the basihyal both above

and below the curved bar. In the outer part of its area of insertion is a very constant V-shaped notch into which the origin of the inner part of the hyo-glossus fits.

The mylo-hyoid is attached to the transverse ridge which so often can be faintly seen on the front of the basihyal, and which has been described already. The sterno- and omo-hyoid need no special remark.

The middle constrictor rises from the outer border of the lesser cornu, and from thence its origin runs right along the outer border of the great cornu to the very tip. In two cases out of the seven there was a break in its origin of over 1 cm. opposite the middle of the cornu, and in every case the muscle seemed to be attached much more strongly near the base and tip.

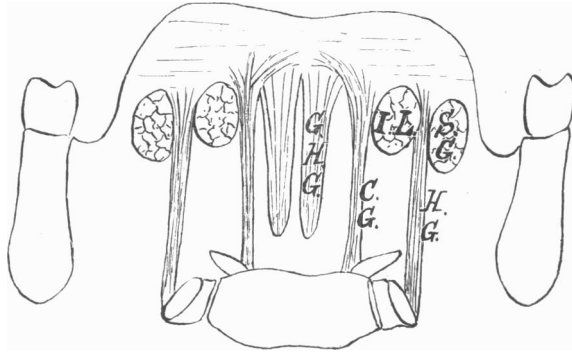


FIG. 7.—Diagrammatic section of the tongue and hyoid bone through the bases of the greater cornua to show the relations of the chondro-glossus (C.G.).

I.L., inferior lingualis (cut); G.H.G., genio-hyo-glossus (by membrane); C.G., chondro-glossus; H.G., hyo-glossus; S.G., stylo-glossus.

The hyo-glossus rises from the lateral part of the anterior surface of the body, where it is embraced by the genio-hyoid, and from the outer border of the great cornu as far as its tip, lying just external to the origin of the middle constrictor. Gaps in its continuity are often seen.

The stylo-hyoid and digastric are inserted into the outer border of the great cornu at a little distance from its base. The digastric is attached not only by a loop of connective tissue but by some of its own tendinous fibres. It has been shown already how this attachment tends to evert or pull up the outer lip.

The thyro-hyoid rises from the outer border of the great cornu on its under surface. It seldom extends for more than the basal half of the cornu, and occasionally just reaches the body. Its attachment is much stronger near the base of the cornu than near the tip.



## AGE-CHANGES IN THE HYOID.

In the cartilaginous model of the hyoid in a child at birth or during the first year the curved bar already referred to is a striking characteristic. At this age it is seen, especially if the cartilage be allowed to dry, that the bar is quite continuous with the cartilages of the lesser cornua, and that its greatest downward convexity reaches to a point below the middle of the body of the hyoid in the middle line.

From the evidence of the numerous specimens which I am able to exhibit at this age, as well as from that of the adult bones, in which the bony curved bar is always continuous with the lesser cornua and sometimes is so distinctly separate from the rest of the body of the hyoid that a thread can be passed between them, I am inclined to think that this curved bar is the second visceral arch, while the rest of the body of the hyoid, with which alone the

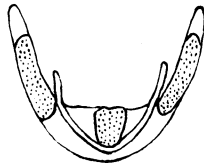


FIG. 8.—Hyoid of child during the first year to show the continuity of the lesser cornua with the curved bar. The ossified part is dotted.

greater cornua articulate, is the third. On referring to the embryology of the tongue, it will be noticed that the tuberculum impar appears between the ventral ends of the right and left halves of the second arch and, as these chondrify toward the mid-line, they have to skirt round the back of (caudad) the tuberculum which forms the middle part of the tongue.

It is quite true that in fishes and amphibians the ventral median part of the hyoid apparatus is formed of distinct chondrifications, forming the copula, with which the visceral arches articulate, so that in these lower forms the arches themselves do not reach the mid-ventral line. There is, however, so far as I know, no reason to believe that the copular apparatus is retained even in the most rudimentary form in the mammals. It seems probable that it is completely suppressed, and that the visceral arches of the two sides meet in the middle line without any intervening structure.

It will furthermore be noticed that this ventral position of the curved bar or second visceral arch, as I believe it to be, to the rest of the basihyal or third arch, is quite in harmony with the telescoping process which is so

noticeable in all the visceral arches, since each arch tends to telescope inside the one above (cephalad) it.

The time of appearance of the ossific centres is uncertain. I have little doubt that the great cornua are usually the first to ossify, since I have a specimen of a child of eight months in which they are bony for 1 cm., although no centre has appeared for the body.

In another specimen from a 2 years old child, the greater cornua are ossified for the same distance, while the body only has a bony deposit the size of a pin's head.

In full-term fetuses I have sometimes found an ossification in the great cornua and sometimes not, but there can be no doubt that, if it is not present at birth, it comes very soon after, because not one of the 27 hyoids of children which I have collected fails to show it, and the youngest of them is from a child of 3 weeks.

The rate of growth of this centre varies immensely; in one child of 5 weeks it was 7 mm. long, while in another of 3 months it was only 5 mm.

The following six hyoids of children in their second year are instructive :—

Months old.	Length of bony thyro-hyal.
12	14 mm.
13	11 "
14	13 "
20	11 "
24	14 "
24	10 "

The average of these lengths is 12 mm., and this, I presume, is about the length to which it generally reaches in the second year.

Some idea of its subsequent growth may be gathered from the following table :—

Sex.	Years old.	Length of bony thyro-hyal.
♂	2½	13 mm.
?	3	15 "
♀	3	16 "
♂	4	10 "
♂	5	16 "
♀	6	17 "
♂	7	15 "
♂	10	20 "
♀	13	20 "
♂	14	21 "
♀	14	21 "
♂	17	33 "

Sex.	Years old.	Length of bony thyro-hyal.
♂	20	30 mm.
♂	21	24 „
♂	21	30 „
♂	23	29 „
♂	26	34 „

It seems, from the foregoing, that the ossification in the great cornu grows about 1 cm. in the first year, another centimetre between the first year and puberty, and a third between puberty and 25 years.

Up to 30 years of age a cartilaginous cap is found at the free end of the cornu, though I have never seen it in older bones.

The great cornu is said to synostose with the body of the bone about middle life. This no doubt is true, but my specimens show that it often does so on one side long before the other. The following table, in which the bones are arranged in decades, gives some idea of the process:—

Age.	No. of specimens.	Cases of unilateral fusion.	Cases of bilateral fusion.
Birth to 20	30	1 (3·3 %)	...
21-30	13	2 (15·4 %)	...
31-40	16	5 (31 %)	2 (12·1 %)
41-50	12	1 (8·3 %)	6 (50 %)
51-60	22	3 (13·6 %)	8 (36·4 %)
61-70	13	2 (15·4 %)	5 (38·5 %)
71 and over	3	...	3 (100 %)

This table shows that unilateral synostosis may occur in the second decade (my youngest specimen of it was 20 years old), and that bilateral synostosis is quite rare until the fifth decade is reached. It is, however, a common thing to meet with people between 60 and 70 in whom the body and great cornua of the hyoid are quite separate, though in the earlier decades (up to about 35) the bony elements are usually separated by a buffer of cartilage 3 to 5 mm. thick which later becomes a mere line.

Of the 14 cases in which only one of the greater cornua was united, the synostosis was on the right in 6 and on the left in 8. There is no reason, therefore, with the statistics at present before us, to believe that one side synostoses earlier than the other.

The centre for the body probably appears just before or after birth, and usually a little later than that for the great cornu. At first it occupies only that part of the body which is above the curved bar, but by the end of the first year it has invaded and passed that point, according to my specimens.

One specimen shows a well-marked glosso-hyal process as early as the fifth week. There is often, too, in these very young specimens a notching of the upper border of the centre, which I am inclined to regard as an indication of a transitory double origin like that of the vertebral centra. The body is completely ossified by 20, the inferior lateral angle on each side being the part which remains cartilaginous longest.

The lesser cornu is generally described in the text-books as ossifying in the second year; but, although I have 27 specimens fairly evenly distributed over the first 17 years, I have not one which shows this bony centre until the fourteenth year is reached. It is then pretty well marked, I fancy more so than usual, because in a girl of 13 it is altogether absent, while in a youth of 17 it is much smaller than in the above-mentioned boy of 14. The junction of the lesser cornu with neighbouring parts has been discussed already.

#### SUMMARY.

The chief points to which I would call attention in this paper are:—

1. The existence of the curved bar on the anterior surface of the body joining the two lesser cornua and apparently corresponding to the basal part of the second visceral arch.
2. That the digastric and stylo-hyoid muscles are attached to the outer border of the great cornu near its base and produce an everted lip or notch which is generally quite evident.
3. That all the muscles attached to the great cornu spring from its outer border.
4. That a rudimentary glosso-hyal process is a normal feature of the hyoid and corresponds to the point at which the thyro-glossal duct reaches the basihyal.
5. That, if paragraphs 1 and 4 are substantiated, the second visceral arch passes altogether ventral to the thyro-glossal duct.
6. That the chondro-glossus is a constant muscle and the inferior lingualis does not rise from the hyoid.
7. That the lesser cornua do not ossify until the fourteenth year.
8. That the lesser cornua never form synovial joints with the body of the hyoid, though they often do so with the greater cornua.
9. That synostosis between the great cornu and body often occurs on one side long before the other.
10. That synostosis between the lesser cornua and body is extremely rare, though more often found between the lesser and greater cornua.
11. That the normal shape and size of male and female hyoids have been established by a series of careful measurements.