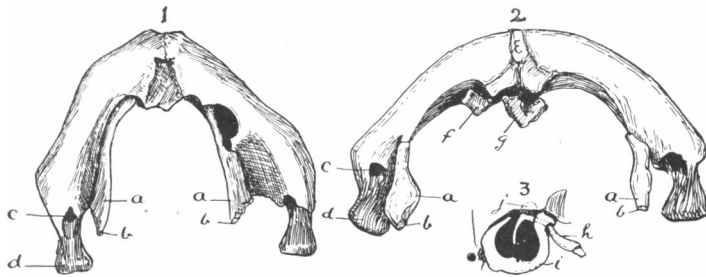


ABNORMAL OSSIFICATION OF MECKEL'S CARTILAGE. By  
 ARTHUR KEITH, M.D., *Conservator of the Museum of the Royal  
 College of Surgeons, England.*

IN 1879 my colleague Mr Shattock described in this Journal (vol. xiv. p. 201) a case in which Meckel's cartilage had undergone ossification between the mandible and the malleus. I have been able to find no record of a similar case; but recently, when investigating two specimens from the museum representing certain malformations of the tongue, I found that



FIGS. 1, 2, 3.—1, Mandible of a deformed fetus viewed from below; 2, mandible of an anencephalic fetus; 3, tympanic bone, malleus, and processus gracilis of Mr Shattock's case

*a*, Meckelian ossicles; *b*, facet for processus gracilis; *c*, dental foramen; *d*, condyle; *e*, os mentale; *f*, *g*, ossicles; *h*, processus gracilis; *i*, tympanic bone; *j*, head of malleus.

Meckel's cartilage was ossified in the manner described by Mr Shattock. His specimen was obtained from a case of achondroplasia; one of mine came from a deformed foetus (fig. 1), and the other from an anencephalic foetus (fig. 2). In fig. 1 the two bars of bone, which I regard as ossifications of Meckel's cartilage, are attached to the symphyseal or incisor part of the mandible on each side and articulate behind with a strong processus gracilis of the malleus (see 3). One margin of the bone is free, its other margin is closely united to the inner side of the mandible by fibrous tissue. In fig. 2 the Meckelian bars are shorter and covered with a closely adherent periosteum—such a periosteum as one finds in bones which are ossified in cartilage. They articulate with the mandible at the posterior end of the mylohyoid ridge, and at the other there is a facet for the process of the malleus. In this specimen there are three ossicles at the symphysis: (*e*)

in the symphysis (os mentale); (*f*) a small ossicle attached to the right half of the mandible near the symphysis; (*g*) a semi-divided bone behind the symphysis, to which it is attached, and also is imbedded in the tissue at the frenum of the tongue. In fig. 3 the processus gracilis of the malleus of Mr Shattock's specimen is figured (No. 730, R.C.S.M.). It is a strong, rounded bar of bone which emerges from the tympanum between the tympanic ring and the spine of the sphenoid to articulate with the Meckelian ossicles.

There is in those specimens a complete ossification of the cartilaginous skeleton of the first visceral arch. Two explanations may be offered: (1) the condition is similar to that seen in the second or hyoid arch—and one may infer that the characters of the one had been transferred to the other in a manner similar to the transference of the characters of the first sacral to the last lumbar segment; (2) the more probable explanation is that Meckel's cartilage has resumed a form it possessed before the temporo-maxillary joint had been evolved. The evidence of these specimens is in favour of those who regard the temporo-maxillary joint as a late acquisition in the evolution of the Vertebrata.