

## Case reports

### **Homozygous familial hypercholesterolaemia with supra-aortic stenosis treated by surgery<sup>1</sup>**

W G Hendry MRCP

Mary Seed BM

Waller Cardiac Department and Metabolic Unit  
St Mary's Hospital, London W2 1NY

We present here a common complication of a rare disorder. Severe aortic stenosis in a young patient with homozygous familial hypercholesterolaemia has been relieved surgically using an aortic root-widening procedure.

#### *Case report*

In 1976, at the age of 6 years, DD presented with a squint. She was noted to have bilateral arcus and was referred to the Metabolic Unit at St Mary's Hospital, when she was found to have an elevated serum cholesterol level of 17 mmol/l and investigation of the other members of the family showed both parents to have heterozygous Type IIa familial hypercholesterolaemia. Homozygous hypercholesterolaemia was diagnosed in the patient and her elder sister. She was asymptomatic, but on examination an ejection systolic murmur was heard and an electrocardiogram showed left ventricular hypertrophy by voltage criteria. She was started on therapy with a low saturated fat diet, fibric acid, nicotinic acid and cholesterol binding resins. She was followed up regularly and on this regimen her plasma cholesterol fell to between 7.8 and 11.6 mmol/l. She remained well, but by 1981 her ECG had developed ST segment and T wave changes of left ventricular strain. In mid-1983, aged 13 years, she started to complain of fatigue and breathlessness on exertion and was referred for cardiological assessment. Physical examination again revealed an ejection systolic murmur, now with an early diastolic murmur and clinical left ventricular enlargement. ECG confirmed left ventricular hypertrophy with strain; chest X-ray showed cardiac enlargement (cardiothoracic ratio 52%). At cardiac catheterization under general anaesthesia, a gradient of 130 mmHg across the aortic valve was found, while angiography showed extreme left ventricular hypertrophy with vigorous systolic contraction. An aortic root angiogram

demonstrated funnelling of the root with partial obliteration of the coronary sinuses (Figure 1) but no lesion of the coronary arteries was seen. Although coronary artery disease was a likely finding, selective angiography was not attempted in view of the hazards of this procedure in the presence of coronary ostial stenosis. The aortic valve appeared thickened and there was trivial aortic regurgitation.

In view of the severity of the stenosis, aortic valve surgery was performed by Mr R N Sapsford. At operation, dense deposits of firm atheromatous tissue in the right and non-coronary sinuses and severe ostial stenosis of the right coronary artery were found. The left coronary ostium appeared normal. The aortic valve, whose cusps were thickened, was excised, the aortic root was enlarged to insert a Bjork-Shiley prosthesis and saphenous vein was grafted to the right coronary artery. Since operation she has made excellent progress and has returned to normal activities. She remains on diet, lipid-lowering drugs and warfarin.

#### *Discussion*

Familial hypercholesterolaemia has autosomal dominant inheritance. The heterozygote phenotype is found in one in 500 of the population while the homozygote is rare at one per million. The condition is characterized by raised plasma cholesterol, elevated low-density lipoprotein and, frequently, reduced high-density lipoprotein. The basic abnormality is a relative or, in the case of the homozygote, profound reduction in the number and activity of the low-density lipoprotein receptors normally found on the surfaces of all cells, which consequently cannot take up cholesterol from the plasma by the normal mechanism. Cholesterol is instead cleared by the macrophage scavenger pathway, resulting in the formation of xanthomata and a greatly increased tendency to atheroma.

The consequent cardiac complications of this condition are thus rapidly progressive coronary artery disease which may present clinically with premature angina pectoris, early myocardial infarction or sudden death, and xanthomatous involvement of the aortic valve and aortic root giving rise to aortic stenosis. Allen *et al.* (1980) described 7 such patients aged 12–25 years. All had a systolic murmur and an abnormal aortic root on angiography, 6 having an aortic valve gradient. Four complained of angina pectoris, 2 of these also having experienced syncope. Three patients have undergone surgery. Our patient

<sup>1</sup>Case presented to Clinical Section, 13 April 1984.  
Accepted 8 November 1984

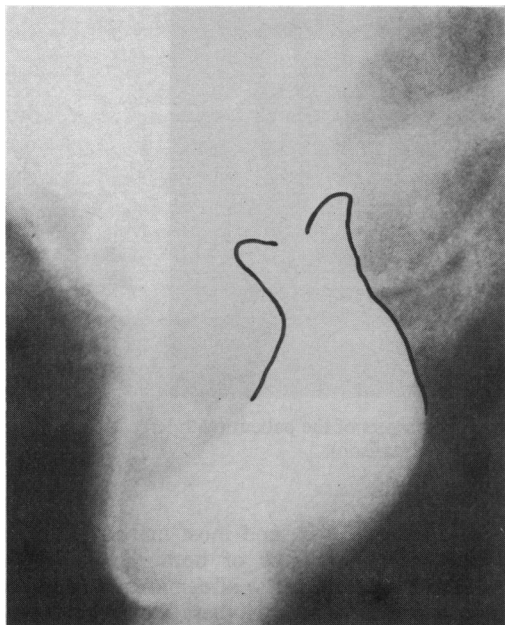


Figure 1. Aortic root angiogram (45° LAO) showing abnormal funnelled appearance (outlined) of the aortic root resulting from xanthomatous deposits, with obliteration of the coronary sinuses

showed the same typical funnelled appearance of the aortic root with supra-annular narrowing (Figure 1), although at catheterization the gradient was found to occur at the level of the valve, presumably as a result of the valve thickening and restricted cusp movement. The xanthomatous deposits may result in narrowing of the coronary ostia causing angina. Such deposits were found at operation in our patient and although she did not have angina, coronary artery bypass grafting to one artery was carried out.

Aortic surgery was recommended in this patient in view of the severity of the aortic stenosis. The aortic valve was replaced following enlargement of the aortic root to allow the use of an adequately sized prosthesis, using a technique first described by Manouguian & Seybold-Epting (1979). The aortotomy incision was extended down through the aortic valve ring into the anterior leaflet of the mitral valve, and the defect so created was repaired using a pericardial patch to reconstitute the mitral valve and aortic root while enlarging the valve ring. A more radical surgical approach to this problem, involving combined cardiac and liver transplantation, has been described recently by Starzl *et al.* (1984), but this would not have been justified in our patient.

Her early progress and symptomatic improvement, with rapid increase in both weight and stature, have been excellent and compare very well

with the experience of others (Allen *et al.* 1980). Her prognosis is greatly improved with relief of the aortic stenosis, but more effective control of her hypercholesterolaemia (current level 10.5 mmol/l) will be necessary to prevent further xanthoma formation. The method of choice will be low-density lipoprotein apheresis using adsorption columns (Borberg *et al.* 1983) when this becomes available in the United Kingdom.

**Acknowledgments:** We are grateful to Professor V Wynn and Dr E M M Besterman for their permission to report this case.

#### References

- Allen J M, Thompson G R, Myant N B, Steiner R & Oakley C M (1980) *British Heart Journal* 44, 361-368  
Borberg H, Bode C, Mattele L, Oette K, Tauchert M & Stoffel W (1983) In: Plasma Separation and Plasma Fractionation. Ed. H J Gurland and M J Lysaght. Karger, Basel; pp 266-271  
Manouguian S & Seybold-Epting W (1979) *Journal of Thoracic and Cardiovascular Surgery* 78, 402-412  
Starzl T E, Bahnon H T, Hardesty R L *et al.* (1984) *Lancet* i, 1382-1383

#### Pachydermoperiostosis with multiple basal cell carcinomata<sup>1</sup>

R H Meyrick Thomas MA MRCP

J D T Kirby FRCP

Department of Dermatology

St Bartholomew's Hospital, London EC1A 7BE

Pachydermoperiostosis is an uncommon, inherited disease otherwise known as idiopathic, or primary, hypertrophic osteoarthropathy. We report a patient with pachydermoperiostosis in whom multiple basal cell carcinomata have developed. The possibilities that these lesions may have resulted from radiotherapy, or may be related to the primary disease are discussed.

#### Case report

A 63-year-old man was diagnosed as having pachydermoperiostosis in his twenties. He had received orthopaedic treatment in childhood for swollen knees and genu valgum. In his teens he developed excessive sweating from his hands and

<sup>1</sup>Case presented to the Section of Dermatology, 17 May 1984. Accepted 8 November 1984