

Fulminant ulcerative colitis in late pregnancy and the puerperium

J B Anderson FRCS G M Turner FRCOG R C N Williamson MD MChir *Departments of Surgery and Obstetrics, Bristol Royal Infirmary and Bristol Maternity Hospital*

Keywords: colitis, ulcerative; megacolon, toxic; pregnancy complications

Paper read
to Section of
Colo-Proctology,
14 March 1986

Summary

Four patients underwent emergency colectomy during pregnancy or the puerperium for complications of ulcerative proctocolitis. Three had inactive colitis at conception, while in the fourth the disease started during pregnancy. Three patients required subtotal colectomy and ileostomy for toxic dilatation during the third trimester or within 5 days of delivery, and the fourth underwent proctocolectomy postpartum for intractable colitis. There were no maternal deaths but 2 of 4 infants died. One child weighing 1.4 kg survived vaginal delivery during the 33rd week of pregnancy, 2 weeks after his mother had undergone emergency colectomy.

Introduction

Ulcerative colitis preferentially affects women between the ages of 20 and 39 years¹ and does not impair fertility. Thus up to 50% of females who develop the disease before the age of 45 will subsequently become pregnant². Between 30% and 50% of women with colitis will have a relapse during or immediately after pregnancy. Early reports emphasized that the onset or exacerbation of symptoms at this time was frequently fatal to both mother and baby³, but recent improvements in care mean that a safe outcome can usually be anticipated, at least for the mother⁴.

Emergency colectomy is seldom required for complications of ulcerative colitis during pregnancy, and operation is associated with a high mortality rate both for the fetus and the mother. We report 4 such patients with fulminating colitis, all of whom survived an emergency colectomy, although 2 of the infants were stillborn.

Patients and results

Four patients underwent emergency colectomy for severe ulcerative proctocolitis soon after the birth of their child, or, in one case, 2 weeks antepartum. Operation followed delivery by 2 days, 5 days and 5 weeks in the 3 postpartum cases (Table 1). Two babies were stillborn, one was delivered at term without complication and one survived delivery at 33 weeks weighing only 1.4 kg; thus 3 of the 4 deliveries were premature. Two women had had previous normal deliveries.

Three of the mothers had developed ulcerative colitis 1–10 years before conception and suffered a severe relapse during the third trimester. The fourth had no previous history and was admitted to hospital at 28 weeks with lower abdominal pain and bloody diarrhoea. In each case initial treatment included oral and topical corticosteroids, together with sulphasalazine (Salazopyrin), and symptomatic improvement followed. In the most recent case (No. 4) the β -sympathetic agonist ritodrine was administered to prevent premature birth following emergency resection of a toxic megacolon at 33 weeks (Figure 1); delivery was indeed delayed for a further 12 days and the infant survived. In the other patients delivery (whether premature or full-term) led to exacerbation of colitis, and 2 of these 3 developed toxic dilatation within a few days of birth.

One patient came to operation 5 weeks postpartum because of progressive deterioration despite intensive medical therapy. Each of the others had radiological evidence of gross colonic distension and in one case the caecum perforated preoperatively. The 3 women with toxic dilatation underwent subtotal colectomy and ileostomy formation (Table 2); two have had subsequent excision of the rectal stump for

Table 1. Details of presentation and outcome in 4 women with fulminant colitis in late pregnancy

Patient no.	Age	Parity	Duration of UC	Week of relapse	Week of birth	Time of colectomy	Fetal outcome
1	25	1	2 years	28	34	2 days postpartum	Stillborn
2	25	0	10 years	37	40	5 days postpartum	Alive (4.0 kg)
3	28	3	1 year	28	34	5 weeks postpartum	Stillborn
4	18	0	Nil	28●	33	12 days antepartum	Alive (1.4 kg)

● Initial onset of disease at this time

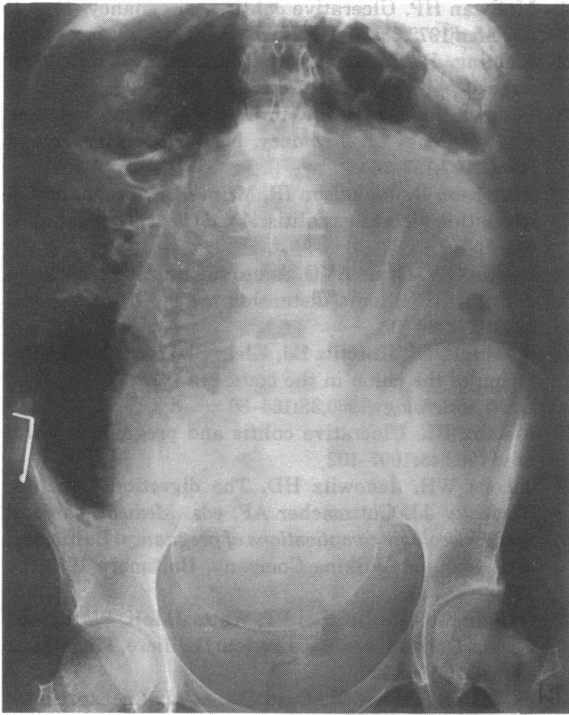


Figure 1. Toxic dilatation of the colon in 33rd week of pregnancy

persistent proctitis and in the third this procedure is under consideration. The fourth woman with intractable colitis had a proctocolectomy in the absence of appreciable dilatation of the bowel. Particular difficulty was encountered during 2 of the operations. In one there was faecal peritonitis, while in the other the grossly inflamed and dilated bowel had to be mobilized without disturbing the gravid uterus. Fortunately all 4 mothers survived, though two developed serious intra-abdominal sepsis postoperatively.

Three patients have been investigated for secondary infertility. One of these subsequently had 3 spontaneous abortions during the first trimester and was found to have a balanced translocation between the long arms of chromosomes 13 and 15; she eventually gave birth to a healthy child at 34 weeks. The fourth patient became pregnant again 4 years after colectomy despite previous faecal peritonitis and a pelvic abscess; the pregnancy was terminated on medical advice.

The social morbidity was high, with 3 of the 4 women separating from their partners, although 2 of them have since remarried.

Discussion

Certain facts have been established from previous reviews of the association between pregnancy and ulcerative proctocolitis. First, ulcerative colitis does not affect fertility⁴⁻⁷. A recent survey showed that the involuntary infertility rate among 147 married women with the disease was only 6.8%, while some 10% of all marriages in the UK are childless because of fertility problems⁸. Second, ulcerative colitis generally has no effect on the outcome of pregnancy⁴⁻⁷. Among 209 completed pregnancies in the Oxford study, 84% produced normal full-term babies and 77% resulted in uncomplicated vaginal delivery; low birth weight and post-maturity were no more common than usual. Even when ulcerative colitis first developed during pregnancy, there was a good chance (88%) of a normal live birth⁸. Despite these figures, our experience emphasizes that patients ill enough to require operation during or immediately after pregnancy have a high risk of stillbirth. Whether such a risk is any greater than that of any other intra-abdominal operation undertaken during late pregnancy remains uncertain.

Third, some 30% of women with inactive colitis at the time of conception will develop an exacerbation of their disease during pregnancy or the puerperium^{4,5,8}, a figure close to the expected recurrence rate in a comparable group of non-pregnant women^{9,10}. Colitis that is active at the time of conception is more likely to be troublesome: up to two-thirds of patients remain symptomatic or deteriorate thereafter⁸. McEwan¹¹ reported 3 deaths among 9 women who required operation during pregnancy or the puerperium, but no mention was made of the activity of the disease at the start of pregnancy. Ulcerative colitis occurring for the first time during pregnancy has previously been considered particularly dangerous, with a maternal mortality rate in the region of 15%¹², although prompt and vigorous medical therapy should reduce this risk.

Ulcerative colitis tends to relapse or appear for the first time either during the first trimester or in the puerperium⁴⁻⁸. It has been suggested that the high circulating levels of serum 17-hydroxycorticosteroids during the second and third trimesters induce remission at this time⁹; levels fall sharply following delivery¹³. Although cortisol comprises 90% of total plasma 17-hydroxycorticosteroids in the third trimester of pregnancy, the increase is actually due to elevated levels of the glucocorticoid-binding protein, transcortin. Biologically active cortisol remains

Table 2. Operative details and long-term results

Patient no.	Operation	Postoperative complications	Follow up	Further operation	Subsequent fertility	Social outcome
1	Colectomy, ileostomy (caecal perforation)	Pelvic abscess	10 years	Proctectomy at 12 months	1 termination	Divorce
2	Colectomy, ileostomy	Nil	10 years	Proctectomy at 3 months	3 spontaneous abortions, 1 live birth	Satisfactory
3	Proctocolectomy, ileostomy	Pelvic and subphrenic abscess	5 years	—	2° infertility	Divorce, remarriage
4	Colectomy, ileostomy	Nil	2 years	—	2° infertility	Divorce, remarriage

unchanged⁵, and there is no increased steroid action in pregnancy. It is interesting to note that symptoms in each of our cases began during the third trimester.

Although ulcerative colitis and pregnancy frequently coexist, therefore, it is rare for fulminating disease to ensue and require operation to save the mother's life before or after delivery. We have found only 35 such cases in the literature^{11,14-25}. The overall fetal mortality rate among these patients was 53% and the maternal mortality rate was 29%. While maternal death is becoming less frequent, the high stillbirth rate probably reflects the severity of the disease rather than the effects of operation. Despite the problems encountered by our 4 patients during their pregnancies, it is interesting to note that each has tried (and 2 have succeeded) to become pregnant again, albeit generally by a different husband.

References

- 1 Goligher J. Ulcerative colitis. In: *Surgery of the anus, rectum and colon*. 5th ed. London: Baillière Tindall, 1985
- 2 MacDougall I. Ulcerative colitis and pregnancy. *Lancet* 1956;ii:641-3
- 3 Barnes CS, Hayes HM. Ulcerative colitis complicating pregnancy and the puerperium. *Am J Obstet Gynecol* 1931;22:907-12
- 4 Vender RJ, Spiro HM. Inflammatory bowel disease and pregnancy. *J Clin Gastroenterol* 1982;4:231-49
- 5 Jarnerot G. Fertility, sterility and pregnancy in chronic inflammatory bowel disease. *Scand J Gastroenterol* 1982;17:1-4
- 6 Sorokin JJ. Pregnancy and inflammatory bowel disease. *Obstet Gynecol* 1983;62:247-51
- 7 Donaldson RM. Management of medical problems in pregnancy - inflammatory bowel disease. *N Engl J Med* 1985;312:1616-19
- 8 Willoughby CP, Truelove SC. Ulcerative colitis and pregnancy. *Gut* 1980;21:469-74
- 9 de Dombal FT, Watts JM, Watkinson G, Goligher JC. Ulcerative colitis and pregnancy. *Lancet* 1965;ii:599-602
- 10 Nielsen OH, Andreasson B, Bandesen S, Jarnum S. Pregnancy in ulcerative colitis. *Scand J Gastroenterol* 1983;18:735-42
- 11 McEwan HP. Ulcerative colitis in pregnancy. *Proc R Soc Med* 1972;65:279-81
- 12 Fielding JF. Inflammatory bowel disease and pregnancy. *Br J Hosp Med* 1976;15:345-52
- 13 Peterson RE. Cortisone. In: Fuchs F, Klopper A, eds. *Endocrinology of pregnancy*. New York: Harper and Row, 1977:157-76
- 14 Abramson D, Jankelson IR, Milner LR. Pregnancy in idiopathic ulcerative colitis. *Am J Obstet Gynecol* 1951;61:121-9
- 15 Peskin GW, Davis AVO. Acute fulminating ulcerative colitis with colonic distension. *Surg Gynecol Obstet* 1960;110:269-76
- 16 Marshak RH, Korelitz BJ, Klein SH, et al. Toxic dilatation of the colon in the course of ulcerative colitis. *Gastroenterology* 1960;38:165-80
- 17 Maddix BL. Ulcerative colitis and pregnancy. *Minn Med* 1962;45:1097-102
- 18 Jacobs WH, Janowitz HD. The digestion tract. In: Rovinsky JJ, Guttmacher AF, eds. *Medical, surgical and gynecologic complications of pregnancy*. Baltimore: Williams and Wilkins Company, Baltimore 1965, pp 190-4
- 19 Goligher JC, de Dombal FT, Watts JM, Watkinson G, eds. *Ulcerative colitis*. London: Bailliere, Tindall and Casswell, 1968:197
- 20 Jalan KN, Sircus W, Card WI, et al. An experience of ulcerative colitis. I. Toxic dilatation in 55 cases. *Gastroenterology* 1969;57:68-82
- 21 Holzbach RT. Toxic megacolon in pregnancy. *Am J Dig Dis* 1969;14:908-10
- 22 Flatmark AL, Nordoy A, Gjone E. Radical surgery for ulcerative colitis during pregnancy. *Scand J Gastroenterol* 1970;6:45-7
- 23 Ritchie JK. Ileostomy and excisional surgery for chronic inflammatory disease of the colon. A survey of one hospital region. *Gut* 1971;12:528-40
- 24 Webb MJ, Sedlack RE. Ulcerative colitis in pregnancy. *Med Clin North Am* 1974;58:823-7
- 25 Cooksey G, Gunn A, Wotherspoon WC. Surgery for acute ulcerative colitis and toxic megacolon during pregnancy. *Br J Surg* 1985;72:547

(Accepted 9 October 1986. Mr Anderson is now in the Department of Urology, Royal Hallamshire Hospital, Sheffield)