

Does venous function deteriorate in patients waiting for varicose vein surgery?

S Sarin FRCS D A Shields FRCS J Farrah BSc J H Scurr FRCS

P D Coleridge-Smith FRCS *Department of Surgery, University College and Middlesex School of Medicine, The Middlesex Hospital, Mortimer Street, London W1N 8AA*

Keywords: varicose veins; chronic venous insufficiency; photoplethysmography; ultrasonography; audit

Summary

We have looked at the deterioration in the condition of the lower limbs in a group of 36 patients who were waiting for a median time of 20 months for varicose vein surgery, using clinical examination, colour Duplex scanning and photoplethysmograph (95% refilling times). We found a significant deterioration in this group of patients, with four limbs initially unaffected developing reflux on Duplex scanning, of which three had clinical varicose veins (all four were offered surgery), and of the initial 56 involved limbs, 10 further sources of reflux were found (18%), necessitating alteration of the initial planned surgical procedure. No patient developed deep venous insufficiency or ulceration while on the waiting list, although there was one new case of lipodermatosclerosis. However, had surgery been undertaken after the first assessment, 14 patients (25%) would potentially have required further surgery, although accepting this as justification for allowing patients to wait takes no account of patient suffering or quality of life while waiting for operation.

Introduction

The waiting times for many surgical procedures, performed in NHS hospitals, are now well over 2 years. Minor and intermediate elective procedures are particularly affected and varicose vein surgery probably receives the lowest priority in most surgical units.

The effect of waiting time on progression of venous disease has not been investigated before. Though it is likely that the underlying disease process continues to progress, until recently it has not been possible to assess changes in venous function with any accuracy. The development of sophisticated non-invasive tests like Duplex ultrasound scanning¹⁻³ and photoplethysmography⁴⁻⁷ can provide additional objective information to clinical examination.

The aim of this paper was to investigate whether there was any deterioration in patients with varicose veins awaiting surgery and whether this changed the operative procedure required.

Methods

All patients referred to the Middlesex Hospital with venous disease undergo a non-invasive venous assessment in the vascular laboratory after the first outpatient visit. This includes full clinical examination, photoplethysmography and colour Duplex ultrasound scanning.

A history is taken, and clinical examination carried out by a clinician who records the presence of long

or short saphenous vein varicosities, the clinical site of reflux (sapheno-femoral, sapheno-popliteal or perforator) and whether lipodermatosclerosis (LDS) or ulceration are present. Lipodermatosclerosis is defined as erythema, induration and pigmentation in the gaiter area.

Photoplethysmography is carried out on the same occasion by a technician using a Vasculab PPG-13 photoplethysmograph (MedaSonics, Fremont, California), with the patients seated and legs dependent; they are asked to dorsiflex their ankles 10 times, and 95% refilling time measured. The test is repeated and the values given are the mean of two readings. Above- and then below-knee cuffs are then applied and the test repeated. A 95% refilling time of less than 15 s is defined as abnormal in our laboratory⁸.

All patients also have Duplex scanning undertaken by an experienced operator using an Acuson 128 (Acuson, Mountain View, California) with a 7 MHz linear array transducer and colour flow mapping. The test is carried out with the patient standing and taking weight on the contralateral limb to that being examined. Both the superficial and deep veins are assessed to identify sites of venous incompetence. Reflux is defined as reverse flow lasting more than 0.5 s on release of manual calf compression^{9,10}. All investigations are carried out between 10.00 and 12.00 h at a room temperature of 21°C, as ambient temperature and time of day have been shown to affect measurements of venous function¹¹.

A group of 36 patients admitted to the Middlesex Hospital in 1991 for varicose vein surgery were investigated. All had previously undergone non-invasive venous assessment, and underwent repeat non-invasive venous testing just prior to their operation.

The results of the clinical examination, photoplethysmography and Duplex scanning were compared with the same investigations undertaken when the patient was first placed on the waiting list. We then looked at the deterioration in venous disease, both in the initial presenting limb and in initially-normal limbs. We assessed how many further procedures were required because of the wait, ie how many limbs that were initially normal then required surgery, and how many extra procedures were carried out on the originally affected limb.

The descriptors used are medians with interquartile ranges, and Wilcoxon's paired Sign Rank Sum test was used to compare for changes within subjects.

Results

A total of 36 patients were assessed. The sex ratio was M : F 10 : 26, and the median age at operation

was 55 (34-60) years. The median time interval between the first and second non-invasive assessment was 20 (15-27) months. At the initial examination 56 limbs had varicose veins, of which 43 were primary and 13 recurrent. Sixteen limbs were normal.

Clinical examination

Comparison of the clinical findings revealed that 48 limbs when first seen had varicosities in the distribution of the long saphenous vein, but at the second visit this had increased by three. Similarly, although only seven limbs had varicosities in the distribution of the short saphenous vein when first examined, this had increased to 18 when examined before operation. When we compared the findings of lipodermatosclerosis, six limbs continued with skin changes, and one further limb became involved. Only one limb had a venous ulcer at the first visit, and this had healed prior to operation, with no new cases occurring. Of the 16 clinically normal limbs on first examination, five limbs (31%) developed clinical varicose veins: four in the distribution of the long saphenous vein and one in the short saphenous system.

Duplex findings

At first examination, 40 limbs were found to have reflux at the sapheno-femoral junction, but this had increased to 45 at the second examination. Eleven limbs had sapheno-popliteal reflux at the first visit, and this increased to 20 at the second. Only two patients were found to have deep venous insufficiency (popliteal vein reflux), and no further cases were recorded at the second examination. Therefore, 14 new cases of reflux on Duplex scanning were found on the second examination, an increase of 27%.

Of the 16 limbs that were normal at the first visit, four (25%) developed reflux on Duplex scanning (two sapheno-femoral junctions, two sapheno-popliteal junctions and one mid thigh perforators), of which three also developed clinical varicosities. In the limbs that had clinical disease at the first visit ($n=56$), 10 had further sources of reflux (three sapheno-femoral junctions, four sapheno-popliteal junctions and three mid thigh perforators) were identified on Duplex scanning at the second examination, a deterioration in 18% of limbs.

Photoplethysmography

The photoplethysmography findings in the group of limbs that were clinically normal at the first visit are

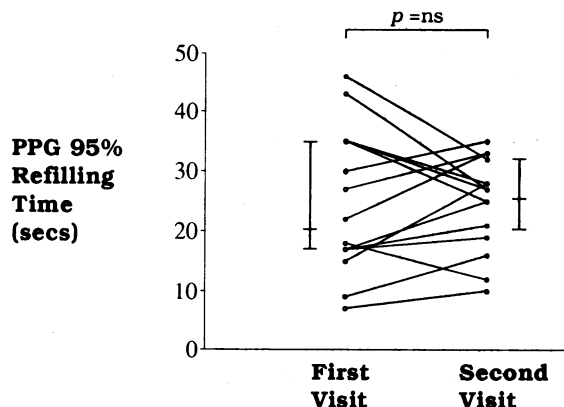


Figure 1. Comparison of the photoplethysmography (PPG) refilling times at the first and second examination for those limbs that were clinically normal at the first visit ($n=16$). Wilcoxon's Rank Sum test for paired samples.

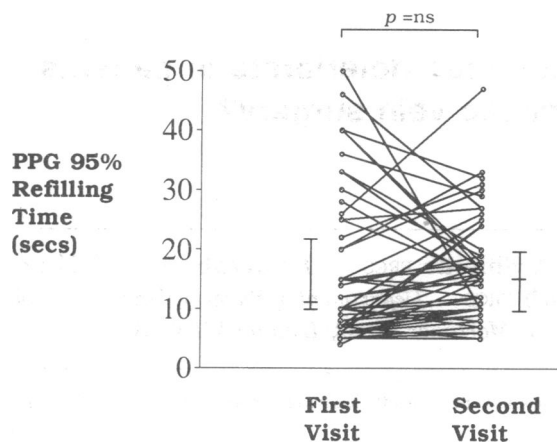


Figure 2. Comparison of the photoplethysmography (PPG) refilling times at the first and second examination for those limbs that were clinical abnormal at the first visit ($n=56$). Wilcoxon's rank sum test for paired samples

shown in Figure 1. Though the 95% refilling times increased from a median 20 (17-35) s to 26 (20-32) s, this was not statistically significant. Those patients with clinical varicose veins (Figure 2) also showed no significant deterioration in the 95% refilling times between the two visits (10 (7-22) s vs 15 (9-20) s, $P=ns$). The 95% refilling times at the first (15 (8-32) s) and second (15.5 (8.5-21) s) visits in those limbs which were normal on Duplex scanning at the first visit but not the second, which again does not show any significant change.

Discussion

Clinical examination alone is an unsatisfactory method for assessing change in varicose veins, whether with time or surgical intervention. McAdam *et al.*¹⁷ have shown that clinical assessment can vary both within and between observers, with an intra-observer agreement of symptomatic response and visual improvement following surgery of only 30%, and an inter-observer agreement of 60% in evaluating visual improvement¹². We, therefore, elected to supplement clinical examination with more objective tests of venous function. Photoplethysmography and colour Duplex scanning were selected as it is likely that they measure different aspects of venous disease - the former providing an assessment of calf muscle pump function and venous reflux⁴⁻⁷, the latter a detailed description of venous anatomy and valvular function^{1-3,13}.

We have been able to demonstrate that in our group of patients, of those limbs initially identified as having a surgically correctable abnormality of the venous system, 18% showed a deterioration on Duplex scanning in their condition, necessitating extension of the planned surgical procedure in 10 limbs. Twenty-five percent of initially normal limbs ($n=16$) developed varicosities over the period of study, and then required surgery on the newly affected limb. This emphasizes that full re-assessment must be carried out prior to surgery on both affected and 'normal' limbs in patients who have been on the waiting list for any length of time, and that the initial assessment cannot be relied upon when planning operative procedures, as allowance must be made for possible further pathology developing since first seen.

The development of varicose veins in previously normal limbs tends to support the hypothesis that

there is an underlying abnormality in vein structure in patients with varicose veins. Both clinical examination and colour Duplex scanning showed deterioration while on the waiting list, although the prolonged refilling time on photoplethysmography was not statistically significant. This may be because all patients were provided with surgical stockings while on the waiting list, although we have not looked at levels of patient compliance during this period. Stockings have been shown to improve PPG refilling times, though no effect has been shown consistently on valvular reflux¹⁴⁻²⁰.

No patient developed venous ulceration while on the waiting list, and the one person who initially had ulceration healed while waiting for surgery. This form of gross clinical deterioration is unlikely to have been seen in this group of patients. Patients who had active ulceration requiring a surgical procedure to allow healing, or who were at risk of ulceration, are unlikely to be left on a non-urgent waiting list, and any patient subsequently developing ulceration is likely to have his admission expedited. This group, therefore, represents patients who were not thought likely to deteriorate significantly while on the waiting-list.

It is difficult to quantify the effects of a prolonged wait for venous surgery. Clearly, there is a significant deterioration in the clinical conditions of patients, and there is also considerable morbidity for the patients while they wait. However, this has to be offset against the substantial number of patients (up to one quarter) who would require a second procedure at a later date if surgery had been carried out promptly after the first assessment. This study does show that, even in a group of patients thought to be at low risk of worsening of their varicosities, there is a significant deterioration in the clinical condition of such patients, together with a concomitant increase in the number of abnormalities found on Duplex examination.

References

- 1 Persson AV. Use of ultrasonic colour imaging in the evaluation of the vascular system. In: Nicolaides A, Salmasi A-M, eds. *Cardiovascular applications of Doppler ultrasound*. New York: Churchill Livingstone, 1988: 357-64
- 2 Grant EG, Tessler FN, Perella RR. Clinical Doppler imaging. *Am J Radiol* 1989;152:707-17
- 3 Foley WD, Middleton WD, Lawson TL, Erikson TL, Quiroz FA, Macrander S. Colour Doppler ultrasound imaging of lower extremity venous disease. *AJR* 1989; 152:371-6
- 4 Kempczinski RF, Berlatzky Y, Pearce WH. Semi-quantitative photoplethysmography in the diagnosis of

lower extremity venous insufficiency. *J Cardiovasc Surg* 1986;27:17-23

- 5 Li J-M, Anderson FA, Wheeler HB. Non-invasive testing of venous reflux using photoplethysmography: standardization of technique and evaluation of interpretation criteria. *Bruit* 1983;7:25-9
- 6 Abramowitz HB, Queral LA, Flinn WR, et al. The use of photoplethysmography in the assessment of venous insufficiency: a comparison to venous pressure measurements. *Surgery* 1979;86:434
- 7 Nicolaides AN, Miles C. Photoplethysmography in the assessment of venous insufficiency. *J Vasc Surg* 1987;5:405-12
- 8 Sarin S, Shields DA, Scurr JH, Coleridge Smith PD. Photoplethysmography: a valuable non invasive tool in the assessment of venous dysfunction? *J Vasc Surg* (in press)
- 9 Scott Miller S, Foote AV. The ultrasonic detection of incompetent perforating veins. *Br J Surg* 1974;61:653-6
- 10 Nicolaides AN, Sumner DS, eds. *Investigation of patients with deep venous thrombosis and chronic venous insufficiency*. London: Med-Orion, 1991
- 11 Bishara RA, Sigel B, Rocco K, et al. Deterioration of venous function in normal lower extremities during daily activity. *J Vasc Surg* 1986;3:700-6
- 12 McAdam WAF, Horrocks JC, DeDombal FT. Assessment of the results of surgery for varicose veins. *Br J Surg* 1976;63:137-40
- 13 Coleridge Smith PD. Noninvasive venous investigation. *Vasc Med Review* 1990;1:139-66
- 14 Sigel S, Edelstein AL, Felix Jr R, Memhardt CR. Compression of the deep venous system of the lower leg during active recumbency. *Arch Surg* 1973;106:38-43
- 15 Sigel B, Edelstein AL, Savitch L, Hasty JH, Felix Jr R. Type of compression for reducing venous stasis. *Arch Surg* 1975;110:171-5
- 16 Lewis CE Jr, Antoine J, Mueller C, Talbot WA, Swaroop R, Sterling Edwards W. Elastic compression in the prevention of venous stasis. A critical re-evaluation. *Am J Surg* 1976;132:739-43
- 17 Husni eA, Ximenes C, Goyette EM. Elastic support of the lower limb in hospital patients. A critical study. *JAMA* 1970;214:1456-62
- 18 Gjores JE, Theulesius O. Compression treatment in venous insufficiency evaluated with foot volumetry. *Vasa* 1977;6:364-368
- 19 Jones NAG, Webb PJ, Rees RI, Kakkar VV. A physiological study of elastic compression stockings in venous disorders of the leg. *Br J Surg* 1980;67:569-72
- 20 Evander E, Evander A, Scigala E, et al. Use of photoplethysmography to evaluate the effectiveness of elastic support stockings. *Bruit* 1984;8:75-8

(Accepted 23 March 1992)