

## Case reports

### Body builder's liver

A Klava BSc<sup>1</sup> P Super FRCS<sup>1</sup>

M Aldridge FRCS<sup>2</sup> J Horner FRCS<sup>2</sup>

P Guillou MD FRCS<sup>1</sup> <sup>1</sup>Academic Surgical Unit,  
St Mary's Hospital, Praed Street, London W2 1NY and  
<sup>2</sup>Department of Surgery, Ashford Hospital,  
London Road, Ashford, Middlesex TW15 3AA, UK

**Keywords:** anabolic steroids; liver tumour; hepatocellular carcinoma

#### Introduction

Anabolic and other sex steroids have for some time been known to induce hepatic abnormalities. Besides hepatic adenoma, other abnormalities include peliosis hepatitis, focal nodular hyperplasia and hepatocellular carcinoma.

#### Case report

A 35-year-old, professional body builder presented in February 1991 with acute epigastric pain. Over a period of 4 h, the pain became much more severe, sharp and constant, radiating through to his back and causing him a great deal of distress. The remainder of the history was unremarkable other than self-administration of anabolic steroids (25 mg nandrolone decanoate, a 3-weekly intramuscular depot preparation, and 30 mg norethandrolone) on alternate days for the previous 3 years.

Examination revealed a muscular physique, sinus tachycardia and cool clammy peripheries. His abdomen was exquisitely tender and rigid with marked hepatomegaly. Bowel sounds were present and rectal examination normal.

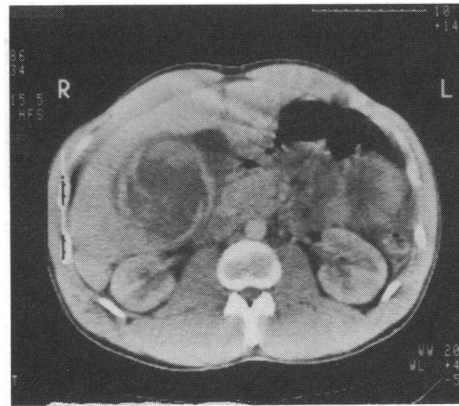
A full blood count revealed a leucocytosis and low haemoglobin. Peritoneal lavage detected the presence of red cells. Total bilirubin, alkaline phosphatase and alanine aminotransferase were mildly elevated and hepatitis B screen and  $\alpha$ -fetoprotein were normal. Plain abdominal films showed a suspiciously large liver shadow and abdominal ultrasound demonstrated the presence of a 9 cm, partly solid, partly cystic space occupying lesion in the right lobe of the liver. Coeliac angiograms later revealed a relatively avascular mass, containing some pools of contrast.

The patient was resuscitated with blood and large volumes of colloid. A diagnosis of steroid induced tumour was made and anabolic steroid administration discontinued. Serial scanning has demonstrated the lesion to be resolving up to 1 year after presentation (Figure 1).

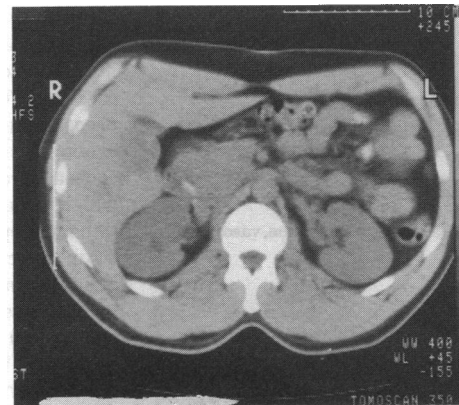
Fine needle aspiration, attempted 1 month after initial presentation, failed to obtain an adequate tissue sample, provoking a further small haemorrhage. On the basis of regression in size and improvement in the patient's condition, further instrumentation was considered unnecessary.

#### Discussion

The association between anabolic steroids and hepatocellular carcinoma was first recognized in the early 1970s<sup>1</sup>. This was particularly evident in patients with hypoplastic anaemia, receiving anabolic steroids to improve bone marrow function. Since then, the development of hepatocellular carcinoma



(a) Case presented to Clinical Section, 15 March 1993



(b)

Figure 1. (a) A computerized tomography (CT) scan on initial presentation; (b) CT scan almost 12 months later

has been seen in cases receiving anabolic steroids for a variety of other conditions such as paroxysmal nocturnal haemoglobinuria and hypopituitarism.

The role of sex hormone dependence in the development and progression of liver tumours may be based on their association with oral contraceptive preparations and anabolic steroids<sup>2</sup>. Striking evidence of endocrine dependence has been shown in many cases with cessation and regression of tumour growth on discontinuing androgen therapy<sup>3</sup>. This has been further supported by detecting the presence of oestrogen and androgen receptors in tumour tissue<sup>4</sup>.

Barrows *et al.*<sup>5</sup> completed a retrospective study of 227 post-mortem cases at the Liver Tumour Registry (Louisville, USA). The majority were young women in hyperoestrogenic states (recently pregnant or taking oral contraceptives) with benign adenomas and focal nodular hyperplasia being the commonest histological findings.

There appears to be some disparity between the histological classification and the way these tumours behave. The cases of McCaughan *et al.*<sup>3</sup> show prominent degrees of nuclear and cytoplasmic pleomorphism together with macroscopic appearances favouring a diagnosis of hepatocellular carcinoma. Their biological behaviour, however, is comparable to that seen with adenomas and not consistent with the relentlessly progressive disease seen when other aetiologies are responsible for the formation of hepatocellular carcinoma. On the basis of these findings, hepatocellular carcinoma is a likely diagnosis in this particular case despite the benign radiological appearance.

A case reported by Creagh *et al.*<sup>6</sup> described a young athlete presenting with abdominal pain and haemorrhage which was ultimately fatal. At post-mortem, malignant transformation of the liver could be seen with hyperplasia and nodule formation, but the presence of a true tumour could be regarded as contentious.

The hazards of non-therapeutic anabolic-androgenic steroid administration and their trivial usage have been highlighted by these recent reports. Possible disturbances to liver structure and function as well as life threatening consequences should be made clear to all those using such substances to enhance athletic success and physique.

#### References

- 1 Johnson FL, Feagler JR, Lerner KG, Majerus PW, Siegel M, Hartman JR, *et al.* Association of androgenic-anabolic steroid therapy with development of hepatocellular carcinoma. *Lancet* 1972;ii:1273

- 2 Anthony PP. Liver tumours. *Baillieres Clin Gastroenterol* 1988; 2:501-22
- 3 McCaughan GW, Bilous MJ, Gallagher ND. Longterm survival with tumour regression in androgen induced liver tumours. *Cancer* 1985;56:2622-6
- 4 Wilkinson ML. Sex steroids and primary hepatocellular carcinoma. *Anticancer Res* 1987;7:1071-7
- 5 Barrows GH, Mays ET, Christopherson WM. Steroid related neoplasia in human liver. *Int Symp Princess Takamatsu Cancer Res Fund* 1987;18:47-59
- 6 Creagh TM, Rubin A, Evans DJ. Hepatic tumours induced by anabolic steroids in an athlete. *J Clin Pathol* 1988;41:441-3

(Accepted 19 May 1993)

## Ergot induced myocardial ischaemia in a patient without vasospastic disorder

Ido Paz MD Yehuda Carmeli MD

Department of Internal Medicine, Hadassah Mount Scopus, POB 24035, Jerusalem 91240, Israel

**Keywords:** myocardial ischaemia; ergot therapy; migraine, vasospastic disorder

### Introduction

Myocardial ischaemia following ergot therapy for migraine had been previously reported<sup>1-4</sup>. An association is known to exist between the vasoactive disorders migraine headache, Raynaud's phenomenon and variant angina<sup>5-6</sup>. Here we present a patient without any of these disorders who had ergot induced transient myocardial ischaemia.

### Case report

A 35-year-old male presented with anginotic chest pain for the first time in his life. He had no history of ischaemic heart disease (IHD), nor risk factor for it except for mild overweight.

The patient's past medical history revealed paranoid type schizophrenia which was treated by clozapine and biperidine tablets. Under this treatment the disease was well controlled except for a single hospitalization 3 years prior to admission. He worked full-time as a salesman, and lived a normal life. The patient received dihydroergotamine for no clear indication for the 3 years preceding his current hospitalization. He had no history of either migraine headache or Raynaud's phenomenon. Careful history did not suggest overdose of the drug. On admission, physical examination and psychiatric interview were unremarkable.

The electrocardiogram demonstrated inverted T waves in leads V4 V6. Serum levels of creatinine phosphokinase (CK) had risen to a peak of 618  $\mu$ L. Thyroid functions tests were normal.

The ergot preparation was discontinued, his chest pain subsided, serum CK levels declined gradually and the T waves abnormalities returned to normal. No evidence of myocardial infarction or myocardial ischaemia was found on Tc99 scan (MIBI) 5 days after admission. Thallium stress test done a few weeks later had similar results.

Echocardiogram was normal. During 2 years of follow-up he was well and free of both chest pain and headache.

### Comments

Ergot alkaloids are in common use for the treatment of migraine headache, and are usually well tolerated. Several cases have been reported in which patients treated by ergot preparations for migraine had had ischaemic cardiac events<sup>1-4</sup>, some of them fatal<sup>2</sup>. These cases were presumably caused by ergot induced coronary arteries vasospasm, to which patients who suffer from variant angina are known to be susceptible<sup>5</sup>.

An association is known to exist between migraine headache and other vasoactive disorders<sup>5-8</sup>. Miller<sup>7</sup> had noted a possible relation between variant angina, migraine and Raynaud's phenomenon in a series of 62 patients. Similarly, Heupler *et al.* had reported vasospastic phenomena in 37% of 30 patients who had coronary spasm and no significant atherosclerosis on catheterization<sup>8</sup>. In two patients of this series ergotamine had caused an exacerbation of the anginal syndrome<sup>8</sup>. Therefore, it was suggested that there is a subgroup of patients whose migraine is part of a 'generalized vasospastic disorder'<sup>7</sup>. These patients seem to be those whose coronary arteries may be susceptible to the effect of ergot alkaloids. In our patient detailed medical history and work-up, as well as 2 years of follow-up did not suggest either significant coronary arteries atherosclerosis or any evidence for migraine, Raynaud's phenomenon or any other vasospastic disorder. To our knowledge this is the first case reported in which myocardial ischaemia, secondary to dihydroergotamine ingestion, is manifested in a patient with none of these vasospastic disorders.

The young male presented here had taken dihydroergotamine for a few years without any complaint. This is consistent with some of the cases described<sup>1,3,4</sup>, as the ergot preparation may have been started up to 8 years prior to the onset of the ischaemic event<sup>1</sup>.

The case described should call the attention of medical personnel to myocardial ischaemia as a possible adverse effect of ergot alkaloids. It seems prudent to avoid their use in patients who suffer from ischaemic heart disease. Moreover, some patients without any obvious vasospastic disorder may be susceptible to the coronary vasospastic effect of this medication.

### References

- 1 Goldfischer JD. Acute myocardial infarction secondary to ergot therapy. *N Engl J Med* 1960;262:860-3
- 2 Benedict CR, Robertson D. Angina pectoris and sudden death in the absence of atherosclerosis following ergotamine therapy for migraine. *Am J Med* 1979;67:177-8