

to this tumour suppressive effect of retinoids. The mechanism of action of these drugs is not clear, but seems more likely to be a general effect on tumour growth than restoration of normal DNA repair<sup>4</sup>.

#### References

- 1 Arlett CF, Harcourt SA, Cole J, Green MHL, Anstey AV. A comparison of the response of unstimulated and stimulated T-lymphocytes and fibroblasts from normal, xeroderma pigmentosum and trichothiodystrophy donors to the lethal action of UV-C. *Mutat Res* 1992;273:127-35
- 2 Cole J, Arlett CF, Norris PG, Stephens G, Waugh APW, Beare DM, *et al*. Elevated HPRT mutant frequency in circulating T-lymphocytes of xeroderma pigmentosum patients. *Mutat Res* 1992;273:171-8
- 3 Lehmann AR, Kirk-Bell S, Arlett CF, Paterson MC, Lohman PHM, Weerd-Kastelein EA, *et al*. Xeroderma pigmentosum cells with normal levels of excision repair have a defect in DNA synthesis after UV irradiation. *Proc Natl Acad Sci USA* 1975;72:219-23
- 4 Kraemer KH, DiGiovanna JJ, Moshell AN, Tarone RE, Peck GL. Prevention of skin cancer in xeroderma pigmentosum with use of oral isotretinoin. *N Engl J Med* 1988;318:1633-7
- 5 Pichler E, Fritsch P. Xeroderma pigmentosum: Tumorphylaxe mit Etrétinate. *Hautarzt* 1984;35:159-61
- 6 Strong A. Xeroderma pigmentosum variant: prevention of cutaneous neoplasms with etretinate. In: *Retinoids today and tomorrow*, Vol 17. London: Mediscript, 1989:40-2

(Accepted 23 September 1992)

## Pancreaticoduodenal artery aneurysm: diagnostic and management difficulties

A J N Taylor MBBS M J Hershman MS FRCS  
D Hadjiminis FRCS A G Tanner FRCS  
R D Rosin MS FRCS Department of Surgery,  
St Mary's Hospital, London WC2

*Keywords:* pancreas; aneurysm; haemorrhage

Pancreaticoduodenal artery aneurysms are rare cases of obscure gastrointestinal haemorrhage. We present a case with coexistent coeliac axis occlusion and discuss diagnostic and management problems.

#### Case report

A 67-year-old man presented with dark red gastrointestinal haemorrhage. Six years previously he had an abdominoperineal excision of a rectal carcinoma. Over the next 4 weeks he had 10 further bleeds, each of about 1 l and of rapid onset and short duration. The bleeding site was not demonstrated by colonoscopy, gastroscopy, computerized tomography (CT) scan or two angiograms performed during active bleeding.

Following a further large bleed, a laparotomy was performed. There were extensive adhesions but no evidence of tumour. The whole bowel was full of blood but no bleeding site was identified, despite extensive on table endoscopy. Two end ileostomies were raised to identify the direction of any further bleeding.

He had no further bleeding for 4 weeks, then had a large bleed via the proximal ileostomy. An angiogram revealed an inferior pancreaticoduodenal artery aneurysm (Figure 1). In addition, the coeliac axis filled retrogradely via the gastroduodenal arcade. The aneurysm was embolized on two occasions.

He continued to bleed and had another laparotomy which revealed extensive adhesions and a grossly disorganized pancreas. The large aneurysm was adherent to duodenum and encased in pancreas. All surrounding vessels were grossly abnormal. Aneurysm repair was impossible. It disintegrated on dissection and with difficulty, the feeding vessels were ligated.

Postoperatively, he deteriorated and a further laparotomy revealed ischaemia of the colon and ileum. These were

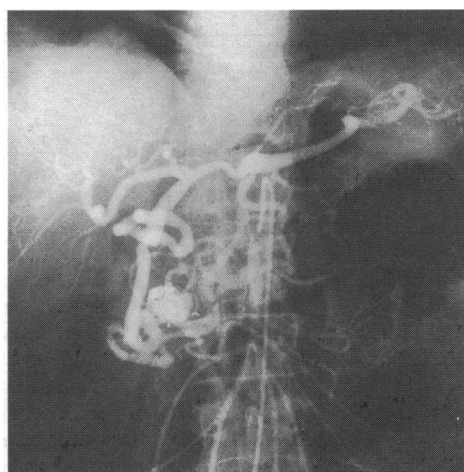


Figure 1. Arteriogram showing pancreaticoduodenal artery aneurysm with coils from embolization

resected but he failed to recover and died. He received a total of 104 units of blood.

#### Discussion

Pancreaticoduodenal artery aneurysms account for 3% of visceral artery aneurysms<sup>1</sup> and are usually caused by pancreatitis or trauma. Less frequently, they may be due to atherosclerosis, as in this case. These aneurysms have no pathognomonic features and are difficult to diagnose. The usual presentation is abdominal pain which may be general or local, simulating gastric, biliary or pancreatic disease<sup>2</sup>.

Fifty per cent of patients present with major bleeding into the gastrointestinal tract<sup>3</sup>. This patient illustrates the diagnostic difficulty that bleeding from these rare aneurysms may cause. Abdominal X-ray is not particularly helpful as it does not show the arterial calcification which occurs with other visceral aneurysms<sup>4</sup>. CT scanning may demonstrate unusual aneurysms but was unhelpful in this case, perhaps due to pancreatic disorganization. Arteriography is the only definitive investigation<sup>5</sup>, but this also, was noncontributory on two occasions. Similarly, exploratory laparotomy for obscure gastrointestinal haemorrhage reveals the bleeding site in only 30% of cases<sup>6</sup>.

There is no apparent correlation between aneurysm size and the risk of rupture. However, it is generally agreed that asymptomatic aneurysms should be surgically treated when they expand to a diameter three to four times the original vessel size<sup>7</sup>. When bleeding occurs, it may stop with conservative treatment but repeated rebleeding is usual. Small

Case presented to  
Clinical Section  
9 October 1992

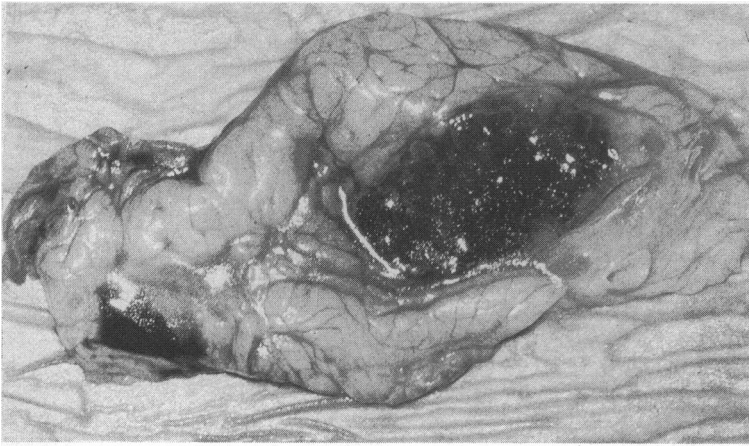


Figure 2. Postmortem appearance of pancreas and aneurysm

aneurysms may be adequately treated by underrunning<sup>8</sup>. Larger ones require ligation of the feeding vessels and excision of the aneurysm. This cannot always be performed and pancreaticoduodenectomy may be required. Larger aneurysms have a 50% mortality rate<sup>2</sup>.

In this case, there was complete occlusion of the coeliac axis and the pancreaticoduodenal artery was its main collateral (Figure 2). There have been only two previous reports of true pancreaticoduodenal artery aneurysms rupturing into the pancreatic duct system when this abnormality is present<sup>2,9</sup>. These aneurysms require repair not excision in order to maintain circulation to the gut. Unfortunately, this was technically impossible.

#### References

- 1 Stanley JC. Splanchnic artery aneurysms. In: Rutherford RB, ed. *Vascular surgery*. Philadelphia: WB Saunders Co, 1977:673
- 2 West JE, Berhardt H, Bowers RF. Aneurysms of the pancreaticoduodenal artery. *Am J Surg* 1968;115:835-9
- 3 Stanley JC, Thompson NW, Fry WJ. Splanchnic artery aneurysms. *Arch Surg* 1970;101:689
- 4 Weicher WA, Fox P, Brooks JW, Vinik M. The roentgenographic diagnosis of aneurysm of the superior mesenteric artery. *Am J Roentgenol* 1970;109:138-42
- 5 Borlaza G, Seigal R, Eckhauser FE. CT and angiographic demonstration of a gastroduodenal pseudoaneurysm in a pancreatic pseudocyst. *J Comput Assis Tomogr* 1979;3:612-15
- 6 Retzlaff JA, Hagedom AB, Bartholomew LG. Abdominal exploration for gastrointestinal bleeding of obscure origin. *JAMA* 1961;177:104-7
- 7 Spanos PK, Kloppedal EA, Murray CA. Aneurysms of the gastroduodenal and pancreaticoduodenal arteries. *Am J Surg* 1974;127:345-8
- 8 Small DJ, Houghton PWJ, Mortensen NJMcC. True aneurysm of the pancreaticoduodenal artery: a rare cause of retroperitoneal bleeding and delayed diagnosis. *Br J Surg* 1988;75:721
- 9 Gangahar DM, Carreth SW, Rees HE, Buchman RJ, Breiner MA. True aneurysms of the pancreaticoduodenal artery: a case report and review of the literature. *J Vasc Surg* 1985;2:741-2

(Accepted 9 November 1992)

## Mumps virus meningoencephalitis complicated by subarachnoid haemorrhage

H Hamdan MB BCh

D Carrington BSc DTM&H MRCPath<sup>1</sup>

R F Gledhill BSc MD MRCP Neurosciences

Department, Rashid Hospital, Dubai, United Arab Emirates and <sup>1</sup>the Bacteriology Department, Royal Infirmary, Glasgow UK

**Keywords:** mumps virus; meningoencephalitis; subarachnoid haemorrhage

Subarachnoid haemorrhage (SAH) is a well recognized, albeit occasional, complication of viral encephalitis<sup>1</sup>. We are not aware, however, of published accounts describing SAH complicating meningoencephalitis where mumps virus was the responsible agent.

#### Case report

A 35-year-old man was seen on 14 March 1990, earlier that day he had become drowsy. There was a 2-week history of fever and rigors, followed by unilateral scrotal swelling. Worsening headache and intermittent vomiting had been

present for 6 days. A family member reputedly had mumps sialadenitis in late February.

At presentation, the temperature was 36°C, pulse 56 per min and blood pressure 110/65 mmHg. The left scrotum was swollen without testicular tenderness. Neurologic examination was remarkable for obtundation and bilateral papilloedema. Signs of meningeal irritation were absent. Routine blood studies disclosed  $18 \times 10^9/l$  white cells with 86% polymorphs.

Cranial computed tomography on 16 March revealed blood in the interhemispheric fissure. Lumbar puncture yielded uniformly blood stained cerebrospinal fluid (CSF) containing a xanthochromic supernatant,  $8300 \times 10^6/l$  red cells,  $700 \times 10^6/l$  white cells, with polymorphs 21% and lymphocytes 79%, and 0.91 g/l protein. Four vessel angiography 3 days after admission and again 1 month later was normal. Normal or negative results were obtained for tests of haemostasis and coagulation, treponemal serology and antinuclear antibodies.

Specimens taken on 21 March were positive by complement fixation for antibody to mumps virus S and V antigens, in serum at 1 : 1 024 and in CSF at 1 : 64. The albumin concentrations in serum and CSF were, respectively, 41 g/l and 0.43 g/l, yielding an antibody index (CSF antibody : serum antibody/CSF albumin : serum albumin<sup>2</sup> of 5.9 (<1.5 in health<sup>3</sup>). Mumps specific immunoglobulin (IgM) was tested in serum and found positive. Concurrent IgG and IgM titres against cytomegalovirus and herpes simplex, varicella zoster and measles virus were all <1 : 8 in both serum and CSF.