

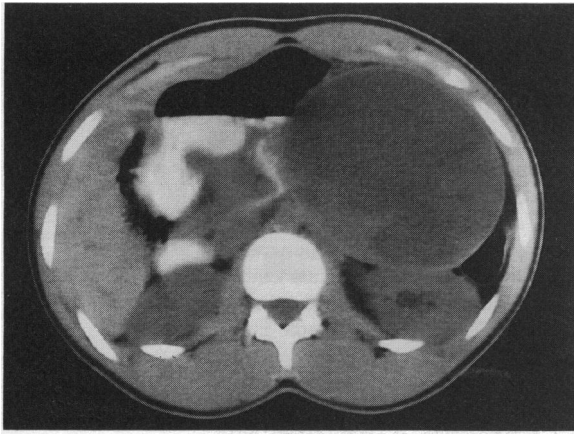Figure 1. Computerized tomography scan showing a mass in the tail of the pancreas

tissue was normal. The tumour cells were polygonal, monomorphic, and contained prominent eosinophilic granules. Few mitotic figures and no nuclear pleomorphism were seen.

The histological appearance suggested a papillary cystic neoplasm (PCN) of the pancreas.

Discussion

PCN of the pancreas was first described by Frantz¹, and approximately 100 cases have been reported². PCN usually occurs in young women³ and accounts for 1% of exocrine pancreatic tumours. At least 50% of reported cases have been women of African origin.

Elevated levels of type II oestrogen receptors have been reported⁴. This is unusual but not unique in visceral tumours. Immunohistochemical studies have reported elevated levels of α -1 antitrypsin. Alpha-1 antitrypsin is synthesized in the liver in response to oestrogen⁵ and occurs in ovarian mesodermal tumours, with a similar distribution to that of PCN⁶.

The histological appearances suggest a benign tumour, but local invasion of the surrounding tissues occurs in 16% of cases, and liver metastases in 7% of cases². There are at least two reports of tumour related deaths due to widespread abdominal metastases⁷, both in older patients³.

PCN is a tumour of low grade malignancy. A more aggressive form has been described with a different age and sex distribution⁷. Classical PCN has a good prognosis, and resection usually results in a complete cure. The origin of PCN remains controversial. Both exocrine and endocrine cell markers have been observed^{6,8}. Undifferentiated stem cell markers⁸ suggest that it may develop from a pluripotent stem cell. Recent reports favour a pleuripotent embryological origin for this tumour⁷. The predominantly young female distribution of this tumour suggests oestrogen and progesterone may have a role in its pathogenesis.

Acknowledgments: We thank Mr P W Crane and Dr H Rees for their help and support in the preparation of this case, and Mr R K S Philips for his permission to present his patient.

References

- 1 Frantz VK. Tumours of the pancreas. In: Blumberg CW, ed. *Atlas of Tumour Pathology*, Series 1, fascicles 27 & 28. Washington DC: Armed Forces Institute of Pathology, 1959:32-3
- 2 Sclafani LM, Reuter VE, Coit DG, Brennan MF. The malignant nature of papillary and cystic neoplasm of the pancreas. *Cancer* 1991;**68**(1):153-7
- 3 Matsunou H, Konishi F. Papillary cystic neoplasm of the pancreas, a clinico-pathologic study concerning tumour ageing and malignancy of 9 cases. *Cancer* 1990;**65**(2):283-91
- 4 Carbone A, Ranelletti F, Rinelli A, Vecchio F, Lauriola L, Piantelli M, et al. Type II oestrogen receptors in papillary cystic tumour of the pancreas. *Am J Clin Pathol* 1989;**92**:572-6
- 5 Ladanyani M, Mulay S, Arseneau J, Betterz P. Oestrogen and progesterone receptor determination in the papillary cystic neoplasm of the pancreas. *Cancer* 1987;**60**(7):1604-11
- 6 Morohosi T, Kanda M, Home A, Chott A, Dreyer T, Klöppel G, et al. Immunocytochemical markers of uncommon pancreatic tumours: Acinar cell carcinoma, pancreaticoblastoma and solid-cystic (papillary-cystic) tumour. *Cancer* 1987;**59**(4):739-47
- 7 Matsunou H, Konishi F, Yamamichi N, Takayanagi N. Solid infiltrating variety of papillary cystic neoplasm of the pancreas. *Cancer* 1990;**65**(12):2747-57
- 8 Miettinen M, Partanen S, Fraki O, Kwilaakso E. Papillary cystic tumour of the pancreas: An analysis of cellular differentiation by electron microscopy and immunohistochemistry. *Am J Surg Pathol* 1987;**11**(11):855-65

(Accepted 27 September 1993)

Liquefying panniculitis associated with acinous carcinoma of the pancreas responding to octreotide

M J Hudson-Peacock BSc MRCP¹

C F B Regnard MBChB BMSc² P M Farr MD MRCP¹

¹Department of Dermatology, Royal Victoria Infirmary, Newcastle upon Tyne and ²Palliative Medicine, St Oswald's Hospice, Newcastle upon Tyne

Keywords: panniculitis; carcinoma; pancreas; octreotide

Introduction

Panniculitis has been associated with both polyarthropathy and a wide range of pancreatic disorders¹. Although resolution of panniculitis can occur with control of the

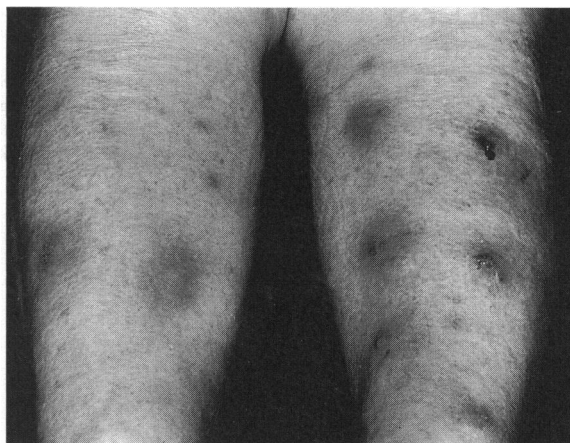

Figure 1. Multiple inflammatory nodules on the legs

pancreatic disease, this is usually not possible with pancreatic carcinoma. We present a patient in whom such control was achieved with octreotide, a somatostatin analogue.

Case presented to
Section of
Dermatology,
21 January 1993

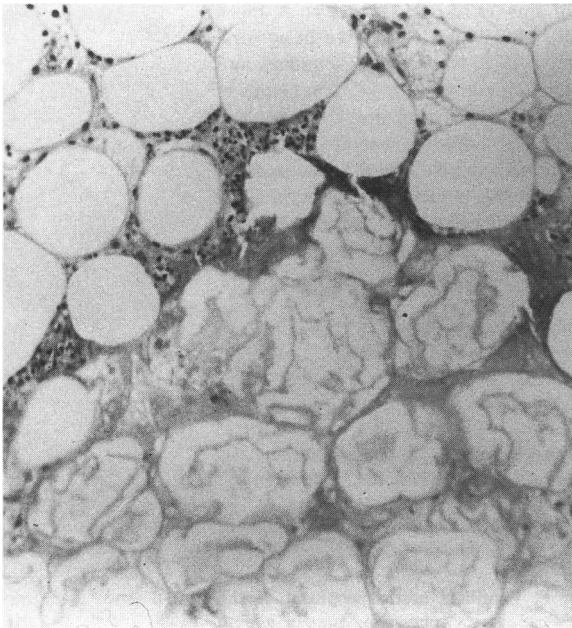


Figure 2. Skin biopsy (of a nodule) showing an area of subcutaneous fat necrosis with the characteristic ghost-like fat cells

Case report

A previously well 79-year-old woman was admitted with a 4-month history of tender nodules affecting the lower legs, and recent onset of localized joint tenderness and malaise. Examination showed multiple subcutaneous inflammatory nodules on the legs in various stages of evolution (Figure 1). Some of the larger lesions were necrotic and exuded a viscous fatty material. Early nodules were palpable with no surface change. Non-tender masses were palpable in the epigastrium and right upper quadrant. Localized tenderness was present over the right upper femur and in a number of foot joints associated with overlying nodules. Subsequently she developed tenderness in the ankles and elbows.

Skin biopsy showed subcutaneous fat necrosis without vasculitis but with a mixed inflammatory cell infiltrate that surrounded ghost-like fat cells with indistinct walls and no nuclei (Figure 2). Abdominal ultrasound showed a cavitating 8 cm mass in the tail of the pancreas and a 6 cm solid mass between the right and left lobes of the liver. An ultrasound-guided biopsy of the pancreatic mass revealed poorly differentiated adenocarcinoma. Other investigations, including serum amylase measured on four occasions and 24-h urinary amylase were normal.

During investigation the patient continued to develop further painful nodules on a daily basis on the legs, trunk and arms, and especially over bony prominences. They did not respond to 30 mg prednisolone daily for 6 days. Within 24-h of starting octreotide 50 µg twice-daily by subcutaneous injection, no new nodules appeared. Although she subsequently deteriorated and died of metastatic disease 3 weeks later, no new nodules appeared during this time.

An autopsy confirmed the diagnosis of pancreatic carcinoma and showed it to be of the acinous type. In addition, a

metastatic deposit in the neck of the right femur, a right deep venous thrombosis and small pulmonary emboli were found.

Discussion

Nodular liquefying panniculitis with associated ghost cells seen on histology can occur as a result of any pancreatic disease including pancreatitis, pancreatic carcinoma¹ and developmental anomalies such as a pancreatic divisum². The original association of panniculitis and pancreatic disease was reported in 1883 by Chiari³ and the association of polyarthropathy, panniculitis and pancreatic carcinoma described in 1908 by Berner⁴. The latter syndrome is not common with fewer than 25 cases reported, and of these only three were women. In only two patients was control of panniculitis achieved, and this followed 5-fluorouracil treatment in one⁵, and combination chemotherapy with bleomycin, adriamycin, cyclophosphamide, oncovin and prednisolone in the other¹.

The pathogenesis of the subcutaneous fat necrosis has not been fully explained, but probably involves release of amylase, trypsin and lipase from the pancreas⁶. Whether these enzymes reach the tissues via the circulation or lymphatics or a combination of both is not known. The current hypothesis is that the permeability of subcutaneous blood and lymph vessels are altered by trypsin, allowing lipase to enter fat cells where it converts neutral fats into free fatty acids and glycerol with resultant fat necrosis^{2,7}.

Octreotide is a long acting octapeptide of somatostatin with a number of properties including reduction of pancreatic enzyme output⁸. That no new nodules appeared from the day after treatment was started with octreotide until the patient's death 3 weeks later, provides further supportive evidence for the causative role of pancreatic enzymes in the fat necrosis associated with pancreatic disease, and suggests that octreotide may offer a means of controlling this process.

References

- 1 Tannenbaum H, Anderson LG, Schur PH. Association of polyarthrits, subcutaneous nodules and pancreatic disease. *J Rheum* 1975;2:14-20
- 2 Haber RM, Assaad DM. Panniculitis associated with a pancreas divisum. *J Am Acad Dermatol* 1986;14:331-4
- 3 Chiari H. Uber die sogenannte Fettnekrose. *Prager Med Wschr* 1883;8:285-6
- 4 Berner O. Subkutane Fettgewebsnekrose. *Virchow Arch Pathol Anat* 1908;193:510-18
- 5 Good AE, Schnitzer B, Kawanishi H, Demetropoulos KC, Rapp R. Acinar pancreatic tumour with metastatic fat necrosis. Report of a case and review of rheumatic manifestations. *Am J Dig Dis* 1976;21:978-87
- 6 Sibrack LA, Gouterman IH. Cutaneous manifestations of pancreatic diseases. *Cutis* 1978;21:763-8
- 7 Hughes PSH, Apisarnthanarax P, Mullins JF. Subcutaneous fat necrosis associated with pancreatic disease. *Arch Dermatol* 1975; 111:506-10
- 8 Battershill PE, Clissold SP. Octreotide. A review of its pharmacodynamic and pharmacokinetic properties, and therapeutic potential in conditions associated with excessive peptide secretion. *Drugs* 1989;38:658-702

(Accepted 4 October 1993)