

Section Meetings

Management of empyema thoracis

John A Odell ChB FRCS(Ed) *Department of Cardiothoracic Surgery,
Mayo Clinic, Rochester, MN 55905, USA*

Keywords: empyema thoracis; drainage of empyema; decortication

Definitions

An empyema thoracis is simply a collection of pus in the pleural space. Some have tried to define it differently, but this is unnecessary; many term a parapneumonic effusion associated with bacterial pneumonia, lung abscess, or bronchiectasis an empyema whereas others state that only parapneumonic effusions with positive pleural fluid cultures can be called an empyema¹. Likewise, others use the term 'complicated parapneumonic effusion' to refer to those effusions that do not resolve without tube thoracostomy¹. Another term that is frequently used, particularly in regions where tuberculosis is common, is the term 'tuberculous empyema'. However, we do not normally classify a straw-coloured effusion from which tubercle bacilli are isolated as an empyema, nor do we often find thick caseous tuberculous pus within the pleura (this is invariably a tuberculous lobar pneumonia which has been intubated percutaneously because of difficulty in radiographic interpretation). What is frequently meant by a 'tuberculous empyema' is a bacterial empyema complicating active or previous tuberculosis.

An empyema may be associated with positive bacterial cultures or may even be sterile. The diagnosis does not require any complicated tests such as glucose, LDH, pleural pH or leukocyte count (it is obvious to the naked eye!). If reliance on laboratory investigations influences management then patients with rheumatoid pleurisy, tuberculosis, malignancy or lupus pleuritis may be inadequately managed by intercostal drainage. The only investigations necessary are fluid and, if obtained, a pleural biopsy, sent for bacteriological and histological examination. Occasionally chylothorax, because of its appearance, can be confused with empyema but this condition usually occurs in specific circumstances.

The confusion in terminology probably is a result of the stages in evolution of any empyema. The first stage is an exudative phase in which a focus of infection adjacent to the visceral pleura leads to increased permeability of the visceral pleura and the accumulation of a small usually sterile parapneumonic effusion. The pleural fluid is an exudate in which leukocytes may be found. For those who investigate, the glucose is normal as is the pH. Occasionally, the septic lung focus adjacent to the pleura may rupture directly into the pleural space; if it communicates with a bronchus a broncho-pleural fistula develops. The second stage, the fibrinopurulent stage, is characterized by a much larger fluid collection which is obviously pus (it contains many polymorphonuclear leukocytes, bacteria and cellular debris). Of importance is a tendency for fibrin to be deposited on both the visceral and parietal pleura and a tendency for

loculation, particularly posteriorly. The pleural fluid pH and glucose level become progressively lower and the LDH level increases. In the third or organizational stage, fibroblasts grow into the exudate from both the visceral and parietal pleural surfaces to produce an inelastic membrane called the pleural peel or cortex.

Historical perspective

Those cases of empyema or dropsy which are treated by incision or the cautery, if the water or pus flows rapidly all at once, certainly prove fatal.

When empyema is treated either by the cautery or incision, if pure and white pus flow from the wound, the patients recover, but if mixed with blood, slimy and fetid they die.
*Hippocrates*²

Cardiothoracic surgery probably began with the management of empyema. Most empyemas were associated with pulmonary infection and sometimes became obvious when pus discharged spontaneously from the chest wall (an empyema necessitans or necessitatis or, in modern terms, a pointing empyema).

Those early physicians involved with medical treatment determined the exact site for surgical drainage by establishing the maximal site of pain, or by smearing the chest with potters clay. The site that dried first, the hottest and most inflamed, was chosen then as the site of drainage. Early chest drains used were hollow reeds.

Hippocrates described drainage of an empyema and he recognized the smell of anaerobic infection and its association with a poor prognosis². The Greek physicians at that time had advanced the techniques of managing empyema to include early diagnosis, irrigation and placement of an indwelling tube. These techniques became the standard of care for over two millennia.

Little therapeutic progress beyond open drainage was made until the 19th century, when needles to locate and aspirate an empyema were developed³, and drainage of the chest with an underwater seal was introduced⁴. It was soon realized that drainage was sometimes more effective after resection of a portion of rib. Thoracoplasty as a form of treatment for empyema was pioneered⁵; and the operation of decortication, which was discovered almost by accident⁶, was further developed⁷. Decortication enjoyed a vogue after the First World War, only to fall into disuse until revived during the Second World War^{8,9}. Only with the introduction of basic anaesthetic techniques, an understanding of the dangers of an open pleural cavity that had not been made rigid by fibrin deposition and the use of antimicrobial therapy did real progress in the management of empyema occur.

One surgeon, Evarts Graham, stands as one of those, who advanced considerably our understanding

Paper read to
Cardiothoracic
Section,
27 May 1993

of empyema^{10,11}. In 1918 he was appointed to the US Army Empyema Commission which was charged to investigate the high mortality, averaging 30.2%, but ranging as high as 70% or more, in camps where open drainage was standard practice. He defined the difference between pneumococcal and streptococcal empyema: pneumococcal empyema tended to occur late in the course of pneumococcal pneumonia and be associated with thick and creamy pus whereas streptococcal empyema occurred earlier in the phase of the disease when the pleural exudate was serofibrinous.

Early open drainage as practised at that time frequently led to collapse of the lung from pneumothorax which, superimposed upon pneumonia, was often fatal. When the principles Dr Graham elucidated were applied by the Empyema Commission, the mortality was reduced to 3.4%. The essential points of these new principles were: (1) careful avoidance of an open pneumothorax in the acute stage; (2) the prevention of a chronic empyema by the rapid sterilization and obliteration of the infected cavity; and (3) careful attention to the nutrition of the patient.

Aetiology of empyema

An empyema follows infection of the structures surrounding the pleural space; an infection solely of the pleural space probably does not occur.

In the lung, empyema commonly follows pneumonia but may also be associated with lung abscess and bronchiectasis. Lung abscess usually elicits an inflammatory pleuritis over the adjacent pleura that obliterates the pleural space and lessens the likelihood of empyema, but, if the lung abscess is particularly acute and the organisms virulent, the abscess may rupture into the pleural space before obliteration has occurred, producing a pyopneumothorax or empyema. In the vast majority of patients with bronchiectasis the pleural space is also obliterated but there are exceptions and in this situation empyema is possible. In both bronchiectasis and lung abscess an empyema can develop on the contralateral side presumably because of aspiration of pus and the development of a subpleural pneumonia.

In some communities trauma is the most frequent cause of empyema. During the First World War and the early part of the Second World War empyema occurred in 25-30% of all thoracic casualties but decreased to 6% among thoracic casualties in Vietnam^{12,13}. The frequent finding of resistant organisms in empyema fluid that follows chest trauma suggests that this may be associated with poor techniques of chest intubation rather than a contaminated weapon.

An empyema may be associated with infection below the diaphragm (a liver abscess, either pyogenic or amoebic, or a subphrenic abscess). Interestingly, empyema does not result in subdiaphragmatic infection, probably because of the cranial direction of the lymphatics and the negative intrathoracic pressure compared to the abdominal cavity.

Mediastinal infection may result in an empyema. The most common example is rupture of the oesophagus. The patient usually has a characteristic history and clinical signs, but occasionally patients are seen late in the disease and the diagnosis only suspected after food contents are drained from the pleural space. Mediastinitis and empyema may also follow infections of the head and neck¹⁴⁻¹⁶.

Management

The patient with an empyema may have variable symptoms difficult to distinguish from those of the primary provocation, whether this be 'pneumonia', mediastinitis, subphrenic abscess or posttraumatic haemothorax. He may be virtually asymptomatic or may be frankly toxic, depending upon the causal organisms, the volume of pus within the pleural space and the host defence mechanisms. Other features result from occupation of the pleural space: dyspnoea; diminished movement of a hemithorax; dullness to percussion; diminished breath sounds; and, if the empyema is large, displacement of the mediastinum to the opposite side.

The patient with a bronchopleural fistula gives a distinctive history - whenever he lies on the side opposite to the empyema he coughs excessively and the volume of pus produced is frequently large. The patient with a pointing empyema characteristically has a discharging sinus or a chest wall swelling that may be confused with an abscess. Most pointing empyemata are associated with tuberculosis: if associated with trauma or previous chest surgery this may occur at any site where the chest wall was previously breached. The patient with an amoebic empyema usually has a painful tender liver.

A relatively asymptomatic patient may be referred with an opacity on the chest radiograph that raises the possibility of empyema, but the differential diagnosis may include pleural tumor, pulmonary tumor or even hydatid disease. Occasionally, pus may be loculated (encysted, fissural, mediastinal, subpulmonary). The appropriate first investigation in this patient is ultrasound or computerized tomography (CT) examination to determine as far as possible the nature of the opacity. Hydatid disease is obvious: it has a density approximating water: a tumour has a solid density; an empyema is of variable density and a fluid component is usually present. Recently using CT examination attenuation in the extrapleural tissues has been described in association with empyema^{17,18}. Occasionally, by CT or ultrasound, it is impossible to differentiate tumor from empyema and some clinicians would aspirate at this point to obtain a diagnosis; others would proceed direct to thoracotomy if the patient was fit and the tumour thought resectable.

Some assessment of the underlying lung is essential if major surgery such as decortication is planned. An investigation frequently undertaken previously, in the relatively asymptomatic patient with a radiographic opacity compatible with an empyema, or patients who have had an empyema previously drained, was bronchography. It was argued that decortication of an empyema would be inappropriate and unsuccessful if the underlying lung was abnormal and bronchiectatic: the patient would still be at risk of the complications of bronchiectasis and more importantly the underlying lung would not readily expand and obliterate the space after decortication. The correct operation in these circumstances is pulmonary resection plus decortication. Although in theory this is the right approach there are disadvantages. If the opacity is large and dense interpretation of a bronchogram may be impossible and, sometimes the bronchi are so crowded together that the presence of normal or bronchiectatic lung cannot be excluded. Today the concern about bronchography no longer prevails

because a suitable bronchographic agent no longer exists. The manufacture of Dionisol has been stopped and bronchography can no longer be done safely. CT scanning is said to be adequate for the diagnosis of bronchiectasis but one requires expensive equipment, an experienced radiologist who needs to take multiple fine cuts of the lung and who understand the bronchial anatomy. CT scanning of the chest therefore should be considered prior to decortication, if the aetiology of the empyema could possibly be bronchiectasis or lung abscess. All too frequently the surgeon is told that underlying bronchiectasis is present but not the distribution of bronchiectasis. The procedure has become analogous to exercise testing in ischaemic heart disease: one can prove it exists but the surgeon does not know which vessel to graft.

In the majority of patients the diagnosis is obvious. The patient is ill and pyrexial, he may have a productive cough, a leucocytosis and chest pain. The chest radiograph is, in the vast majority, characteristic - a posterior D-shaped opacity that invariably reaches the hemidiaphragm. The diagnosis is confirmed by needle aspiration at the site determined by the chest radiograph. The finding of 'anchovy sauce' pus, caseous material, a draining sinus, or pus that contains sulphur granules may suggest the diagnosis of amoebic, tuberculous, or actinomyces with the need for special culture techniques or other investigations.

Any delay in the correct management of empyema may lead to prolonged hospitalization and morbidity: the later the stage of the empyema, the more difficult and prolonged it is to treat. Too much reliance on antibiotics and aspiration rather than well established principles, in the belief that this avoids 'painful and dangerous' surgical interventions, may, in fact, worsen the situation.

Further management depends upon the consistency of the pus and the state of the patient and is shown diagrammatically in Figure 1. If the pus is thin a large closed intercostal drain is inserted. If the pus is thick fibrin and pus will not drain effectively, then either rib resection (open drainage) or decortication is necessary. What determines whether the patient should have a decortication or a rib resection depends upon the state of the patient. A toxic ill patient, and included in this category is the patient with a broncho-pleural fistula, and the patient obviously unfit for major surgery is managed by open drainage.

Open drainage of an empyema does not exclude the patient from later management by decortication if the patient's condition improves.

The underlying cause of the empyema should be treated at the same time as the empyema. Pneumonia usually responds to appropriate antibiotics. A lung abscess in association with an empyema requires separate drainage of the abscess and empyema. This is usually done as an open procedure. A soft de Pezzar drain is placed in the centre of the abscess and the pleura separately drained¹⁹. The abscess usually decreases in size quite rapidly. Bronchiectasis should be resected at the same time as decortication, or if total unilateral bronchiectasis is present a pneumonectomy should be performed through the empyema space²⁰. This rather radical procedure offers the only chance of cure: although postoperative empyema is likely, it is not inevitable²⁰. Subphrenic collections of pus should be separately drained. Oesophageal rupture can be managed using various methods, the discussion of which is outside the scope of this article. The empyema cannot be cured unless the oesophageal leak is controlled. Wide drainage of the mediastinum and dependent drainage of the pleural space through a thoracotomy is usually necessary.

Drainage

Drainage, whether closed or open should be done at the most dependant site of the empyema collection. The exact site may be determined after the installation of oily Lipiodal into the empyema cavity. Invariably this is at the angle of the eighth or ninth rib posteriorly. The technique of drainage is well described by Le Roux *et al.*¹⁹.

If a visceral fibrin layer has not formed, exposure of the empyema cavity to atmospheric pressure will result in collapse of the underlying lung. This possibility must be considered at the time of rib resection. If movement of the underlying lung is present the 'open drain' must be converted to a closed system by suturing the skin layers closed around the drain. It may later be converted to an open system within a few days, once a fibrin layer has formed.

Drains are removed only when drainage is minimal and obliteration of the pleural cavity as judged by serial chest radiographs and the use of sinograms has occurred. In patients drained during the exudative phase, obliteration occurs within days. In those patients drained later, this takes longer. In adult patients with a thick restrictive cortex managed only by open drainage, obliteration of the empyema space may take 3 months or longer²¹. In children obliteration occurs more rapidly and is measured in weeks. Obliteration takes place by adherence of the parietal and visceral cortex at the periphery of the empyema space and the formation of granulation tissue. Once the two layers of fibrin are adherent absorption of the fibrin takes place. Despite good open drainage, the space may become loculated during healing and exudate trapped may cause recurrence of symptoms of infection.

The patient initially managed by closed intercostal drainage usually improves dramatically within 24 to 48 h. If his clinical condition does not improve and if the chest radiograph demonstrates incomplete evacuation of pleural pus, possibly because of loculation or fibrin formation the patient may require rib resection and open drainage. In patients with multiple

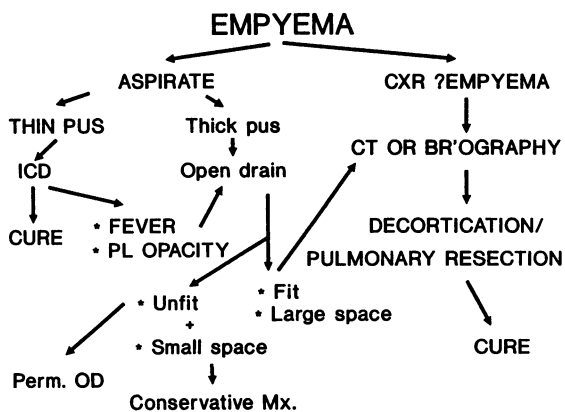


Figure 1. Flow diagram demonstrating how empyema is managed. CXR=Chest X-ray; ICD=intercostal drain; CT=computerized tomography; Br'ography=bronchography; PL=pleura; Perm. OD=permanent open drain; Mx=mix

pleural fluid levels, 'the disorganized pleural space' management is best done by an open procedure as loculi and adhesions need to be broken down.

There is a group of patients including, the elderly unfit patient with a large empyema space or the patient with a calcified empyema, in whom management is best suited by the creation of a permanent open drain (Eloesser flap)²². In this procedure flaps are created in order to line the drainage tract with skin. This obviates the need for chest tubes to maintain patency of the drainage tract and prevents premature closure.

Antibiotic therapy

Although antibiotic therapy has definitely improved the outlook of patients with empyema the principles of treatment that were learned by hard-won experience in the preantibiotic era should not be forgotten. Reliance on antibiotics may in fact delay appropriate surgical intervention and prolong morbidity.

Aminoglycosides concentrations are not detected in pleural pus after systemic administration either because they do not penetrate the blood-pleural barrier in empyema or are bio-inactivated by the pleural pus^{23,24}. It is possible that this situation exists with other antibiotics. Ciprofloxacin, however, has been shown to penetrate the pleural space easily and achieve concentrations well above the MIC90 of most pathogens normally associated with empyema²⁵.

The prime object of management is therefore drainage of the pus. If this has been adequate there is little need for long-term antibiotic therapy. Antibiotics are used until defervescence has occurred (usually within a week) and as perioperative cover during a surgical procedure. The selection of the appropriate antibiotic is based on the Gram stain of pleural fluid, culture of aspirated fluid or sputum and of the likely organism if cultures or Gram stain are unhelpful. In the intervening period while awaiting results a broad spectrum antibiotic effective against anaerobes and aerobes should be used.

There are isolated reports of the instillation of antibiotics²⁶, antiseptics^{27,28} and streptokinase^{1,29,30} into the empyema space: presently there is no general agreement on their use.

Decortication

This procedure involves a full thoracotomy with removal of all pus and fibrous tissue from the visceral pleura. It is a major procedure and should not be performed on patients who are debilitated, either from the empyema, the underlying pathological process or age. In patients with post traumatic empyema it can safely be assumed that the underlying lung is, in the vast majority, normal. In other patients the underlying lung should be assessed by CT scanning to exclude bronchiectasis or lung abscess. If there is bronchiectasis this should be resected at the same procedure. A rigid bronchoscopy is done at the induction of anaesthesia to exclude an empyema complicating a foreign body or a malignant tumour obstructing a lobar of main stem bronchus. If a tumour is observed it is best to abandon the procedure and carefully reevaluate the patient.

It is not necessary to remove the parietal pleura at decortication as the underlying lung more readily fills the space and the parietal pleural peel absorbs with time³¹. Removal of the parietal cortex, especially if chronic, may be associated with excessive bleeding. There are exceptions: the parietal cortex is removed

in a patient with a long-standing empyema associated with crowding of the ribs and scoliosis. In these patients, the parietal cortex may inhibit chest wall movement and expansion of the decorticated lung.

If decortication fails and the lung does not expand to fill the pleural space an open drainage procedure and conservative management is pursued. In these patients the underlying lung is likely to be abnormal and should be carefully reassessed. Repeat decortication is seldom worth while.

There is considerable debate, particularly, of the correct management of childhood empyema, concerning the merits of early decortication versus open drainage³². Many believe that postoperative hospital stay is reduced if early decortication rather than open drainage is performed. Using the approach advocated management does not involve a choice: those that are fit are managed by decortication; those unfit or ill are managed by a drainage procedure. In children, rapid defervescence rapidly follows drainage and the child can often be discharged within a week or two. It must be appreciated that radiographic improvement lags behind clinical improvement and the temptation to continually seek radiographic improvement by physical means must be resisted.

Other surgical options

Empyectomy

This refers to a specific manoeuvre - the complete excision of a small empyema without spillage of pus. A previous drainage procedure or the presence of a broncho-pleural fistula precludes this operation. Operative details have been well described by Dugan and Samson³³. Dissection is begun in the extrapleural plane and when the edges of the empyema sac are reached, the surgeon 'turns the corner' and then decorticates the inner surface of the empyema from the visceral pleura. Dissection is particularly difficult over the diaphragm where the endothoracic fascia is thin and the extra pleural plane poorly developed.

Microvascular free muscle flaps

There are patients in whom multiple previous operations to deal with a chronic empyema, usually with a broncho-pleural fistula, have failed. Under normal circumstances the use of a muscle flap would be considered but if the local muscles have been divided at previous thoracotomies, these muscles are frequently small and atrophied. In these circumstances Chen *et al.*³⁴ have used microvascular free muscle flaps. Contralateral latissimus dorsi and the lower four digitations of serratus anterior are mobilized on the same vascular pedicle, namely the thoracodorsal artery and vein. These muscle flaps are then anastomosed to the remnants of the thoracodorsal artery and vein on the affected side. He states these vessels are easily found³⁹. His results in his small series are excellent. The fistula is closed and the empyema space is obliterated.

'Clagett' open-window thoracostomy

An option that may be considered in patients unwilling or unable to cope with a permanent open drain, in whom decortication is undesirable or unsuccessful, is the procedure initially described by Clagett and Geraci³⁵ for management of postpneumonectomy empyema. The same principles may be used for patients with an empyema who have had a limited or no previous pulmonary resection. Results appear

to be better compared to a postpneumonectomy group³⁶.

Thoracoplasty

The purpose of thoracoplasty is to remove the rigidity of the outer chest wall and so establish contact between the now flexible chest wall and either residual lung; or, after pneumonectomy, with the mediastinum in order to obliterate the empyema space. The procedure is rarely undertaken today because of the deformity that results and the success of other forms of management.

References

- 1 Light RW. Parapneumonic effusions and empyema. *Clin Chest Med* 1985;**6**:55-62
- 2 Hippocrates. In: *Classic Descriptions of Disease by RH Major*. Springfield Illinois: Charles C Thomas Publisher, 1965:568-9
- 3 Atwate EC, Morrill Wyman and the aspiration of acute pleural effusions. 1850. A letter from New England. *Bull Hist Med* 1972;**36**:235-56
- 4 Hewitt C. Drainage of an empyema. *BMJ* 1876;**1**:317
- 5 Estlander JA. Sur le resection des côtes dans l'empyème chronique. *Rev Mens* 1897;**8**:885-8
- 6 Fowler GR. A case of thoracoplasty for the removal of a large cicatricial fibrous growth from the interior of the chest, the result of an old empyema. *Med Rec* 1883; **44**:838-9
- 7 Délorne E. Nouveau traitement des empyèmes chroniques. *Gaz Hop* 1894;**67**:94
- 8 Burford TH, Parker EF, Samson PC. Early pulmonary decortication in the treatment of posttraumatic empyema. *Ann Surg* 1945;**122**:163-90
- 9 Samson PC, Burford TH. Total pulmonary decortication; its evolution and present concepts of indications and operative technique. *J Thorac Surg* 1947;**16**:127-45
- 10 Olch PD. Everts A Graham in World War 1: The Empyema Commission and service in the American Expeditionary Forces. *J Hist Med Allied Sci* 1989; **44**:430-46
- 11 Peters RM. Empyema Thoracis: Historical perspective. *Ann Thorac Surg* 1989;**48**:306-8
- 12 Levitsky S, Annable CA, Thomas PA. The management of empyema after thoracic wounding: observations on 25 Vietnam casualties. *J Thorac Cardiovasc Surg* 1970; **5**:630-4
- 13 Patterson LT, Schmitt HJ, Armstrong RG. Intermediate care of war wounds of the chest. *J Thorac Cardiovasc Surg* 1968;**55**:16-23
- 14 Lalwani AK, Kaplan MJ. Mediastinal and thoracic complications of necrotising fasciitis of the head and neck. *Head Neck* 1991;**13**:531-9
- 15 Hussan WU, Keaney NP. Bilateral thoracic empyema complicating adult epiglottitis. *J Laryngol Otol* 1991; **105**:858-9
- 16 Chong WH, Woodhead MA, Millard FJ. Mediastinitis and bilateral thoracic empyemas complicating adult epiglottitis. *Thorax* 1990;**45**:491-2
- 17 Takasugi JE, Godwin JD, Teefey SA. The extrapleural fat in empyema: CT appearance. *Br J Radiol* 1991; **64**:580-3
- 18 Waite RJ, Carbonneau RJ, Balikian JP, Umali CB, Pezzella AT, Nash G. Parietal pleural changes in empyema: appearance at CT. *Radiology* 1990;**175**: 145-50
- 19 Le Roux BT, Mohlala ML, Odell JA, Whitton ID. Suppurative disease of the lung and pleural space. Part I: empyema and lung abscess. *Curr Problems Surg* 1986;**23**:4-89
- 20 Odell JA, Henderson BJ. Pneumonectomy through an empyema. *J Thorac Cardiovasc Surg* 1985;**89**:423-7
- 21 Bartlett JG, Finegold SM. Anaerobic infections of the lung and pleural space. *Am Rev Respir Dis* 1974;**110**:56-77
- 22 Eloesser L. Recollections: Of an operation for tuberculous empyema. *Ann Thorac Surg* 1971;**11**:210
- 23 Thys JP, Vanderhoeft P, Herchuelz A, Bergmann P, Yourassowsky E. Penetration of aminoglycosides in uninfected pleural exudates and in pleural empyemas. *Chest* 1988;**93**:530-2
- 24 Bryant RE, Hammond D. Interaction of purulent material with antibiotics used to treat Pseudomonas infections. *Antimicrob Agents Chemother* 1974;**6**:702-7
- 25 Morgenroth A, Pfeuffer HP, Seelmann R, Schweisfurth H. Pleural penetration of ciprofloxacin in patients with empyema thoracis. *Chest* 1991;**100**:406-9
- 26 Holmes-Sellers T, Cruikshank G. Chronic empyema. *Br J Surg* 1951;**38**:411-32
- 27 Conlan AA, Abramor E, Delikaris P, et al. Taurolidine installation as therapy for empyema thoracis; a prospective study of 50 patients. *S Afr Med J* 1983; **64**:653-5
- 28 Hutter JA, Harari D, Braimbridge MV. The management of empyema by thoracoscopy and irrigation. *Ann Thorac Surg* 1985;**39**:517-20
- 29 Bergh NP, Ekroth R, Larsson S, Nagy P. Intrapleural streptokinase in the treatment of haemothorax and empyema. *Scand J Thorac Cardiovasc Surg* 1977; **11**:265-8
- 30 Aye RW, Froese DP, Hill LD. Use of purified streptokinase in empyema and hemothorax. *Am J Surg* 1991;**161**:560-2
- 31 Neff CC, van Sonnenberg E, Lawson DW, Patton AS. CT follow-up of empyemas: pleural peels resolve after percutaneous catheter drainage. *Radiology* 1990;**176**: 195-7
- 32 Kennedy AS, Agness M, Bailey L, White JJ. Decortication for childhood empyema. The primary provider's peccadillo. *Arch Surg* 1991;**126**:1287-91
- 33 Dugan DJ, Samson PC. Surgical significance of the endothoracic fascia: the anatomical basis for empyectomy and other extrapleural techniques. *Am J Surg* 1975; **130**:151-8
- 34 Chen H, Tang Y, Noodhoff MS, Chang C. Microvascular free muscle flaps for chronic empyema with bronchopleural fistula when the major local muscles have been divided - one-stage operation with primary wound closure. *Annals of Plastic Surg* 1990;**24**:510-6
- 35 Clagett OT, Geraci JE. A procedure for management of postpneumonectomy empyema. *J Thorac Cardiovasc Surg* 1963;**45**:141-5
- 36 Bayes AJ, Wilson JAS, Chiu RC-J, Errett LE, Hedderich G, Munro DD. Clagett open-window thoracostomy in patients with empyema who had and had not undergone pneumonectomy. *Canadian J Surg* 1987;**30**:329-31

(Accepted 3 November 1993)