

# Knee pain and the infrapatellar branch of the saphenous nerve

T D Tennent BSc FRCS N C Birch FRCS(Orth)<sup>1</sup> M J Holmes FRCS<sup>2</sup> R Birch FRCS<sup>2</sup> N J Goddard FRCS

*J R Soc Med* 1998;91:573-575

## SUMMARY

**Pain over the front of the knee is common after surgery or trauma but often a definite diagnosis is difficult to make. Over the past year we have seen five cases in which the pain could be ascribed to damage to a branch of the infrapatellar branch of the saphenous nerve. Two were subsequent to trauma and three to surgical procedures. In all five cases surgical exploration gave symptomatic relief. Eight cadaveric knees were prosected to explore further the anatomy of this nerve in relation to the injuries. Injury to one of these branches should be considered in cases of persistent anterior, anteromedial or anterolateral knee pain or neurological symptoms following surgery or trauma.**

## INTRODUCTION

After a direct blow or surgery, patients sometimes report chronic pain over the front of the knee. The pain may or may not be associated with the injury. Two patients have lately been seen at the Royal Free Hospital with localized anterior knee pain following an identifiable injury to the front of the knee. Both reported anteromedial pain and altered sensation over the anterolateral infrapatellar region of the knee. A further three patients with similar pain following surgery to the knee have been seen at the Peripheral Nerve Injury Unit at the Royal National Orthopaedic Hospital, Stanmore. All five patients underwent surgical exploration. In those with a history of trauma no neuroma was found but the symptoms resolved completely after neurolysis. In those whose pain followed surgery, neuromata were found. Excision of these gave pain relief but left an area of anaesthesia over the anterolateral aspect of the knee.

Although the infrapatellar branch of the saphenous nerve is well described in anatomical works<sup>1</sup> it receives little mention in surgical texts. We therefore dissected eight cadaveric knees to demonstrate the superficial neuroanatomy of the infrapatellar region.

## CASE HISTORIES

### Traumatic origin

Two patients developed pain subsequent to a direct blow to the front of the knee. The first was a 57-year-old taxi-driver

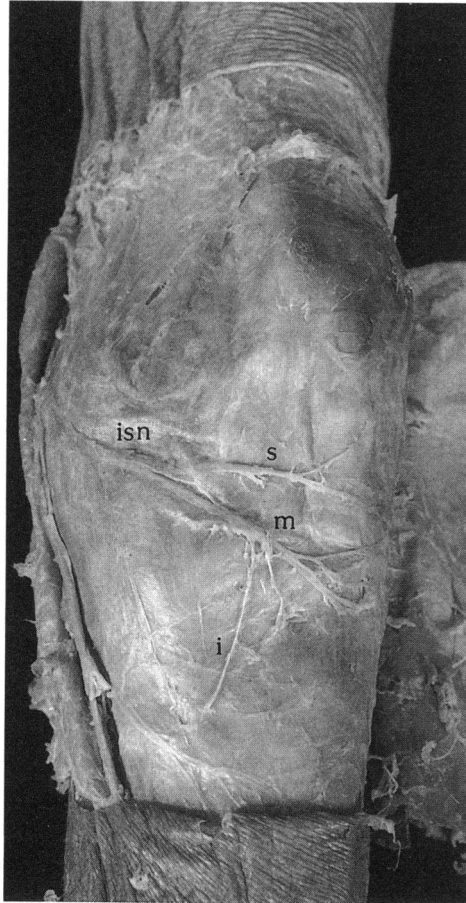
who sustained a 'dashboard' injury and the second a 30-year-old nurse who was struck on the anteromedial aspect of the knee with a lead pipe. Her symptoms had persisted for ten years. Both patients complained of a tender area over the anteromedial aspect of the knee with an area of numbness lateral to the patellar tendon. Both had a positive Tinel's sign over the tender area and injection of local anaesthetic and steroid into this area produced temporary symptomatic relief. In these patients the area of maximal tenderness was explored surgically under general anaesthesia with tourniquet control. No neuromata were found but neurolysis of the nerve gave immediate resolution of symptoms postoperatively.

### Surgical origin

The first postsurgical patient was a woman aged 50 with rheumatoid arthritis who had undergone a total knee replacement 4 years previously via an anterior approach. This was followed 2 years later by a patella resurfacing operation in which the old incision was reopened. After the second operation she complained of anteromedial pain and an area of hypersensitivity laterally. The second was a woman of 45 who developed a tender spot in the scar after an anterior cruciate ligament repair via an anterior approach. She had a positive Tinel's sign radiating laterally. The third was a 37-year-old woman who developed anteromedial knee pain after knee arthroscopy. She had a tender area related to the medial arthroscopy portal scar with a positive Tinel's sign radiating laterally. At surgical exploration under general anaesthesia with tourniquet control neuromas were found and excised in all three cases. Postoperatively all had relief of the pain and were left with an area of anaesthesia lateral to the patellar tendon.

Orthopaedic Department, Royal Free Hospital, London NW3 2QG, UK; <sup>1</sup>Orthopaedic Department, Northampton General Hospital, Cliftonville, Northampton NN1 5BD, UK; <sup>2</sup>Peripheral Nerve Injury Unit, Royal National Orthopaedic Hospital, Brockley Hill, Stanmore, Middlesex, UK

Correspondence to: Mr T D Tennent FRCS, 6 Viscount Close, Friern Barnet, London N11 3PX, UK



**Figure 1** Anterior prosection of the left knee displaying the infrapatellar branch of the saphenous nerve and its main branches. Isn=infrapatellar branch of the saphenous nerve; s=superior branch; m=middle branch; i=inferior branch

### CADAVERIC STUDY

Permission to prosect the cadaveric specimens was kindly given by the Department of Anatomy, Royal Free Hospital School of Medicine. An incision was made along the medial aspect of the knee at the level of the long saphenous vein. The proximal limit was 5 cm above the patella and the incision was extended inferiorly to below the level of the tibial tuberosity. A skin flap was then raised laterally extending to the fibula without disturbing the subcutaneous fat. This gave a wide exposure to the prepatellar anatomy and allowed the full course of the nerve to be seen.

In all eight cadaveric knees the relations of the nerve to the patellar tendon were similar. The infrapatellar branch of the saphenous nerve emerges from the fascia lata medial to and at a level with the inferior pole of the patella with the knee in the extended position. It then divides into three branches medial to the lower pole of the patella, anterior to the long saphenous vein. The superior branch runs transversely just inferior to the lower pole of the patella, ending lateral to the patellar tendon. The middle branch divides from the superior branch medial to the medial

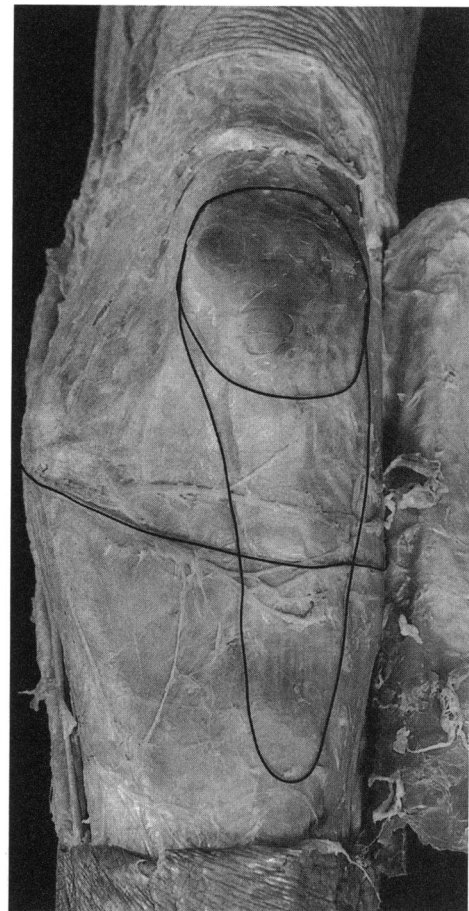
border of the patellar tendon and runs obliquely across the tendon, dividing into its terminal branches at the lateral border. The inferior branch is the smallest and runs down in relation to the medial border of the tendon, ending at the level of the tibial tuberosity (Figure 1).

To demonstrate the bony anatomy, pins were inserted into the anterior aspect of the knee joint and their position was marked with 2.0 silk ligature. The positions of the patella and the patellar tendon were marked in a similar manner (Figure 2).

### DISCUSSION

#### Anatomy

The saphenous nerve arises as a division of the femoral nerve and leaves the adductor canal between the tendons of gracilis and semitendinosus. It then divides into the main saphenous branch, which continues down to the ankle, and the infrapatellar branch. The latter traverses the knee below the patella, dividing into three branches before combining with the anterior branch of the lateral cutaneous nerve of the thigh, the intermediate cutaneous nerves of the thigh and the anterior branch of the medial cutaneous nerve of the thigh to form the prepatella plexus<sup>1</sup>. Standard surgical



**Figure 2** Prosection as for Figure 1 with the patellar tendon and joint margin delineated

texts also make reference to the relation of the nerve to the knee but the clinical implications are not usually stressed<sup>2</sup>.

## Trauma

Dashboard injuries to the infrapatellar branches of the saphenous nerve are rare. Traumatic prepatellar neuralgia as a consequence has been described on two occasions<sup>3,4</sup> but in the earlier report<sup>3</sup> there is no indication as to which nerve may have been involved. In the more recent series the nerve responsible was felt to be the anterior branch of the lateral cutaneous nerve of the thigh. The authors suggested that, because the patella is more lateral when the knee is flexed, injury to the lateral cutaneous nerve will be more common in dashboard injuries. Detenbeck<sup>5</sup> described a single case of a dashboard injury to the infrapatellar branch of the saphenous nerve, causing pain anteriorly and anteromedially; this was treated surgically with a good result. A further five cases of neuralgia of non-surgical aetiology have been described by Lippitt<sup>6</sup>, all treated by neurolysis of the infrapatellar branch. He recommended consideration of injury to this nerve in unexplained anterior knee pain.

## Surgical injury

The surgical approach for a total knee replacement is described in *Campbell's Operative Orthopedics* as 'a straight longitudinal incision beginning 7.5 cm proximal to the superior pole of the patella, extending over the patella and ending at the medial border of the tibial tuberosity'<sup>7</sup>. The incision cuts through skin and subcutaneous tissue down through the capsule of the knee joint, allowing the patella to be dislocated laterally during the course of the operation.

During knee arthroscopy, the knee is flexed to 45–90 degrees and two entry portals are commonly used. The first is a stab incision 1 cm above the joint line and 1 cm lateral to the patellar tendon, the second a stab incision 1 cm above the joint line and medial to the tendon<sup>2</sup>. There are several less commonly used portals for gaining access to other parts of the knee.

Injury to the nerve following open meniscectomy has been described by Swanson<sup>8</sup>, who concluded that damage to the nerve is almost inevitable during this operation in view of the distribution of branches.

Small<sup>9,10</sup> reported damage to the nerve in two patients after arthroscopy but stated that it was an infrequent occurrence. Sherman<sup>11</sup> reviewed 2646 knee arthroscopies and detected a 0.5% incidence of injury to all of the prepatellar nerves. In 53% of the cases the injuries were related to the placement of an anteromedial or posteromedial portal. He suggested that the placement of the posteromedial portal should be assisted by transcutaneous illumination to help identify the nerve. Mochida and Kikuchi<sup>12</sup> dissected the nerve in 129 cadaveric knees

and described two variants—a type 1 nerve running low and obliquely across the patellar tendon, and a type 2 running transversely below the lower pole of the patella. They reviewed the incidence of damage to this nerve during the placing of arthroscopy portals and concluded that the nerve was damaged in 22% of cases. They showed that if the arthroscopy portals were sited in an area medial to the patella the risk of damage was greatly reduced.

## CONCLUSION

The infrapatellar branches of the saphenous nerve may be damaged by trauma or surgery with resultant anterior or anteromedial pain and an associated lateral area of altered sensation. We believe that surgeons should be aware of the presence of this nerve and the relation of its branches to the patellar tendon and we therefore recommend several changes to practice:

- Before surgery, patients should be warned of the risk of nerve injury
- Arthroscopy incisions should be done with due consideration of the nerve anatomy
- Portals should be made with a horizontal, clean incision
- Portals should not be sutured since the nerves may be caught up in the suture
- Anterior longitudinal knee incisions should be made cleanly through prepatellar tissues to reduce the risk of neuroma formation

## REFERENCES

- 1 Berry M, Bannister LH, Standing SM. Nervous system. In: Williams PL, ed. *Gray's Anatomy*. New York: Churchill Livingstone, 1995:1279–82
- 2 Miller RH. Arthroscopy of the lower extremity. In: Crenshaw AH, ed. *Campbell's Operative Orthopedics*. St Louis: Mosby, 1992:1787–864
- 3 Gordon GC. Traumatic prepatellar neuralgia. *J Bone Joint Surg* 1952;**34B**:41–4
- 4 Ipkeme JO, Gray C. Traumatic prepatellar neuralgia. *Injury* 1995;**26**:225–9
- 5 Detenbeck LC. Infrapatellar traumatic neuroma resulting from dashboard injury. *J Bone Joint Surg* 1972;**54A**:170–2
- 6 Lippitt AB. Neuropathy of the saphenous nerve as a cause of knee pain. *Bull Hosp Joint Dis* 1993;**52**:31–3
- 7 Tooms RE. Arthroplasty of the ankle and knee. In: Crenshaw AH, ed. *Campbell's Operative Orthopedics*. St Louis: Mosby, 1992:389–439
- 8 Swanson AGJ. Prepatellar neuropathy following medial meniscectomy. *Clin Orthop* 1983;**181**:151–3
- 9 Small NC. Complications in arthroscopy: the knee and other joints. *Arthroscopy* 1986;**4**:253
- 10 Small NC. Complications in arthroscopic surgery performed by experienced arthroscopists. *Arthroscopy* 1988;**4**:215
- 11 Sherman OR, Fox JM, Snyder SJ, et al. Arthroscopy—no problem surgery? *J Bone Joint Surg* 1986;**68A**:256–64
- 12 Mochida H, Kikuchi S. Injury to the infrapatellar branch of the saphenous nerve in arthroscopic knee surgery. *Clin Orthop Rel Res* 1995;**320**:88–94