EXPULSIVE HEMORRHAGE: ITS INCIDENCE IN CATARACT SURGERY AND A REPORT OF FOUR BILATERAL CASES

BY *John W. Payne,* MD, *Anthony J. Kameen,* MD (BY INVITATION), *Allan D. Jensen,* MD (BY INVITATION), AND (BY INVITATION) *Norval E. Christy,* MD

INTRODUCTION

THE TERM "EXPULSIVE HEMORRHAGE" WAS PROPOSED BY TERSON[1] IN 1894 TO DEscribe an acute choroidal hemorrhage occurring during intraocular surgery which usually resulted in a lost eye. Since then the term has come to encompass a wide spectrum of this ocular complication. This ranges from a localized contained choroidal hemorrhage to an extrusion of intraocular contents with a lost eye.[2] Choroidal hemorrhages may occur spontaneously, posttraumatically, associated with intraocular pathology, or secondary to many types of intraocular surgery.[3-10] Acute choroidal effusion is a rare condition with many signs similar to acute choroidal hemorrhage.[11-14] It has been postulated by Winslow et al[4] in 1974 and recently by Maumenee and Schwartz[15] that unrecognized serous or serosanguineous choroidal effusions may precede and lead to expulsive hemorrhage. Bilateral cases are fortunately extremely rare. To our knowledge there are only six reported cases of bilateral expulsive hemorrhage.[16-21]

We are reporting on the incidence of acute expulsive hemorrhage in a total of 13,890 cases of cataract extraction at the Wilmer Institute of the Johns Hopkins Hospital (JHH) and Greater Baltimore Medical Center (GBMC) from 1978 through 1983, and 180,690 cases of cataract extraction at the Christian Hospital in Taxila, Pakistan from 1963 through 1983. Predisposing factors and the role of treatment will be discussed. The six bilateral cases of expulsive hemorrhage will be reviewed and four additional cases will be presented. Finally, a classification of choroidal hemorrhage is offered as a means of distinguishing the wide range in severity of this process.

REVIEW OF THE LITERATURE

The earlist case of expulsive hemorrhage related to cataract surgery was reported in the German literature in 1774 by Hellmann.[22] In 1786 de Wenzel[23] was the first to describe the complication in the French literature. Pfingst[24] in 1936 first reported on the incidence of this complication with a series of 2 cases in 25,000 cataract extractions or 0.08%. In 1966 Holland[25] reported on 135 cases from 54,239 cataract operations by 20 authors for an average incidence of 0.25%. Taylor[26] in 1974 reviewed the reports of 115 cases of expulsive hemorrhage from a total of 58,735 cataract operations by 11 authors for an average combined incidence of 0.20%. The rates of occurrence ranged from 0.05% to 0.40%.

The histopathology of expulsive hemorrhage has been well described by Samuels,[27] Manschot,[28,29] and Müller.[30] Manschot[28,29] presented the anatomic findings in ten cases. In nine of the ten cases a ruptured necrotic posterior ciliary artery was the source of hemorrhage. A short posterior ciliary artery was involved in eight cases; while both a long and short posterior ciliary artery were involved in one other. Glaucoma was present in five of the ten cases. Hypertension was a factor in six of ten cases. Müller[30] reported the pathology of eight cases in which glaucoma was documented in two and hypertension in one case. The short posterior ciliary vessels were implicated, with the site of vascular entry from the sclera to the subchoroidal space being most commonly involved. In a recent report Wolter[31] also found a rupture of the long posterior ciliary artery to be the cause of an expulsive hemorrhage.

A clear-cut pattern of predisposing factors has never been elucidated. Most investigators, however, are in agreement that glaucoma, hypertension, and generalized arteriosclerosis may predispose the posterior ciliary vessels to vascular necrosis.[6,25,26,29-32] The hypotonia caused by a surgical incision leads to the rupture of the vessel. The fact that the majority of patients with expulsive hemorrhage are in the elderly age group gives credence to this possibility. Cordes,[33] however, reported four cases of expulsive hemorrhage during congenital cataract surgery in patients ranging from 4 months to 21 years of age. Francois et al[21] similarly noted expulsive hemorrhages in four young patients in previously fine health. These reports indicate that ocular systemic disease or advanced arteriosclerosis is not always a necessary factor in the pathogenesis of expulsive hemorrhage. Taylor[26] has postulated that there may be a higher incidence of expulsive hemorrhage in general anesthesia as opposed to local anesthesia.

The timing of the expulsive hemorrhage in relation to surgery is of interest. One would think that if the rupture of a necrotic vessel with

ocular hypotonia were the sole cause then a majority of the hemorrhages would occur soon after opening the incision into the anterior chamber. Pau,[34] however, reported that one-third of the cases occurred during surgery, one-third between 3 and 6 hours postoperatively, and one-third between 7 hours and 9 days postoperatively. Jaffe[32] states that at least 50% of the hemorrhages occur within the first few days after surgery. Winslow et al[4] and recently Maumenee and Schwartz[15] have postulated that perhaps many expulsive hemorrhages begin with an acute serous choroidal effusion. One could then easily postulate that the detachment of the posterior choroid and the sudden stretching of the posterior ciliary vessels causes them to rupture. Of particular interest in this regard is the report of Gressel et al[35] on eight cases of delayed severe nonexpulsive suprachoroidal hemorrhage occurring after filtering operations in aphakic eyes. All eight cases were noted to have serous choroidal detachments before the hemorrhage occurred. The hemorrhages occurred anywhere from 19 hours to 7 days following surgery. Hoffman et al[36] in a recent prospective study found unsuspected choroidal hemorrhage on the first postoperative day in 16 of 521 eyes. Hemorrhages were found in over 14% of highly myopic eyes and 4% of moderately myopic eyes, and in less than 1% of those without any significant myopia.

The first case of bilateral expulsive hemorrhage was reported by Verhoeff[16,17] in 1931 during discussion of Samuels paper[27] (Table I). Actually this was a follow-up on the same patient in whom Verhoeff had performed the first sclerotomy to save an eye from postoperative expulsive hemorrhage. Apparently the patient returned 6 years later with glaucoma in the other eye. This left eye was lost 4 days following an iridotasis procedure despite sclerotomies. Verhoeff in that discussion also mentioned a second case of his in which both eyes were apparently lost from expulsive hemorrhage. In 1959 at the meeting of the American Ophthalmological Society, Henderson[37] reported a case of expulsive hemorrhage during cataract extraction with survival of the eye. In the subsequent discussion three more bilateral cases were presented—by Danielson,[18] Castroviejo,[19] and Berens[20] respectively. Later in 1966 in a review of their experience with expulsive hemorrhage, Francois et al[21] reported another bilateral case in the French literature.

It is generally agreed that anticipating which patients are predisposed to expulsive hemorrhage is difficult.[38] Patients with extensive vascular disease, glaucoma, hypertension, and particularly those with a history of expulsive hemorrhage in the other eye should be managed with the possibility of this dreaded complication in mind. Maximal ocular hypotension achieved by hyperosmotic agents and external pressure is probably of

TABLE I: BILATERAL EXPULSIVE HEMORRHAGES (PREVIOUSLY REPORTED)

AUTHOR	SEX/AGE	PREOP VISION/TENSION		SURGERY	THERAPY	FINAL RESULT
Verhoeff[16,17]	60 M	1st eye	20/40 72 mm Hg	Sclerostomy for glaucoma	Sclerotomy × 3	20/200
		2nd eye	"Acute glaucoma" (6 yrs later)	Iridotasis	Sclerotomies	Lost
Verhoeff[17]	"I have another in which it occurred in one eye and a few years later in the other"					Presumably lost
Danielson[18]	F	1st eye	—	Cataract extraction	—	Lost
		2nd eye	—	Cataract extraction	—	Lost
Castroviejo[19]	—	1st eye	—	Cataract extraction	3 preplaced sutures-tamponaded	20/25
		2nd eye	—	Cataract extraction	5 preplaced sutures-tamponaded	20/25
Berens[20]	—	1st eye	—	—	—	Lost
		2nd eye	—	—	—	Lost
Francois et al[21]	39 F	1st eye	4/200	Cataract extraction	—	Lost
		2nd eye	Mature lens (12 yrs later)	Cataract extraction	—	Lost

value.[32] Preoperative and intraoperative anesthesia should be adequate.[26,27] Preplaced sutures facilitate rapid closing of the wound. Additional sutures should be used in closing the wound. Jaffe[32] considers placing a preparatory trephine or scleral incision inferior temporally at the onset of surgery in those patients so predisposed.

Verhoeff[16] in 1915 reported the first successful treatment of an expulsive hemorrhage. He advocated a small triangular sclerotomy incision placed temporally, with excision of the apex of the triangle to allow for the exit of blood.[13] In 1938 Vail[39] reported two cases in which the eyes were salvaged, employing Verhoeff's method of sclerotomy in each. Samuels[27] studied eight eyes microscopically and advocated Verhoeff's approach. Shaffer[40] concurred and stressed the importance of creating an incision which would remain open for several days to permit blood escape. Duehrs and Hogenson[38] reported saving an eye by performing posterior sclerotomy and tight limbal wound closure. There are now many other reports indicating some success with this approach.[2,8,37,41-44] Tight early closure of the limbal wound, if possible, tamponades the hemorrhage and limits its severity. Bair[43] emphasized that forced injection of fluid such as saline or balanced salt solution into the anterior segment of the eye may push the retina and choroid backward and help evacuate the hemorrhage through the sclerotomy. The postoperative management consists of topical, subconjunctival, subtenons, or systemic steroid administration for control of inflammation. Cycloplegic and antiglaucomatous medications are also often indicated.

RESULTS AND CASE REPORTS

In the years 1978 through 1983 there were 6548 cataract operations performed at the Wilmer Institute of JHH and a total of 8 expulsive hemorrhages for an incidence of 0.12% (Table II). In the same time period 7342 cataract operations were performed at the GBMC with a total of six expulsive hemorrhages for an incidence of 0.08%. In the years 1963 through 1983, 180,600 cataract operations were performed at the Christian Hospital in Taxila, Pakistan with 87 expulsive hemorrhages for an incidence of 0.05%. The overall incidence of expulsive hemorrhages in the Baltimore cases was 0.10%, compared to the Taxila cases with an incidence of 0.05%. There is a statistically significant lower incidence of expulsive hemorrhage in the Taxila series compared to the Baltimore cases ($P < 0.025$, $\chi^2 = 5.90$).

Between 1978 and 1983 there was a revolutionary change in the technique of cataract surgery in the United States which is reflected in the

TABLE II: INCIDENCE OF EXPULSIVE HEMORRHAGE IN CATARACT SURGERY

	NO OF OPERATIONS	NO OF HEMORRHAGES	RATE	PERCENT
JHH*	6548	8	1:819	0.12
GBMC*	7342	6	1:1223	0.08
Taxila**	180,690	87	1:2076	0.05

*1978 through 1983.
**1963 through 1983.

statistics from the JHH and the GBMC (Table III). In 1978, 89% of cataract surgery was by the intracapsular technique. By 1983, the elective extracapsular or phacoemulsification technique was used in 95% of cataract surgery.

In the years 1978 through 1983, 5710 intracapsular cataract extractions (ICCEs) were performed at the Wilmer Institute and GBMC with eight cases of expulsive hemorrhage for an incidence of 0.14% (Table IV). In the same time period 8180 extracapsular cataract extractions (ECCEs) were performed at these institutions with six cases of expulsive hemorrhages for an incidence of 0.07%. All cases performed in Taxila from 1963 through 1983 were ICCEs, and the incidence of expulsive hemorrhage was 0.05%. There is no significant difference in the incidence of expulsive hemorrhage in the Baltimore cases between ICCE and ECCE technique. However, there is a statistically significant lower incidence of expulsive hemorrhage in the Taxila series compared to the Baltimore ICCE group ($P = 0.007$, $\chi^2 = 7.46$).

The time of occurrence of expulsive hemorrhage is tabulated in Table V. Of the 14 Baltimore cases, 13 occurred intraoperatively, and only 1 occurred postoperatively—after a 6-day uneventful course. Of the 87 Taxila cases, only 13 occurred intraoperatively. Over two-thirds occurred on the first postoperative day; eight occurred on the second postoperative day; and several others, later on.

TABLE III: RECENT TRENDS IN CATARACT SURGERY (JHH & GBMC)

	1978	%	1983	%
ICCE	1608	89.1	177	5.5
ECCE	28	1.6	2655	82.6
Phacoemulsification	169	9.3	383	11.9
Other	4		1	
Total	1809		3216	

TABLE IV: INCIDENCE—TYPE OF EXTRACTION

	NO OF OPERATIONS	NO OF HEMORRHAGES	RATE	PERCENT
GBMC/JHH*				
ICCE	5710	8	1:714	0.14
ECCE	8180	6	1:1363	0.07
Taxila**				
ICCE	180,690	87	1:2076	0.05

1978 through 1983.
**1963 through 1983.

The 14 cases at JHH and the GBMC between 1978 and 1983 were reviewed in detail (Table VI). The ages of the patients in these cases ranged from 58 to 92 years and the average was 80 years. Five patients were men and nine, women. Eight cases were by ICCE; and six, by ECCE. Glaucoma was a factor in 9 of 14 cases. Hypertension was present in 4 of 14 patients. A Honan balloon was used for hypotensive effect in four cases; and massage in five other cases. Twelve of the cases were performed under local or local with standby anesthesia, and 2 were under general anesthesia. Two expulsive hemorrhages occurred at the time of incision, 11 with lens delivery, and 1 6 days postoperatively. Preplaced sutures were used in 10 of 14 cases. Associated problems such as coughing, vomiting, or patient movement were not significant factors. Six of the patients had sclerotomies at the time of hemorrhage, and five had vitrectomies. Visual results ranged from 20/20 to no light perception (NLP). Five patients had vision between 20/20 and 20/40; two patients, 20/50 and 20/200; and one patient, finger counting. Six of the 14 eyes were lost.

Following are four case reports of bilateral expulsive hemorrhages.

CASE 1

This 70-year-old white woman with a 5-year history of insulin-dependent diabetes presented in 1949 with mature bilateral cataracts. Vision was light perception and

TABLE V: TIME OF OCCURRENCE

	TOTAL	AT SURGERY	ON POSTOPERATIVE DAY					
			1	2	3	4	5	6
GBMC/JHH	14	13						1
Taxila	87	13	62	8	1	2	1	

TABLE VI: EXPULSIVE HEMORRHAGE DATA ON 14 CASES

Age	Range (58-92)	Median (85)	Average (80)	
Sex	Male (5)	Female (9)		
Type of surgery	ICCE (8) (3 combined glaucoma)			ECCE (6)
Glaucoma	Chronic (7)	Acute (2)		
Medical illness	Hypertension (4)	Dementia (2)	Diabetes (1)	Renal failure (1)
Hypotensive measures	Honan (4)	Massage (5)	Mannitol (2)	
Anesthesia	Local (6)	Standby (6)	General (2)	
Time of hemorrhage	At incision (2)	With lens delivery (11)		Late (1) (6 days postoperative)
Preplaced sutures	Yes (10)	No (4)		
Associated factors	None			
Surgical treatment	Sclerotomies (6)	Vitrectomy (5)		
Visual results*	20/20-20/40 (5)	20/50-20/200 (2)	FC-HM (1)	LP-NLP (6)

*FC, finger counting; HM, hand motion; LP, light perception; NLP, no light perception.

counting fingers. Tension was normal. Her right eye was operated on under general anesthesia. After the section was made, the lens delivered itself, followed by a copious amount of vitreous and then retina before the sutures could be tightened. No sclerotomy was performed. The eye was lost.

Two and one-half months later the left eye was operated on—again under general anesthesia. A paracentesis was performed to slowly reduce the intraocular pressure. A corneal scleral section was then made with two preplaced 6-0 black silk sutures. The lens was removed intact without difficulty using forceps. It was immediately followed by a copious amount of vitreous and retina. The second eye was lost.

CASE 2

This Pakistani woman had open-angle glaucoma with preoperative pressures of 30 and 53 mm Hg. She presented to the Christian Hospital in Taxila, Pakistan for care in 1963. Data about her age, preoperative blood pressure, and/or other medical problems are not available. Under local anesthesia a corneoscleral incision was made at the 12 o'clock position for 1 to 2 hours and an iridencleisis was performed. No sutures were used. Both eyes were operated on at the same sitting and the patient left the operating room in good condition. The patient had no excessive coughing or vomiting.

Twelve hours postoperatively in her bed on the ward, she suffered bilateral expulsive hemorrhages. The patient was returned to the operating room where the prolapsed intraocular contents were excised and the superior wound secured. The vision in both eyes was lost. Following this case a decision was made never to operate on both eyes of any patient at one sitting.

CASE 3

This 79-year-old white man had enjoyed excellent ocular health until approximately 3 months before his admission when he had painless, progressive loss of vision. Approximately 3 weeks before admission he developed further loss of vision and pain in both eyes. He was seen 1 week prior at Baltimore City Hospital and was found to have light perception vision in each eye with bullous keratopathy, intraocular pressures of 60 mm Hg, closed angles, and swollen cataractous lenses. He was treated with acetazolamide (Diamox) 500 mg every 6 hours and pilocarpine 4% four time a day to both eyes.

Oh August 23, 1979, intraocular cataract extraction was performed on the left eye under local anesthesia, but the patient became combative during the surgery and he suffered an expulsive hemorrhage. Further details of the surgery are not known.

He was transferred on the first postoperative day to the JHH on maximum antiglaucomatous medication. His medical history was remarkable for aortic aneurysm repair in 1971 and a history of ethanol abuse. There was a history of asbestos exposure with chest x-ray abnormalities compatible with this. Approximately 1 year before admission a diagnosis of Parkinson's disease was made, and he began suffering from dementia. There was also a history of angina, congestive heart failure, and mild adult-onset diabetes. Although there was a history of labile hypertension, blood pressure was 140/80.

On ocular examination, the right eye had light perception vision with good projection. On the left there was no light perception. The right eye was moderately injected with bullous keratopathy and a nonreactive pupil. On the left, the cornea was moderately opaque and the superior anterior chamber was filled with blood although inferior iris was visible. There was pigment, evidently iris, beneath a superior conjunctival flap. At the slit lamp, on the right, there was severe bullous keratopathy with moderate flare and cell in the anterior chamber and a dense cataract. The anterior chamber was shallow peripherally. On the left there was marked bullous keratopathy with blood in the superior anterior chamber and no other details. Intraocular pressure was 50 mm Hg on the right and on he left was firm to finger touch. The fundi could not be visualized. Blood work, electrolytes, and cardiogram were essentially normal.

On August 27, 1979 cataract surgery on his right eye was performed under general anesthesia, using in addition a lid block and retrobulbar injection of 2% Xylocaine and 0.75% Marcaine with Wydase. Intravenous mannitol was given at the time of general anesthesia and he had extensive manual massage. Preoperative intraocular pressure was reduced to 17 mm Hg. With a limbus-based flap, a partially penetrating groove was made in the superior 150 degrees. Three 8-0 black silk sutures were preplaced. A vitreous tap was made through the pars plana superiorly to further lower intraocular pressure. The anterior chamber was entered and a sector iridectomy performed. The lens was removed with a cryoprobe and vitreous and iris fell back. While the wound was being closed, the anterior hyaloid face bulged and vitreous was lost. An anterior vitrectomy was performed. A diagnosis of an expulsive hemorrhage was made. There was a gray fundus reflex.

The wound was tied using numerous interrupted sutures of 8-0 nylon. No further sclerotomy was performed. Postoperatively, the patient had no evident light perception, although he remained comfortable. His intraocular pressures remained at levels of 15 to 20 mm Hg. There continued to be a large choroidal hemorrhage and retinal folds and he was discharged to a nursing home on September 11, 1979 with no light perception in either eye. He died within the next month of heart failure.

CASE 4

This 79-year-old white woman had an 8-year history of chronic simple glaucoma controlled on topical Timoptic (timolol) 0.5% twice daily and pilocarpine 4% three times a day to both eyes. She had high blood pressure for some 20 years controlled on a combination of reserpine, hydralazine hydrochloride, hydrochlorothiazide (SER-AP-ES) daily.

Her best corrected visual acuity in the right eye was 20/100 and the left eye 20/100. There were 2 to 3+ cortical cataracts. The intraocular tension in the right eye was 18 mm Hg and the left eye 18 mm Hg. On gonioscopy the angles were grade I to II. The visual fields were full. There was a 40% cupping of the right disc and 50% cupping of the left disc.

In February 1980 under a local anesthesia she underwent an ICCE in the right eye combined with a trabeculectomy. Three 8-0 black silk sutures were preplaced in a mattress fashion at the 10 o'clock, 12 o'clock, and 1:30 o'clock position and a trabeculectomy was done at the 11 o'clock position. After removal of the lens, the anterior hyaloid face fell way back. The preplaced sutures were then tied and cut.

At this point, without any coughing or straining on the part of the patient, there was a sudden firming up of the eye with an anterior displacement of the iris. A copious amount of vitreous was lost through the trabeculectomy. A full iridectomy was performed and a local vitrectomy. The trabeculectomy was sealed rapidly with 8-0 black silk sutures. At this point retina could be seen in the microscope just behind the iris which was virtually flat against the back of the cornea. The intraocular tension was 50 mm Hg at this time. No sclerotomy was performed.

On the first postoperative day the vision was hand motions and the anterior chamber had reformed and the intraocular tension was 17 mm Hg. A hemorrhagic detachment of the retina and choroid could be seen with the handlight.

Subsequently, the intraocular pressure rose to a high of 34 mm Hg, but was controlled with topical medications and acetazolamide. A fluorescein angiogram was taken 3½ weeks postoperatively as the retina began to settle, Fig 1 demonstrates the area of residual choroidal hemorrhage. Fig 2 is the fluorescein and leakage of dye from a retinal vessel.

At 2 months postoperatively the visual acuity was counting fingers at 2 ft and there was slow settling of the elevated choroidal hemorrhage. This completely resolved in about 6 months. At 8 months the vision was correctable to 20/50 and she was given aphakic glasses. By 1 year her visual acuity was 20/30+ and she read 0.37 M print.

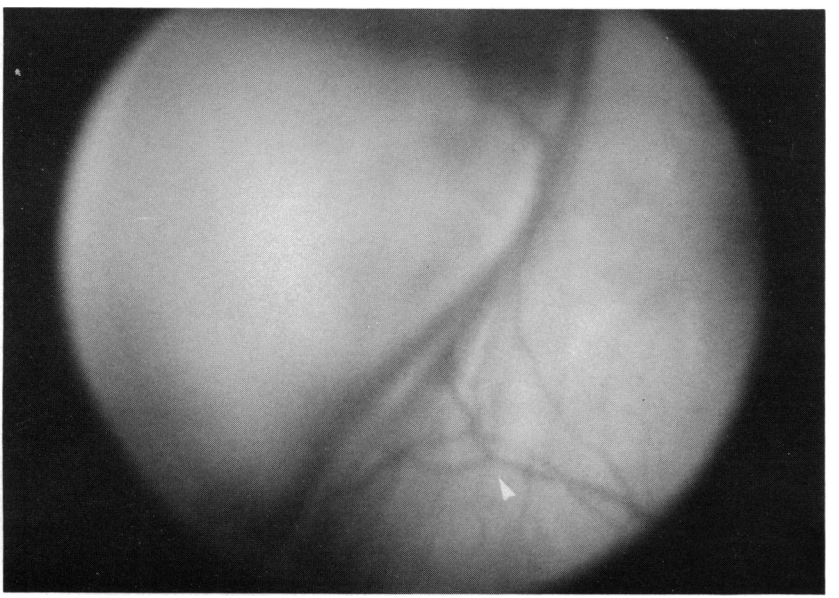

FIGURE 1
Case 4: Fundus photograph of right eye taken 3½ weeks postoperatively. Residual choroidal hemorrhage elevates retina and choroid temporally. *Arrow* points to retinal vessels posterior to hemorrhage.

She then became anxious to have a similar procedure on her left eye. This was delayed until February of 1984 when the vision in her left eye reached hand motions. Plans were then made to do an ECCE on the left eye. In the operating room the blood pressure was controlled at 135/70. After a retrobulbar injection and a Honan cuff for 10 minutes the intraocular pressure was 7 mm Hg. Three 8-0 black silk sutures were preplaced in a mattress fashion. The delivery of the nucleus went without problems as did most of the aspiration of the residual cortex. However, after a sudden bout of emesis, there was a rapid firming up of the eye. The anterior chamber shallowed, posterior capsule remained intact, but the intraocular tension was 35 mm Hg. It was impossible to continue with the irrigation aspiration of a small amount of residual cortex. Through the microscope an elevated black mass was seen in the lower nasal quadrant. Multiple postplaced 10-0 nylon sutures were used to secure the wound and no sclerotomy was performed.

One week postoperatively her vision was correctable to 20/400 with temporary glasses. There was a large elevated choroidal hemorrhage in the nasal area of the fundus. The intraocular tension was controlled with topical timolol. Photographs were taken 4 weeks postoperatively (Fig 3). By 4 months the choroidal hemor-

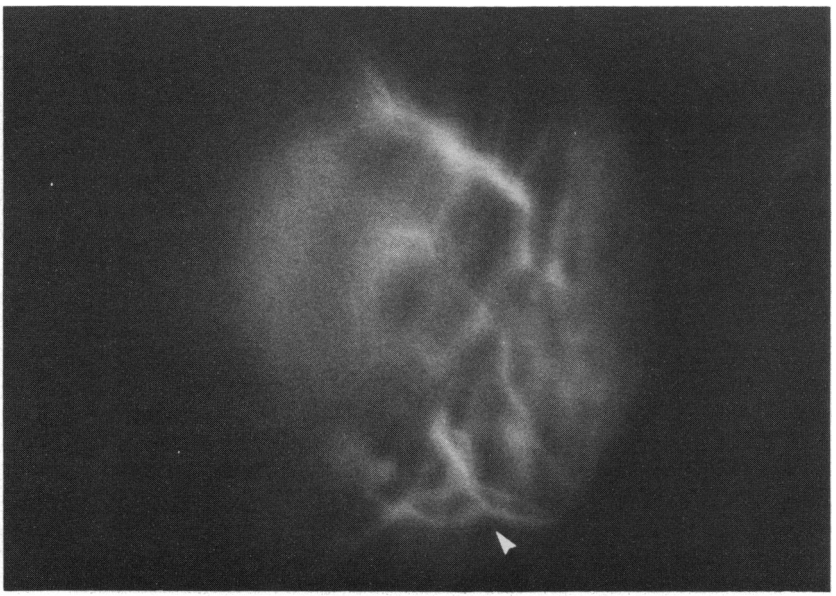

FIGURE 2
Case 4: Fluorescein angiogram of same area as in Fig 1. *Arrow* points out identical retinal vessel pattern. Note blocked choroidal fluorescence over area of choroidal hemorrhage as well as leakage from an overlying retinal vessel.

rhage had almost completely resolved and the visual acuity was correctable to 20/60.

It has now been over 5 years since the ICCE on her right eye and 1 year since the ECCE on her left eye. Her visual acuity is correctable to 20/30+ in each eye and the intraocular tensions are 16 mm Hg and 18 mm Hg, respectively, controlled on timolol 0.5% twice daily to both eyes. There is some peripheral pigment epithelial mottling that perhaps is the only residua of the severe bilateral intraoperative choroidal hemorrhages that she sustained.

DISCUSSION

Expulsive hemorrhage is the most disastrous complication of intraocular surgery. Fortunately for both physician and patient, it is an extremely rare phenomenon. The range in incidence of expulsive hemorrhage reported in the literature is 0.05% to 0.40%, with the larger series by Taylor[26] and Holland[5] citing 0.20% and 0.25% incidence, respectively. The incidence in our cases ranged from 0.05% to 0.12% (Table II)—with the overall incidence in the Baltimore cases being 0.10% and Taxila cases

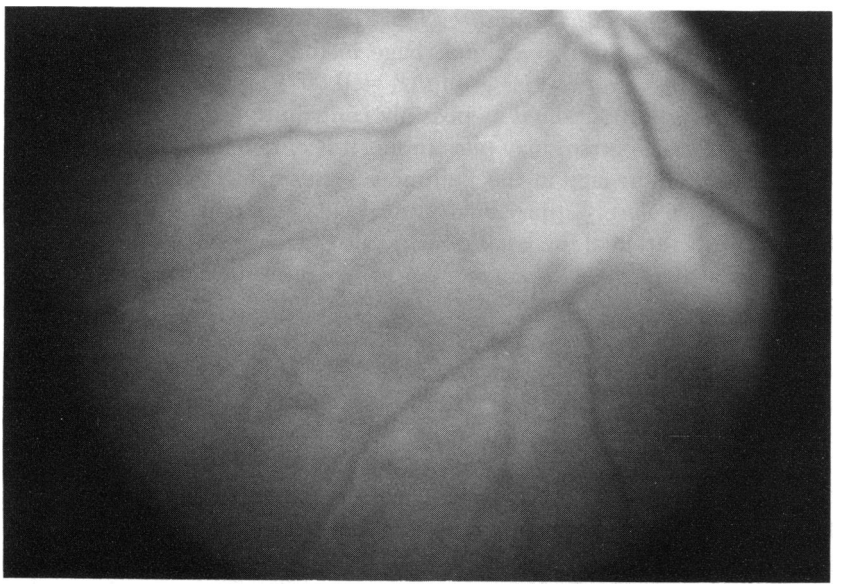

FIGURE 3
Case 4: Fundus photograph of left eye 4 weeks postoperative, showing residual choroidal hemorrhage inferiorly.

0.05%. This difference is statistically significant ($P < 0.025$, $\chi^2 = 5.90$), Possible causes for the lower incidence of expulsive hemorrhage in the Taxila cases include differences in patient population, in operating technique, and in the recognition of this complication. The Pakistani patient population may be much younger and prone to less arteriosclerotic disease and glaucoma. The quick (3 to 5 minute) surgical procedure in Taxila allows less time for hypotony—a likely predisposing factor. Finally, because the eye is closed quickly, potential expulsive hemorrhage may be tamponaded early on and not subsequently recognized.

The years 1978 to 1983 have seen a rapid change from ICCE to ECCE in the United States and this change is evident in the Wilmer and GBMC experience (Tables III and IV). ICCE was performed in 89% of cases in 1978 and only 5.5% of cases in 1983. ECCE was performed in 1.6% of cases in 1978 and and 83% of cases in 1983. The incidence of expulsive hemorrhage in the Baltimore cases with ICCE was 0.14%, and with ECCE 0.07%. Thus, there has been a trend toward a lower incidence of expulsive hemorrhage during this period in the Baltimore cases. Though the difference is not statistically significant with the present data, future

studies may substantiate this impression. However, there is a statistically lower incidence of expulsive hemorrhage in the Taxila series compared to the Baltimore intracapsular group ($P = 0.007$, $\chi^2 = 7.46$). All of the factors previously mentioned as possibly contributing to the lower incidence in the Taxila group may play a role. It is of note that the incidence of expulsive hemorrhage in the Baltimore series using the extracapsular technique more closely approximates the Taxila experience. It is possible that the preservation of the posterior capsule plays a role in the decreased incidence of expulsive hemorrhage with extracapsular surgery in the Baltimore series.

The time of occurrence of expulsive hemorrhage is interesting (Table V). Thirteen of the 14 Baltimore cases (93%) occurred intraoperatively whereas 13 of the 87 Taxila cases (15%) were noted at operation. Only one Baltimore case occurred postoperatively—on the sixth postoperative day after a previously uneventful course. Sixty-two of the 87 Taxila cases (71%) occurred on the first postoperative day, 8 (9.2%) on postoperative day 2, and the remaining 4 on postoperative days 3 to 5. The large difference between time of occurrence in the Baltimore and Taxila cases is probably due to multiple factors, such as, operating time, suturing techniques, and postoperative activity. Cataract surgery in Taxila takes approximately 3 to 5 minutes compared to 30 to 60 minutes in the Baltimore cases. Consequently, there is more time during surgery in the Baltimore series for a choroidal hemorrhage to occur and manifest itself. If an expulsive hemorrhage were to occur 5 minutes after the initial incision in a Taxila cataract procedure, the patient would be off the table and it would likely to unnoticed until the first postoperative day. In Taxila three preplaced 8-0 silk sutures are the routine method of closure. This provides less of a water light closure than present suture techniques used in conjunction with the operating microscope at both Baltimore hospitals. Moreover, the postoperative activity of cataract patients in the United States is regulated by physician instruction. On the other hand, in Taxila postoperative instruction usually goes unheeded. It is not uncommon to see many patients bowing their heads to the floor in prayers of thanksgiving only minutes postoperatively. Such postoperative activity may contribute to the increased expulsive hemorrhages noted on the first day after surgery.

Table VI presents possible predisposing factors to expulsive hemorrhage as well as the surgical management, treatment, and visual outcome in the 14 cases of the Baltimore series. The average age was 80 years, an age predisposed to arteriosclerosis, hypertension, and glaucoma. Indeed, glaucoma was present in 9 of 14 patients (64%) and hypertension, in 4 of

14 (29%). Two other patients had senile dementia. In two-thirds of the cases some form of external pressure was used preoperatively to lower the pressure. Twelve of 14 cases were performed under local anesthesia while 2 were under general anesthesia. This disparity is probably not significant, as well over 95% of cataract surgery in the Baltimore hospitals is done under local anesthesia or standby. Taylor[26] speculated that general anesthesia might carry a higher risk of expulsive hemorrhage. However, the widespread use of local anesthesia does not allow us to make an adequate comparison. Eleven of the cases (79%) occurred at the time of lens delivery. It is apparent that preplaced sutures offer a rapid means of closing and tamponading the wound if hemorrhage occurs. However, the final postoperative visual acuity was no better in those cases in which preplaced sutures were used. Intraoperative sclerotomies were performed in 6 of 14 cases (43%) and were effective in draining the hemorrhage. Four of these eyes were lost. Undoubtedly, sclerotomies were performed in the more severe cases with subsequent poorer results. Final visual outcome varied from 20/20 to no light perception. Seven cases (50%) were 20/200 or better 1 year postoperatively. Over one-third were 20/40 or better. However, the other seven cases were essentially lost eyes.

The four bilateral cases presented demonstrate the wide spectrum of visual results with this complication. Previous reports have never emphasized the possibility, though rare, of bilateral expulsive hemorrhage. When operating on the second eye of a patient whose first eye has had an expulsive hemorrhage, it would be wise to remember that lightning can and does strike twice in the same place. Appropriate precautions should include careful control of blood pressure, preoperative intraocular pressure reduction, the smallest wound possible, and preplaced sutures. The extracapsular technique may prove to be helpful in modifying diastrous results from this complication by maintaining the posterior capsule. Being prepared to quickly close the limbal incision and to do a sclerotomy, when indicated, may save the eye. The surgeon (JWP) in case 4 is convinced that the favorable outcome in both eyes was due to preplaced sutures allowing an immediate tamponade of the wound.

Because of the broad spectrum of choroidal hemorrhage and the great variability of those associated with intraocular surgery, we propose a classification of choroidal hemorrhage (Table VII). It is hoped that this classification may serve to clarify the subject by giving ophthalmologists a concise terminology to use.

TABLE VII: CHOROIDAL HEMORRHAGE

I. Spontaneous
II. Associated with ocular pathology, ie:
Perforated corneal ulcer, hypotony, cyclodialysis, tumor, other
III. Trauma
IV. Associated with intraocular surgery, ie:
Cataract extraction, glaucoma procedures, penetrating keratoplasty, sclerotomy during retinal detachment procedures
A. Intraoperative
1) Complete expulsive—loss of vitreous and retina
2) Partial expulsive—no loss of vitreous and/or lens, but no loss of retina
3) Nonexpulsive—no loss of intraocular contents
B. Postoperative
1) Complete expulsive—loss of vitreous and retina
2) Partial expulsive—no loss of vitreous and/or lens, but no loss of retina
3) Nonexpulsive—no loss of intraocular contents
a) Severe
b) Limited

SUMMARY

Between 1978 and 1983, 13,890 cataract extractions were performed in Baltimore at JHH and the GBMC with 14 expulsive hemorrhages for an incidence of 0.10%. In the years 1963 through 1983, 180,690 cataract extractions were performed in Taxila, Pakistan with 87 expulsive hemorrhages for an incidence of 0.05%. Reasons for the significant differences in incidence are presented. The six reported cases of bilateral expulsive hemorrhage are reviewed. Four more cases are added. A classification of choroidal hemorrhage is presented.

ACKNOWLEDGMENTS

The authors are grateful to the Baltimore ophthalmic community for their cooperation in this study. Drs A. E. Maumenee, W. Richard Green, J. Brumback, T. Pappavaselio, R. B. Welch, A. Sommer, and E. Newby gave helpful advice. Drs Earl Kidwell and Roy Scholz generously allowed us to include their cases. Mrs Viva Kropp, Miss Ellen Blake, and Ms Sharon Becker gathered incidence data at Johns Hopkins Hospital and the Greater Baltimore Medical Center. Mrs Maria Maggio was invaluable in searching out references. Ms Virginia Ketler, my faithful secretary, typed the manuscripts.

REFERENCES

1. Terson A: NEED TITLE. *Arch Ophthalmol* 1894; 17:110.
2. Girard LJ, Spak HE, Hawkins RS, et al: Expulsive hemorrhage during intraocular surgery. *Trans Am Acad Ophthalmol Otolaryngol* 1973; 77:119-125.
3. Williams DK, Rentiers PK: Spontaneous expulsive choroidal hemorrhage. *Arch Ophthalmol* 1970; 83:191-194.
4. Winslow RL, Stevenson W, Yanoff M: Spontaneous expulsive choroidal hemorrhage. *Arch Ophthalmol* 1974; 92:33-36.
5. Cahn PH, Havenor WH: Spontaneous massive choroidal hemorrhage with preservation of the eye by sclerotomy. *Am J Ophthalmol* 1963; 56:568-571.
6. Green WR: The uveal tract, in WR Spencer, RL Font, WR Green, EL Howes Jr, FA Jakobiec, LE Zimmerman (eds): *Ophthalmic Pathology. An Atlas and Textbook*, ed 3. Philadelphia, WB Saunders, 1985; vol 3, chap 19.
7. Perry HD, Hsieh RC, Evans RM: Malignant melanoma of the choroid associated with spontaneous expulsive choroidal hemorrhage. *Am J Ophthalmol* 1977; 84:205-208.
8. Wolter JR: Expulsive hemorrhage during retinal detachment surgery. *Am J Ophthalmol* 1961; 51:264-266.
9. DeVoe G: Hemorrhage after cataract extraction of clinical and experimental investigation of its cause and treatment. *Arch Ophthalmol* 1942; 28:1069-1096.
10. Owens WC, Hughes WF: Intraocular hemorrhage in cataract extraction. *Arch Ophthalmol* 1947; 37:561-571.
11. Ruiz ES, Paul PC: Expulsive choroidal effusion: A complication of intraocular surgery. *Arch Ophthalmol* 1976; 94:69-70.
12. Bellows AR, Chylack LT, Epstein DL, et al: Choroidal effusion during glaucoma surgery in patients with prominent episcleral vessels. *Arch Ophthalmol* 1979; 97:493-497.
13. Savir H: Expulsive choroidal effusion during cataract surgery: In a case with Fuch's heterochromic cyclitis. *Ann Ophthalmol* 1979; 11:113.
14. Campbell JK: Expulsive choroidal hemorrhage and effusion—a reappraisal. *Ann Ophthalmol* 1980; 12:332-340.
15. Maumenee AE, Schwartz MF: Acute intraoperative choroidal effusion. Submitted for publication.
16. Verhoeff FH: Scleral puncture for expulsive subchoroidal hemorrhage following sclerostomy—scleral puncture for postoperative separation of the choroid. *Ophthalmol Rec* 1915; 24:55-59.
17. Verhoeff FH: in discussion, Samuels B: Postoperative nonexpulsive subchoroidal hemorrhage. *Arch Ophthalmol* 1931; 6:840-851.
18. Danielson RW: in discussion, Henderson JW: Expulsive subchoroidal hemorrhage associated with cataract extraction. *Trans Am Ophthalmol Soc* 1959; 57:195-209.
19. Castroviejo R: in discussion, Henderson HW: Expulsive subchoroidal hemorrhage associated with cataract extraction. *Trans Am Ophthalmol Soc* 1959; 57:195-209.
20. Berens C: in discussion, Henderson HW: Expulsive subchoroidal hemorrhage associated with cataract extraction. *Trans Am Ophthalmol Soc* 1959; 57:195-209.
21. Francois PM, Wannebroucg L, Guilber-Legand M: Les hemorragies expulsives: A propos de 6 ca. *Bull Soc Ophtalmol Fr* 1966; 66:579-585.
22. Hellmann JC: *Der Graue Staar und dessen Herausnehmung, nebst einigen Boebachtungen*. Magdeburg, 1774.
23. de Wenzel MJB: *Traite de la cataracte*. Paris, PJ Duplain, 1786.
24. Pfingst AO: Expulsive choroidal hemorrhage complicating cataract extraction. *South Med J* 1936; 29:325-328.
25. Holland G: Zurklinik der expulsive blutung nach katarak operation. *Klin Monatsbl Augenheilkd* 1966; 149:859-864.
26. Taylor DM: Expulsive hemorrhage: Some observations and comments. *Trans Am Ophthalmol Soc* 1974; 82:157-169.

27. Samuels B: Postoperative nonexpulsive subchoroidal hemorrhage. *Arch Ophthalmol* 1931; 6:840-851.
28. Manschot WA: Expulsive hemorrhage. *Acta Ophthalmol* 1942; 19:237.
29. ———: The pathology of expulsive hemorrhage. *Am J Ophthalmol* 1955: 40:15-24.
30. Müller H: Expulsive hemorrhage. *Trans Ophthalmol Soc UK* 1959; 79:621-633.
31. Wolter JR: Expulsive hemorrhage: A study of histopathological details. *Albrecht Von Graefes Arch Klin Exp Ophthalmol* 1982; 219:155-158.
32. Jaffe NS: *Cataract Surgery and Its Complications*. St Louis, CV Mosby, 1981, pp 420-428.
33. Cordes FC: Linear extraction in congenital cataract surgery. *Am J Ophthalmol* 1961; 52:355-360.
34. Pau H: Der zeithaktor beider expulsiven blutung. *Klin Monatsbl Augenheilkd* 1958; 132:865-869.
35. Gressel MG, Parrish PK, Hever DK: Delayed nonexpulsive suprachoroidal hemorrhage. *Arch Ophthalmol* 1984; 102:1757-1760.
36. Hoffman P, Pollack A, Oliver M: Limited choroidal hemorrhage associated with intracapsular cataract extraction. *Arch Ophthalmol* 1984; 102:1761-1765.
37. Henderson JW: Expulsive subchoroidal hemorrhage associated with cataract extraction. *Trans Am Ophthalmol Soc* 1959; 57:195-209.
38. Duehr PA, Hogenson CD: Treatment of subchoroidal hemorrhage by posterior sclerotomy. *Arch Ophthalmol* 1947; 38:365-367.
39. Vail D: Posterior sclerotomy as a form of treatment in subchoroidal expulsive hemorrhage. *Am J Ophthalmol* 1938; 21:256-260.
40. Shaffer RN: Posterior sclerotomy with scleral cautery in treatment of expulsive hemorrhage. *Am J Ophthalmol* 1966; 61:1307-1311.
41. Vail D: Subchoroidal expulsive hemorrhage occurring during Thiopental Sodium (sodium pentothal) anesthesia: Its treatment by sclerotomy. *Arch Ophthalmol* 1949; 42:562-566.
42. Goren SB: Expulsive subchoroidal hemorrhage following cataract surgery. *Am J Ophthalmol* 1966; 62:536-537.
43. Bair HL: Expulsive hemorrhage at cataract extraction: Report of a case and an additional recommendation for its management. *Am J Ophthalmol* 1966; 61:992-994.
44. Newby WE, Welch RB: The management and classification of expulsive choroidal hemorrhage. *Presented at the 28th Clinical Meeting of the Wilmer Residents Association*. Baltimore, April 24-26, 1969. (Unpublished).

DISCUSSION

DR DANIEL M. TAYLOR. I would like to congratulate Doctor Payne and associates for their excellent paper on expulsive hemorrhage, the most dramatic and devastating complication of intraocular surgery. I am in complete agreement with the contents of Doctor Payne's paper. My comments will therefore be supportive.

A the 1974 AOS meeting I presented a series of five expulsive hemorrhages that I had experienced from 1951-1973.

Ten years later I have personally had an additional 16 expulsive hemorrhages, for a total of 21 in over 7000 intraocular procedures from 1951-1984 for an incidence of 0.3%. This may be an American record. However, I shall refrain from applying to the Guiness Book of Records. Regrettably, the 16 additional expulsive hemorrhages over the last 10 years leave me with no deeper understanding than I had after the first 5 hemorrhages. In recent years my surgery has included a much

larger number of complicated cases requiring extensive and prolonged procedures. This undoubtedly contributes to my rising and skewed incidence. On the plus side I have learned to be more comfortable with the complication. My increased index of suspicion has permitted me to deal more rapidly and effectively with the problem, thus resulting in a 62% salvage rate.

The immediate cause of expulsive hemorrhage during intraocular surgery is the sudden change in the intraocular pressure gradient when the eye is opened. These changes will be greater if the arterial pressure is chronically elevated due to hypertensive cardiovascular disease or is acutely elevated at the time of surgery due to anoxia, CO_2 build up, pressor drugs, or venous obstruction (valsalva-vomiting, bucking, coughing).

The underlying and contributing cause is the presence of arteriolar necrosis of the short and long posterior ciliary arteries. Manschot showed that the most common site is just after the vessel emerges from the zero pressure scleral wall to enter the superchoroidal space, where the intraocular pressure averages some 20 mm Hg. Arteriolar necrosis may be due to degenerative vascular disease, such as hypertensive arteriosclerotic cardiovascular disease and diabetes. It may also occur on a nutritional basis in an otherwise normal eye, since the vessel walls of the small arterioles are nourished by filtration only. The average filtration pressure of 30 mm Hg is the difference between the average intraocular arterial pressure of approximately 50 mm Hg minus the intraocular pressure of 20 mm Hg. If the patient has chronic glaucoma with an average tension of 35 mm Hg and the arterial pressure remains at 50, the resulting filtration pressure of only 15 mm Hg might result in inadequate nutrition of the vascular wall and subsequent arteriolar necrosis.

All three of the above factors played a significant role in at least 18 of my own expulsive hemorrhages. Only one occurred without an explanation. An additional two were the result of severe postoperative trauma resulting in wound rupture. Of the 18 cases with a plausible explanation, 3 were caused by a sudden rise in arterial pressure after the eye had been opened for a prolonged period. One occurred from bucking under anesthesia. The second occurred from severe uncontrollable coughing and the third from acute urinary retention that could not be immediately relieved, with the blood pressure suddenly increasing from 140/90 to 220/140. Fourteen patients had underlying conditions that would have a tendency to produce arteriolar necrosis. Eleven had hypertensive arteriosclerotic cardiovascular disease. One of the 11 also had diabetes and 3 also had chronic glaucoma. One of the latter had already lost the fellow eye from expulsive hemorrhage. Three patients had chronic glaucoma without hypertensive cardiovascular disease. Three patients had chronic glaucoma without hypertensive cardiovascular disease. Two patients had serious eye disease and were undergoing extensive reconstructive surgery in an effort to salvage the globe.

Fifteen of my patients had the expulsive hemorrhage during surgery. Four occurred during the early postoperative period and two occurred many months following keratoplasty from acute trauma with wound dehiscence.

This experience parallels the Baltimore series and not the Pakistan series,

where most of the latter were reported during the early postoperative period. I agree with Doctor Payne's theory that the speed of surgery in Pakistan, including rapid wound closure, probably masks the presence of an operative subchoroidal hemorrhage that does not fully manifest itself in the operating room only to be discovered at the time of the first postoperative dressing.

In my experience the incidence of expulsive hemorrhage is much higher with keratoplasty than with cataract extraction and is also more difficult to manage. I experienced nine expulsive hemorrhages in approximately 1500 keratoplasties, for an incidence of 0.6%. Four of these were extensive reconstructive keratoplasties; two were triple procedures, and one had lost their fellow eye from expulsive hemorrhage. By contrast the incidence of expulsive hemorrhage during cataract surgery was much lower, amounting to nine cases in 5250 cataract extractions, or an incidence of 0.17%. Further breakdown reveals that for routine intracapsular cataract extraction there were only three hemorrhages in 3250 cases for an incidence of 0.09%. When intracapsular cataract extraction was combined with an iris supported intraocular lens there were three hemorrhages in 800 cases for an incidence rising to 0.38%. With extracapsular surgery and posterior chamber intraocular lens insertion there were only two hemorrhages in 1200 cases for an incidence of 0.16%. I do not believe however, that the presence of the capsule is a significant factor and certainly affords little protection when a short ciliary artery ruptures.

Treatment consists of rapid wound closure to tamponade the bleeding vessels and early adequate scleral drainage. Vitrectomy may be performed after the bleeding has been controlled. I have salvaged 9 of 15 eyes with this technique when the hemorrhage occurred during surgery. Six were lost. All four eyes that developed a massive subchoroidal hemorrhage during the early postoperative period were salvaged without treatment but for the most part did poorly. One had no light perception, two were left with light perception, and one returned after 2 years to 20/30. The two eyes that suffered traumatic postkeratoplasty wound dehiscence were lost.

Finally we must realize that there is no way to avoid an expulsive hemorrhage. They will occur inspite of our best efforts. A heightened index of suspicion does permit us to operate more efficiently and effectively should an expulsive hemorrhage occur. We must be particularly wary of any patient who has had a previous expulsive hemorrhage as Doctor Payne's paper so amptly demonstrated. We can also be on guard when patients have hypertensive cardiovascular disease, chronic obstructive pulmonary disease, and chronic glaucoma and make every effort to control these conditions prior to surgery. It must be remembered however, that the vast majority of patients with these various conditions that are often uncontrolled, easily undergo successful and uneventful cataract surgery. Bucking under anesthesia can be totally illiminated by using local anesthetics. Severe coughing and a tendency to vomit prior to surgery must be controlled or preferably the case should be cancelled entirely. Surgery may be easily and safely performed on another day. One must also be willing to accept the risk of a higher incidence of expulsive hemorrhage if he is engaged in extensive reconstructive procedures

including total penetraing keratoplasties on seriously diseased eyes, triple procedures, etc.

In summary I agree completely with Doctor Payne and co-workers and congratulate them for their comprehensive review of the subject.

DR GEORGE SPAETH. I wish to stress the importance of prompt closure of the incision in patients experiencing an expulsive hemorrhage. If the eye can be closed prior to the extrusion of any contents other than iris, vitreous, and lens, the outlook for recovery of good vision is excellent. If heavy suture such as 7/0 are placed as soon as the corneal or scleral incision is made, and are inserted as a horizontal mattress so that they can be pulled up immediately, it is almost always impossible to close the eye promptly enough to assure saving the globe.

We've just reviewed my glaucoma surgical cases and found that expulsive hemorrhage is approximately ten times more common in patients with glaucoma than in those without glaucoma. Thus, preparation for this complication is especially important in such patients. With proper preparation an event which has been traditionally considered a catastrophe usually becomes merely a very troublesome complication, with eventual good recovery of visual function.

DR GEORGE HILTON. One of our staff has had over 12 cases of expulsive hemorrhage in his practice and he's had unusually good results by using his thumb. He pulls down the preplaced suture immediately and puts his thumb right over the limbal wound. It is usually a 5 to 6 mm wound, and he holds that for 10 minutes or so, and then adds his postplaced sutures. That method seems to make sense. We feel the two major factors are advanced age and hypotony. We can't do anything about the age, but hypotony is one thing we can manage and it should be avoided. So we would recommend no posterior sclerotomies but closure of the wound immediately with the thumb and permanent closure with additional sutures. One last thought, if one has had an expulsive hemorrhage in one eye and you are getting ready to operate on the second eye, wouldn't it be better not to lower the intraocular pressure, but to do the operation as a pars plana lensectomy and keep the intraocular pressure normal throughout the whole case. The entire operation could be done at 20 mm of mercury with the Fragmatome. This is strictly an arm chair idea. But we do encourage consideration of immediate tamponade and no sclerotomies.

DR A. EDWARD MAUMENEE. I, too, would like to congratulate Doctor Payne on a very excellent presentation and to see the change in the attitude of handling forward bulging of the vitreous. Of the previous discussors of the paper, several have pointed out that the most important thing to do is to tamponade the wound and allow the pressure to rise without doing a posterior sclerotomy. I have a paper that will appear in the June or July issue of the AJO in which I try to point out that I think, in most instances, the forward protrusion of vitreous occurs from acute uveal effusion. I have one patient who had interstitital keratitis and luetic choroiditis. I did a corneal transplant on her and was able to close the wound sufficiently

and because of her vitreous and ciliary body prolapse performed a sclerotomy for drainage. I drained her for 1 hour and all I got was clear serous fluid. Right at the end there was some slight blood staining. I have now collected about four other cases in addition to the six that I have reported in the AJO in whom I have looked at postoperatively with both transillumination and fluorescein angiography and can say that with acute uveal effusion this will absorb in a matter of 1 week. Whereas, hemorrhage takes 3 to 4 months sometimes to absorb. So, I too would make a plea to you to forget Verhoeff's stabbing technique of 1912, close the wound. Why uveal effusion can push the pressure up to 80 mm Hg in the eye I don't know, but it certainly will stop the bleeding and stop the uveal effusion and you will have a much better chance of ending up with a patient with excellent visual acuity.

Dr William Glew. Thank you, Doctor Guerry. I once had a case of an elderly woman I was following with cataracts not advanced enough to require surgery, and she developed a sudden loss of vision in one eye. The anterior chamber became shallow with transient increase in pressure and I was able to see a large subchoroidal hemorrhage. I have always considered this as a "preop" expulsive-type hemorrhage that never had a chance to expulse and I wanted to ask Doctor Payne if a similar case had been seen during the period of his study. It must be extremely rare.

Dr Morton Cox. I would like to share an experience of treating one patient whose expulsive choroidal hemorrhage caused a giant retinal tear. I first saw her 24 hours after cataract surgery. The corneal scleral wound had been successfully closed but she had a total hyphema which obscured all view of the posterior segment of the eye. Contact B ultrasonography demonstrated choroidal detachments and also indicated that the inferior retina had been dragged superiorly almost to the point of incarceration in the superior corneal scleral wound.

I first removed the clotted blood and vitreous from the anterior chamber with a suction cutter inserted between sutures in the corneal scleral wound. The anterior vitreous and hemorrhage immediately behind the iris was then excised via the same route. When the anterior segment was adequately visualized the infusion suction cutter and the infusion port was inserted through their usual positions in the pars plana. Sclerotomies were performed to drain straw colored fluid from the suprachoroidal space and the volume was simultaneously replaced with infusion through the infusion cannula. The inferior retina was torn 180 degrees at the ora serrata. The posterior flap was dragged forward and superiorly by the prolapsing vitreous. It was technically difficult to avoid the retina while trying to remove the prolapsing vitreous. For this reason a silicone oil bubble was infused through the ocutome infusion cannula. This bubble was then expanded as the vitreous was dissected from the prolapsing retina with the infusion suction cutter. Visual control was excellent because of the optical properties of the silicone much more satisfactory than it would have been had gas been used for the same purpose.

It was technically possible to remove all of the vitreous adherent to the inferior

retina while simultaneously expanding the silicone bubble. Finally, internal drainage was performed under the giant tear and the silicone expanded to push the entie retina back into its normal position.

The giant retinal tear was treated with transscleral cryotherapy under direct visual control. No scleral buckle was performed.

The silicone was removed from the eye without complication approximately 2 months postoperatively. The corrected visual acuity is now 20/30.

DR DANIEL M. TAYLOR. After hearing Doctor Maumenee I just have to make another 10-second comment. A agree that tamponading thru rapid wound closure is the most important therapeutic step that one can take in the management of operative expulsive hemorrhage. However, if you are performing a penetrating keratoplasty and the cornea has been totally removed, there is no way that you can quickly close the eye. In this instance drainage of the subchoroidal space becomes critical, in order to permit subsequent placement of the graft with a tamponading effect. If the hemorrhage is severe and it is apparent that the retina and choroid will be extruded thru the wound, then temporary tamponading can be accomplished by simply placing ones thumb over the keratoplasty site. This will gain time, and makes it possible to perform an eye salvaging posterior sclerotomy to neutralize the destructive expulsive forces. It may even be necessary to place a plastic catheter with an attached syringe in the subchoroidal space to assist drainage, while the graft is being sutured into position. I have had success with the latter technique on several occasions.

DR JOHN PAYNE. I greatly appreciate all the comments of the discussants, and particularly Doctor Taylor. As Doctor Taylor went through his slides, it seemed to me that his statistics on extracapsular and extracapsular with intraocular lens compared to intracapsular showed a trend toward a lower incidence of expulsive with extracapsular extraction. So I would like to study those a little more carefully. In regard to Doctor Spaeth, we had no way of getting at the data as to how many of those 13 thousand cataract cases were actually glaucoma patients too. The record rooms just didn't have that information and we didn't review 13 thousand individual charts. We only reviewed the charts of the 14 cases that had expulsives. In regard to Doctor Hilton, I certainly agree that a tamponade is the preferable way to do it, but sometimes you are unable to close the wound at all when the retina is prolapsing. In those cases I would certainly think a sclerotomy would be indicated to see if you can't get the retina back in the eye before you tamponade it. Also, in regard to Doctor Hilton's mention of a pars plana lensectomy as a possibility, I was told of a case at the Wilmer Meetings 3 weeks ago by a retina surgeon. He was referred a patient who had had an expulsive in the first eye with a detachment in the other. He was able to repair that detachment. Later on he proceded to do the cataract on this second eye by pars plana technique. Twelve hours after pars plana removal, the eye was lost, went to no light perception, from an expulsive hemorrhage. In regards to Doctor Maumenee's comments on choroidal effusion, certainly some of these expulsives may be preceded by effusions of

a serous or a serosanguinous nature. However, I certainly don't think all of them are preceded by effusions, because some of the very sudden ones, if they are drained, show blood right away. Doctor Glew presents an interesting case of a preop expulsive. I don't know quite what to make of that without having a more complete history. I appreciated Doctor Cox's comments about the giant tears.