

THE PATHOGENESIS OF RETINAL DETACHMENT WITH MORNING GLORY DISC AND OPTIC PIT*

BY *A. Rodman Irvine*, MD, *J. Brooks Crawford*, MD, AND

(BY INVITATION) *John H. Sullivan*, MD

INTRODUCTION

CONTROVERSY EXISTS OVER THE SOURCE OF SUBRETINAL FLUID IN RETINAL DETACHMENTS associated with two congenital optic nerve anomalies—morning glory disc and optic pit. Some authors have recently reported small tears adjacent to the optic nerve in patients with retinal detachment and morning glory disc.¹⁻³ Others have argued that the liquid vitreous reaches the subretinal space not via a retinal tear, but rather via the optic nerve pit or a developmental defect in the optic nerve.⁴ Another group have proposed that the subretinal fluid does not come from the vitreous but rather from cerebrospinal fluid.^{5,6} The passage of the radiopaque dye metrizamide from the subarachnoid space into the subretinal fluid seems conclusive evidence of a connection between the two.⁶ Finally, one report suggests that the fluid arises from the orbital tissues.⁷ A question in this controversy is whether morning glory disc and optic nerve pit represent two points in the spectrum of colobomas of the optic nerve entrance and share a common mechanism of subretinal fluid formation, or whether they are separate entities with different mechanisms of retinal detachment.⁸⁻¹⁰ This paper reports a serendipitous intraoperative finding in a child with morning glory disc and compares the biopsy specimen from that case with a case of optic pit from our pathology files and cases previously reported. This is the first case with histopathology from a well-documented, typical morning glory disc and validates the findings in those histopathological specimens which had been felt possible but atypical or undocumented cases of this condition.^{8,11-13} The findings indicate that morning glory disc and congenital pit of the optic nerve do represent two points in the spectrum of presentation of coloboma of the optic nerve

*From the Department of Ophthalmology, University of California, San Francisco, Medical Center. Supported in part by CORE grant EY 02162B.

entrance and share basic similarities which suggest that the vitreous cavity, subarachnoid space, and subretinal space may all be interconnected in these conditions.

CASE HISTORY

This 3-year-old boy was found to have a morning glory disc in the right eye at age 4 months, when he was examined because of strabismus. Patching of the left eye 4 hours per day was instituted and was well tolerated. The child could play actively with the left eye patched. At 2.8 years, he was examined and vision was estimated to be 20/400 in the right eye and 20/30 in the left. The next month he began complaining of decreased vision during the periods that his left eye was patched and he was found to have a total retinal detachment in the right eye. Examination under anesthesia revealed no retinal breaks, either peripherally or posteriorly. He was followed for 2 months and when there was no spontaneous reattachment, a vitrectomy with air-fluid exchange and external drainage of subretinal fluid was performed. During this vitrectomy search for a posterior retinal tear was repeated and none was found. The retina was reattached transiently but as soon as the air-bubble began to resorb, it redetached.

The family then moved to California and the child was first seen at the University of California, San Francisco Medical Center at age 3.2 years. He was found to have a bullous total retinal detachment with a morning glory disc in the right eye. Because of the history of useful vision in that eye prior to its detachment, it was elected to perform an optic nerve sheath fenestration in hopes of reattaching the retina.

At surgery, the optic nerve was exposed medially by a transconjunctival approach. After performing a 180° conjunctival peritomy, the medial rectus muscle was detached from the globe. Sutures were passed through the stump of the medial rectus and beneath the superior and inferior recti to abduct the globe. A modified tracheal dilator was used to expose the optic nerve sheath.¹⁴ Using the operating microscope, the ciliary vessels were brushed aside and a slit was made with a meringotomy knife into the optic nerve sheath 5 mm from the globe. A 4 mm by 2 mm window was resected from the sheath with Belluci scissors and submitted for histopathology. When the sheath was opened, cerebrospinal fluid began to escape along with viscous material resembling vitreous.

Throughout surgery, the eye had gradually become soft and collapsed, presumably because of the persistent pressure on the globe necessitated to expose the optic nerve sheath and the fact that previous vitrectomy had

produced a liquid vitreous. A mixture of sterile air and 33% sulphur hexafluoride gas was injected into the vitreous through the pars plana to reform the globe and help flatten the retina. To our surprise, once the globe was reformed and the pressure brought to normal or slightly above, gas was seen bubbling out through the opening in the optic nerve sheath. The globe remained formed and the bubbling ceased once the intraocular pressure seemed normal or slightly below. To convince ourselves of the validity of this phenomenon, we injected a bit more gas via the pars plana, and again bubbles were seen escaping through the hole in the optic nerve sheath. There was thus definite communication between the vitreous cavity and this perineural space, despite the fact that there was no apparent optic nerve pit, nor peripapillary retinal break.

On the first day postoperative, the retina was flat and the gas bubble filled the vitreous cavity. As the bubble began to recede during the first few days postoperatively, however, the bullous detachment began to recur and we felt surgery had failed. At examination 3 weeks postoperative, however, the bubble was gone and the retina was totally flat. It has remained so for the past 6 months (Fig 1).

HISTOPATHOLOGY

The tissue received for histopathologic examination measured $4 \times 2.5 \times 1.5$ mm. Sections were made through this tissue. The tissue showed a collagenous layer and a deeper remnant resembling sensory retina, retinal pigment epithelium, and vitreous (Fig 2). The part resembling neural retina showed a nuclear layer with cells having round and spindle-shaped basophilic nuclei and eosinophilic cytoplasm. Another layer of eosinophilic cytoplasm with few cell nuclei resembled a plexiform layer. No well defined basement membrane could be identified. A layer of cells was heavily packed with large melanin granules of a type seen in retinal pigment epithelium. Pale eosinophilic, slightly fibrillar material on one surface of the more cellular part of the specimen demonstrated mucopolysaccharides sensitive to hyaluronidase.

This biopsy specimen was compared with the tissue in an eye with an optic pit in our histopathology files (Fig 3). The eye with an optic pit showed a focal enlargement of the scleral opening (the "pit") through which incompletely differentiated retinal tissue herniated alongside the optic nerve, just as reported by Gass.⁵ The herniated tissue in these cases with optic pit looked identical to that in the biopsy specimen from our patient with morning glory disc.

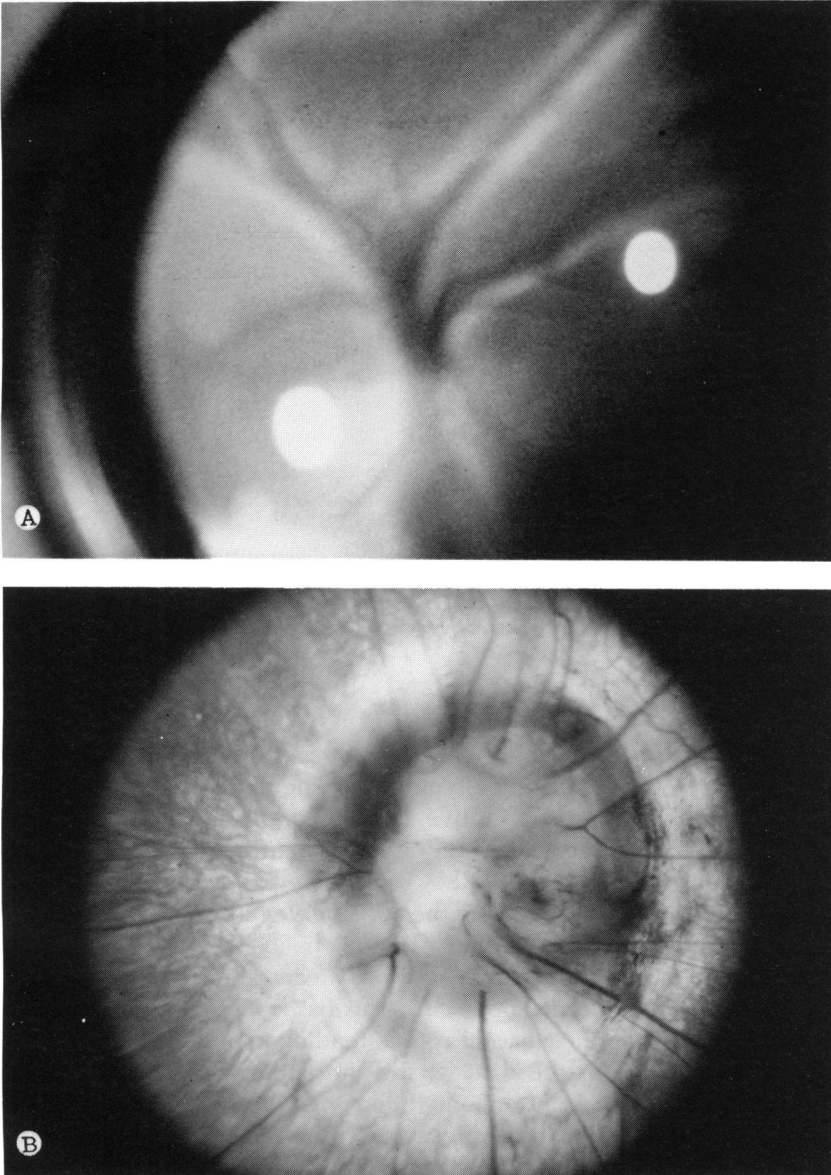


FIGURE 1

Morning glory disc. A: Preoperative appearance with bullous retinal detachment hiding disc. B: Postoperatively, retina has flattened and an unobstructed view of disc shows typical pattern with a wide scleral rim, collagenous or glial tissue filling central portion of disc and vessels radiating from disc-like spokes of a wheel. No obvious pit is recognized.

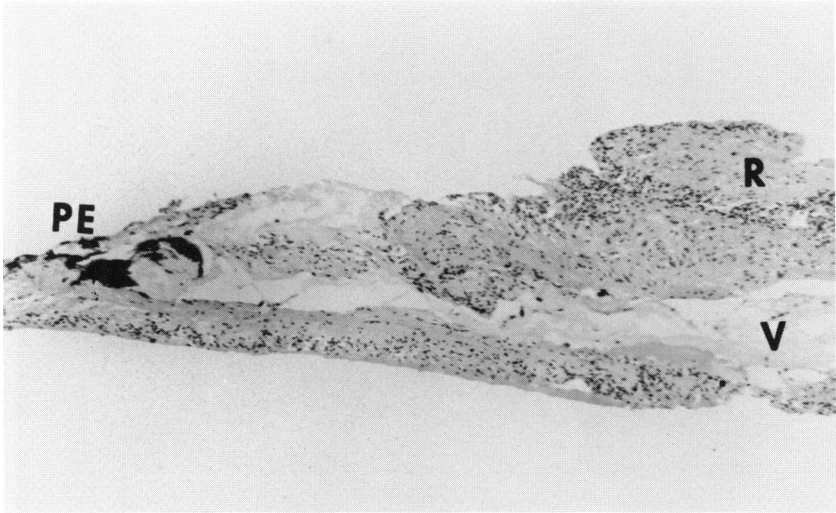


FIGURE 2

Histopathology of biopsy specimen shows incompletely differentiated sensory retina with nuclear layering (R), a layer of mucosysaccharide material sensitive to hyaluronidase (V), and cells with large melanin granules of type seen in retinal pigment epithelium (PE) (original magnification, $\times 30$).

DISCUSSION

Histopathology is not available on previous cases with fundus examination and photography documenting a typical morning glory disc. Some cases felt to be probably representative of this condition have been described.^{8,12,13} These cases, however, either lacked the fundus description or photographs to verify whether they represented morning glory discs or they appeared as tumors involving the optic nerve rather than having the typical morning glory appearance. Histopathology in these cases has shown certain basic similarities. There was a central mass of connective tissue in place of the normal optic cup. This tissue often appeared to put tangential traction on the adjacent retina, tending to pull the retina up in folds over the edge of the disc, giving the appearance of tumor and perhaps adding a tractional component that might help in development of the detachment. The lamina cribrosa was absent or incomplete and vitreous was sometimes seen herniating posteriorly through the area where the lamina was absent. There was a markedly enlarged scleral opening with poorly differentiated retinal tissue and pigment epithelium herniating through the scleral opening down alongside the optic nerve to abut the subarachnoid space. These reported cases have thus shown a basic

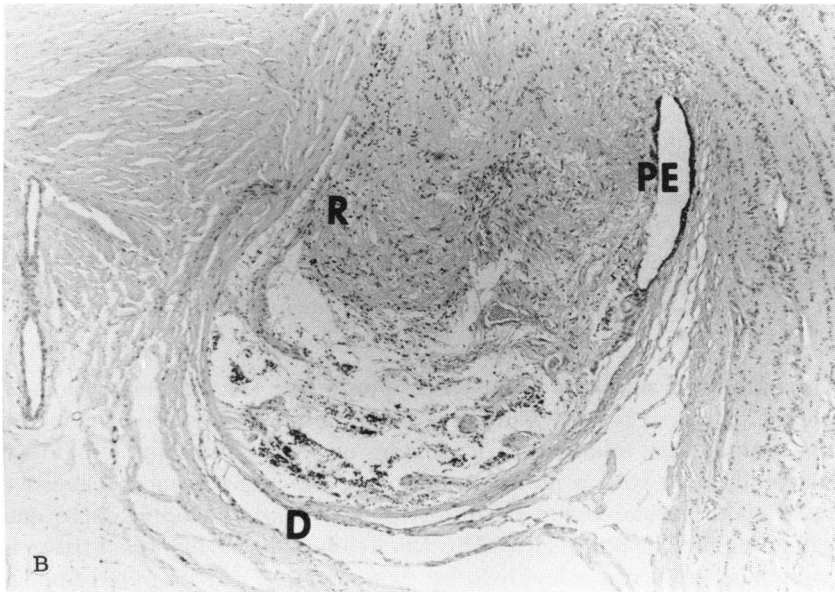
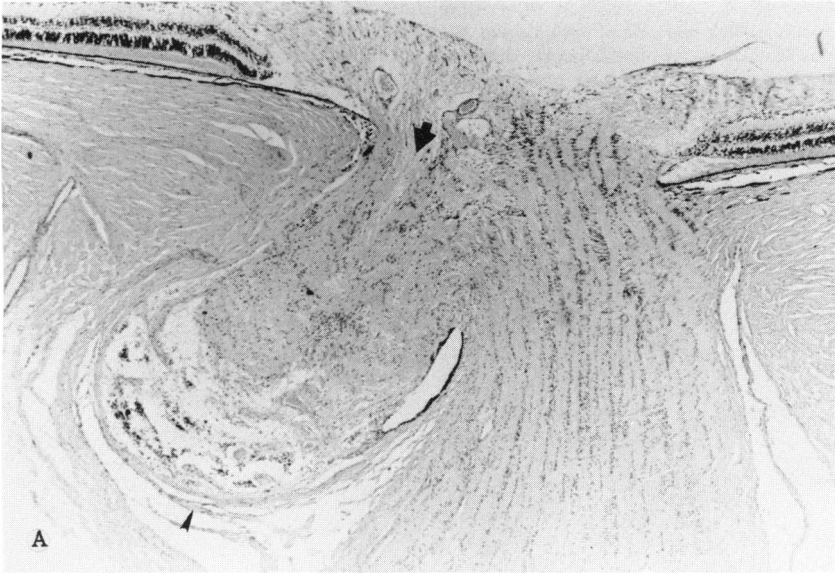


FIGURE 3

Optic pit. A: Low power view shows herniation of retinal tissue through enlarged scleral opening along one side of optic nerve. As described by Gass, connective tissue separating this knuckle of herniated, poorly differentiated retinal tissue from subarachnoid space is tenuous and could well have porous openings (*small arrow*). At other end, potential space between two walls of this outpouching of retinal tissue would be, at least theoretically, in continuity with vitreous (*large arrow*) (original magnification, $\times 10$). B: A higher power view shows dura (D), poorly differentiated retinal tissue (R), and pigment epithelium (PE) just as in biopsy specimen in Fig 1 (original magnification, $\times 30$).

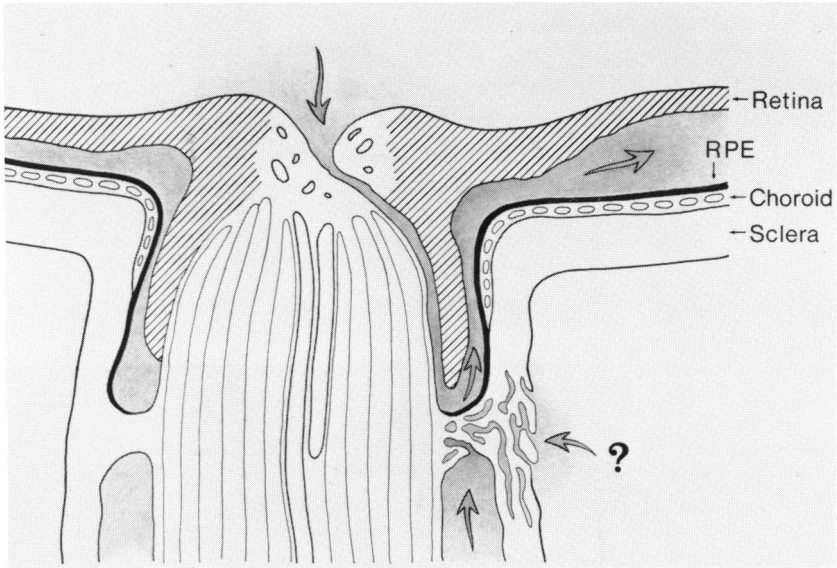


FIGURE 4

Schematic representation of possible intercommunication of vitreous cavity, subretinal space, subarachnoid space, and orbit due to porous nature and incomplete differentiation of herniated tissues in an optic pit or morning glory disc.

histopathologic similarity to the cases of optic pit. The difference is one of degree. Whereas the eye with an optic pit demonstrates a focal defect in the peripapillary sclera, with herniation of poorly differentiated retinal tissue, the eye with a morning glory disc has a much more extensive defect with retinal tissue herniated 360° around the optic nerve and extending further posteriorly. This staphylomatous herniation of tissue is sometimes extensive enough to be demonstrated on computed tomography scan, although a computed tomography scan on our patient, at 14 months of age, failed to reveal any such obvious, gross defect.

The present case shows that a typical morning glory disc with associated detachment had a staphylomatous outpouching of redundant, poorly differentiated retinal tissue alongside the optic nerve similar to that described in the cases felt to represent possible histologic examples,^{8,12,13} and, therefore, lends further support to the idea that these cases do illustrate the type defect found in morning glory disc. This seems to be the same defect that is present, though to a lesser degree, in congenital pit of the optic nerve. The present case also suggests a solution to the controversy between those who argue that the subretinal fluid in non-rhegmatogenous detachments with these anomalous discs comes from the vitreous and those who argue that it comes from the subarachnoid space or orbital tissues. The passage of gas bubbles from the vitreous cavity into the perineural space and out the window in the sheath into the orbit suggests that the vitreous, subretinal, subarachnoid, and even orbital spaces may all be interconnected due to the incomplete differentiation and porous nature of the herniated tissues in the coloboma (Fig 4).

ACKNOWLEDGMENT

Dr Thomas C. O'Neil referred the patient and encouraged the surgical efforts that led to retinal reattachment.

REFERENCES

1. von Fricken MA, Dhungel R: Retinal detachment in the morning glory syndrome: Pathology and management. *Retina* 1984; 4:97-99.
2. Harris MJ, DeBustros S, Michels RG, et al: Treatment of combined traction-rhegmatogenous retinal detachment in the morning glory syndrome. *Retina* 1984; 4:249-252.
3. Akigama K, Azuman X, Hida T, et al: Retinal detachment in morning glory syndrome. *Ophthalmic Surg* 1984; 15:841-843.
4. Brown GC, Shields JA, Patty BE, et al: Congenital pits of the optic nerve head: I. Experimental studies in collie dogs. *Arch Ophthalmol* 1979; 97:1341-1344.
5. Gass JDM: Serous detachment of the macula secondary to congenital pit of the optic nervehead. *Am J Ophthalmol* 1969; 67:821-849.
6. Chang S, Haik BG, Ellsworth RM, et al: Treatment of total retinal detachment in morning glory syndrome. *Am J Ophthalmol* 1984; 97:596-600.
7. Lin CCL, Tso MOM, Vygantas CM: Coloboma of the optic nerve associated with serous maculopathy: A clinicopathologic correlative study. *Arch Ophthalmol* 1984; 102:1651-1654.
8. Rock JH, Wright GF: Coloboma of the optic nerve entrance. *Br J Ophthalmol* 1966; 50:705-709.
9. Jensen PE, Kalina RE: Congenital anomalies of the optic disc. *Am J Ophthalmol* 1976; 82:27-31.
10. Beyer WB, Quencer RM, Osher RH: Morning glory syndrome: A functional analysis including fluorescein angiography, ultrasonography, and computerized tomography. *Ophthalmology* 1982; 89:1362-1367.
11. Haik BG, Greenstein SH, Smith ME, et al: Retinal detachment in the morning glory

- anomaly. *Ophthalmology* 1984; 91:1638-1647.
12. Pedler C: Unusual coloboma of the optic nerve entrance. *Br J Ophthalmol* 1961; 45:803-807.
 13. Cogan DG: Coloboma of the optic nerve with overlay of peripapillary retina. *Br J Ophthalmol* 1978; 62:347-350.
 14. Galbraith JEK, Sullivan JH: Decompression of the perioptic meninges for the relief of papilledema. *Am J Ophthalmol* 1973; 76:687-692.

DISCUSSION

DR WILLIAM H. JARRETT II. Colobomatous (staphylomatous) malformations of the optic nerve have been recognized for many years; artist's drawings of this anomaly can be found in older textbooks and atlases. In 1970, Kindler coined the term "morning glory optic disc syndrome" to describe this congenital anomaly of the optic disc, likening it to the flower of that name.

The salient characteristics of the morning glory optic disc syndrome include the following: enlarged optic papilla ($\times 2$ to 4); funnel-shaped excavation of the disc; glial hyperplasia covering the center of the disc; radially oriented exit of vessels from the disc; vascular sheathing and stretching; annular peripapillary pigment epithelial disturbance; progressive traction on the retina adjacent to the disc.

Detachment of the retina is a frequent complication of the morning glory optic disc syndrome. Of the ten cases described in Kindler's article, three developed retinal detachment in the affected eye. Other authors subsequently published on retinal detachment in association with this disc anomaly. Since no retinal breaks were found in any of these cases, the detachments were considered to be non-rhegmatogenous in origin, and very few were operated. Haik et al reported on 32 eyes in 30 patients with the morning glory optic disc syndrome; 11 of these eyes developed a detached retina. Most of these cases were not operated; interestingly, four of the detachments spontaneously reattached, an average of 7½ years after the onset of the detachment; two later redetached. Chang et al was the first to report successful retinal reattachment after removal of a segment of dura from the distal portion of the optic nerve. The retina became reattached, but only after a second procedure to drain subretinal fluid. This was the case, referred to by Doctor Irvine, in which metrizamide dye injected into the subarachnoid space was demonstrated in the subretinal space. In both of these papers, the authors postulated an open communication between the subarachnoid space and the subretinal space to explain the pathogenesis of the detachment.

In 1984, von Fricken was the first to identify a retinal tear in a retinal detachment complicating the morning glory anomaly. In his case, a slit-like hole was found in the disc structure itself, which was thought to account for the detachment. A similar case was reported by Michels and co-workers. Both cases were repaired with pars plana vitrectomy techniques, with laser photocoagulation applied around the disc in Michels' case. A report by Beyer et al from the Bascom Palmer Eye Institute is germane to the finding of retinal tears near the disc in such cases. The authors observed 10 cases over an extended time period and were able to document, by serial photography, glial hyperplasia on the disc, with

progressive tangential traction on the adjacent retina. In one case, macular xanthophyllic pigment was demonstrated within the abnormal disc structure itself. These observations introduced a dynamic concept to this disease entity, and it takes very little imagination to see how a peripapillary retinal break could form, causing a rhegmatogenous retinal detachment. Thus, the literature documents both rhegmatogenous and nonrhegmatogenous retinal detachment with this peculiar disc anomaly.

There is ample evidence that the morning glory optic disc syndrome and congenital hole or pit of the optic disc are similar clinical entities, differing only in the degree of abnormality. When retinal detachment occurs in these entities, the source of the subretinal fluid is in dispute. One school holds that the subretinal fluid comes from the vitreous cavity and gains access to the subretinal space via a direct communication through the pit. Precisely this route was demonstrated histologically in a collie dog with an optic nerve pit. Others believe that the subretinal fluid is actually cerebral spinal fluid which gains access to the subretinal space via an abnormal communication with the subarachnoid space.

Doctor Irvine and co-authors have expanded our knowledge of this fascinating anomaly by demonstrating, for the first time, the presence of retinal tissue in the perineural space. This is clearly analogous to the "nests" of retinal tissue which have been found in the nerve in cases of optic nerve pit which have been examined histologically. Thus I believe he is entirely correct in asserting a close kinship between the morning glory disc syndrome and congenital hole or pit of the optic disc.

Clinically, Doctor Irvine has demonstrated beyond question a communication between the vitreous cavity and the subarachnoid space; air injected into the vitreous cavity bubbled out through the dural opening in the nerve. Unfortunately, we still don't know where the subretinal came from in his case. While a fistula was demonstrated between the vitreous and the subarachnoid space, we have no absolute proof of a fistulous communication between the subarachnoid space and the subretinal space.

What is clearly needed, and thus far lacking, is a complete clinicopathologic correlation in which a well documented, well studied clinical case eventually is studied histologically, with special efforts to demonstrate communications between the vitreous, subarachnoid space and the subretinal space.

I should like first to offer a suggestion to the author and secondly to ask him some crucial questions. In future such cases, when the subretinal fluid is drained, I suggest that the fluid be collected and subjected to biochemical analysis, to try to settle once and for all the questions of whether this is spinal fluid or fluid derived from vitreous cavity. Only when we have characterized the subretinal fluid biochemically, can we answer the question as to whether this fluid comes from the vitreous or is in deed spinal fluid in a most unusual place.

Finally, I pose these questions to Doctor Irvine: what precipitated the detachment in the first place in this child; if the subretinal fluid indeed comes from the subarachnoid space, how is the pressure gradient between the eye and the central nervous system overcome? Finally, to what do you attribute the eventual reat-

tachment, which occurred some weeks after the initial surgery was performed?

I congratulate Doctor Irvine and his colleagues on a fine paper and I appreciate the opportunity of commenting on it.

DR DAVID G. COGAN. I would like to comment not only on this extraordinarily interesting paper but on the superb presentation by Doctor Irvine. He is a real worthy of the Irvine block.

Perhaps a few words may be permitted regarding the gray halo about the disc, shown well in Doctor Irvine's photograph and frequently in other cases of the morning glory appearance. This is due in part to the hyperplasia of the pigment epithelium but more especially because the pigment epithelium in these cases extends a considerable distance posteriorward ensheathing the "coloboma." In consequence we are viewing the pigment epithelium tangentially through many cells rather than perpendicularly through a single cell layer. This bears on the uniqueness of the pigment epithelial termination at the nerve head in the normal eye. There must be few, if any, other places in the body where there is a normal "hole" in an epithelial layer.

My comments are relevant to the morning glory syndrome insofar as the epithelium does not seem to be able in these cases to find its signal for a normal termination; in consequence, it continues posteriorward in sheets and thereby contributes to the characteristic ophthalmoscopic appearance.

DR JERRY A. SHIELDS. I would like to congratulate Doctor Irvine on his extremely interesting paper. He alluded to the studies of Doctor Brown, Doctor Goldberg, Doctor Patty, and me regarding the source of the subretinal fluid in the collie dog, who can develop an optic pit and retinal detachment similar to that seen in the human.

In that experiment, we tried to establish a connection between the subarachnoid space and the subretinal space by injecting india ink into the subarachnoid space of the optic nerve. We were unable to get the india ink to pass from the subarachnoid space into the subretinal space when this was done. However, when we injected the india ink into the vitreous cavity through the pars plana, it did enter the pit and appeared in the subretinal space. Microscopic examination of these dogs eyes showed a direct continuation between the vitreous cavity, and optic pit, and the subretinal space. We could not demonstrate such a continuation between the subarachnoid space, the optic pit, and the subretinal space. This suggested that in the dog, the subretinal fluid comes from the vitreous into the subretinal space by way of the optic pit.

In humans, there is indirect evidence that the fluid comes from the vitreous. Although the optic pit is present at birth, the patient does not develop the symptomatic retinal detachment until later in life when the vitreous begins to become liquefied. We have observed liquid vitreous with slit lamp biomicroscopy in the region of the pit in patients who develop a detachment. We speculate that when the posterior vitreous becomes liquefied, it passes through the pit and into the subretinal space leading to the detachment. On the basis of these animal

studies and clinical observations in humans, we believe that the liquefied vitreous is the source of the subretinal fluid associated with optic pits in both dogs and humans.

Once again, I would like to thank Doctor Irvine for this most interesting contribution.

DR ALEX IRVINE. I thank Doctor Jarrett and all of the discussants for their points. Doctor Jarrett pointed out correctly that our case demonstrated a communication between the vitreous cavity and the perineural space, but didn't show any definite communication with the subretinal fluid. I think, however, that the fact that, without our draining the subretinal fluid, the retina did flatten, seems to indicate a communication. The next question asked how we thought making a fistula back alongside the optic nerve led to permanent reattachment in these cases. That's an awfully good question. Doctors Chang and Ellsworth, who were the first to cure such a case in this way, postulated that by making that hole and creating a collapse of the subarachnoid space around the nerve at that point, they incited scar tissue to bind down and close the subarachnoid space at that point. I don't now whether that's true. But I guess that's as good an explanation as stating that the fistula allows fluid from either the vitreous or cerebrospinal fluid (CSF) to drain into the orbit rather than the subretinal space.

The question of why these patients with a congenital defect don't detach until later in life is stimulating. I think it may relate to Doctor Shield's idea that the detachment later in life goes along with liquefaction of the vitreous, except that with the optic pit we often see them detaching at age 10 and 12, and here is this child with morning glory disc detaching at age 3. There is not much liquefaction of the vitreous at that stage. I would think that if our pits and morning glory disc were starting to detach at age 40 this idea would seem more plausible. So I don't know why they go to this age and then detach. Some have felt that in the morning glory disc syndrome the fibrous tissue on the surface of the disc tends to contract, and in doing so puts tangential pull on the perineural retina and may start the retinal separation in that manner. I think Doctor Cogan's case showed such contraction.

The fact was mentioned that the pressure gradient between the intraocular fluid and the CSF would make fluid flow out of the eye into the CSF rather than the other way. I'm not sure that is a valid point. Once the retina starts to detach and the potential subretinal space becomes a real one, fluid seems to move into it regardless of pressure gradients.

Doctor Cogan's point about the pigment epithelium's unusual nature in this area is an interesting one. There is so much work going on presently at Wilmer about pigment epithelial contraction and PVR that I would like to say that maybe we should consider this report on morning glory disc a part of our work at UC on PVF; then we could be presenting it just to be ahead of the Wilmer group in at least one instance of PVR work.

Doctor Shields' point on the collie model is a good one. I would like to say that whereas he showed this one model where the fluid is coming definitely from the

vitreous through the optic pit into the subretinal space, others like Doctor Ellsworth have shown that, at least in some human cases, you can demonstrate by dye injected into the lumbar space that there is passage of material from the CSF into the subretinal space. Together they may indicate that you've got a potential communication between all three spaces (vitreous, CSF, and subretinal fluid) and in some cases one would be a little more at fault and in other cases it may be the other. The main theme of my presentation is to state that the potential is there for them all to be communicating in this area of herniated tissue around the optic nerve, and it is not a question of which one is responsible but rather that in different cases either one may be the source of the subretinal fluid.