

ACUTE EXUDATIVE POLYMORPHOUS VITELLIFORM MACULOPATHY*

BY *J. Donald M. Gass*, MD, *Elaine L. Chuang*, MD

(BY INVITATION), AND (BY INVITATION) *Harold Granek*, MD

INTRODUCTION

THIS REPORT CONCERNS TWO PATIENTS WHO PRESENTED BECAUSE OF headaches and bilateral loss of vision associated with multiple yellow-white subretinal lesions and exudative macular detachment. Both showed unusual angiographic findings, and both experienced return of normal vision following systemic corticosteroid therapy. Resolution of the exudative retinal detachment was followed by development of unusual multifocal polymorphous vitelliform lesions that showed a changing pattern and incomplete resolution over a period of 1 to 2 years.

CASE REPORTS

CASE 1

On June 30, 1982, an apparently healthy 24-year-old blonde man presented with a 2-day history of acute headaches and progressive loss of vision in both eyes. His past medical history and family history were unremarkable. Visual acuity in the right eye was 20/50 and in the left eye was 20/40. The anterior ocular segments were normal except for bilateral sluggish pupillary reaction. Applanation pressure was 20 mm Hg bilaterally. There was a similar fundusoscopic picture in both eyes. In the central macular area, there was an oval-shaped exudative detachment surrounded by fine radiating retinal folds and numerous oval, round and curvilinear yellow-white lesions underlying confluent blister-like areas of serous retinal detachment (Fig 1A and B). These latter changes extended to just beyond the major retinal vascular arcades temporally and the peripapillary area nasally. Two small pigmented nevi were present in the extramacular area of the right eye, and one 5-disc-diameter-sized pigmented lesion interpreted as a nevus with many overlying drusen was present temporally in the left eye (Fig 1C). The optic disc and retinal

*From the Bascom Palmer Eye Institute, University of Miami School of Medicine, Miami, Florida.

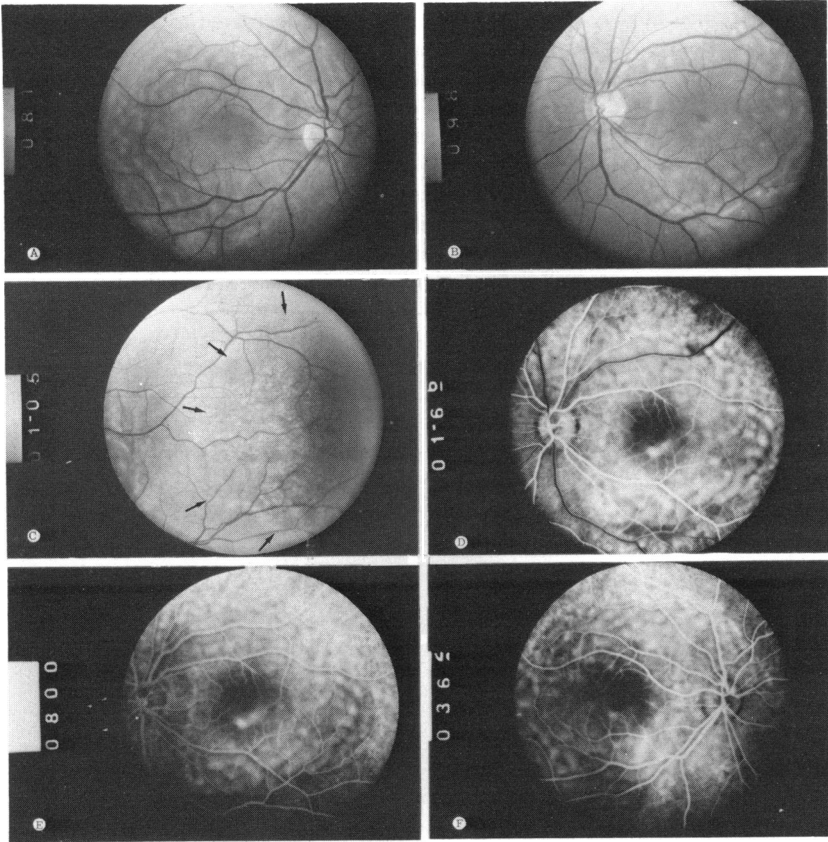


FIGURE 1

Case 1. June 30, 1982. A: Right eye. B: Left eye. C: Left eye, large pigmented nevus (*arrows*) with drusen. D and E: Angiography, left eye. F: Angiography, right eye.

vessels were normal. Early phase arteriovenous angiograms showed marked hyperfluorescence corresponding with the yellow-white lesions in the paracentral areas (Fig 1D and E). Later photographs showed evidence of staining of these lesions but only minimal evidence of diffusion of dye into the surrounding subretinal exudation (Fig 1F). The diagnoses entertained by the local physician were acute posterior multifocal placoid pigment epitheliopathy and Harada's disease. The unusual angiographic features and the presence of multiple pigmented choroidal tumors suggested to one of us (JDMG) the possible diagnosis of bilateral diffuse melanocytic proliferation of the uveal tract. Medical evaluation, however, failed to reveal evidence of systemic disease. Prednisone 80 mg/day by mouth was prescribed. One week later the visual acuity had improved to 20/20 in the right eye and 20/25 in the left eye. As the corticosteroid dosage was tapered the following week

the subretinal fluid reaccumulated and the acuity decreased to 20/40 both eyes (OU). The dosage was increased and the subretinal exudate lessened. By October 4, 1982, the patient was no longer taking cortisone. The visual acuity in the right eye was 20/25 and in the left eye was 20/20. There was still some evidence of subretinal fluid, particularly in the temporal aspect of both maculas (Fig 2A and B). The yellow-white lesions had been replaced by a different pattern of more discrete smaller and more intensely yellow flecks. On December 6, 1982, his visual acuity was 20/20 and J-1 in both eyes. There was less subretinal fluid, but more accumulation of subretinal yellowish material into a meniscus at the inferior macular region of the right eye and a less well-defined meniscus in the same area in the left eye (Fig

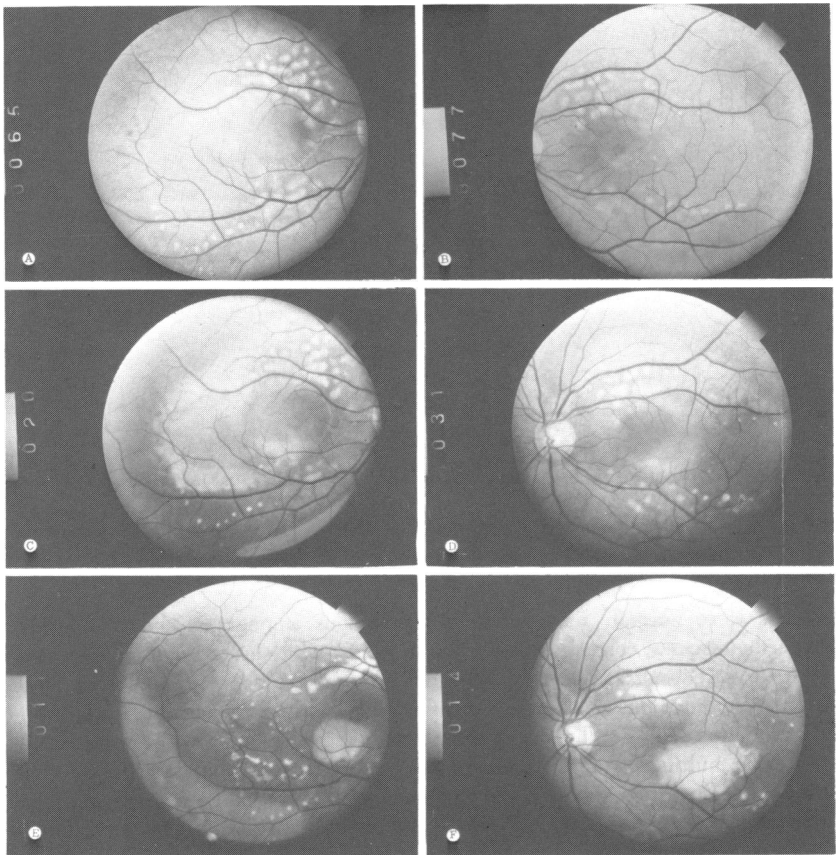


FIGURE 2

Case 1. A: Right eye, October 4, 1982. B: Left eye, October 4, 1982. C: Right eye, December 6, 1982. D: Left eye, December 6, 1982. E: Right eye, June 20, 1983. F: Left eye, June 20, 1983.

2C and D). A repeat fluorescein angiogram showed complete resolution of all the early hyperfluorescent lesions except for one small area in the inferior paracentral region of both eyes. The yellowish lesions were nonfluorescent. On February 24, 1983, an electroretinogram showed normal photopic and scotopic responses and subnormal electro-oculographic (EOG) responses with the light:dark ratio in the right eye of 1.47 and in the left eye of 1.58. On June 20, 1983, the patient was asymptomatic. Visual acuity in the right eye was 20/20 and in the left eye was 20/25. There were less yellow deposits in the peripheral macular areas but there was a discrete yellow lesion in the paracentral region of both eyes (Fig 2E and F). On June 25, 1984, the patient was 20/20 and J-1 OU. There had been further resolution of the yellowish subretinal material, but small yellow round lesions arranged in ring-shaped configuration remained (Fig 3A and B).

CASE 2

A healthy 30-year-old lightly pigmented white male presented on August 22, 1984, with a 1-month complaint of blurring in each eye, and a 1-week history of severe headaches. There were no auditory, dermatologic, or neurologic symptoms. His visual acuity in both eyes was 20/60. There were a few vitreous cells present. He had fundoscopic and fluorescein angiographic changes identical to those described in case 1 (Fig 4A to E). The patient was given prednisone 80 mg/day by mouth and by September his visual acuity had improved to 20/30 OU. The steroids were tapered to 40 mg/day. By November, 1984, he was 20/20 OU. Between then and April, 1985, there was a progressive accumulation of yellowish material in the macula and peripapillary areas of both eyes. This formed a fluid level in the inferior macular region bilaterally (Figs 4F and 5A to D). Fluorescein angiography revealed that this yellow material obstructed the background fluorescence (Fig 5E and F). Some of the focal areas of early hyperfluorescence were still evident at that time. The patient was asymptomatic. He had been maintained on prednisone 10 mg every other day, and except for an attack of gout, he had remained healthy. Medical evaluation including complete blood counts, VDRL, immunoglobulins, sedimentation rates and U/A were all normal except for some elevation of the gamma globulins fractions. The prednisone was discontinued.

In July 1985, an electroretinogram was normal. An EOG showed no evidence of light rise. By October 15, 1985, there had been considerable resolution of the subretinal yellow material which was now distributed in multiple small, generally round flecks throughout the macula and juxtapapillary areas (Fig 6A and B). There was still some evidence of confluence of this material to form menisci. Angiography demonstrated nonfluorescence in the areas of the yellow lesions. Some round hyperfluorescent window defects in the pigment epithelium were still evident in areas between the yellow lesions (Fig 6C). The patient was last seen in January, 1986, with 20/15 visual acuity in both eyes. He was asymptomatic. No vitreous cells were present. There was further resolution of the yellow lesions.

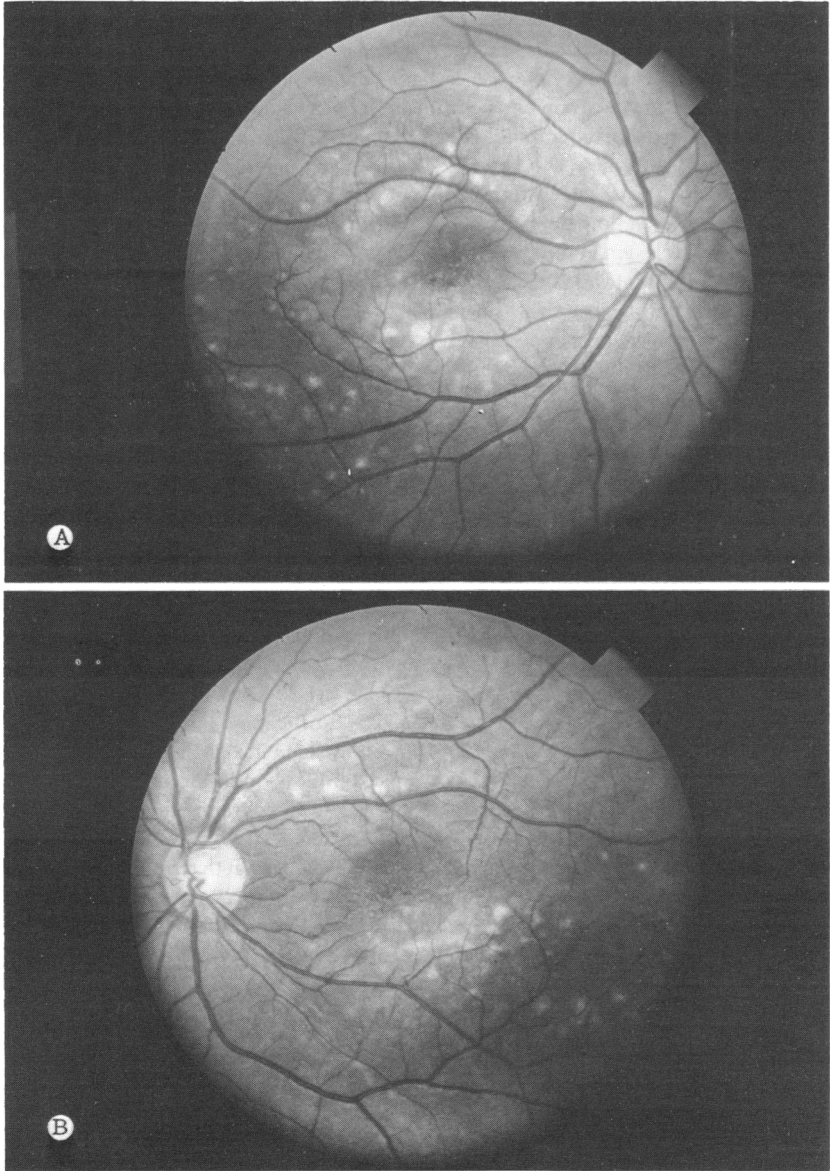


FIGURE 3
Case 1. June 25, 1984. A: Right eye. B: Left eye.

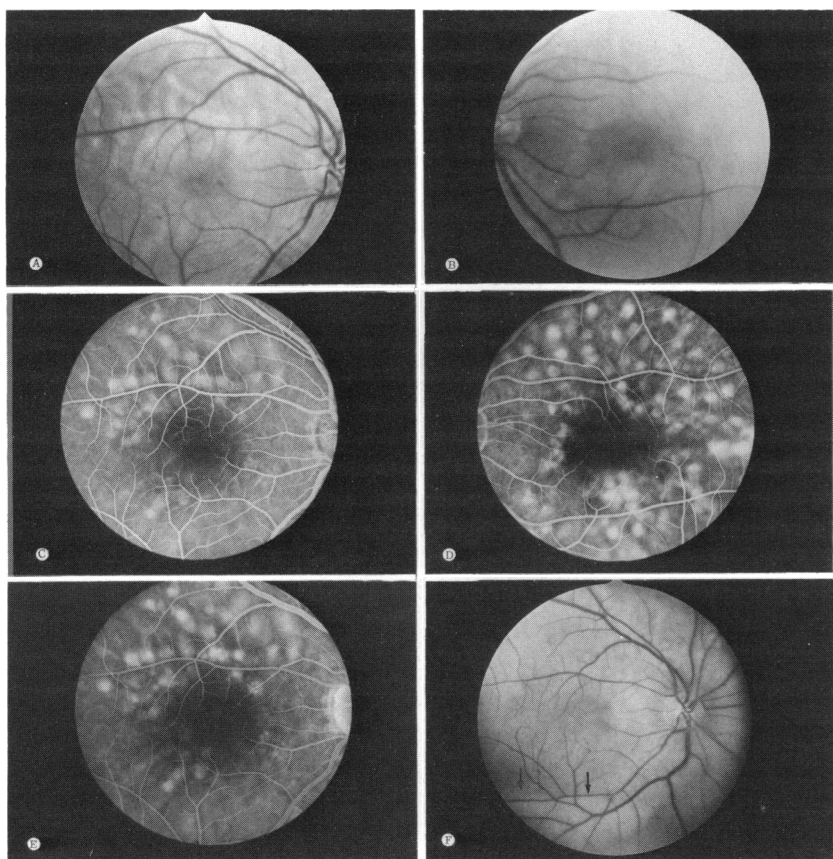


FIGURE 4

Case 2. A: Right eye, August 22, 1984. B: Left eye. C: Right eye arteriovenous phase angiogram. D: Left eye angiogram. E: Right eye angiogram. F: Right eye, December 4, 1984. Note meniscus of yellow subretinal material (arrows).

DISCUSSION

The apparent therapeutic response to corticosteroid in both patients suggests, but does not prove, that the fundus disorder was caused by an inflammatory and possibly an immune mediated disorder. One patient had a few vitreous cells, the other had no biomicroscopic signs of inflammation. The history of headaches and bilateral visual loss, accompanied by exudative retinal detachment suggests a diagnosis of Harada's disease. Both patients, however, were lightly pigmented whites, and their angiographic

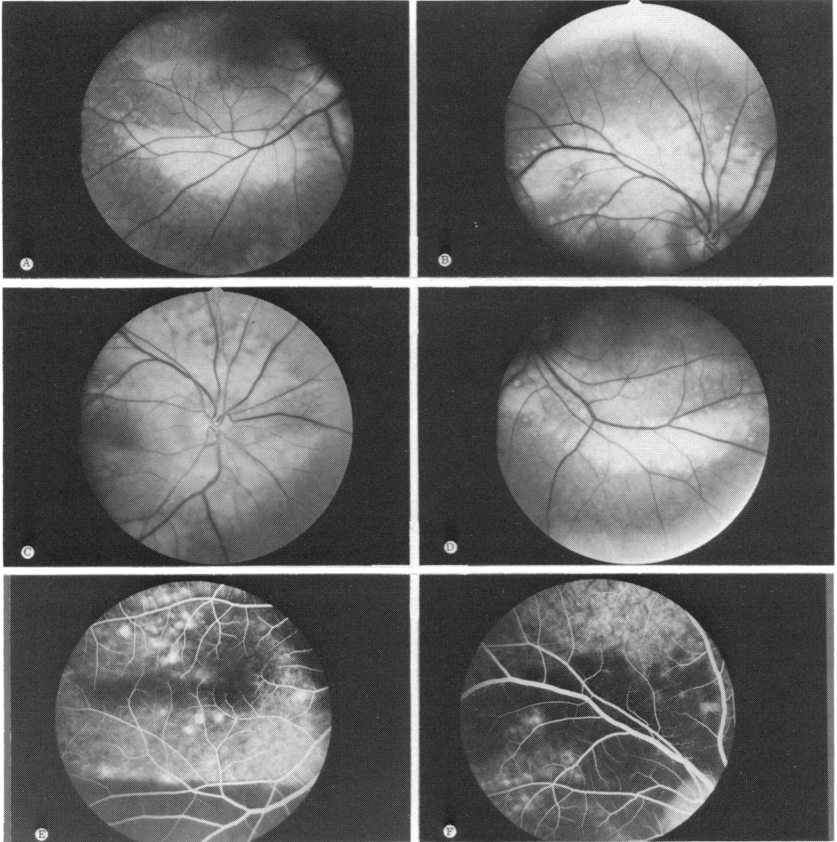


FIGURE 5

Case 2. April 2, 1985. A, B, and C: Right eye. D: Left eye. E and F: Right eye angiogram showing nonfluorescence of vitelliform lesions.

and ophthalmoscopic changes were quite different from that of Harada's disease. The accumulation of yellowish subretinal exudation is not a feature of either Harada's disease or other causes of choroiditis.

The early arteriovenous phase fluorescein angiographic findings of multifocal hyperfluorescence corresponding with the yellow-white lesions suggests that they were focal areas of either acute depigmentation or destruction of the pigment epithelium (RPE) occurring in the absence of obstruction of the underlying choriocapillaris. The appearance of fluorescence was too rapid in these areas to be explained on the basis of serous RPE detachment. Failure of the dye to rapidly diffuse from the choriocapil-

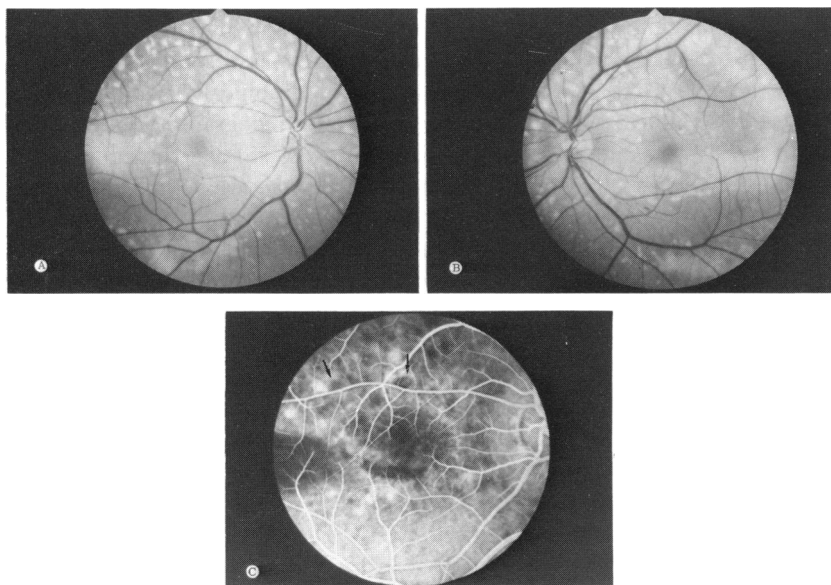


FIGURE 6

Case 2. October 5, 1985. A: Right eye. B: Left eye. C: Right eye angiogram.

laris in these areas into the overlying subretinal exudation suggests focal RPE depigmentation rather than destruction was present. The rapid recovery of vision and resolution of subretinal exudation soon after presentation suggests that the focal areas of RPE destruction may already have been partly repaired by proliferating nonpigmented RPE cells.

What is the explanation for the progressive accumulation of intensely yellow material within the subretinal space as the subretinal exudation resolved and the vision improved? Is it merely the massive accumulation of lipid residue that precipitates as the water component of the exudate is returned to the blood stream? The rapid accumulation of a large amount of this material, its failure to show biomicroscopic evidence of accumulation in the outer retinal layers, its tendency to gravitate to form a meniscus, as well as to accumulate in multiple discrete round or oval clumps often in a ring configuration, are atypical features for the distribution of the yellow lipid-rich exudate that accompanies choroidal neovascularization or focal retinal vascular lesions. Rather, these features are more typical of the vitelliform material accompanying Best's disease. The composition of the vitelliform material in Best's disease is unknown. Lipofuscin has been suggested since vitelliform lesions in Best's disease share some common

clinical and angiographic features of the flecks seen in Stargardt's disease.¹ There is histopathologic evidence that lipofuscin is responsible for the flecks, as well as the dark choroid seen angiographically in Stargardt's disease.^{2-4a} Unlike Stargardt's disease there is no angiographic evidence in Best's disease to suggest a diffuse RPE lipofuscin storage disorder. It is recognized that vitelliform lesions in Best's disease are acquired lesions usually developing in childhood; that they can occasionally be multifocal, that they may be polymorphous^{4b-6}; and that they infrequently may cause rapid onset of visual loss after the development of surrounding subretinal exudation in one or rarely both eyes.^{4b}

Both patients in this report had abnormal EOG findings recorded during the resolving phase of their disorder. Neither had a family history of ocular disease. Unfortunately, neither had family members available for examination. Therefore, we can only speculate as to whether the EOG findings are the result of an inherited anomaly or of acquired damage to the RPE. Fletcher et al⁶ reported a patient with similar multifocal polymorphous vitelliform lesions and an abnormal EOG. They attributed it to Best's disease in spite of absence of a family history of the disorder.

The peculiar fundusoscopic and angiographic changes in the acute phase of this disorder in these two patients is similar to that which occurs in patients who present with bilateral acute visual loss and retinal detachment caused by bilateral benign melanocytic proliferation of the uveal tract associated with an occult metastatic nonocular neoplasm.^{4c} The cause for the acute focal loss of depigmentation of the RPE and the absence of angiographic evidence of occlusion or encroachment on the choriocapillaris in these latter patients is uncertain. It may be the result of a local toxic effect imparted by the uveal melanocytic proliferation that typically spares the choriocapillaris, or of immune-mediated damage to the RPE and retina caused by or associated with the systemic carcinoma. The development of multiple focal pigmented placoid tumors of the choroid in both eyes is the sine qua non of this bizarre syndrome. It is of interest that case 1 had multiple pigmented choroidal nevi when he presented. These lesions, however, did not change during the course of his disease and he failed to develop the other features of this syndrome.

The pathogenesis of the exudative macular detachment and subsequent development of polymorphous vitelliform lesions in the two subjects of this report is unknown. It is probable that the vitelliform material accumulating in the subretinal space was the product of damage to the pigment epithelium rather than the precipitation of lipids derived from blood serum. The presence of abnormal EOG findings during the resolving stages of the disorder is evidence that a widespread abnormality of the pigment epithelium

lium was present. In most instances of an abnormal EOG associated with acquired rather than genetically determined disorders, there is angiographic, as well as ophthalmoscopic evidence of widespread RPE abnormalities extending well beyond the macular region. The pattern of the vitelliform lesions and the abnormal EOG findings in our two patients suggest that they may have been Best's disease carriers, who after some sort of systemic insult manifested the disorder in an acute and peculiar way.

One of us (JDMG) has seen two other patients who had no family history of eye disease, and who when initially seen had polymorphous vitelliform lesions and a course of gradual resolution of these lesions similar to that of the two subjects of this report. Unlike those two patients, however, neither gave a history of acute onset of visual loss and both had normal EOG findings.

Further studies are required to determine whether the syndrome of polymorphous vitelliform lesions occurring after the acute onset of exudative macular detachment is an acquired disease, or an unusual manifestation of a genetically determined disorder, either Best's disease or some other as yet poorly defined RPE dystrophy.

REFERENCES

1. Miller SA: Fluorescence in Best's vitelliform dystrophy, lipofuscin, and fundus flavimaculatus. *Br J Ophthalmol* 1978; 62:256-260.
2. Eagle RC Jr, Lucier AC, Bernardino VD, et al: Retinal pigment epithelial abnormalities in fundus flavimaculatus: A light and electron microscopic study. *Ophthalmology* 1980; 87:1189-1200.
3. Klein BA, Krill AE: Fundus flavimaculatus: Clinical, functional and histopathologic observations. *Am J Ophthalmol* 1967; 64:3-23.
4. Gass JDM: *Stereoscopic Atlas of Macular Diseases: Diagnosis and Treatment*. St Louis, CV Mosby, 1987, a) pp 260, 262; b) pp 242, 243; c) pp 188, 189.
5. Miller SA: Multifocal Best's vitelliform dystrophy. *Arch Ophthalmol* 1977; 95:984-990.
6. Fletcher RC, Jampol LM, Rimm W: An unusual presentation of Best's disease. *Br J Ophthalmol* 1977; 61:719-721.

DISCUSSION

DR ARIAH SCHWARTZ. Doctor Gass has given detailed descriptions of a disease picture in two genetically unrelated patients presenting with some features seen in Best's macular dystrophy. He raises the question whether this acute onset exudative macular detachment with subsequent development of vitelliform lesions is (1) an acquired disease or whether it is (2) an unusual manifestation of a genetically determined disorder, either Best's macular dystrophy or some other poorly defined dystrophy. I will discuss the characteristics presented against the background of Best's macular dystrophy.

Best's vitelliform macular dystrophy inheritance is autosomal dominant and usually manifests early in life in the first or second decade. Vision may be normal for many years with subsequent gradual or rapid decrease, but even in advanced stages the patient frequently maintains reading vision in at least one eye. There is commonly a sequence of ophthalmoscopic changes, although not always in an orderly fashion. Characteristically the first stage presents with a subretinal vitelliform material appearing in one or more lesions at the posterior pole, usually bilateral and with good vision (infrequently a granular macular appearance can precede the vitelliform stage). Rarely the yellow material may disappear completely without residual defects, but the more common course is for the "egg yolk" to break up after some years, usually associated with decrease in vision. Later the yellowish material may settle inferiorly presenting with a fluid level. This is followed months or years later by the development of an atrophic process of the retinal pigment epithelium with further visual decrease. Infrequently there may be late development of subretinal neovascularization with a marked loss of vision in that eye.

The clinical picture of an acute systemic illness onset with severe headaches occurring in young adults, as in Doctor Gass' two cases, is not found in the literature of Best's macular dystrophy. Although some of the earlier descriptions of Best's dystrophy hypothesized inflammatory origin, this was not well documented.

There is another syndrome of adult onset vitelliform macular degeneration, some cases of which appear to be a variant of age-related macular degeneration, and others fit into the diagnosis of pattern macular dystrophy. In either case acute systemic illness is not the mode of onset.

The next diagnostic feature is the reduced electro-oculogram (EOG). The EOG is expressed as a ratio of the mass electrical activity of the retinal pigment epithelium in light as compared with dark, and typically is above 2.0 in normal eyes. It is almost always reduced in Best's macular dystrophy to less than 1.65, reflecting a widespread abnormality of the retinal pigment epithelium. In the absence of other causes, the markedly reduced EOG weighs strongly in favor of Best's vitelliform macular dystrophy. However, a reduced EOG can occur in acquired diseases—retinal detachment, choroidal melanoma without retinal detachment, and fundus diseases with widespread retinal pigment epithelial involvement such as birdshot choroidopathy—as well as in other genetically determined conditions such as fundus flavimaculatus and dominant cystoid macular dystrophy. Doctor Gass' patients showed extensive posterior subretinal fluid and subretinal pigment epithelial lesions. It is quite possible that there was inflammatory retinal pigment epithelial involvement over a much wider area than revealed ophthalmoscopically and angiographically. If so, this inflammatory involvement could reduce the EOG without its having to be specifically related to Best's or some other macular dystrophy. The second possibility is with such a prominent retinal detachment of the entire posterior pole there might have been a more widespread thin subclinical retinal detachment breaking the continuity of the retinal pigment epithelium and photoreceptors and causing the reduced EOG.

The absence of a family history of the disease in Doctor Gass' two patients does

not rule out Best's dystrophy, since family histories are not always reliable, and also sporadic cases can occur. In Best's macular dystrophy it has been found that some family members with normal fundus pictures can have a reduced EOG as the only phenotype expressed. It would be interesting to test the family members of these two patients, even if they do not show evidence of fundus abnormality. If a reduced EOG were found in such family members, it would be supporting evidence for the diagnosis of Best's macular dystrophy.

Next is the question of the vitelliform lesions, raising the question as to whether a vitelliform appearance is specific for Best's. Histopathologic studies suggest the vitelliform material in Best's is lipofuscin. It is generally thought that lipofuscin is produced within the retinal pigment epithelium as a catabolic product of poorly digested retinal photoreceptor outer segments. It can also occur over choroidal nevi and melanomas, blocking fluorescence angiographically in any of these manifestations. The yellowish material observed subretinally in Doctor Gass' cases could be lipofuscin, or it could be the residuals of the subretinal exudate extensively detaching the posterior pole. Yellowish subretinal material has been observed in age-related macular degeneration without family history, in exudates from blood serum products in inflammatory eye disease, in choroid or retinal vascular diseases, and in basal laminar drusen, as well as in adult onset vitelliform macular degeneration. In most of these conditions the yellowish material does not have the characteristic aggregation as in Best's, but clumping as well as solitary discrete foveal and parafoveal yellowish lesions have been observed. Its presence would not have to be pathognomonic for one disease.

A subretinal fluid level is commonly seen in the yellowish lesions in Best's macular dystrophy during its involutonal stages, but it can occur in other biologic situations, eg, within a retinal cyst, in a subhyaloid or subretinal hemorrhage, or even in central serous chorioretinopathy as I observed in one of my patients. Whether lipofuscin or residual exudate, we do not know the physical state of the subretinal yellowish material, ie, whether it is in solution, or a suspension of small insoluble particles within a fluid, or an emulsion of lipid within an aqueous medium. In reviewing the physical chemistry of such fluid states, it is found that in any of these states there could be a separation with settling of the heavier components to result in a fluid level due to any of the following changes: (1) change of pH, (2) addition of an electrolyte as a metabolic byproduct, (3) change in the viscosity of the medium, (4) change in the electrical potential of the suspended particles or droplets, (5) addition of another fluid component, and (6) alteration in the molecular polarity of the components. While a fluid level is characteristic in Best's dystrophy, the biologic mechanisms causing such physical chemical changes do not have to be restricted to any one disease entity.

In Doctor Gass' two patients we have a rare composite disease picture. The vitelliform deposits, the fluid level, and the reduced EOG are much more common in Best's dystrophy, but each of these can be found in other entities. The acute systemic illness onset of the fundus sequence of events would be extremely rare as a feature of Best's macular dystrophy. I would prefer to accept the first of Doctor Gass' choices, namely that these two cases are an interesting and unusual represen-

tation of acute systemic illness with retinal pigment epithelial inflammatory changes and exudative retinal detachment, leaving a residual of subretinal vitelliform lesions and decreased EOG, but without relationship to the genotype of Best's macular dystrophy.

DR SAMUEL D. MCPHERSON, JR. Mr Chairman, I would like to congratulate Doctor Gass on another superb presentation. I just have one question. I may have missed this point in your presentation. One of the characteristics of Harada's disease and the posterior form of sympathetic ophthalmia is lymphocytosis of the spinal fluid, particularly in the stage of prodromal headaches. I wonder if in these patients lumbar punctures were done and if so, what the results were. One further thing, the appearance of the chorioretinal lesions—how do these differ from the similar lesion of Dalen Fuchs in the posterior form sympathetic ophthalmia.

DR J. DONALD M. GASS. First of all, I would like to thank Doctor Schwartz for his excellent discussion and I would like to thank Doctor McPherson, also. In regard to your question, lumbar punctures were not done. The lesions in posterior sympathetic uveitis in my experience which is limited to three cases, show an ophthalmoscopic picture that may simulate acute multifocal posterior placoid pigment epitheliopathy. They are small focal grey-white lesions that are nonfluorescent in the initial phase angiogram but they stain in the later pictures. So they are, in fact, quite different from the lesions in the two patients I presented.