

8. Kruit PJ, van Balen AT, Stilma JS: Cyclosporin A treatment in two cases of corneal peripheral melting syndrome. *Doc Ophthalmol* 1985; 59:33-39

9. Coutu RE, Klein M, Lessel S, et al: Limited form of Wegener's granulomatosis—Eye involvement as a major sign. *JAMA* 1975; 233:868-871

Fatal *Strongyloides stercoralis* Infection in a Patient Receiving Corticosteroids

ANDREW YEE, MD
C. THOMAS BOYLEN, MD
THOMAS NOGUCHI, MD
EDWARD C. KLATT, MD
OM P. SHARMA, MD
Los Angeles

Strongyloides stercoralis can persist as a subclinical infection for years, only to become manifest when host defense mechanisms become impaired.¹⁻⁵ A case of fatal *S stercoralis* infection is presented to underscore the importance of considering *Strongyloides* as a potential infection in an immunocompromised host who has lived in an endemic area.

Report of a Case

The patient, a 78-year-old Cuban man, was referred to the Los Angeles County-University of Southern California Medical Center for the treatment of severe, steroid-dependent, obstructive airways disease. The referring physician also noted that a hoarse voice, difficult deglutition and a sore throat had recently developed. There were no other gastrointestinal complaints on admission. On physical examination he had a respiratory rate of 28 per minute. An indirect laryngoscopy showed normal vocal cords. Diffuse wheezes were heard on examination of the chest.

The leukocyte count was 4,500 per μ l, with 57% segmented neutrophils, 22% band forms, 12% lymphocytes and 8% eosinophils. A sputum Gram's stain showed 3+ polymorphonuclear leukocytes and 3+ Gram-negative rods. A chest x-ray film showed no abnormalities.

Because of progressive respiratory failure, an endotracheal tube was inserted and the patient was placed on mechanically assisted ventilation. Therapy with ampicillin and gentamicin sulfate was started. The patient's airways disease was managed with a regimen of hydrocortisone, aminophylline and metaproterenol sulfate. Despite vigorous therapy, the patient became comatose and hypotensive and died on the third hospital day.

On gross examination at autopsy, the pharynx was clear of lesions, but the trachea showed extensive hyperemia. The gastrointestinal tract from the stomach to the large intestine showed areas of mucosal erosion. Microscopic examination of lung tissue disclosed *Strongyloides stercoralis* organisms in large numbers, with histiocytic infiltrates surrounding the organisms (Figure 1). On microscopic examination of duodenum and jejunum, many *S stercoralis* organisms were seen

in areas of necrosis (Figure 2). The esophagus was normal. The cause of death as determined by autopsy findings was disseminated *Strongyloides stercoralis* infection.

Comment

Strongyloidiasis is endemic throughout the subtropical and the tropical regions of the world. In America, the endemic area is the rural South⁶; our patient had lived in Cuba for most of his life and, presumably, had contracted the infection there. The endogenous cycle, in which filariform larvae can penetrate the gut wall or the perirectal tissue of the host, may persist for as long as 30 years⁶ and may be asymptomatic in 50% of cases.³ Impaired cell-mediated immunity can result in accelerated infection. Hosts at risk include patients receiving immunosuppressive or cytotoxic therapy. Indeed, in animal models, the administration of corticosteroids initially is associated with an absolute increase in worm count and a fractional increase in invasive filariform larvae relative to the noninvasive rhabdoid larvae.⁵ Patients receiving corticosteroid therapy for diseases as varied as the nephrotic syndrome, systemic lupus erythematosus and asthma have had disseminated strongyloidiasis. To date, there have not been cases of hyperinfection with *Strongyloides* reported among patients with the acquired immunodeficiency syndrome, though given the appropriate exposure history, persons in that group would be at risk.¹

Our patient received prednisone at daily doses ranging

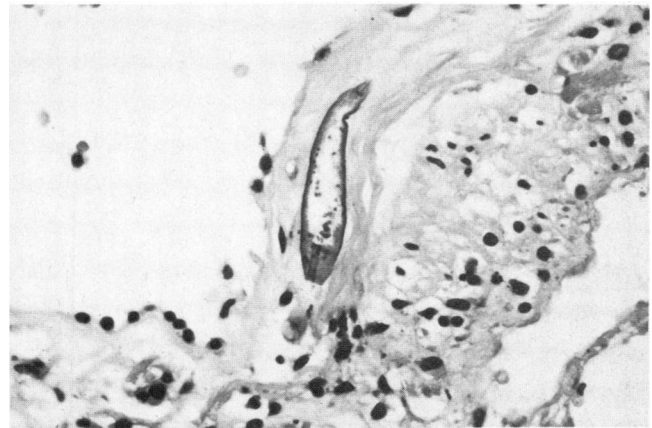


Figure 1.—A photomicrograph of lung tissue shows a filariform larva (reduced from magnification $\times 100$).

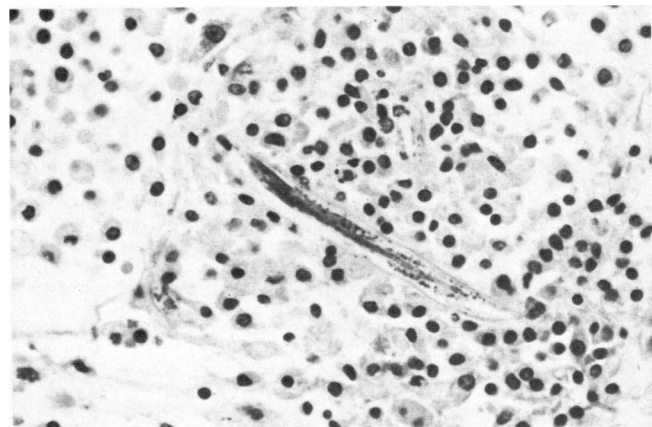

Figure 2.—A photomicrograph of duodenal tissue shows adult *Strongyloides stercoralis* in areas of necrosis (reduced from magnification $\times 100$).

(Yee A, Boylen CT, Noguchi T, et al: Fatal *Strongyloides stercoralis* infection in a patient receiving corticosteroids for obstructive airways disease. *West J Med* 1987 Mar; 146:363-364)

From the Section of Pulmonary Disease, Departments of Medicine and Pathology, Los Angeles County-University of Southern California Medical Center, Los Angeles.

Reprint requests to Andrew Yee, MD, 720 N Vermont St, Los Angeles, CA 90029.

from 20 mg to 40 mg in the six months before admission to our service. The dissemination or accelerated endogenous cycle of the worm is responsible for the clinical findings. There can be the development of abdominal pain, emesis, diarrhea or ileus, the last of which can exacerbate the problem of increasing parasitosis by prolonging gastrointestinal transit time. Filariform larvae can then penetrate across the bowel wall in large numbers, often carrying enteric bacteria "piggy-back" to distant sites.⁵ Respiratory insufficiency may result from accelerated parasitic infestation. Eosinophilia, which may be seen in blood specimens during the indolent phase of infection, is generally not present during the hyperinfective, disseminated phase,² as was the case in our patient, whose absolute eosinophil count on admission was 360 per μ l. Whether this lack of eosinophilia played a permissive role in the development of hyperinfection is not known.

Stool examinations for ova and parasites are often not adequate to achieve a diagnosis,³ as was the case with our patient, who had loose stools develop on the second hospital day. In a case wherein an immunocompromised host who has the appropriate exposure history has gastrointestinal symptoms and wherein initial stool specimens are not diagnostic, duodenal and jejunal fluid examination, for instance by the Enterotest technique, is indicated.⁵ Indeed, it should be emphasized that patients with the appropriate exposure history who have eosinophilia should have several stool specimens sent for ova and parasite studies. Should an initial three stool specimens show no ova or parasites, further diagnostic workup would depend on the clinical picture.

Examining sputum specimens for ova and parasites may also be helpful.² Our patient did complain about a hoarse

voice, sore throat and difficulty swallowing. It is known that the larvae of *S. stercoralis* do migrate into the trachea and the hypopharynx. An examination of sputum for ova and parasites might have been the diagnostic procedure of choice.

Thiabendazole is the medication to use for the treatment of strongyloidiasis. The standard dose is 25 mg per kg of body weight twice a day by mouth for two days. Where hyperinfection or dissemination develops in an immunocompromised host, the treatment is extended to seven days, using the standard dose of thiabendazole. A follow-up upper gastrointestinal tract aspirate is indicated. Immunocompromised hosts at risk for recurrent strongyloidiasis can receive monthly prophylactic treatment.⁵

In summary, hyperinfection or dissemination of *Strongyloides* should be in the differential diagnosis when an immunocompromised host with the appropriate exposure history presents with gastrointestinal and respiratory tract symptoms. Although the signs can be subtle and the diagnosis difficult to establish, treatment is available.

REFERENCES

1. Wilson WR, Cockerill FR III, Rosenow EC III: Pulmonary disease in the immunocompromised host (2nd of 2 parts). *Mayo Clin Proc* 1985; 60:610-631.
2. Cuni LJ, Rosner F, Chawla SK: Fatal strongyloidiasis—In immunosuppressed patients. *NY State J Med* 1977; 77:2109-2113
3. Civantos F, Robinson MJ: Fatal strongyloides following corticosteroid therapy. *Am J Dig Dis* 1969; 14:643-651
4. Leelarasamee A, Nimmannit S, Nakorn SN, et al: Disseminated *Strongyloides*: Report of seven cases. *Southeast Asian J Trop Med Public Health* 1978; 9:539-542
5. Scowden E, Schaffer W, Stone W: Overwhelming strongyloidiasis, an unappreciated opportunistic infection. *Medicine (Baltimore)* 1978; 57:527-544
6. Brown H: *Basic Clinical Parasitology*. New York, Appleton-Century-Crofts, 1975, pp 118-121, 338-339