

result of methicillin interstitial nephritis.<sup>11</sup> Another report suggested that trimethoprim-sulfamethoxazole therapy was the cause of hyperkalemia and metabolic acidosis in a patient with leukemia, although the renal responsiveness to aldosterone was not evaluated.<sup>12</sup>

Our patient presented a unique opportunity for study of the renal tubular defect of interstitial nephritis in which the patient made a spontaneous recovery. His clinical presentation was similar to previous reports of hyperkalemic neuromyopathy of Addison's disease.<sup>4</sup> Like those previously reported, he showed minimal subjective sensory problems with profound quadriplegia. Of interest, his electrocardiogram did not show any of the classic findings of hyperkalemia.

Our patient did not respond to high levels of endogenous aldosterone and was unresponsive to exogenously administered mineralocorticoid as is characteristic of pseudohypoaldosteronism. The patient responded appropriately to a saline and hydrocortisone infusion with rapid improvement in his clinical state and serum potassium level, indicating that the determinants of renal potassium excretion—namely, intratubular sodium concentration and tubular flow rate—were operative. It can only be speculated that the interstitial nephritis was induced by the antibiotic therapy and either caused enough diffuse damage to renal tubules that they were unable to respond to aldosterone, or the aldosterone receptor site or sodium-potassium ATPase activity in the cells was reversibly altered by the inflammatory process. Longitudinal studies of

the patient showed complete resolution of his salt-losing problem.

#### REFERENCES

1. Finch CA, Sawyer CG, Flynn JM: Clinical syndrome of potassium intoxication. *Am J Med* 1946; 1:337-352
2. Armstrong FA: Hyperkalemic familial periodic paralysis. *Ann Intern Med* 1962; 57:455-461
3. Rado JP, Marosi J, Szende L, et al: Hyperkalemic changes during therapy for cirrhosis and ascites with special reference to hyperkalemic intermittent paralysis. *J Am Geriatr Soc* 1968; 16:874-886
4. Bell H, Hayes WL, Vosburgh J: Hyperkalemic paralysis due to adrenal insufficiency. *Arch Intern Med* 1965; 115:418-420
5. Donnell GN, Litman N, Roldan M: Pseudohypoaldosteronism. *Am J Dis Child* 1959; 97:813-828
6. Rabinowitz D, Rosler A, Theodor R, et al: Salt wastage, raised plasma renin activity and normal or high plasma aldosterone: A form of pseudohypoaldosteronism. *Lancet* 1973; 1:959-962
7. Bierich JR, Schmidt U: Tubular Na-K-ATPase deficiency the cause of the congenital renal salt-losing syndrome. *Eur J Pediatr* 1976; 121:81-87
8. Hadler NM, Gill JR, Gardner JD: Impaired renal tubular secretion of potassium, elevated sweat sodium chloride concentration and plasma inhibition of erythrocyte sodium outflux as complications of systemic lupus erythematosus. *Arthritis Rheum* 1972; 15:515-523
9. De Fronzo RA, Cooke C, Goldberg M, et al: Impaired renal tubular potassium secretion in systemic lupus erythematosus. *Ann Intern Med* 1977; 86:268-271
10. Rado JP, Szende L, Szucs L: Hyperkalemia unresponsive to massive doses of aldosterone and renal tubular acidosis in a patient with chronic interstitial nephritis: Clinical and experimental studies. *J Med* 1977; 7:481-510
11. Cogan MC, Arieff AI: Sodium wasting, acidosis and hyperkalemia induced by methicillin interstitial nephritis. *Am J Med* 1978; 64:500-507
12. Kaufman AM, Hellman G, Abramsom RG: Renal salt wasting and metabolic acidosis with trimethoprim-sulfamethoxazole therapy. *Mt Sinai J Med (NY)* 1983; 50:238-239

## Sarcoidosis and Pheochromocytoma

KEVIN M. MURRAY, MD  
RICHARD F. SCHILLACI, MD  
San Diego

THE MOST COMMON presentation of sarcoidosis is as bilateral, symmetric hilar adenopathy noted on chest x-ray films in a patient with minimal, if any, symptoms.<sup>1,2</sup> Pheochromocytoma, on the other hand, has been associated with a dramatic set of symptoms and signs related to catecholamine release by this often-sought but rarely found tumor.<sup>3</sup> We recently cared for a patient who had the classic symptoms of a pheochromocytoma as well as asymptomatic bilateral hilar adenopathy on chest x-ray film and who ultimately proved to have both disorders, an association that has been reported only rarely.<sup>4,5</sup> This case provides the opportunity to discuss the association between sarcoidosis and neoplasia and to examine whether this association might be causal or coincidental.

(Murray KM, Schillaci RF: Sarcoidosis and pheochromocytoma. *West J Med* 1987 Jun; 146:745-747)

From the Department of Internal Medicine (Pulmonary Division) and the Clinical Investigation Department, Naval Hospital, San Diego.

Presented at the 51st annual meeting of the American College of Chest Physicians, New Orleans, Oct 29, 1985. Abstract published in the ACCP Affiliate, vol 1, No. 1, 1986.

The opinions or assertions expressed herein are those of the authors and are not to be construed as official or as reflecting the views of the Navy Department or the naval service at large.

This article is considered, under the Copyright Revision Act of 1976, a "work of the United States government" and accordingly there is no copyright.

Reprint requests to LCDR K. M. Murray, MC, USNR, c/o Clinical Investigation Department, Naval Hospital, San Diego, CA 92134-5000.

### Report of a Case

A 29-year-old black male sailor went to sick bay with symptoms of an upper respiratory tract infection. On examination his blood pressure was 250/180 mm of mercury. His medical history was unremarkable, with no previous hypertension or cardiovascular disease. The family history was positive for mild essential hypertension. The patient was a former smoker. He said he did not use alcohol excessively or take drugs and was taking no medications.

On further questioning, the patient gave a one-year history of recurrent episodes of pounding in his chest, accompanied by a sensation of pulsation throughout his body and a feeling of impending doom. These episodes occurred randomly, approximately four times each month, with no relation to exertion, meals or emotions; they lasted from 10 to 30 minutes and resolved spontaneously. There was no history of headache, cutaneous flushing or other symptoms related to the attacks.

On physical examination the patient appeared well developed, well nourished and in no distress. The pulse rate was 84 beats per minute and the blood pressure was 170/122 mm of mercury. The eye examination, including funduscopic and slit-lamp studies, showed no abnormalities. The lungs were clear. On cardiac examination a grade 2/6 ejection murmur was heard at the lower left sternal border. There were no lifts, heaves or gallop sounds. Pulses were equal in all extremities. The abdomen was unremarkable, with no masses or bruits. There was no peripheral lymphadenopathy. The skin and extremities showed no abnormalities, and results of a neurologic examination were within normal limits.

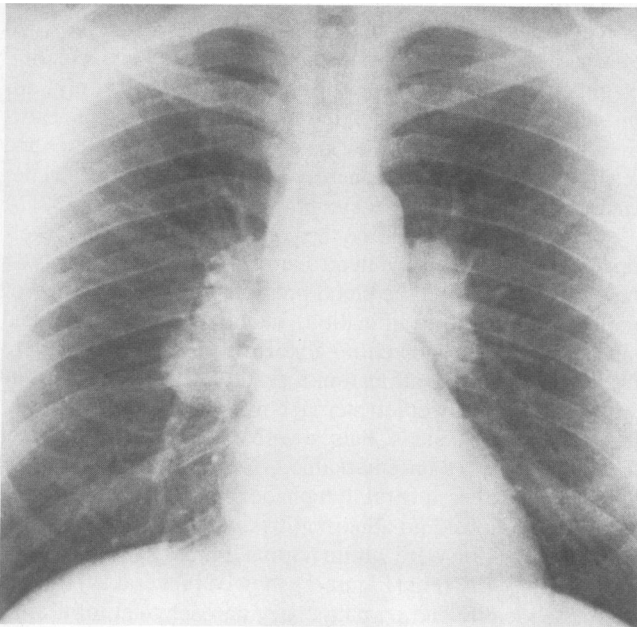
A chest x-ray film (Figure 1) showed bilateral symmetric hilar adenopathy and no pulmonary parenchymal infiltrates. A serum angiotensin-converting enzyme level was 147 units (normal < 125). A urinary vanillylmandelic acid level was

21.6 ng per ml (normal 0.5 to 12), and urinary metanephrine level was 5.9 ng per ml (normal 0.3 to 0.9). A gallium 67 scan (Figure 2) showed increased uptake in the hilar areas. Pulmonary function tests were negative and arterial blood gas levels were normal. Skin tests, including intermediate-strength purified protein derivative (5 tuberculin units), 1:100 coccidioidin and *Candida*, were nonreactive. The electrocardiogram was normal. An abdominal computed tomographic scan (Figure 3) showed a large mass superior to the right kidney.

The patient was treated with a regimen of phenoxybenzamine hydrochloride for control of his hypertension and a laparotomy was done, at which a tumor mass measuring 6.5 by 5.5 by 4.5 cm was found replacing the right adrenal gland. There was no evidence of intra-abdominal or retroperitoneal adenopathy. The tumor histologically was typical of pheochromocytoma. In addition, it had several noncaseating granulomas containing Langhans'-type giant cells (Figure 4). Stains for acid-fast bacilli and fungi were negative.

### Discussion

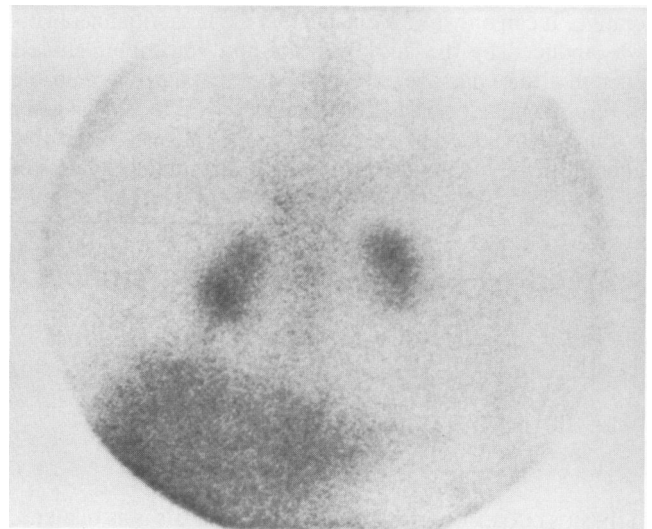
The finding of noncaseating granulomas within the surgical specimen, in the presence of bilateral symmetric hilar adenopathy, a characteristic appearance on a gallium scan and an elevated serum angiotensin-converting enzyme level, establishes the diagnosis of sarcoidosis in our patient. This is the third reported case of coexistent sarcoidosis and pheochromocytoma. Histologic findings in the previously reported cases were identical to those in this case, including the granulomas found within the tumor. Grissom and co-workers reported a giant cystic pheochromocytoma weighing 2,100 grams in an asymptomatic patient.<sup>4</sup> At laparotomy, noncaseating granulomas were present in abdominal lymph nodes and throughout the tumor. This finding, with a chest x-ray film showing unilateral hilar adenopathy and the presence of cutaneous anergy, was felt to establish the diagnosis of systemic sarcoidosis. A gallium scan was not done. Leophonte and associates reported a pheochromocytoma in a patient with a four-year history of thoracic and cutaneous sarcoidosis.<sup>5</sup>



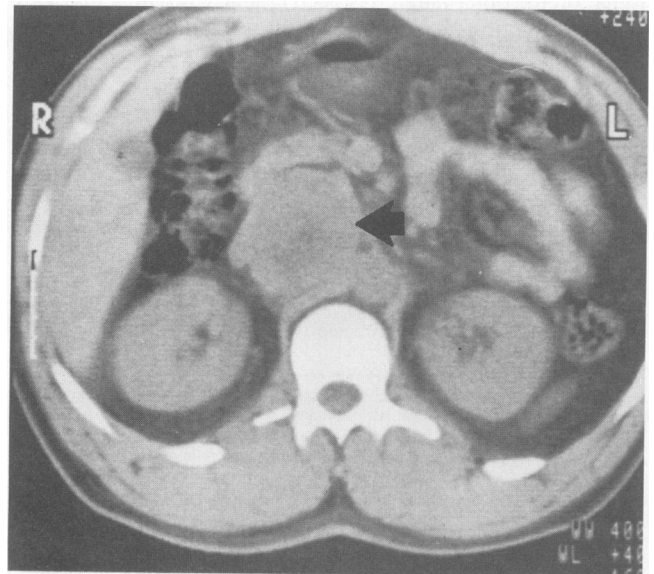
**Figure 1.**—A chest x-ray film shows symmetric bilateral hilar adenopathy.

Again, noncaseating granulomas were found within the tumor. In both previously reported cases of pheochromocytoma and sarcoidosis, it was concluded that the association was purely coincidental.

There have been numerous reports of patients with carcinoma who on histopathologic examination have had noncaseating granulomas in regional lymph nodes draining their tumors.<sup>6,7</sup> These granulomas have been thought to be a normal immunologic reaction to some tumor-related antigen or metabolite, and their presence does not appear to place a patient at higher risk for the development of systemic sarcoidosis. Of greater pertinence to our discussion are the many reports of systemic sarcoidosis in patients with malignancy. Jalan and colleagues reported the case of a patient who had adenocarcinoma of the terminal ileum in an area of "backwash ileitis" due to ulcerative colitis.<sup>8</sup> Lymph nodes in the ileocecal area, the mesentery and the mediastinum were positive for noncaseating granulomas. This suggests that patients with generalized sarcoidosis may have an increased tendency for localized granulomatous reactions to develop in response to neoplastic



**Figure 2.**—A gallium 67 scan shows increased uptake of <sup>67</sup>Ga in both hila.



**Figure 3.**—An abdominal computed tomographic scan shows a large right adrenal mass (arrow).



**Figure 4.**—A pathologic specimen shows noncaseating granulomas within a pheochromocytoma (original magnification  $\times 400$ ).

tissue. An alternative explanation, one that would also account for the findings in our patient, is that some product of the neoplastic tissue first incites the local granulomatous response and then the systemic sarcoidosis.

The possibility that sarcoidosis predisposes to malignancy must also be considered. It is known that cell-mediated immunity in sarcoidosis is abnormal.<sup>9</sup> An absolute lymphopenia, as well as an alteration in the T-cell helper-suppressor ratio and an impaired in vivo responsiveness of T cells to mitogens, is often found. It has been suggested that most of these changes are the result of intense granulomatous inflammation occurring throughout the body, with sequestration of helper T cells in involved tissues, leading to peripheral lymphopenia and altered in vivo responsiveness. These changes are probably responsible for the common clinical finding of cutaneous anergy but are otherwise of questionable significance. Patients with sarcoidosis, for example, are not plagued by opportunistic infections, and all immunologic abnormalities seem to resolve when the disease remits. Nonetheless, it is possible that patients with sarcoidosis have some subtle defect in cell-mediated tumor surveillance, which could lead to an increased incidence of neoplasia.

Brincker and Wilbek reviewed 2,544 cases of sarcoidosis and found 48 cases of cancer, significantly more than expected.<sup>10</sup> The excess was accounted for, however, by an increased number of lymphomas and bronchogenic carcinomas, both of which are well known to mimic sarcoidosis clinically. Tissue correlation was obtained in only five patients, and it is not clear that these patients had systemic sarcoidosis rather than mere local granulomatous inflammation. In another study, Brincker reviewed 1,500 cases of lymphoma and found 19

with noncaseating granulomas.<sup>11</sup> Five of these patients were believed to have systemic sarcoidosis, giving a prevalence of 1 in 300, clearly higher than expected. Three cases of sarcoidosis preceded the onset of lymphoma by 8 to 14 years and two followed by 5 and 17 years; it is difficult to ascribe causality to either disease. The author hypothesized that both lymphoma and sarcoidosis reflected an underlying immunologic abnormality. Other reports of sarcoidosis preceding the discovery of malignancy are rare, and the possibility of a sarcoidosis-related tumor diathesis remains conjectural.

Because there are so few data to support a causal relationship between sarcoidosis and pheochromocytoma, we examined the probability that this association was based on chance alone. The annual incidence of sarcoidosis is 11 to 19 cases per 100,000 population, and it is much more common in blacks, with an incidence in one study of 47.6 cases per 100,000 persons.<sup>1</sup> With a population of 200 million in the United States, we would expect 22,000 cases of sarcoidosis annually. It has been estimated that at least 10% of the adult population has hypertension, which would mean that 2,200 patients annually have both sarcoidosis and hypertension. If the incidence of pheochromocytoma is the same in these patients as in the general hypertensive population,<sup>3</sup> we would expect to find 0.1%, or two cases each year, of pheochromocytoma and sarcoidosis, even if no pathophysiologic association existed! While it is possible that sarcoidosis predisposes to malignancy or that uncharacterized products of neoplastic tissue lead to local granulomatous reactions and systemic sarcoidosis, the independent incidences of pheochromocytoma and sarcoidosis are such that this particular association is most likely coincidental.

#### REFERENCES

1. Mitchell DN, Scadding JG: Sarcoidosis. *Am Rev Respir Dis* 1974; 110:774-802
2. Katz S: Clinical presentation and natural history of sarcoidosis. In Fanburg B (Ed): *Sarcoidosis and Other Granulomatous Diseases of the Lung*. New York, Marcel Dekker, 1983, pp 203-224
3. Manger WM, Gifford RW: *Pheochromocytoma*. New York, Springer-Verlag, 1977
4. Grissom JR, Yamase HT, Prosser PR: Giant pheochromocytoma with sarcoidosis. *South Med J* 1979; 72:1605-1607
5. Leophonte P, Dutau G, Bouissou H, et al: Sarcoidose et phéochromocytome surrénalien. *Poumon Coeur* 1972; 28:333-337
6. Gorton G, Linnell G: Malignant tumors and sarcoid reactions in regional lymph nodes. *Acta Radiol* 1957; 47:381-392
7. Symmers WC: Localized tuberculoid granulomas associated with carcinoma. *Am J Pathol* 1951; 27:493-573
8. Jalan KN, MacLean N, Ross JM, et al: Carcinoma of the terminal ileum and sarcoidosis in a case of ulcerative colitis. *Gastroenterology* 1969; 56:583-588
9. Daniele RP, Dauber JH, Rossman MD: Immunologic abnormalities in sarcoidosis. *Ann Intern Med* 1980; 92:406-416
10. Brincker H, Wilbek E: The incidence of malignant tumors in patients with respiratory sarcoidosis. *Br J Cancer* 1974; 29:247-251
11. Brincker H: Sarcoid reactions and sarcoidosis in Hodgkin's disease and other malignant lymphomata. *Br J Cancer* 1972; 26:120-123