

UVEITIS IN CHILDREN: ANALYSIS OF 274 CASES*

BY *Samuel J. Kimura*, M.D., AND *Michael J. Hogan*, M.D.

IN A PREVIOUS REPORT¹ we described the findings in 47 cases of uveitis occurring in patients 16 years of age or younger out of 900 cases of uveitis surveyed in 1946-54. This preliminary report indicated that anterior uveitis in children is rare, and that chorioretinitis is relatively more common in this age group than anterior uveitis. Since 1954 we have studied 274 additional cases of uveitis and uveitis-like entities which occurred in patients 16 years of age or younger. Some of our previous concepts were confirmed, and others were not.

The present study was made to provide information on the cause, course, and prognosis of an additional group of cases. Such a series of well-followed cases helps establish the natural course of the various childhood uveitis entities and provides information on the etiology and therapy.

MATERIALS AND METHODS

Both uveitis clinic and private patients were studied. Many were referred because of the special problem a given case presented. For this reason the study is not entirely a random sample of uveitis cases which occur in children, but represents the types of lesions seen in a special clinic during a period of ten years. The volume of material and follow-up correct the deficiency. A small series of uveitis cases with an onset during childhood, but first observed during adult life also is included. It is considered apart from the cases seen during childhood. Only cases in which the age of onset was certain are included.

Toxoplasmic retinochoroiditis cases continue to be referred to this clinic because of our special interest. Therefore, the incidence of this

*From the Francis I. Proctor Foundation for Research in Ophthalmology and the Department of Ophthalmology, University of California School of Medicine, San Francisco Medical Center. This work was supported in part by U.S. Public Health Service Research Grant No. NB-01099.

form of uveitis in this series probably is higher than would be expected in other clinics and in routine practice.

Most patients were studied as outpatients, but many were hospitalized. Each patient was examined by at least two observers and the results compared.

All of the records contained the following data: (1) medical history and detailed ophthalmic history; (2) arthritis evaluation; (3) detailed examination of the eyes, including slit-lamp biomicroscopy and ophthalmoscopy with the pupils dilated (infants and young children were examined under general anesthesia); (4) special laboratory examinations in which specific tests were done as indicated by the findings; (5) the methylene blue dye test for toxoplasmosis. The latter was done routinely, but was missed in a few cases for various reasons.

ANALYSIS OF CASES

Two hundred and two patients aged 16 years or younger, out of a series of 1,900 uveitis cases, were studied during the past ten years.

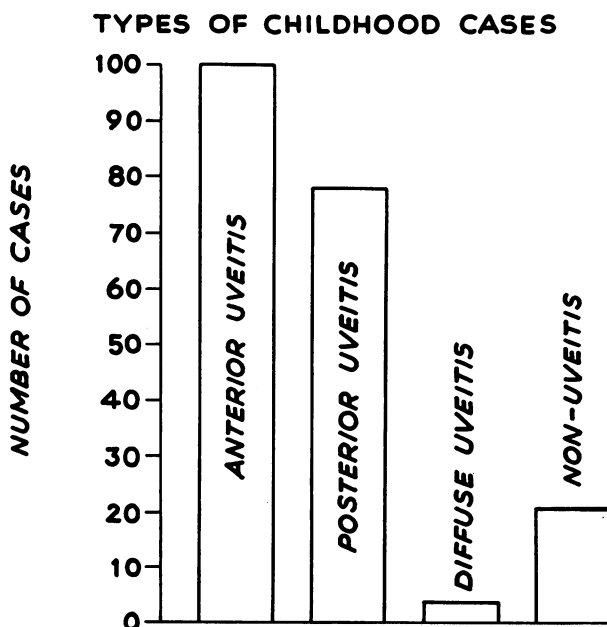


FIGURE 1

SEX DISTRIBUTION OF UVEITIS IN CHILDREN

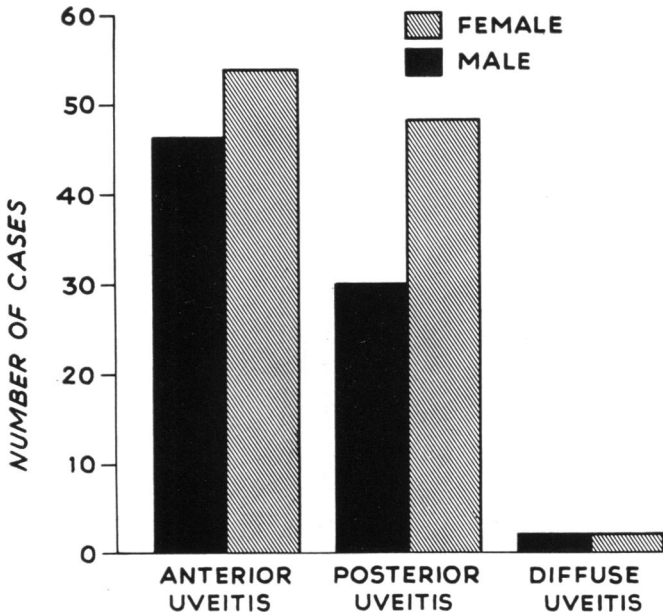


FIGURE 2

Seventy-two additional cases of uveitis in patients over age 16 were studied. In this group the onset of the uveitis was before this age.

The ocular lesions in 202 patients were classified as anterior, posterior, and diffuse uveitis. A by-product of the survey included some non-uveitis entities referred as uveitis, which often were equally interesting. Among this group were conditions which resembled uveitis, but were degenerative or resulted from a congenital defect. Figure 1 shows the number of cases seen in the four categories. Figure 2 shows the sex distribution of the patients. Fifty-four anterior uveitis cases were females and 46 were males. Posterior uveitis was more prevalent in females, 48 patients being females and 30 males. Diffuse uveitis (4 cases) showed an equal distribution among males and females. Among the non-uveitis cases were 5 females and 15 males.

ANTERIOR UVEITIS (100 CASES)

The age of onset of anterior uveitis is shown in Figure 3. This condition obviously is more common in older children. The age of onset usually could be determined by a careful history, but we were

AGE OF ONSET OF CHILDHOOD ANTERIOR UVEITIS

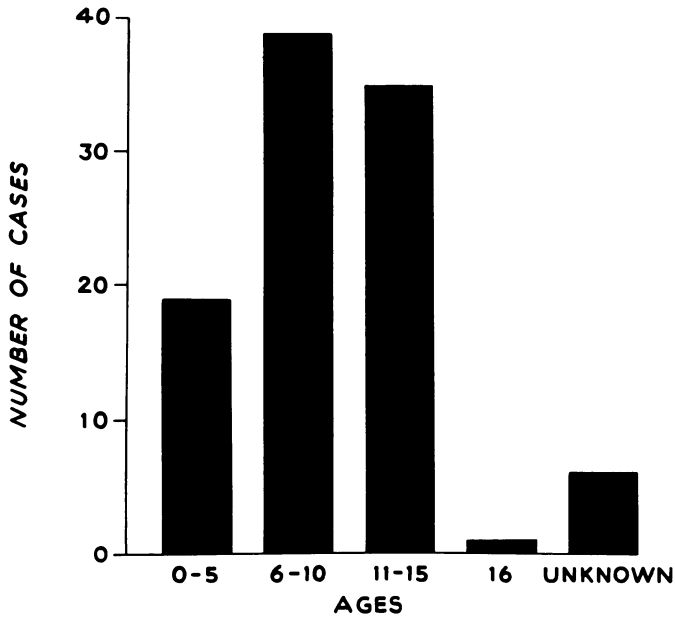


FIGURE 3

unable to determine the age of onset in six patients. It was possible on a clinical basis to place 70 of these 100 cases into a specific uveitis category (Table 1).

The iridocyclitis was acute in 11 and chronic in 35. Only 3 patients had a recurrent type of disease. The inflammation was bilateral in 35 cases, affected the right eye in 8, and the left in 3.

TABLE 1. TYPES OF ANTERIOR UVEITIS IN CHILDREN
(100 CASES)

Iridocyclitis		46 cases
Possible Still's syndrome	8	
Juvenile rheumatoid arthritis	3	
Ankylosing spondylitis	1	
Behcet's syndrome	1	
Sarcoid	2	
Trauma	1	
Unknown	30	
Chronic cyclitis		41 cases
Fuchs' syndrome of heterochromic cyclitis		7 cases
Kerato-uveitis		6 cases
Herpes simplex	5	
Tuberculosis	1	

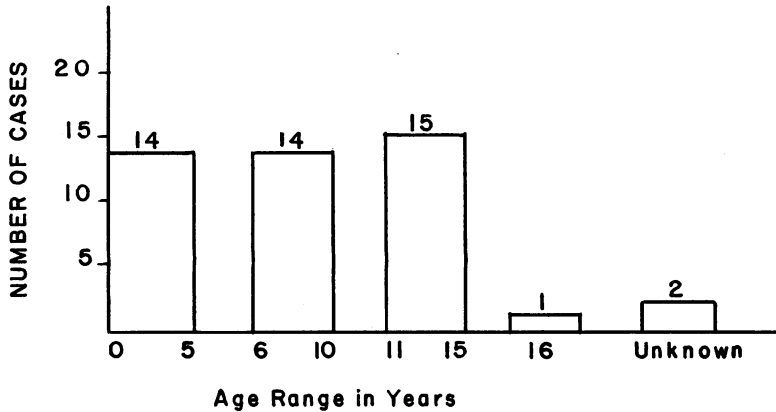


FIGURE 4. AGE OF ONSET OF IRIDOCYCLITIS IN CHILDREN.

Thirteen of the 46 cases were thought to be associated with joint disease. A complete picture of Still's disease was not present in the majority of the cases, and for this reason a presumptive diagnosis was made. Clinically, however, all patients had a very low-grade bilateral iridocyclitis, usually unsuspected until vision was found to be decreased. In some the color of one eye was found to have changed and examination showed a band keratopathy. Three cases diagnosed as associated with juvenile rheumatoid arthritis and one with ankylosing spondylitis showed radiological changes as well as clinical manifestations. The case of Behcet's syndrome had no mucous membrane lesions but did have two attacks of hypopyon iridocyclitis. Viral and bacterial studies of the aqueous humor were negative. The two cases diagnosed as being of sarcoid origin were examples of bilateral granulomatous iridocyclitis in two Negro girls, aged 12 and 13. One had iris nodules with mutton-fat keratic precipitates, but no obvious skin lesions.

We were unable to determine the etiology or establish a general disease association in 30 cases. Eight showed large greasy keratic precipitates and were thought to be granulomatous. One of these eight was thought to be of sarcoid origin, but other signs of this disease were lacking.

TABLE 2. FOLLOW-UP RESULTS OF 18 CASES

Worse	8 cases
Unchanged	3 cases
Improved	7 cases

The age of onset was equally distributed in various groups, as is shown in Figure 4.

Eighteen of these 46 known cases of iridocyclitis have been followed from one to eight years (Table 2). The group judged to be worse had lost vision from such complications as glaucoma, optic atrophy, cataract, keratopathy, and cystic degeneration of the macula. Two patients with chronic iridocyclitis developed bilateral glaucoma and became blind in both eyes in spite of all care.

Chronic cyclitis (41 cases) constituted the single largest group of patients. Roughly 41 per cent of all the patients with anterior uveitis had chronic cyclitis. Figure 5 shows that the majority of the cases

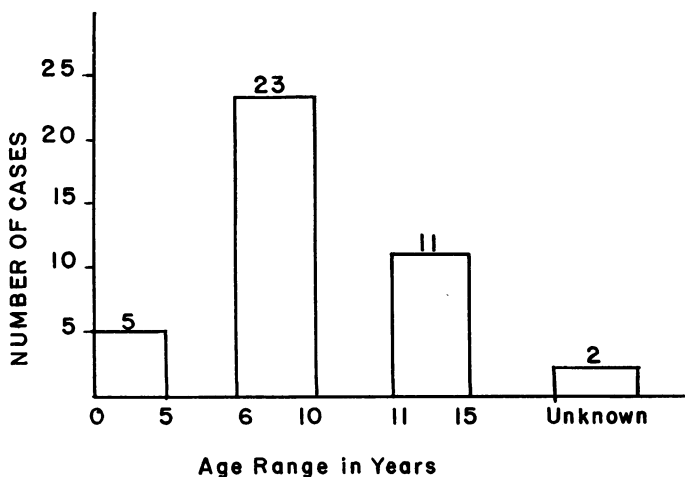


FIGURE 5. AGE OF ONSET OF CHRONIC CYCLITIS IN CHILDREN.

occurred between ages 6 and 10. Twenty-six cases were in males and 15 cases in females. Thirty-one cases were bilateral and 10 were unilateral. In unilateral cases both eyes were affected equally.

The same criteria set forth in a previous paper² were used to classify the severity of the chronic cyclitis. There were 8 mild, 22 moderate, and 11 severe cases (Figure 6).

Twenty-three of the 41 cases have been followed from one to eight and a half years. Six severe cases followed for three to four years all have had further visual loss. One boy has developed complete blindness. The 16 mild or moderately severe cases followed one to eight and a half years have all remained about the same (8 cases) or have shown slight improvement (8 cases). One moderately severe case followed for four years showed slight advancement of the disease.

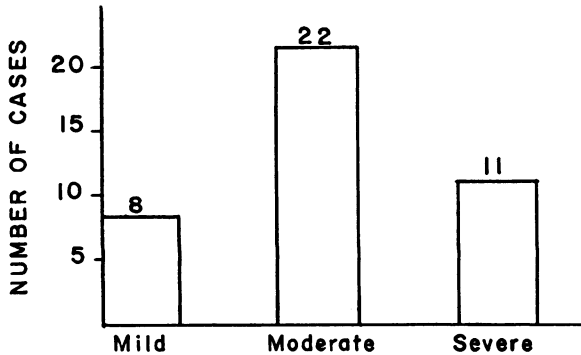


FIGURE 6. SEVERITY OF DISEASE IN 41 CASES OF CHRONIC CYCLITIS.

Five of the cases were unilateral when first seen and remained unilateral during the one to five years they have been followed. The median follow-up was three years.

Fuchs' syndrome of heterochromic cyclitis (7 cases) was present in five males and two females. They were all seen between the ages of 12 to 15 years of age. The age of onset was almost impossible to determine accurately. Four of the 7 cases have been followed from one and one-half to seven years during which time all were active, but only one eye developed a cataract in the affected eye.

Five of the 6 kerato-uveitis cases were examples of *herpes simplex virus iritis*. The diagnosis in all cases was made on clinical grounds based on the findings and an interval history between attacks of keratitis. Tuberculous kerato-uveitis was diagnosed in one case on the ocular findings and the evidence of pulmonary tuberculosis as diagnosed by a pediatrician. The kerato-uveitis healed completely on antituberculous therapy and has remained well for three years.

POSTERIOR UVEITIS (78 CASES)

A presumptive diagnosis of toxoplasmosis was made in 60 of the 78 cases of posterior uveitis. Eighteen cases were of unknown etiology. Table 3 classifies the cases studied in 30 male and 48 female children.

TABLE 3. POSTERIOR UVEITIS

Toxoplasmic	60 cases
Chorioretinitis, unknown etiology	18 cases
Juxtapapillary chorioretinitis	2 cases
Disseminated chorioretinitis	2 cases

The presumptive diagnosis of toxoplasmic chorioretinitis was based on the clinical picture, the course of the disease, and the results of the methylene blue dye test. The age of onset was difficult to determine, but it was apparent that many of the cases were of congenital origin. Visual difficulties usually were detected for the first time during routine preschool and school eye examination. Only two cases were noted to have had a congenital strabismus. Sixty per cent (36 cases) of these *Toxoplasma* cases had recurrent disease which came to the attention of the ophthalmologist because of sudden change in vision. The remaining 24 cases had healed lesions which caused reduced vision.

More females (32 cases) than males (28 cases) had this form of retinitis. The disease was bilateral in 58 per cent of the toxoplasma cases (35 cases), and the macula was involved in 97 per cent (58 cases). Seventeen showed bilateral macular involvement.

TABLE 4. METHYLENE BLUE DYE TEST TITERS
IN 60 CASES OF TOXOPLASMIC CHORIORETINITIS

Negative	8 cases
Positive: undiluted	1 case
1:16	8 cases
1:64	20 cases
1:256	9 cases
1:1024	3 cases
1:2048	1 case
1:2049	3 cases
1:8192	2 cases
Unrecorded or not done	5 cases

Table 4 shows the dye test titers that were obtained from the blood of these 60 cases of toxoplasmic chorioretinitis. A presumptive diagnosis was made in 8 cases which had a negative dye test and in 5 cases in which the dye test was not done.

Table 5 shows the course of the chorioretinitis in 26 cases followed from one to eight years. Recurrences were noted in 7. The recurrence in 5 of the 7 led to further reduction of vision.

TABLE 5. FOLLOW-UP STUDIES ON 26 CASES OF TOXOPLASMIC UVEITIS

<i>Years followed</i>	<i>No. of cases</i>	<i>Recurrences</i>	<i>Healed</i>	<i>Worse</i>
1	6	1	5	1
2	3	2	2	1
3	3		3	
5	3	2	2	1
6	4	1	3	1
7	1		1	
8	5	1	4	1
9	1		1	

CHORIORETINITIS OF UNKNOWN ETIOLOGY (18 CASES). A presumptive diagnosis could not be made in 23 per cent of the posterior uveitis cases. Two patients with juxtapapillary chorioretinitis and 2 with disseminated chorioretinitis were believed to be of tuberculous origin.

DIFFUSE UVEITIS

There were 4 cases of diffuse uveitis (Table 6). The one case of Vogt-Koyanagi-Harada's syndrome occurred in a 15-year-old Negro girl, whose disease commenced with bilateral acute iridocyclitis and spread to involve the posterior eyes within three weeks. At this time she was referred for an opinion. The classic eye findings were observed.

TABLE 6. DIFFUSE UVEITIS (4 CASES)

Vogt-Koyanagi-Harada's syndrome	Female, age 15 yr.
Sarcoidosis	Female, age 12 yr.
Sympathetic ophthalmia	Male, age 15 yr.
Sympathetic ophthalmia	Male, age 3½ yr.

The spinal fluid showed 30 lymphocytes per cubic millimeter. Four months later she developed alopecia, but there were no skin changes.

Sarcoidosis was observed in a 12-year-old Negro girl. The initial lesions were cutaneous, followed by a bilateral granulomatous uveitis. Chest X-ray showed hilar adenopathy, compatible with a radiological diagnosis of sarcoidosis, and the skin biopsy was positive. The corneas showed mutton-fat keratic precipitates. Ophthalmoscopic examination showed numerous vitreous cells and the retina had "candle wax dripping" exudates along the vessels.

The two cases of sympathetic ophthalmia occurred in white males following injury. In one the eye was enucleated one month after the injury. Two weeks later the uninjured eye developed an anterior uveitis. Microscopic study of the enucleated eye revealed the typical changes of sympathetic ophthalmia. Both cases have had a long course, kept under control only by corticosteroid therapy.

NON-UVEITIS ENTITIES

Twenty-three children with non-uveitis disease entities were referred for study as probable types of uveitis. All presented some clinical signs common to those seen in uveitis. The findings in 3 cases emphasized the differential diagnosis of anterior uveitis (Table 7).

The eyes in all three cases showed cells and flare in the aqueous humor or cells in the anterior vitreous. The diagnosis became evident in each case after follow-up studies revealed the nature of the disease.

TABLE 7. DIFFERENTIAL DIAGNOSIS OF ANTERIOR UVEITIS (3 CASES)

Case #1258	Male, onset 11 yr. age	Retinitis pigmentosa
Case #2190	Male, onset 12 yr. age	Glaucomatocyclitis crisis
Case #2584	Female, onset 12 yr. age	Episcleritis

TABLE 8. DIFFERENTIAL DIAGNOSIS OF POSTERIOR UVEITIS (18 CASES)

Macular degeneration	5 cases
Traumatic macular degeneration	2 cases
Endophthalmitis	2 cases
Retinal degeneration (?)	1 case
Optic atrophy	1 case
Macular cyst	1 case
Central serous retinopathy	1 case
Macular edema	1 case
Retinal detachment	1 case
Retinal vasculitis	1 case
Retinal pigment layer atrophy	1 case
Coats' disease	1 case

The retinitis pigmentosa case initially was thought to be an example of chronic cyclitis.

Eighteen other non-uveitis cases involved the posterior segment (Table 8). Two cases of retinochoroiditis with endophthalmitis were studied. Vitreous aspiration revealed numerous eosinophiles. A nematodiasis was considered as the most likely diagnosis since the patients had an associated blood eosinophilia. Both patients were males, aged 4 years.

RECURRENT AND CHRONIC CHILDHOOD UVEITIS

In addition to the 202 children 16 years of age or under, there were 72 patients beyond 16 years in whom the age of onset was before age sixteen. Twenty-three had anterior uveitis, 45 had posterior uveitis, one had a diffuse uveitis, and 3 had a non-uveitis disease. The one case of diffuse uveitis had sympathetic ophthalmia.

The types of anterior uveitis observed are given in Table 9. The

TABLE 9. RECURRENT OR CHRONIC ANTERIOR CHILDHOOD UVEITIS (23 CASES)

	<i>Cases</i>
Iridocyclitis of unknown cause	13
Iridocyclitis associated with rheumatoid arthritis	3
Iridocyclitis associated with spondylitis	1
Chronic cyclitis	3
Kerato uveitis (luetica ?)	1
Fuchs' syndrome of heterochromic cyclitis	2

iridocyclitis was chronic in 8 of 13 cases in Table 9. Four of the 8 were associated with rheumatoid arthritis or spondylitis. The duration of the uveitis in the 8 cases ranged from 4 to 29 years, the median being 12 years. Six showed severe disease with a marked reduction in vision. The 3 cases of chronic cyclitis all dated the onset of their disease to age 15. The duration was roughly 4 to 10 years, and floaters in the field of vision and varying visual loss constituted the principal symptoms. All 3 patients had a relatively mild form of this disease. Both cases of Fuchs' syndrome of heterochromic cyclitis had cataracts, and one had glaucoma. The one case of kerato-uveitis was thought to be of syphilitic origin.

TABLE 10. CHILDHOOD POSTERIOR UVEITIS
(46 CASES)

Toxoplasmosis	39 cases
Etiology unknown	6 cases
Sympathetic ophthalmia	1 case

The types of posterior uveitis in this series are tabulated in Table 10. The 39 cases with probable recurrent toxoplasmic chorioretinitis comprise a small portion of such cases in our total series. These 39 cases are reported simply because they related their disease to a specific period of childhood. Many were undoubtedly examples of congenital toxoplasmosis with a childhood recurrence, followed by later exacerbations in adult life. Only 5 of the total 46 cases were healed when they were first seen by us. Six cases of recurrent chorioretinitis had a negative methylene blue dye test titer of 1:16 or higher and were thought not to be toxoplasmic, but sera were not tested at less than 1:16.

The one case of diffuse uveitis was an example of sympathetic ophthalmia in a 22-year-old female, which started at the age of 8, following a penetrating injury. The uveitis continues to run a protracted chronic course in spite of treatment with corticosteroids. Vision is markedly reduced owing to macular changes and vitreous opacities.

COMMENTS

This series of childhood uveitis patients indicates that anterior is more prevalent than posterior uveitis. It is possible that the anterior uveitis cases are more often discovered than those in the posterior eye, but we feel there is a preponderance of anterior disease in children. We are aware, however, that this series is highly selective, and any statistical analysis would not be valid.

The age of onset could be determined by history in most instances, but probably more accurately in anterior uveitis than posterior uveitis. Anterior uveitis seemed to occur more frequently after five years of age, whereas posterior uveitis, often being congenital, was discovered earlier, most often at preschool vision screening. Only three cases of strabismus due to a macular lesion were noted in this series.

Anterior uveitis in children is not unlike that seen in adult eyes. This type of uveitis could be categorized in a clinical syndrome in 70 per cent of cases. Only thirty of the 100 anterior uveitis cases could not be classified as part of a clinical syndrome. Of these 30 cases, 8 could be further subclassified as a granulomatous anterior uveitis.

Thirty-five of the 46 cases of iridocyclitis were bilateral. As in adults, a certain percentage of anterior uveitis cases are found in patients with joint disease. Eight of the 12 cases were designated as examples of possible Still's syndrome. All had a very low-grade iridocyclitis and band keratopathy, which often was the first sign of the presence of a chronic iridocyclitis. These patients were small for their stated age and exhibited general adenopathy and leukocytosis. Most did not have splenomegaly or other signs that are associated with this syndrome. Still's syndrome is a rare condition in this country and perhaps the 8 cases so diagnosed would not fulfill all the criteria for this disease.

Laurin and Favreau³ recently emphasized the difference between juvenile rheumatoid arthritis and Still's disease pointing out that the latter disease is usually associated with visceral lesions and has an unfavorable prognosis. This distinction is usually not made in the literature and the terms are used synonymously. In the literature the 5.5 to 21 per cent incidence of uveitis probably applies, therefore, to all juvenile rheumatoid arthritides.⁴⁻⁶ The four cases having juvenile rheumatoid arthritis and ankylosing spondylitis had clear-cut clinical findings.

The 18 cases that have been followed provide evidence that iridocyclitis is a serious disease in children, usually running a chronic and relentless course. Serious complications include glaucoma, optic atrophy, cataracts, and band keratopathy. Two of the cases with chronic iridocyclitis developed bilateral glaucoma and progressed to complete blindness.

The large number of chronic cyclitis cases in this series is interesting, and perhaps of some significance, since no effort was made by us to see additional cases. Probably it only emphasizes the point made by us and others that this condition occurs in young people and often is low

grade, causing no inflammation of the eyes to attract the attention of parents or physicians.

The seven cases of Fuchs's syndrome of heterochromic cyclitis all occurred in older children (12-15 years of age). This disease is more prevalent in young adults. Four of these seven cases and a group of older patients have been followed for twelve years. In spite of therapy the disease runs a mild, chronic course, eventually leading to cataract in almost 100 per cent and glaucoma in 20 to 25 per cent of cases. All seven cases had not been recognized as having Fuchs's syndrome of heterochromic cyclitis and were referred to the uveitis clinic, often with few or no symptoms.

Kerato-uveitis cases are interesting and usually an etiologic diagnosis can be made. Herpes simplex is an important cause and prevention is still the best therapy. The infectious nature of this serious eye disease should be emphasized, because infants and young children are infected easily from "canker sore-like" mouth lesions and facial cold sores in the mother. The one case of tuberculous kerato-uveitis had an active pulmonary tuberculosis and, under antituberculous therapy, the keratitis and the nodular iritis cleared and has remained so for over three years.

Posterior uveitis seemed to be more prevalent than the anterior type in our initial series (1954).¹ At that time we had a special interest in toxoplasmosis and many cases of this type were referred for study. The present series combines fewer cases of posterior than anterior uveitis. Of the 78 cases of posterior uveitis a presumptive diagnosis of toxoplasmic chorioretinitis was made in 60 cases. The remaining 18 cases could not be given an etiologic diagnosis, except for two cases of posterior uveitis. These were thought to be examples of nematodiasis on the basis of both the clinical findings and the eosinophiles found in the vitreous aspirated for cytological study.

Sixty per cent (36 cases) of the toxoplasmosis cases had recurrent, active disease.

The methylene blue dye test was negative in 9 of the 60 cases at a titer of 1:16 or greater. It is necessary to test these sera at undiluted as well as at higher dilutions, for recent study showed eye sections positive for cysts even when the dye test was negative at 1:16. One-third of the cases showed a positive titer at 1:64 dilution and roughly one-half of the cases showed 1:64 to 1:256 dilution of sera to be positive.

Twenty-six of the toxoplasmosis cases were followed from one to

eight years. Seven have had a recurrence of the posterior segment disease and invariably with further visual damage. One such eye came to enucleation, but the culture of the eye was negative for toxoplasma organisms.

Diffuse uveitis is a more serious problem but fortunately it is not too common in children. The Vogt-Koyanagi-Harada syndrome is rare in children, but often is very serious and very difficult to manage. The one sarcoidosis case occurred in a Negro girl and caused a severe protracted reduction in vision in spite of treatment.

The two cases of sympathetic ophthalmia emphasize the potential dangers of any ocular wound in a child. In spite of corticosteroid therapy the disease became chronic with serious complications.

The non-uveitis entities referred to the survey clinic were a very interesting and important group of patients. It is very often difficult to differentiate degenerative diseases and vascular lesions from endogenous uveitis.

All of the types of uveitis seen in adults are seen in children. In addition, children with juvenile rheumatoid arthritis and Still's disease develop a low-grade chronic iridocyclitis which is resistant to therapy. Uveitis is a more serious disease in children, simply because of its earlier onset in life. The recurrences over a period of years eventually result in serious loss of vision. Giles⁷ reported the findings in 16 cases of anterior uveitis. He concluded that the anterior uveitis often is chronic and is followed by serious sequelae, such as cataract and glaucoma.

The success of treatment of uveitis in adults and children has improved tremendously in the past 15 years. Giles⁷ stressed the use of steroids, which are of great value, provided they are used judiciously in the proper case. Oral or systemic steroid medications should be used in effective amounts for a short period of time in acute cases. They should be used more carefully in patients with chronic uveitis. The long-term daily use of oral corticosteroids in effective amounts usually is associated with undesirable side effects. Recently we have used an intermittent corticosteroid regimen^{8,9} in acute uveitis. We have found it to be quite effective and a preferred method, since most patients do not become cushinoid even with large doses.

The local steroid therapy of chronic uveitis cases is best accomplished by a sub-Tenon's injection of Depo-medrol. For children it is especially desirable. Injection at six-week intervals usually is well tolerated by the tissues, and accomplishes the desired effect. 0.5 ml. of the 20 mg./ml. solution is given under the upper conjunctiva. The

injection is painless if anesthesia is secured with 4 per cent cocaine solution.

SUMMARY

(1) Two hundred and two patients, aged 16 years or less, have been surveyed for uveitis in our clinic. Seventy-two additional cases with an onset during childhood are reviewed, but the patients were older than 16 years when first seen in our clinic.

(2) Among these 202 patients were 100 cases of anterior uveitis, 78 cases of posterior uveitis, and 4 cases of diffuse uveitis. Twenty patients with entropions resembling uveitis also were surveyed.

(3) Approximately 70 per cent of the anterior uveitis patients could be given an etiologic diagnosis, or recognized as a definite clinical syndrome.

(4) A presumptive diagnosis of toxoplasmosis was made in 60 of the 78 cases of posterior uveitis.

(5) Only four cases of diffuse uveitis were surveyed. This form of uveitis apparently is quite rare.

(6) Non-uveitis entities that pose a differential diagnostic problem include degenerative diseases and vasculitis.

(7) Almost all forms of uveitis in children seriously affect vision, especially if they are chronic. The early onset of the disease perhaps results in visual difficulties earlier in life.

(8) The complications of childhood uveitis are similar to those of adults. Glaucoma especially must be looked for in any childhood uveitis, for it is a major complication.

(9) Treatment is still a major problem in all forms of uveitis and prevention of complications is most important.

ACKNOWLEDGMENT

The authors wish to thank Mrs. Peggy Yamada and Miss Linda Swanson, who helped us greatly in preparing this paper, which required a great deal of chart work and tabulation of the results. We wish also to thank all of the ophthalmologists, who allowed us to see their patients in our uveitis survey clinic.

REFERENCES

1. Kimura, S. J., M. J. Hogan, and P. Thygeson, Uveitis in children, *A.M.A. Arch. Ophth.*, 51:80-8, Jan., 1954.

2. Kimura, S. J., and M. J. Hogan, Chronic cyclitis, *Tr. Am. Ophth. Soc.*, 61:397-417, 1963.
3. Laurin, C. A., and J. C. Favreau, Rheumatoid disease in children, *Canad. M.A.J.*, 89:288-301, Aug. 17, 1963.
4. Smiley, W. K., The visual prognosis in Still's disease with eye involvement, *Proc. Roy. Soc. Med.*, 53(3):196, March, 1960.
5. Godtfredson, E., Pathogenesis of concurrent eye and joint diseases, *Brit. J. Ophth.*, 33:261-70, 1949.
6. Vesterdal, E., and B. Sury, Iridocyclitis and bandshaped corneal opacity in juvenile rheumatoid arthritis, *Acta ophth. Kbh.*, 28:321-37, 1950.
7. Giles, C. L., Anterior uveitis in children, *A.M.A. Arch. Ophth.*, 70:779-85, Dec., 1963.
8. Di Raimondo, V. C., and P. Forsham, Editorial, Some clinical implications of the spontaneous diurnal variation in adrenal cortical secretory activity, *Am. J. Med.*, 21(3):321-3, 1956.
9. Harter, J. C., W. J. Reddy, and C. W. Thorn, Studies on an intermittent corticosteroid dosage regimen, *New England J. Med.* 269(12):591-6, Sept. 19, 1963.

DISCUSSION

DR. W. BANKS ANDERSON. For more than 15 years Drs. Kimura and Hogan, and their associates have been involved in an investigation of uveitis. The complexities of this problem are demonstrated by the fact that even with this special interest they have been unable to establish an etiologic diagnosis in so many of their cases. They have succeeded however in separating their material into three anatomic divisions; anterior, posterior, and diffuse, with wherever possible, subdivisions correlated with categoric systemic disease. Such a classification based on sites of predilection, characteristics in appearance, or patterns of behavior is helpful in bringing some order into a situation badly in need of clarification. Such an arrangement throws the problem into an orderly perspective and permits a critical examination of its different facets.

In the anterior uveitis group of 100 cases 46 are classified as iridocyclitis, 30 of which could not be further identified. Of principal interest are the 12 cases which fall into the uveo-articular complex. Eight of these were associated with Still's syndrome, three with juvenile rheumatoid arthritis, and one with ankylosing spondylitis. In adult rheumatoid arthritis, involving primarily the extremities, the male to female ratio is one to three. In ankylosing spondylitis (Marie-Strumpell arthritis) involving primarily the spine, the male to female ratio is ten to one. Most studies of the uveo-articular complex in adults indicate that approximately 5 per cent of patients with rheumatoid arthritis will develop iritis, and that approximately 25 per cent of patients with ankylosing spondylitis (Marie-Strumpell) will be similarly afflicted. On the basis of clinical behavior, male to female ratio, frequent scleritis, and site of predilection, there seems justification for separating rheumatoid arthritis from spondylitis. On the other hand rheumatologists appear to consider Still's disease, juvenile rheumatoid arthritis, and rheumatoid arthritis as minor variations, principally in age ratio, of the same

disease. If this is true one may question the justification for further breakdown of the uveo-arthritis group as has been done here. The essayists have told us how many children with uveitis have arthritis. Is there any information available as to the number of children with arthritis who also have iritis? Does such a significant differential exist in the incidence or the character of the iritis in children as to support the breakdown of uveo-articular group into the subdivisions noted?

It is interesting to observe the infrequency of sarcoid in this series. This disease is much more prevalent in our area. One-third of all patients with sarcoidosis have ocular involvement. In our clinic in the period 1937-63, 1,500 cases of uveitis were catalogued. Seventy-two of these were under 14 years of age; an incidence of 4.8 per cent. This compares in distribution with the 5.8 per cent incidence in children under 16 in the California study. There were 9 cases of sarcoid (12 per cent) confirmed by biopsy in this small Duke series. All these were Negroes, 6 girls, 3 boys; all were bilateral. Even with steroid therapy this is a devastating disease. The ocular lesions are characteristic; a categorical diagnosis is easy. Unfortunately the poor prognosis cannot be changed until there is a better understanding of the etiology of the disease.

Forty-one of the 100 cases of anterior uveitis were classified as chronic cyclitis. Thirty-one of these were bilateral. The authors have sharply differentiated chronic cyclitis from iridocyclitis and in this we agree. The indolent protracted course of the disease, the absence of external signs of inflammation, the "snowball" globules in the lower anterior vitreous, the secondary vitreous, macular, and papillary changes all seem to indicate a specific pattern unlike that which develops in other types of uveal inflammation. We are surprised that chronic cyclitis has been so frequently noted in children. In the cases we have seen by far the majority have been found in the 25- to 35-year group. I recall only one case under 10 years of age. In our cases, possibly because they were seen after the disease was well established, the most striking feature has been the distention of the retinal veins. The possibility of chronic cyclitis being associated with dysproteinemia was discussed by Dr. Kimura in his paper on chronic cyclitis before this group last year. Investigation by ultracentrifugation revealed no significant deviation from the normal when corrected for age group. Nevertheless the picture in this entity is suggestive of the peripheral changes seen in certain circulatory disorders and the possibility of such a relationship should be kept in mind. For me, this section on chronic cyclitis is the most informative part of this paper. Last year in discussing Dr. Kimura's paper Dr. Maumenee stated, "I repeat that I think so-called 'pars planitis' or peripheral exudative 'retinitis' or 'uveitis' no matter by what name it is called is an entity and should not be confused with many of the lesions classified as cyclitis in the paper just presented." With this statement I am in wholehearted agreement. I expect that further studies will support this concept. I should like to know if Dr. Kimura is in agreement.

Passing over the seven cases of heterochromic uveitis concerning which so little is known I would comment that it seems to me that in the fourth subdivision of anterior uveitis one might well consider the five cases of herpes simplex as exogenous infections contributing little to our understanding of the basic nature of our problem. It is surprising that the author reports only one case of anterior uveitis due to tuberculosis. In my own experience I have seen one dormant iris activated by an intradermal tuberculin test and two cases of recurrent iritis associated with recurrent cutaneous tuberculid reactions. Tubercle bacilli were recovered from lymph node biopsies in one of these cases. These three cases were seen more than 20 years ago. In our clinic we continue to see a significant number of adults with active posterior tubercular uveitis but along with the phlyctenules the anterior type has disappeared.

The authors have made a presumptive diagnosis of toxoplasmosis in 60 of 78 cases of posterior uveitis, 18 are classified as unknown. Even allowing for especial interest in this disease it is difficult to associate such a high incidence with our experience. The disease is said to be bilateral in 58 per cent of cases, the maculas involved in 97 per cent with 17 per cent showing bilateral macular involvement. We are accustomed to think of bilaterality of ocular involvement as the *sine qua non* of systemic disease. In the anterior uveitides 35 of 46 cases had bilateral involvement. In chronic cyclitis 31 of 41 showed bilateral involvement. Uveitis from other proven causes—syphilis, tuberculosis, blastomycosis, and diffuse chorioretinitis—shows a much higher incidence of bilateral involvement. One would suppose that with the usual signs of overwhelming infections so frequently demonstrable by X-ray a higher incidence of bilateral posterior uveitis would prevail in this disease. Perhaps the authors will forgive the skepticism of one trained in the days when a positive tuberculin skin test was presumptive evidence of tubercular uveitis in questioning the validity of the interpretation of the Sabin dye test as positive evidence of toxoplasmosis. If time permits I should like Dr. Kimura to comment on the reliability of this test.

As has been shown in this paper there are many known causes of uveitis ranging from virus infection to nematode infestation. Any one observer will rarely encounter more than two or three of these rarer causes of uveal inflammation. Any generalization which can be drawn from such knowledge of the relationships which may exist between specific disease and certain types of iritis will be useful in alerting the pediatrician to the possibility of such a complication. Forewarned, vision may be preserved by early treatment.

DR. J. V. CASSADY. This paper surely represents a great deal of effort and the authors are to be commended for such a fine presentation.

It is very unusual to have negative dye tests with such unmistakable evidence of toxoplasmosis. In our laboratory, we had one such negative dye test with definite evidence of toxoplasmosis. This occurred in a child

with hydrocephalus and bilateral retinochoroiditis. Both the dye test and dermatologic reaction to toxoplasmosis were negative. At the suggestion of Dr. Frenkel, we repeated the dye test running the titer to a much higher dilution than 1:16,000 which had been previously used and discovered that the dye test was positive in 1:5,000,000 titer. Dr. Frenkel has pointed out that occasionally prozones influence the dye test. This might have been a factor in the negative tests in Dr. Hogan and Kimura's report. If the test were carried to very high titers, it might be positive.

DR. RUDOLPH WITMER. I want to congratulate Dr. Kimura and Dr. Hogan on this very nice paper. I had essentially the same question to ask: how can you possibly make a diagnosis of toxoplasmic posterior uveitis in these 8 cases out of 60 where you had a negative dye test? I think it may be a prozone, but still it is intriguing.

Dr. Francis Kettery reported one case last year in his clinic where the dye test titers were made. They were also negative, but it was found possible to culture *Toxoplasma* from the retroretinal fluid. However, the dye test titer in the serum was negative.

DR. HOGAN. I want to thank all the discussers for their comments. I agree with Dr. Anderson in connection with his discussion of the classification of joint disease. We continued the classification presented here only because we adopted it early in our studies.

Originally the patients had been diagnosed as having Still's disease, juvenile rheumatoid arthritis, or ankylosing spondylitis. If you will remember our original paper on joint disease and uveitis, we did not distinguish too clearly between rheumatoid arthritis and so-called rheumatoid arthritis involving the spine, or spondylitis. Since that time serologic and other evidence has come to light which makes it quite clear that the group of patients with spondylitis are quite distinct from those with rheumatoid arthritis. Also, information has become available that Still's disease and juvenile rheumatoid arthroiditis probably are variants of the same condition, as pointed out by Dr. Anderson. In some children the disease is severe and is accompanied by systemic manifestations, and in other patients it is more mild and is not accompanied by significant systemic disease. The only information available in children—as to the prevalence of uveitis in children with juvenile rheumatoid arthritis—is the publication of Smiley in 1960. He found a 5.5 per cent incidence of uveitis in children with juvenile rheumatoid arthritis.

With respect to sarcoidosis, the prevalence of sarcoidosis in our group of patients is low, probably because there are few Negro children in our uveitis clinic. However, sarcoidosis is a rather uncommon disease in our area.

I know it seems bad to make the diagnosis of toxoplasmosis in the presence of a negative dye test, but Dr. Kimura has pointed out that at

the time we studied these children we were in the habit of testing serum titers at 1:16 or higher. He also pointed out that if we had performed the test in undiluted serum probably all cases would have had positive tests. The reason we now do the test in undiluted serum is because in the San Francisco bay area we have found that if we do the test routinely on undiluted serum we have almost 100 per cent positive dye tests.

With respect to the dye test, we cannot place too much emphasis on the titer. We recently carried out a study with Dr. Leon Jacobs and with Dr. Jack Remington. We sent them fifteen sera that had been processed. Three sera showed a marked discrepancy in the result and the other twelve were fairly close. In two sera Dr. Jacobs had a titer of 1:64,000; Dr. Remington and our laboratory had 1:8,000 or 1:4,000. In the third serum, Dr. Jacobs had 1:8,000 and Dr. Remington had 1:4,000, and our test was negative in undiluted serum.

When things like this happen, I think it makes us all pause and think about laboratory tests in general. As with all tests, we know we cannot depend on the result of one test. We have to do repeated studies on these patients. I think this statement will answer Dr. Witmer's question and also that of Dr. Cassady.

In regard to prozones, this has been a subject of much discussion between Frenkel and a number of others working in this field. Frenkel has been the only one who has shown the importance of the prozone. Dr. Cassady would be the second observer to show that the prozone phenomenon is found in certain sera.

We do run our dye tests in fourfold dilutions, and we practically always run the test up to 1:8,000. I think if there were a prozone we certainly would pick it up by doing this.