

# EPIBLEPHARON\*

BY *Carl Cordes Johnson, M.D.*

THE PRESENT COMMUNICATION is essentially a case report in which a new method of surgical treatment for epiblepharon of the upper and lower lids is presented.

The impetus for making the report was the referral in a short space of time of four children with epiblepharon. The first child, aged three months, came with a diagnosis of "entropion" of the upper lids, and the second (Figure 1) was diagnosed as having "entropion of the lower lids." In the third child, with epiblepharon of upper and lower lids, the referring diagnosis was "ankyloblepharon." The fourth child, a six-year-old girl, presented with a diagnosis of "bilateral ptosis and epicanthus" (Figure 2). Her operations constitute the basis for this report. She had rather mild epiblepharon of both lower lids, noticeable chiefly on downward gaze, combined with very marked epiblepharon of the upper lids and epicanthus tarsalis.

Epiblepharon of the upper lids may be considered to be an exaggeration of epicanthus tarsalis. Epicanthus tarsalis is quite common in young children and is normal in some Oriental races, but the exaggerated form, called epiblepharon superioris, is distinguished from simple epicanthus tarsalis by the lack of a true superior palpebral fold and the presence of a fold of skin which overlaps the lid margin and presses the lashes against the cornea.<sup>1</sup> In epiblepharon of the lower lids, a skin fold also overlaps the lid margin and presses the cilia against the cornea.

It is most important that epiblepharon be differentiated from entropion, because treatment in the two conditions is quite different. It is, of course, possible that the two conditions may be combined, or that irritation of the cornea by the lashes may produce a secondary entropion in cases of epiblepharon.<sup>2</sup>

Congenital entropion is quite rare. Fox<sup>3</sup> found only 22 cases in the

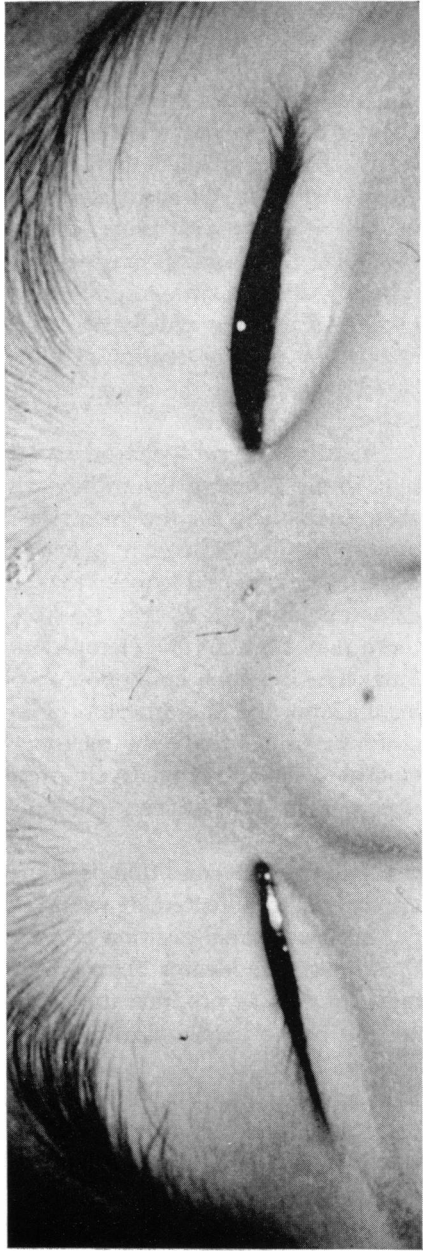
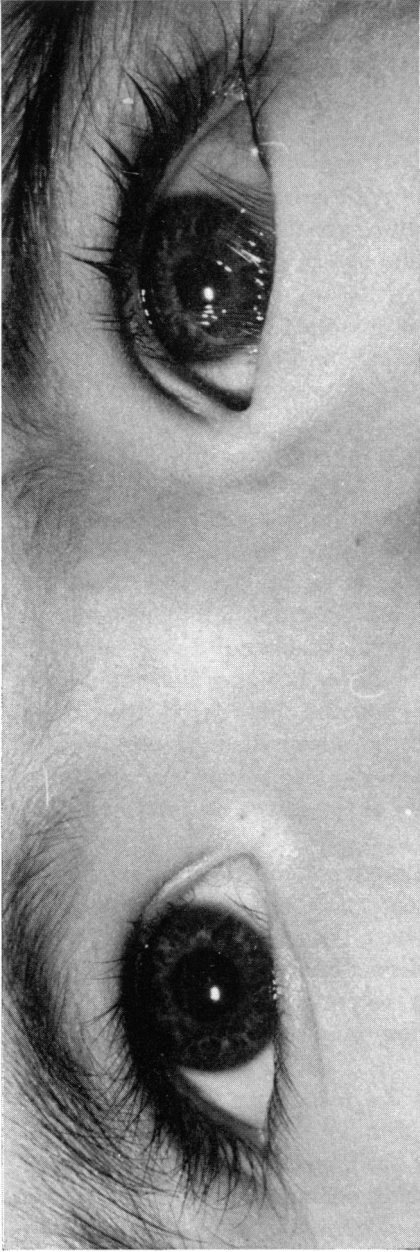\*From the Department of Ophthalmology, Harvard Medical School and the Massachusetts Eye and Ear Infirmary.

literature and in some of these the diagnosis appears to be in doubt. In order for a diagnosis of entropion to be made, the lid margin itself must be turned in against the globe. In epiblepharon it is not; only the lashes turn and they turn straight up (lower lids) or straight down (upper lids), so that they lie flat against the cornea, being held there by the fold of skin. This may, in the lower lid, be present only in downward gaze. Of greatest importance is the fact that true entropion usually worsens with time, while epiblepharon usually lessens and in the lower lids usually disappears by the age of one or two years. The differentiation between epiblepharon of the upper lids and epicanthus tarsalis is perhaps chiefly of academic interest because the former is essentially an exaggeration of the latter. It must not, however, be confused with ptosis; the upper lid margins themselves are at the proper height.

The cause of epiblepharon superioris has been ascribed to a Z-shaped kink in the fibers of the orbicularis and it is stated that the levator in such cases "inserts too near the lid margin."<sup>4</sup> Such statements are interesting but difficult to prove anatomically. From my own surgical experience it would appear that, in the lower lid, the cause is simply an anomalous fold of skin. Possibly, if the condition lasts long enough, there may be some hypertrophy of orbicularis fibers.<sup>2</sup> Swan<sup>5</sup> reported four cases in which epiblepharon of the lower lids was associated with insufficiency of the inferior oblique muscles. He stated that these children usually have a narrow interpupillary distance epicanthus, chubby cheeks, and relatively prominent eyes. In my experience, there is no correlation between epiblepharon of the lower lids and any type of epicanthus.

I believe the condition is somewhat more complicated when the upper lids are affected. It would appear that the orbicularis fibers are not in their normal position or do not have their normal attachments to the tarsus. The levator fibers, which normally extend forward to insert into the skin to produce the superior palpebral fold, are not present and, as in the case presented here, there may not be a normal orbital septum.

In spite of the fact that the lashes are in contact with the cornea, there is in most instances of epiblepharon no evidence of injury to the cornea. When the lashes are actually eroding the epithelium, surgery must be done at an early age if the lashes cannot be pulled away from the cornea and kept away by the use of collodion applied to the skin of the lower lid. If such injury is not striking, then surgical correction should be postponed until it is certain that the condition will not



resolve spontaneously. When surgical correction does become necessary, the procedure used is somewhat different from that used to correct entropion.

A six-year-old child had bilateral epiblepharon of both upper and lower lids with the lashes rubbing the corneas, without any visible damage. Examination showed epiblepharon of the lower lids to be slight, apparently having largely regressed and being evident chiefly in downward gaze. Epiblepharon of the upper lids was so marked that the parents and the referring physician had thought that the child had severe bilateral ptosis. As is shown in the photograph (Figure 2), the folds covered the lid margins and the lashes, and the fold of epiblepharon of the upper lids continued around over the inner canthi as a Mongolian-type epicanthus tarsalis. It was difficult to measure the actual height of the lids because of the overhanging skin fold, but the upper lid margins did not appear to cover the corneas more than 2 to 3 mm, an approximately normal position in a child of this age.

In treating epiblepharon, Duke-Elder<sup>6</sup> and others have stated that the fold may be simply excised. Simple excision in this condition does not seem to be any more reasonable than excision of a bow-string scar or excision of an epicanthal fold. Either the fold should be lengthened or the skin fastened more securely to the tarsus, or both. If one were to excise the fold in the upper lid and fasten the skin to the tarsus, pulling the lower skin flap upward to bring the lashes into position, as is done in the operation for ptosis from the external approach<sup>7,8</sup> or in the Oriental lid fold operation,<sup>9</sup> it is probable that the epicanthal portion of the fold would be exaggerated.

Lengthening of scars or skin folds may be accomplished in various ways using V-Y or Z-plastys, as in the treatment of the usual types of epicanthus.<sup>10,1</sup> In this case a modification of this principle was used. An incision was made the full length of the upper lid, about 6 mm above the lash line, down to the tarsus. It was carried over the inner canthus on the apex of the fold and a V-incision was made at its inner end (Figure 3A). Orbicularis fibers were quite scarce. Excess skin was excised and a narrow strip of orbicularis fibers was excised adjacent

---

FIGURE 1 (OPPOSITE PAGE, TOP)

Epiblepharon of the right lower lid of a 19-month-old child has almost completely corrected itself. The epiblepharon on the left remains. It was later corrected by the author's method.

FIGURE 2 (OPPOSITE PAGE, BOTTOM)

Bilateral epiblepharon of upper and lower lids in a six-year-old girl.

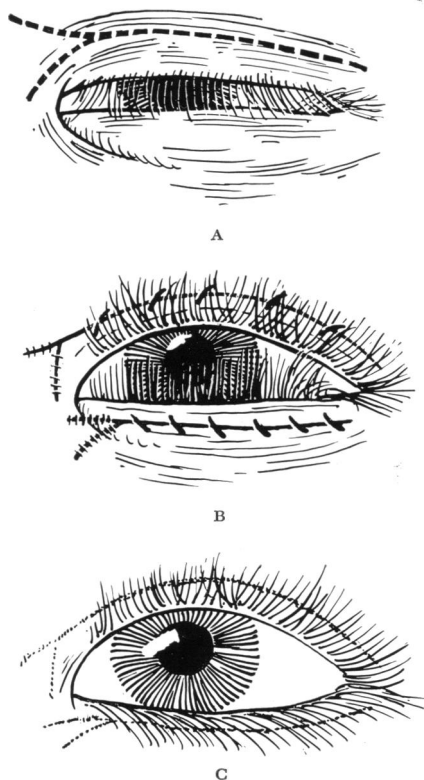


FIGURE 3

A, the incision used for correction of epiblepharon of the upper lid. B, the incision used for correction of epiblepharon of the lower lid. C, the final result.

to the upper and lower skin margins, so that the skin could be sutured directly to the tarsus. As soon as the orbicularis was excised, orbital fat prolapsed. Prolapsing of orbital fat usually indicates that the orbital septum has been perforated, but in this case nothing resembling an orbital septum could be identified. The prolapsing fat was excised and the skin was closed as in the usual ptosis procedure,<sup>7,8</sup> bringing double-armed sutures of 4-0 monofilament nylon through from the conjunctival surface of the tarsus and through the skin edges. Suturing was started at the temporal end of the incision and each suture was placed through the tarsus slightly nasal to its path through the upper skin edge, each suture thus pulling the upper skin slightly and pro-

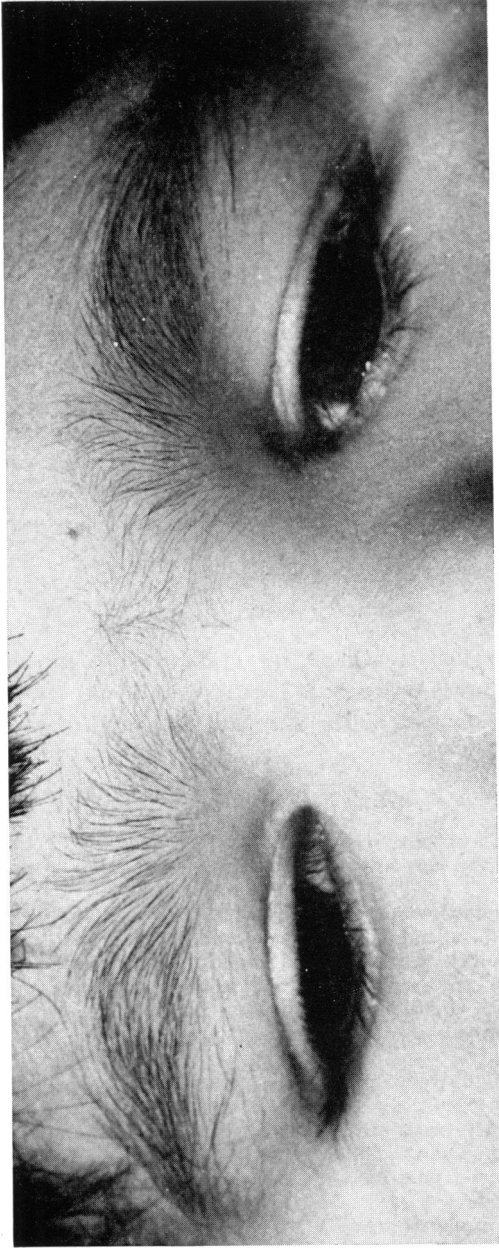


FIGURE 4

The final result of the surgery, as described in the patient shown in Figure 2. The epicanthal fold on the right is completely obliterated but a minimal fold remains on the left. The photograph was taken with the eyes in downward gaze.

gressively nasalward to relax the skin at the inner canthus so that the effect of the V-Y incision was enhanced. The V at the inner canthus was converted to a Y, and this skin was sutured with 6-0 silk. A Frost suture<sup>11</sup> was placed through upper and lower lid margins and the lower lid was pulled up to cover the globe. A pressure dressing was placed and left for six days. On the sixth day the sutures were removed.

Several months later a similar procedure was performed on each lower lid. An incision was made the full length of each lower lid, about 3 to 4 mm below the lash line, with a V at the inner end (Figure 3B). A narrow strip of orbicularis adjacent to the skin margins was excised. The skin was closed starting at the temporal end of the incision with each 6-0 silk suture starting in the lower skin edge, taking a bite in tarsus slightly nasally and coming out through the upper skin edge opposite the tarsal bite, thus pulling the lower skin edge progressively nasalward. In addition, the V at the inner end was converted to a Y to lengthen the fold in this region. The result has been quite satisfactory (Figure 4).

#### SUMMARY

A method of surgical treatment for epiblepharon inferior and for epiblepharon superior is presented. To the best of my knowledge, this constitutes a new approach to the surgical treatment of the condition.

#### REFERENCES

1. Johnson, C. C., Epicanthus, *Am. J. Ophth.*, 66: 939, 1968.
2. Czukrász, I., Congenital entropion due to epiblepharon, *Brit. J. Ophth.*, 34:318, 1950.
3. Fox, S. A., Primary congenital entropion, *Arch. Ophth.*, 56:839, 1956.
4. Karlin, D. B., Congenital entropion, epiblepharon, and antimongoloid obliquity of the palpebral fissure, *Am. J. Ophth.*, 50:487, 1960.
5. Swan, K. C., The syndrome of congenital epiblepharon and inferior oblique insufficiency, *Am. J. Ophth.*, 39 (Pt. II):130, 1955.
6. Duke-Elder, S., *System of Ophthalmology*, Vol. III, London, Henry Kingdon, 1964, p. 859.
7. Johnson, C. C., Blepharoptosis: A general consideration of surgical methods, *Am. J. Ophth.*, 38:129, 1954.
8. Johnson, C. C., Blepharoptosis: Selection of operation, operative techniques, complications, *Arch. Ophth.*, 66:793, 1961; 67:18, 1962.
9. Sayoc, B. T., Plastic construction of the superior palpebral fold, *Am. J. Ophth.*, 38:556, 1954.
10. Johnson, C. C., Surgical repair of the syndrome of epicanthus inversus, blepharophimosis and ptosis, *Arch. Ophth.*, 71:510, 1964.
11. Frost, A. D., Supporting suture in ptosis operations, *Am. J. Ophth.*, 17:633, 1934.

## DISCUSSION

DR. WENDELL L. HUGHES. Dr. Johnson has elucidated the differentiation between congenital epiblepharon and congenital entropion.

(Slide) This slide illustrates a case of severe epiblepharon with entropion of the right lower lid and a simple epiblepharon of the left lower lid. For the correction of the deformity I have used a similar technique but have been somewhat more radical, removing the pretarsal portion of the orbicularis and cleaning off the tissues down to the tarsus, before reattaching the skin.

For the correction of an associated epicanthus I have also been much more radical. (Slide) Usually, as in this case (and similarly in cases of blepharophimosis) there is a noticeable lack of the normal depression around the medial canthus. The correction of this combined deformity (the epicanthal fold and the flat medial canthal area) can be accomplished by means of a Y-V procedure nasally with removal of all of the tissue down to the periosteum. (Slide) The stem of the Y is planned on the side of the nose with the two arms extending above and below the medial canthus into the upper and lower lids respectively. (Slide) Of prime importance is the removal of all subcutaneous tissue down to the periosteum above and below the medial canthal tendon. If the flattening is extreme the medial canthal tendon must be detached and reattached more posteriorly. (Slide) The skin forming the fold of epicanthus is pulled nasally and anchored posteriorly by means of double-arm supramid sutures. (Slide) The skin incision is then closed, forming a V along the stem of the Y on the side of the nose. The depression is maintained by means of a small, tightly wound ball of gauze held in place by means of a pressure dressing changed at weekly intervals for a period of three weeks.

I would feel that this method of dealing with the medial canthal part of the deformity might be considered in Dr. Johnson's case to correct not only the skin fold but also to create a more pleasing depression in the area of the medial canthus.

I wish to thank Dr. Johnson for his courtesy in allowing me to see his paper beforehand.

DR. CARL C. JOHNSON. I wish to thank Dr. Hughes for his discussion. I would like to point out, however, that the treatment of epicanthus inversus is somewhat different from the treatment of epiblepharon. Epiblepharon is a little more closely allied to epicanthus tarsalis. Both Dr. Hughes and I have used a Y-V in epicanthus inversus, but I tend more to use a double Z than the Y-V. In treatment of these children with epiblepharon it is the reverse; rather than a Y-V I use a V-Y, going in the opposite direction.