

# WOUND HEALING AFTER CATARACT EXTRACTION AND POSITION OF THE VITREOUS IN APHAKIC EYES AS STUDIED POSTMORTEM\*

BY *Marshall D. Heller*, MD (BY INVITATION),  
*S. Rodman Irvine*, MD, *Bradley R. Straatsma*, MD,  
AND (BY INVITATION) *Robert Y. Foos*, MD

THE PROGRAM OF routinely removing and examining eyes during autopsies performed at the UCLA Center for the Health Sciences and the Veterans' Administration Hospital in Long Beach provided a unique opportunity to obtain this series of 102 aphakic eyes from 72 patients. Flaxel and Swan<sup>1</sup> reported in detail on wound healing in 18 postmortem eyes. A larger series of human aphakic eyes was examined by Dunnington,<sup>2,3</sup> but his series was composed of eyes removed because of uncontrollable pain due to complications following surgery. In contrast, the series reported here includes only eyes removed from patients who died while in the hospital and who had uncomplicated aphakia of varying duration. All were over 50 years of age except four. Three of these were over 40 and one was 34. Twenty-seven had unilateral aphakia and in one portion of the study the 27 phakic fellow eyes were included for comparative purposes.

At the onset we were interested primarily in why the undersurface of the wound was susceptible to vitreous adhesions months after cataract surgery and whether posterior vitreous detachment always follows cataract surgery.

The available material provided information on:

1. Wound healing in relation to duration of aphakia;
2. Healing of incisions anterior to Schwalbe's line as compared with those posterior and, in a few instances, comparison of shelving or oblique with vertical incisions;
3. Effect of adherence of iris and vitreous on wound healing;

\*From the Jules Stein Eye Institute, the Department of Ophthalmology and the Department of Pathology, UCLA School of Medicine, Los Angeles, California 90024.

4. Completeness of wound healing as judged by presence or absence of posterior gaping, regeneration of endothelium and formation of Descemet's membrane; and
5. Incidence of posterior vitreous detachment.

#### METHODS

All specimens were fixed in 10 per cent formalin and transferred to 50 per cent alcohol. At the outset of the study, 89 specimens that had already been imbedded in celloidin were reviewed. During the course of the investigation, thirteen more aphakic eyes became available for detailed gross examination and three of these were sectioned and stained in time to be included in the final correlation of gross with microscopic findings.

Ninety of the 102 eyes were sectioned horizontally, in a plane just superior to the optic disc and fovea, crossing the cataract incision at the 10:00 and 2:00 o'clock meridians. The remaining 12 eyes were sectioned vertically, crossing the cataract incision at the 11:00 and 1:00 o'clock meridians. Gross examination was performed with a dissecting microscope and a movable source of focal illumination. Of the 102 eyes, 92 were available for histologic examination. These were imbedded in celloidin, sectioned and stained with hematoxylin-eosin, periodic acid-Schiff and picroaniline blue-Lillie.

#### RESULTS

##### WOUND HEALING RELATED TO DURATION OF APHAKIA

The duration of aphakia was known in 64 eyes. There was incomplete wound healing in 34 of these as judged by posterior gaping, that is failure of the posterior stroma to form a smooth posterior surface. Four cases, with duration of aphakia less than a month (8 hours, 10, 12, and 21 days) were excluded from Table 1 as the wounds were grossly separated by postmortem handling. With duration one to six months, all but one showed posterior gaping, as seen in Figure 1. After seven months, 25 showed no posterior gaping, as seen in Figure 2. Twenty-four showed posterior gaping. However, in only two instances of aphakia of seven or more months duration was posterior gaping present without coincident attachment of iris to the wound. This indicates that most wounds are well healed by seven months unless iris becomes attached, preventing wound edges from uniting, as in Figure 3.

Table 1 also shows that, of eight incisions posterior to Schwalbe's line,

WOUND HEALING RELATED TO DURATION OF APHAKIA. TABLE I

Duration (No eyes)	Posterior Gaping		No Posterior Gaping
	Iris Adherent	No Iris Adherent	
0-6 mo (11)	● ●	●●●● ●●●●	●
6-24 mo (12)	●●●● ●●●		●●●●●●●●
2-5 yrs (14)	●●●● ●●●●	●	●●●●●●
5-10 yrs (13)	●●●● ●●●●	●	●●●●●●●●
>10 yrs (10)	●●●● ●●●●		●●●●●●
Totals.	24	10	26

- Wound anterior to Schwalbe's line
- Wound posterior to Schwalbe's line (in trabeculae)
- ▨ Vitreous attached to wound

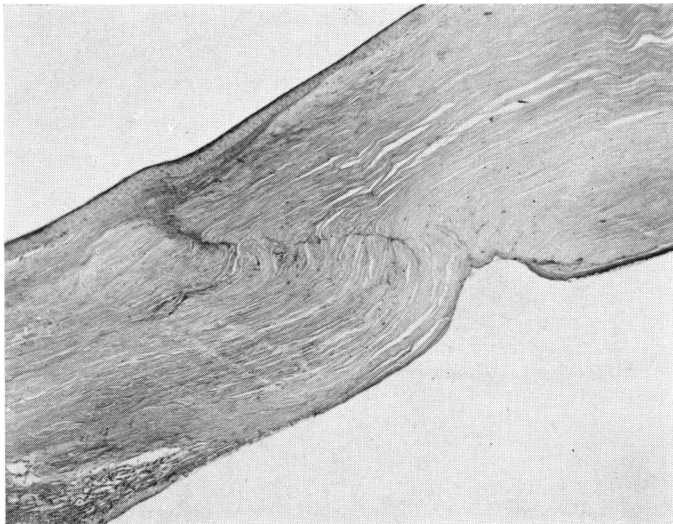
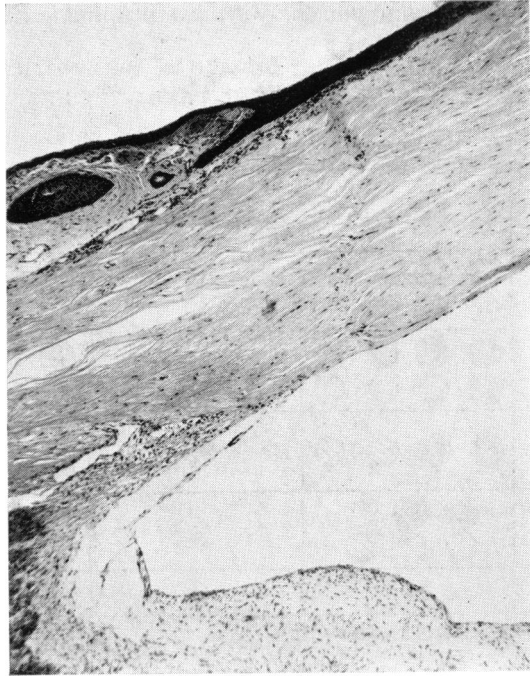
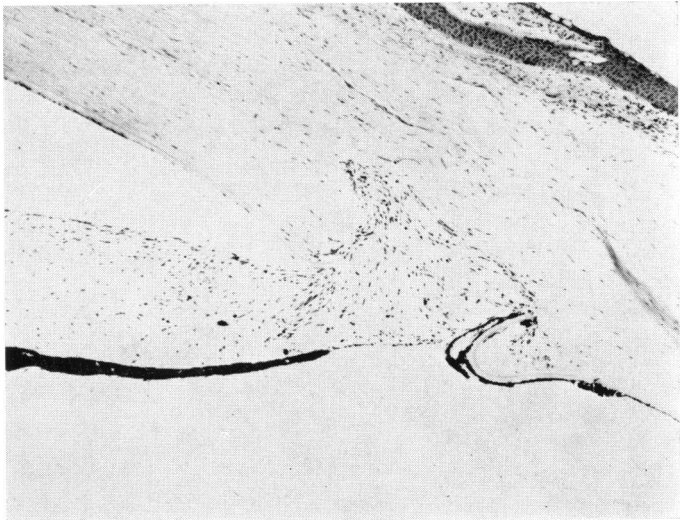


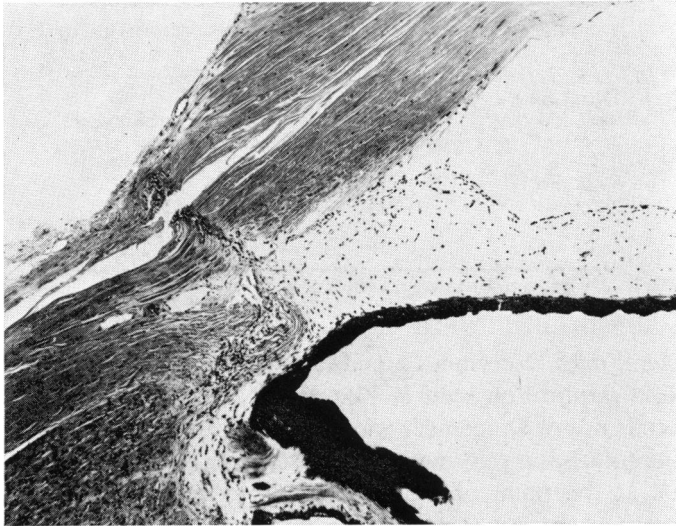
FIGURE 1  
Posterior gaping of wound five months after cataract extraction.  
(× 56)



**FIGURE 2**  
No posterior gaping of wound 15 months after cataract extraction. ( $\times 41$ )



**FIGURE 3**  
Posterior gaping with iris adherence and incarceration 7 years after cataract extraction. ( $\times 56$ )

**FIGURE 4**

Incision posterior to Schwalbe's line with trabecular damage, posterior wound gaping and iris adherence 4½ years after cataract extraction. ( $\times 56$ )

seven had posterior gaping but five of the seven had iris attached to the wound, as in Figure 4. It is not surprising that wounds into the trabeculae are prone to have iris incarcerated.

There were 49 oblique or shelving wounds; nine vertical, and two shelving on one side and vertical on the other. Twenty-five of 49 shelving and seven of nine vertical showed posterior gaping. We feel that no statement should be made as to the advantage or disadvantage of oblique versus vertical sections on the basis of such limited data.

#### REGENERATION OF DESCemet's MEMBRANE

Microscopic sections stained with periodic acid-Schiff were examined to determine the extent of regeneration of Descemet's membrane.

Although barely discernible prior to 24 months, Descemet's membrane could be identified as early as four months postoperatively as a thin line comparable in thickness to the basement membrane of the corneal epithelium anterior to Bowman's membrane (Figure 5a). Between two and five years, the thickness of Descemet's had increased to about  $\frac{1}{2}$  that in uninvolved cornea (Figure 5b). By ten years the thickness had increased to  $\frac{3}{4}$  (Figure 5c) and, by 22 to 23 years, approached  $\frac{1}{2}$  to  $\frac{1}{2}$  the thickness of adjacent Descemet's (Figure 5d).

TABLE 2. REGENERATION OF DESCMET'S MEMBRANE IN WOUNDS OF APHAKIC EYES

Duration aphakia	No. eyes	Average thickness*
0-6 mo	11	*
6-25 mo	12	*
2-5 yrs	14	1/8
5-10 yrs	13	1/4
>10 yrs	10	1/3-1/2

\*Compared to normal thickness

In several eyes Descemet's membrane was composed of two distinct lamellae, a duplication seen in Figure 6. No evidence of reuniting of the severed ends of Descemet's was found. In eyes with posterior gaping and adherent iris, no reformation of Descemet's or corneal endothelium was seen at the point of iris attachment (Figure 3). In three eyes, vitreous as well as iris was attached to the wound.

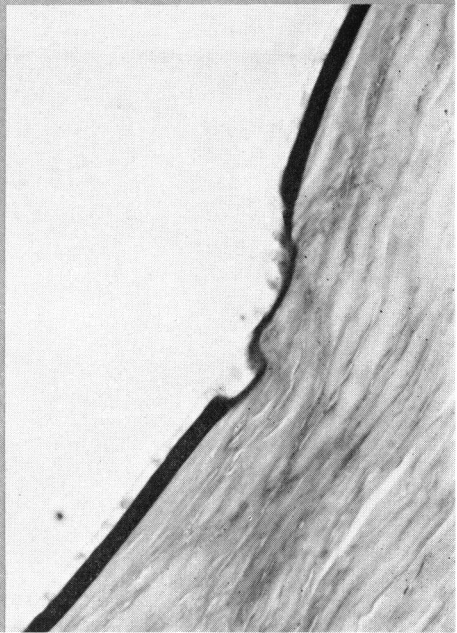

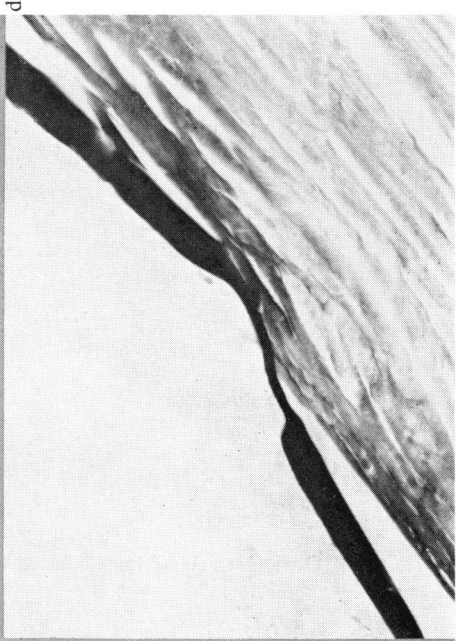
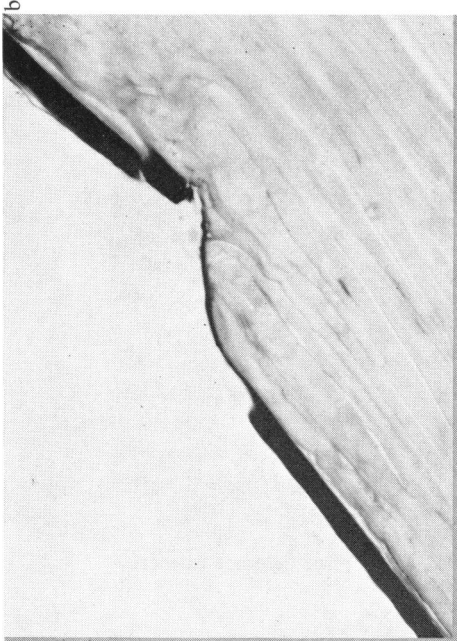
No correlation of the morphology of the endothelial cells with wound healing was evident on routine histologic examination with light and phase microscopy. In many sections with minimal reformation of Descemet's, cells in the wound area resembled those of adjacent, uninvolved cornea. In contrast, endothelial cells in several eyes appeared altered, swollen in some instances, thin and attenuated in others. Figure 7 shows such endothelial cells and posterior gaping seven years after cataract extraction.

#### THE POSITION OF THE VITREOUS

The position of the vitreous was studied histologically in 93 aphakic eyes and compared with 1000 phakic eyes, previously reported by Heller, Foos and Straatsma,<sup>4</sup> as outlined in Table 3. Twenty-six of the 93 aphakic eyes (28 per cent) showed no posterior vitreous detachment. A cortical layer of vitreous remained attached to the retina in the region of the posterior pole (Figure 8). In six eyes (6 per cent), the vitreous was partially detached, the posterior hyaloid seeming to have peeled away

FIGURE 5

A. Descemet's membrane comparable in thickness to the basement membrane of the corneal epithelium 5 months after cataract extraction ( $\times 263$ ); B. Descemet's membrane  $\frac{3}{4}$  normal thickness 7 years after cataract extraction ( $\times 263$ ); C. Descemet's membrane  $\frac{1}{4}$  normal thickness 10 years after cataract extraction ( $\times 263$ ); D. Descemet's membrane  $\frac{1}{2}$  normal thickness 22 years after cataract extraction ( $\times 263$ ).




a

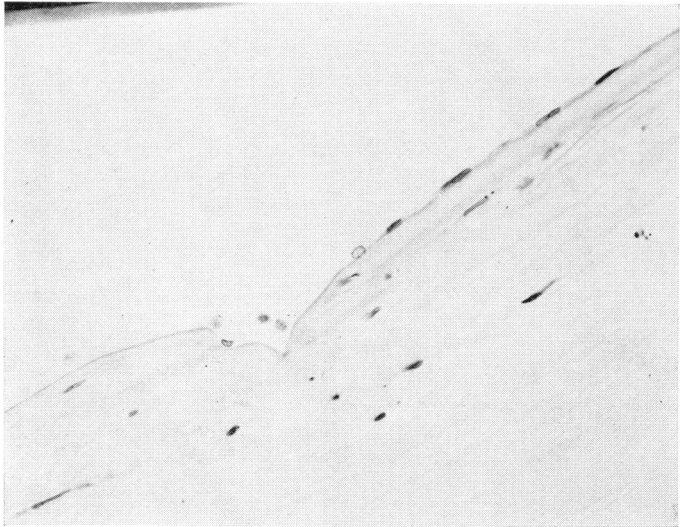
c

b

d



**FIGURE 6**  
Descemet's membrane laminated 10 years after cataract extraction  
( $\times 263$ )



**FIGURE 7**  
Abnormal endothelium in the area of the incision 7 years after cataract extraction ( $\times 263$ )



TABLE 3. POSTERIOR VITREOUS DETACHMENT IN 1000 PHAKIC AND 93 APHAKIC EYES

PVD	Phakic	Aphakic
None	86%	28%
Partial	2%	6%
Complete	12%	66%

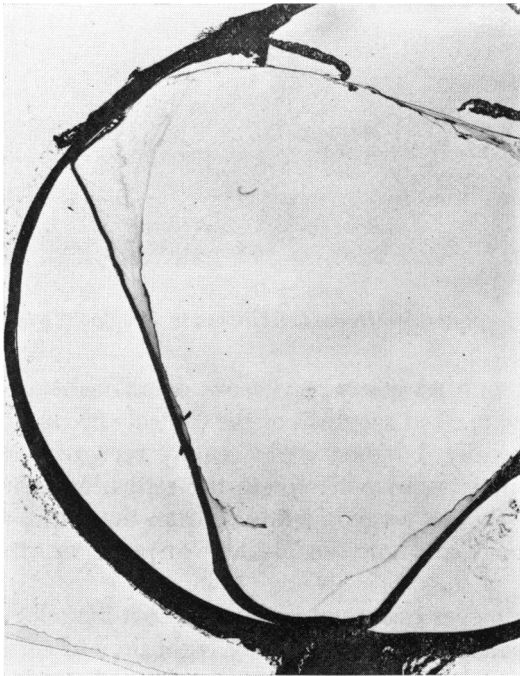


FIGURE 8

No posterior vitreous detachment in an aphakic eye with extensive lacunar degeneration and a thin layer of vitreous in contact with the entire retina and optic disk.

from the retina posterior to the equator. Sixty-one eyes (66 per cent), showed complete posterior vitreous detachment (Figure 9); with posterior hyaloid peeled away from the retina anterior to the equator.

The 72 per cent extent of posterior vitreous detachment is contrasted with the 14 per cent reported in 1000 phakic eyes. Of 339 phakic eyes from patients over 65 years of age at the time of death, only 34 per cent showed posterior vitreous detachment. The finding of 26 aphakic eyes

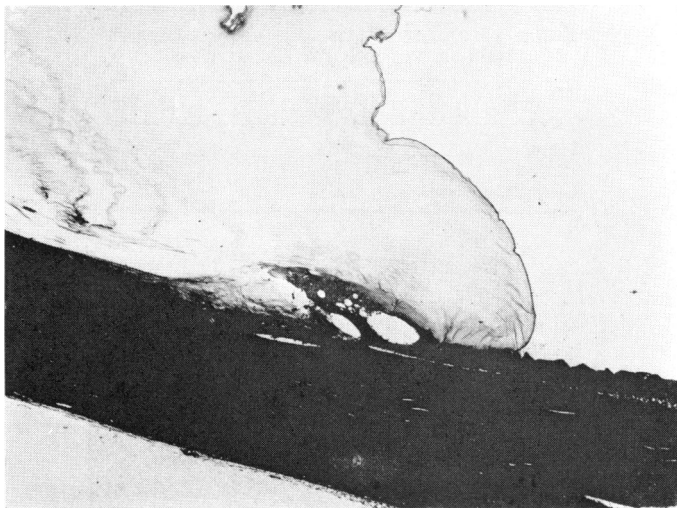


FIGURE 9

Complete posterior vitreous detachment in an aphakic eye.

(28 per cent) with no posterior vitreous detachment was unexpected. All 26 did show marked syneresis of the central vitreous as seen grossly and microscopically, but one could readily recognize remnants of a cortical layer of vitreous adherent to the retina, as seen in Figure 8. There was no peeling away of vitreous from the retina as is typically seen, both grossly and microscopically,<sup>4</sup> in posterior vitreous detachment.

Of 13 aphakic eyes examined grossly, but not included in Table 3 as not yet processed for microscopic study, eight showed complete vitreous detachment; four showed no detachment and one showed partial detachment, an incidence comparable to that in Table 3, found in microscopic sections.

Three of the eight with complete posterior vitreous detachment showed vitreous so congealed as to fail to be affected by gravity, remaining anterior to the equator whether the eye were held cornea up or cornea down (Figure 10), in hanging-drop fashion. In the other five, vitreous moved freely, layering out anteriorly or posteriorly as the eye was tipped, cornea up or down.

To evaluate in a reasonably direct manner the effect of cataract extraction on posterior vitreous detachment, 27 patients with unilateral aphakia at the time of death were analyzed. The aphakic eyes were compared with the phakic fellow eyes after being processed and ex-

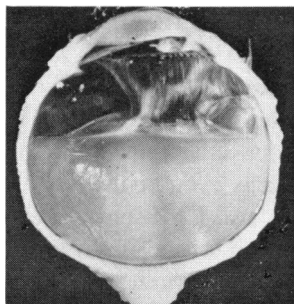


FIGURE 10A  
Complete posterior vitreous detachment with vitreous congeal and unaffected by gravity: held cornea up

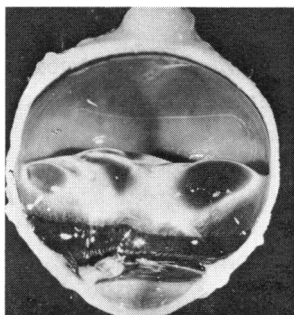


FIGURE 10B  
Held cornea down.

TABLE 4. POSTERIOR VITREOUS DETACHMENT IN 27 CASES OF UNILATERAL APHAKIA

PVD	Phakic eye	Aphakic eye
None	74%	41%
Partial	8%	4%
Complete	18%	55%

amined in a similar manner. The incidence of no posterior vitreous detachment, partial, and complete posterior vitreous detachment in these pairs of eyes is noted in Table 4.

There was no posterior vitreous detachment in 74 per cent (20) phakic eyes as compared with 41 per cent (11) in fellow aphakic eyes. Complete posterior vitreous detachment was seen in only 18 per cent (5) of the phakic eyes with 55 per cent (15) in fellow aphakic eyes.

#### DISCUSSION

The data presented on aphakic eyes, following surgery by different surgeons, using various techniques, available at autopsy and not re-

moved because of ocular complications, invite the following considerations:

Limbal incisions were found further anterior to Schwalbe's line more often than is generally appreciated by the surgeon (Table 1). Relatively few vertical incisions, only nine, were found. Because these tend to have a vertical inclination to the limbus, and may even be inclined posteriorly, it is important, as emphasized by Swan and Christensen,<sup>5</sup> to purposely avoid the trabeculae when making a "watch crystal" vertical section. The merits of vertical versus slanting incisions warrant further review, and should include consideration of the placement, tightness and elasticity of the sutures.<sup>6,7</sup>

Clinically, the posterior aspect of the wound can almost always be identified by gonioscopy, appearing as an irregular dark line, anterior to Schwalbe's line (Figure 11). This appearance can be explained by gaping, as in Figure 12, or slight overriding, dimpling, or notching of the posterior edges of the wound of varying degrees, as seen in Figures 6 and 13, or by increased translucence from alteration in the thickness of Descemet's, only  $\frac{1}{2}$  the thickness of the adjacent membrane being attained even after 23 years (Figure 5d). Histologically we interpret as posterior gaping a failure of the posterior stroma to form a smooth posterior surface. The rate of formation of Descemet's may vary with age at the time of surgery but can not be compared with that reported for animals.<sup>2</sup>

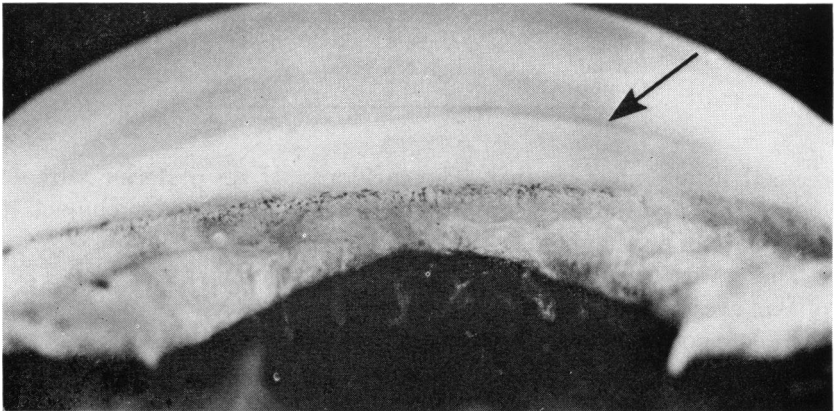



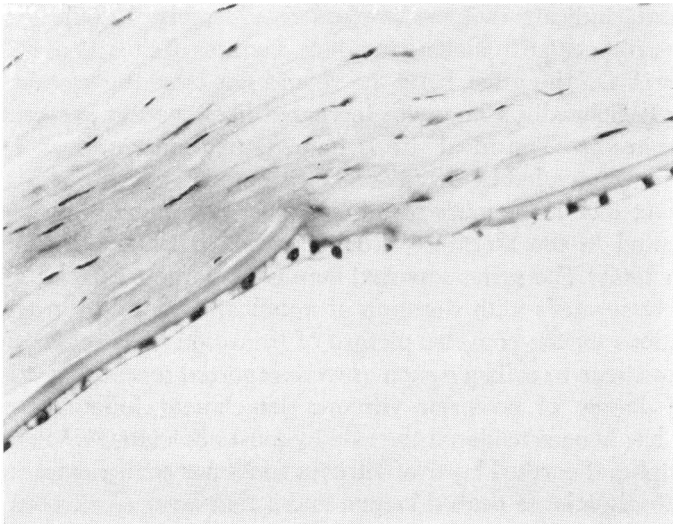
FIGURE 11

Gonioscopic appearance of the incision, seen as a dark line anterior to Schwalbe's line.



**FIGURE 12**

Dark line of incision scar related to irregularity of the stromal scar and posterior gaping.



**FIGURE 13**

Partial regeneration of Descemet's membrane and notching 10 years after cataract extraction. ( $\times 263$ )

The effect of adhesions of iris to the wound, always preventing normal restructuring of the posterior wound, has not previously been so clearly demonstrated. The iris adhesion prevents corneal endothelialization and reformation of Descemet's membrane. Apparently abnormal restructuring did not interfere significantly with the ultimate clinical result as in this series of "normal" aphakic eyes without post-operative complications visual acuity was 20/40 or better in 32 of the 35 eyes in which final visual acuity was recorded.

Endothelium, formed early in the wound area, may be normal or abnormal, or it may be attenuated or swollen for many years post-operatively. This may account for the predilection of vitreous to attach to the inner aspect of the incision when anterior hyaloid rupture occurs months or years after surgery,<sup>8</sup> or contribute to superior limbal corneal edema<sup>9</sup> and a chronic irritable eye as a late complication of cataract surgery.<sup>8</sup>

Failure to find the same per cent of wounds showing vitreous attachments as seen clinically, 10 per cent,<sup>8</sup> is not surprising because staining of vitreous in the anterior chamber is difficult and vitreous strands are easily disturbed in preparation of specimens. Ideally, to demonstrate vitreous attachments, we should have a clinical history, observe autopsy eyes with slitlamp, and section and stain to include the attachments.

The data indicate that the surgeon should make a definite effort to avoid the trabeculae in making incisions, because of the risk of incarceration of iris. On the other hand, he should not have the section too far anterior to Schwalbe's line with increased likelihood of accessibility to broken vitreous. The ideal site is immediately anterior to Schwalbe's line, as recommended by Swan and Christensen.<sup>5</sup>

The fact that Descemet's membrane does not reunite has been well documented in the literature, from Parsons, in 1904,<sup>10</sup> to Flaxel and Swan in 1969.<sup>1</sup> The series reported here is the largest correlating thickness of Descemet's with duration of aphakia. This study provided no observations on the complex picture of transition of granulation tissue to fibrous tissue to collagen such as were reported recently by Flaxel.<sup>11</sup>

Some degree of posterior vitreous detachment following cataract surgery has been considered the rule by most clinicians.<sup>12,13</sup> Persistence of a peripheral cortical layer of vitreous in 28 per cent was unexpected. Undoubtedly a large central lacuna and a thin layer of vitreous on the retinal surface looks like posterior vitreous detachment to clinicians, the anterior surface of the cavity appearing to be the posterior hyaloid membrane.

To make the correct diagnosis, this apparent posterior vitreous mem-

brane must be traced inferiorly and superiorly. If it curves posteriorly to line the retina, a large intravitreal lacuna is present. If it curves anteriorly toward the vitreous base, a posterior vitreous detachment is present. Another helpful indication of complete posterior detachment is the presence of cellular elements or a ringshaped opening on the posterior vitreous membrane at the site of former vitreous attachment at the optic disk.<sup>4</sup> A persistent thin cortical layer would probably not be recognized on a slitlamp examination.

#### SUMMARY

Judging completeness of wound healing by absence of posterior gaping, regeneration of endothelium and reformation of Descemet's membrane, we conclude that:

1. Wounds of less than six months' duration are not well healed posteriorly. Most wounds are well healed in seven months unless iris or vitreous, or both, are attached to the wound, in which case restructuring of the wound is altered indefinitely.
2. In eyes with iris, or iris and vitreous, adherent to the wound, there was no reformation of endothelium or Descemet's at the point of attachment and posterior gaping persisted.
3. Wounds posterior to Schwalbe's line showed more posterior gaping than those anterior, probably because of coincident incarceration of iris.
4. The incidence of posterior vitreous detachment shown microscopically, 72 per cent, and persistence of a thin cortical layer of vitreous attached to the retina, 28 per cent, is a finding inconsistent with clinical reports of nearly 100 per cent posterior vitreous detachment in aphakia.

#### REFERENCES

1. Flaxel, J. T., and K. C. Swan, Limbal wound healing after cataract extraction, *A.M.A. Arch. Ophth.*, 81:653, 1969.
2. Dunnington, J. H., Ocular wound healing with particular reference to the cataract incision, *A.M.A. Arch. Ophth.*, 56:639, 1956.
3. Dunnington, J. H., *Diseases and surgery of the lens (Symposium)*, p. 158. St. Louis, Mo., C. V. Mosby, 1957.
4. Heller, M. D., B. R. Straatsma, and R. Y. Foos, Detachment of the posterior vitreous in phakic and aphakic eyes: Presented at Jules Gonin Club Meeting, Lausanne, Switzerland, September, 1970. Accepted for Publication in *Trans. Jules Gonin Club*, edited by E. B. Streiff, Vol. 80, New York, S. Karger.
5. Swan, K. C., and R. Christensen, Half-lap incision and closure in cataract surgery, *Am. J. Ophth.*, 61:1330, 1966.
6. Welsh and Welsh, *The New Report on Cataract Surgery*, Miami Educational Press, 1969.

7. Dunnington, J. H., and E. F. Regan, *Am. J. Ophth.*, 35:167, 1952.
8. Irvine, S. Rodman, A newly defined vitreous syndrome following cataract surgery, *Am. J. Ophth.*, 36:599, 1953.
9. Brown, S. I., and J. M. McLean, Superior limbal dystrophy after cataract extraction, *Trans. Am. Acad. Ophth.*, 73:465, 1969.
10. Parsons, J. H., *The Pathology of the Eye: Vol. 1, Part 1*, New York, G. P. Putnam's Sons, 1904.
11. Flaxel, J. T., Histology of cataract extractions, *A.M.A. Arch. Ophth.*, 83:436, 1970.
12. Jaffe, N. S., and D. S. Light, Vitreous changes produced by cataract surgery: a study of 1058 aphakic eyes, *A.M.A. Arch. Ophth.*, 76:541, 1966.
13. Irvine, S. Rodman, Pupillary block and angle block after cataract surgery, *Annals of Ophth.*, 2:178, 1970.

### DISCUSSION

DR ELLEN REGAN. Three years ago at the American Medical Association Flaxel and Swan reported the histologic examination of 18 aphakic eyes obtained at post mortem. This was the largest such study to that date and I was very much impressed not only by the authors' fine work but by their ability to obtain these 18 eyes. Today I wish to express my overwhelming respect for the tenacity and perseverance required by Heller, Irvine, Straatsma, and Foos to obtain 102 clinically well healed aphakic eyes. Our West Coast colleagues compel our admiration.

The problem of prolonged posterior gaping of the cataract incision is intriguing for most of us have believed that the framework of wound healing, the cells and ground substance, is completed much earlier than six months. Late changes in wound healing involve an increase in tensile strength which in turn is derived from maturation of collagen fibers. As the present authors have shown Descemet's membrane is also a late development.

According to these authors' findings there must be late changes in the wounds in the area of posterior gaping for this phenomenon was observed in seven of eight eyes without intraocular tissue adherent to the wound and removed within six months of operation, but in only one of 26 similar eyes removed later than the sixth postoperative month. Why does such delayed wound healing occur? What activates the process when it does take place? Could a clue be found in knowing how many of the 11 eyes removed within six months of surgery were removed at two months, how many at four months and how many at six months after operation?

As clinicians it is important to know when the cataract incision is well healed. In this respect Thorpe's studies are helpful. In his gonioscopic observations of 318 aphakic eyes, Thorpe found 66 which showed minor separations of the posterior wound eight to twelve weeks after operation. The separations were usually between the suture sites. In 53 of these eyes the area of posterior gaping closed by the end of the fourth month after cataract extraction.



When I received the authors' paper I thought a constant aphakic refraction would indicate a firmly healed corneoscleral incision. Therefore, I selected at random 50 aphakic eyes with normal postoperative healing which have been observed for more than one and one-half years after surgery.

Forty-four of the 50 eyes had a permanent refraction by 2½ months after operation, four by the fourth postoperative month and two showed changes in refraction more than six months after surgery. Would the authors hazard an opinion on the role of posterior gaping with and without tissue inclusion in late refractive changes after cataract extraction?

Most of us who have studied ocular wound healing have been aware of the role of tissue incarceration in preventing normal healing of endothelium and permitting such abnormal processes as stromal overgrowth but I did not realize this endothelial problem had not been discussed in modern literature. I thank the authors for calling it to our attention.

In 1953 Irvine showed that late attachment of the vitreous to the cataract incision might take place at the site of posterior gaping. Today he and his colleagues have presented the finding of central syneresis of the vitreous which I suspect is a most important concept, because clinically the condition may mimic posterior detachment of the vitreous. I hope the authors will tell us how we may differentiate between syneresis and detachment of the vitreous. Can this thin layer of vitreous in front of the retina account for macular puckering and some preretinal membranes?

DR TROUTMAN. In support of general surgeons, we have just seen a very adequate demonstration of their dictum that a surgical wound heals from front to back and not from end to end. We believe, and have practiced for the last seven to eight years, that the cataract incision should be closed much more deeply than has been customary. The anterior one-third to one-half suture placement and closure of a cataract incision invites the posterior gaping that Drs Heller, Irvine, Straatsma and Foos have demonstrated histologically. We also advocate using a non-absorbic monofilament nylon suture that maintains the wound closure for a period of six months postoperative, closely approximating Descemet's membrane.

Another important aspect is the trend to very early fitting and wearing of contact lenses immediately post-cataract surgery. The pressure and manipulation of the eye and wound may have some effect on the incision. I wonder if there is any information as to whether or not the eyes examined had worn contact lenses.

DR IRVINE. We must keep in mind that some of the eyes in this report were removed at autopsy as long as 12 years ago, and sections made from celloidin blocks prepared at that time. In some instances surgery was performed 10 to 20 years ago, and we do not know the exact technique used but we do know the eyes were "normal" aphakic eyes, with good vision.

There were eleven eyes with duration of aphakia 6 months or less, and all but one of these showed posterior gaping. We do not know the explanation. Perhaps sutures were not properly placed. We do know that the findings warn us that posterior gaping can persist for years. It can be monitored postoperatively by gonioscopic examination, and it always surprises me to see the dark line and ridge gonioscopically. An attempt to understand this initiated this study.

I believe the word "syneresis" was first used by Dr Schepens. I believe Dr Straatsma objects to it, although in the Oxford and Webster dictionaries it is described as a degenerative cavity with a surrounding wall, as Dr Regan indicated. I think we can use "syneresis," although I said "posterior lacuna" to avoid the word.

As Dr Troutman says, we are now using finer sutures and placing them deeper than when these eyes were done. Sutures are now less reactive, and we do get better wound closure and have fewer iris and vitreous adhesions.

As to the effect of contact lenses, I do not know whether or not the patients in this series were subjected to the trauma of putting in contact lenses. From my own experience I would say that patients do have trouble if contacts are fitted too early – that is, earlier than 2 or 3 months – with resultant broken vitreous and irritable eye.

I want to emphasize the fact that eyes do remain irritable for a long time if iris or vitreous has adhered to the posterior surface of the wound.