

SILICONE KERATOPROSTHESIS*

BY *Albert D. Ruedemann, Jr.*, MD

FOR OVER 120 YEARS OPHTHALMOLOGISTS HAVE ATTEMPTED TO REPLACE CLOUDY OR diseased corneal tissue with both homologous and heterologous tissue. Nussbaum, in 1852, attempted to replace diseased corneal tissue with a glass collar button type keratoprosthesis.¹ In the recent past, the work of Cardona and his colleagues has been most prominent in the development of various types of implants. It would appear that the majority of these implants are made with a rather pure form of poly-methyl or ethyl methacrylate. Part of the implant may be made from teflon or some other inert plastic substance.

Although silicone of medical grade is known to be relatively inert for various purposes in the body, optical grade medical silicone has not received much attention from the ophthalmologist.

After several conferences with Mr Fritz Jardon, and Mr Irwin Ritter of Jardon Plastic Research, the first silicone keratoprostheses were formulated in the summer months of 1962. Four immature stump tail monkeys were obtained by grant.† A surgical procedure was determined and outlined. (see outline)

PROCEDURE: MONKEY

Monkey number one was operated upon in November, 1962. The others were operated upon at intervals thereafter. Several procedural points should be noted: (1) It was felt that the earliest procedures were to be performed merely to obtain a through and through corneal scar. (2) The keratoprostheses were to be placed eccentric to the center of the cornea so that the monkey's vision would be interfered with as little as possible. (3) The procedure was to be performed exactly simulating operating room conditions. In brief, an intralamellar corneal flap was made through a temporal opening. When the flap had been made allowing the insertion of

*From the Department of Ophthalmology, Wayne State University School of Medicine, Detroit, Michigan.

†Detroit Receiving Hospital Research Corporation.

TABLE I. PLASTIC CORNEAS FOR MONKEYS

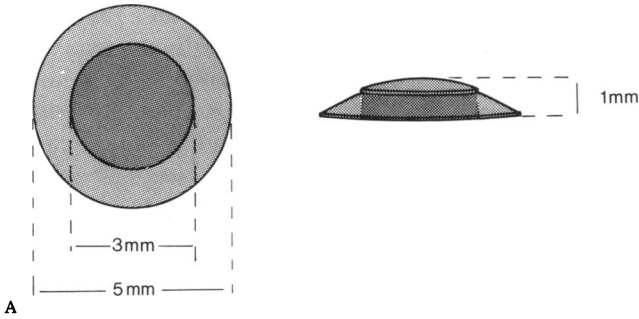
-
- A. Four Stumptail monkeys
 1. Corneal diameter 9-10 mm
 2. Pupil 1-2 mm
 3. Thickness of cornea approximately 0.7 mm
 - B. Anesthesia
 1. Ether
 2. Experienced anesthetist
 - C. Instruments
 1. Plastic corneas (? mold with curve or keratometer for corneal curve)
 2. Trephine 3 mm or 4 mm
 3. Inserter
 4. Gill and Paufigue
 5. Needle holder and 7-0 or 6-0 plain sutures
 6. St. Martin Tier
 7. Lid sutures
 - D. Procedure.
 1. Anesthetize with ether
 2. Lid sutures superior and inferior
 3. Use large trephine edge to cut peripheral groove
 4. Split cornea
 5. Cut central button
 6. Insert plastic with inserter
 7. Sew edge of lamellar section of cornea
 8. Sew lids together
-

the prosthetic device, a 3 mm corneal trephine was placed through the layers in which the central portion of the button would be placed. After placement of the implant, the lamellae of the cornea were sutured at the limbus and the chamber reformed with air. The eye was dressed with Polysporin ophthalmic ointment and the lids were sewn together. No implant was retained more than three months. The third and fourth monkeys were operated upon using the second model keratoprosthesis device which had holes cut in the flange of the single piece cast device.

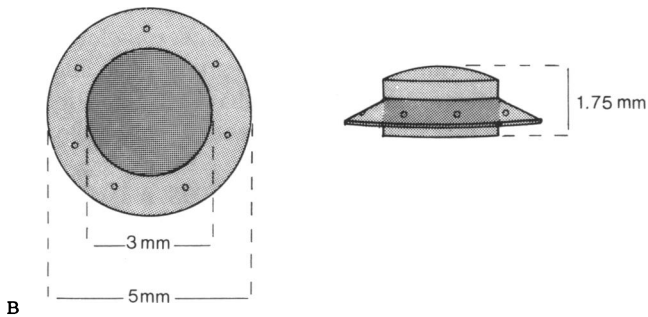
Monkey number four was operated upon again in February, 1963 and expired one day post operative. Monkey number three was also operated upon again in February of 1963. The other two monkeys were operated upon again in May of 1963. The postoperative course was more or less uneventful except that monkey number two had extruded its keratoprosthesis by July 2, 1963 and there was a notable descemetocoele. The other two monkeys had their prosthetic devices in place. Monkey number one was treated with Eastman 9-10 monomer. The two remaining buttons extruded by the fall of 1963.

In February of 1964 the procedure was repeated on three monkeys using the perforated model silicone implant. The three remaining monkeys maintained their implants through the summer of 1964 at which time the implants were all noted to be extruded.

KERATOPROSTHESIS I



KERATOPROSTHESIS II



STUMP-TAILED MONKEY

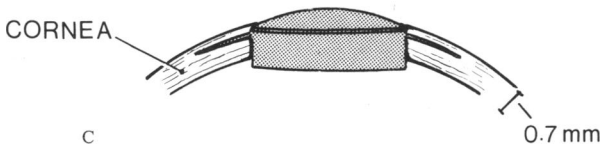


FIGURE 1

A: Keratoprosthesis number one. The original design used on the first series of stump tail monkeys. B: Keratoprosthesis number two. It should be noted that peripheral holes were placed in the flange of the implant as well as increasing the thickness of the implant from 1 mm to 1.75 mm. C: Method of placement in the stump tail monkey. Intralamellar placement of implant. The anterior curve of the implant was obtained by a mold obtained from the anterior segment of the monkey and related to the original anterior curve of the cornea.

RESULTS

Four monkeys had the same eye operated upon three times over a period of nearly two years. One monkey expired after the second surgical procedure. Following the first operation on all four monkeys, no button was retained more than three months. On the succeeding procedures, all four buttons, with the exception of the one used in the expired monkey, were retained from three to six months. No surgical infection was noted following any of the procedures. Not one eye was lost. There was notable difficulty with anesthesia and postoperative observation of the operated eyes. The experiment was discontinued in November 1964.

PROCEDURE: RABBIT

On December 14, 1964 Dr Silas Brady, Medical Director of the Dow Laboratories for Medical Research, spoke to the ophthalmology staff and residents of Wayne State University on silicones and their surgical applications. At that time he mentioned the use of dacron cloth in association with silicone materials; binding the two together with silicone glue for cardiovascular application. Subsequent to that it was decided to redesign an implant, utilizing a cast silicone button with a dacron cloth skirt glued to the button.

Shortly thereafter, and by mid January of 1965, a series of ten rabbits were operated upon utilizing the number three model keratoprosthesis. Because the corneal thickness of the rabbit is approximately 0.4 mm, it was decided that the implant would be placed into the anterior chamber. This was after a number of attempts to place an intralamellar button. The operative procedure was changed in that the anterior chamber was entered from the standard superior approach and the implant was placed into the anterior chamber with the dacron cloth resting against the endothelium of the cornea.

RESULTS

No particular surgical difficulty was noted, however, the postoperative care and follow-up in the rabbit series was complicated by severe local staphylococcus (coagulase positive) infection. Several eyes were lost to uncontrolled infection of the anterior segment shortly after surgery. Several infections of the globe and adnexae were controlled with local Garamycin ophthalmic solution which was then an experimental drug. Three eyes were maintained without further incident or difficulty through February 1966 at which time the experiment was concluded.

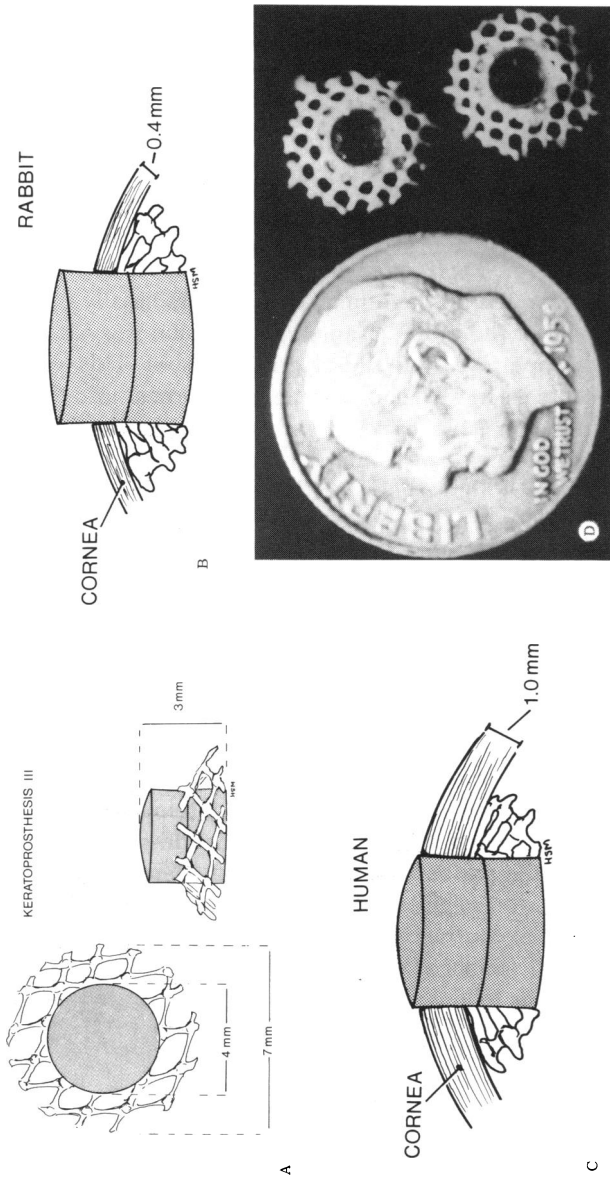


FIGURE 2

A: Keratoprosthesis number three. This is a single piece cast silicone implant with a glued on dacron cloth skirt. After the opening in the anterior chamber was made, usually at the superior limbal area, the implant was put in place through the corneal opening and pushed up with no sutures. The limbal wound was closed. The chamber was occasionally filled with air. B: The placement of the keratoprosthesis implant in the rabbit. Again the anterior curvature of the implant related to the curvature of the anterior corneal surface of the rabbits as obtained by a mold. C: The placement of the keratoprosthesis implant and its position in the human cornea. Again the anterior corneal surface related to the anterior corneal surface as to a basic anterior curvature. The placement of the implant is essentially the same as that noted with the original monkey series. D: The relationship of the keratoprosthesis, number three, to a United States dime in terms of size.

PROCEDURE: HUMAN

The procedure performed on humans was to be only on eyes which fulfilled several requirements: (1) No eye would be considered which had other than a low potential for visual function. (2) No eye would be considered which was thought to have any chance for maintenance of function by regrant or other surgical procedure. (3) No eye would be considered which had less than two corneal or anterior segment procedures relating to the cornea and maintenance of its function. (4) Any eye for consideration would be approved by at least two ophthalmic surgeons; Dr's A. D. Ruedemann, Sr., A. D. Ruedemann, Jr., and O. A. Brown.

The basic procedure performed on the human eyes was essentially that which had been developed for the rabbit. Namely, an incision was made in the limbal area (usually superiorly) into the anterior chamber. This was made after a 3 mm corneal incision was made through the cornea, into the anterior chamber. The limbal incision was enlarged to allow placement of the prosthesis. In many of the eyes it was noted that organization of the anterior segment was so severe that excision of both organized anterior segment and midvitreous tissue was necessary to allow placement of either prosthesis number three or the satellite type (prosthesis number four).

RESULTS

It was obvious, particularly in the eyes that showed degeneration of the anterior ocular segments, that supportive tissues would be necessary. A number of the cases included in the case reports indicate that stored sclera, stored cornea, fresh cornea, stored fascia lata, autologous fascia lata, as well as conjunctiva obtained from the opposite cul-de-sac, would be used if necessary. All of the patients were given local chemotherapy. All of the patients were followed as closely as possible, particularly when secondary infection, cicatricial contraction of the cul-de-sac, or necrosis, might take place. In several instances this was impossible because the patients were not available for follow-up over extended periods.

SUMMARY OF RESULTS

MONKEY

The first experiments performed on the stump tail monkeys answered several questions: (1) Procedure. In a cornea with a thickness of 0.7 mm an intralamellar implant could be performed at least three times in the

same corneal area without technical difficulty. The one attempt at an intralamellar implant using tissue glue did not afford better results than the other techniques. All of the implants were expulsed in six months by a retroprosthetic membrane which seemed to grow across the back of the implant without affecting the anterior chamber, the lens, or creating any unusual tissue reaction. (2) Results. The three remaining monkeys with a flange perforated implant could not retain the implant longer than six months. In no case was an eye lost to infection and at the conclusion of the experiment the three remaining eyes had intact anterior chambers with no cataractous change in the lens.

RABBIT

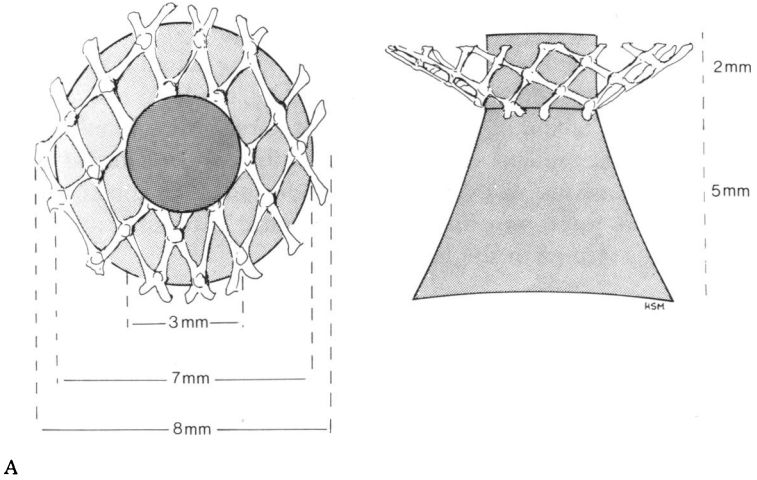
It was obvious that the cornea of the rabbit is not thick enough (0.4 mm) to allow an adequate intralamellar implant. For this reason the procedure was changed to a through and through implant which was placed on the endothelium of the cornea by a dacron cloth skirt. The series of anterior chamber implants were notable in that there was no remarkable surgical reaction. The eye tolerated the silicone implant with the dacron cloth skirt with no apparent difficulty. As the months passed it was obvious that the laboratory milieu created a different maintenance situation from that which was available to the monkeys. The main problem was late extraocular infection. This was fairly well controlled by local instillation of Garamycin ophthalmic solution. At the end of one year, when three rabbits had maintained their implants with no secondary difficulties, it was decided to conclude this experiment and attempt to perform the procedure on the human eye.

HUMAN

This series consists of twenty-seven patients operated upon from the spring of 1966 to the fall of 1973 and all followed under the same controlled circumstances. Regardless of the original diagnosis, at least two-thirds of the eyes subjected to a keratoprosthesis had a fibrotic or cyclitic membrane in the anterior chamber. This was, in fact, the reason for the design of the satellite type implant.

Four patients probably had a significant chance for vision; cases 1, 5, 6 and 7. Case 1 had a diagnosis of dominant Groenouw's dystrophy, plus several systemic diseases; essential hypertension, a bleeding tendency, and gastric ulcers. On each surgical admission he required special medical supervision. His acute loss of vision due to massive vitreous hemorrhage with secondary development of the retroprosthetic membrane, may well have related to one of his several systemic problems. In any

KERATOPROSTHESIS IV



HUMAN

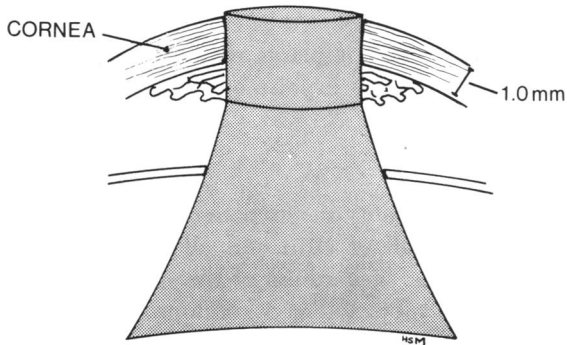


FIGURE 3

A: Keratoprosthesis number four — Satellite type implant used when there was obvious organization of the anterior ocular segment and vitreous. Essentially the same procedure was performed, and in this situation, the limbal area was opened large enough to allow the entry of the implant, which was then pushed in place through the corneal opening, allowing the dacron cloth skirt to adhere to the endothelial surface of the cornea, if such was available. B: The placement of the keratoprosthesis, satellite type, with a fibrotic membrane of the anterior chamber.

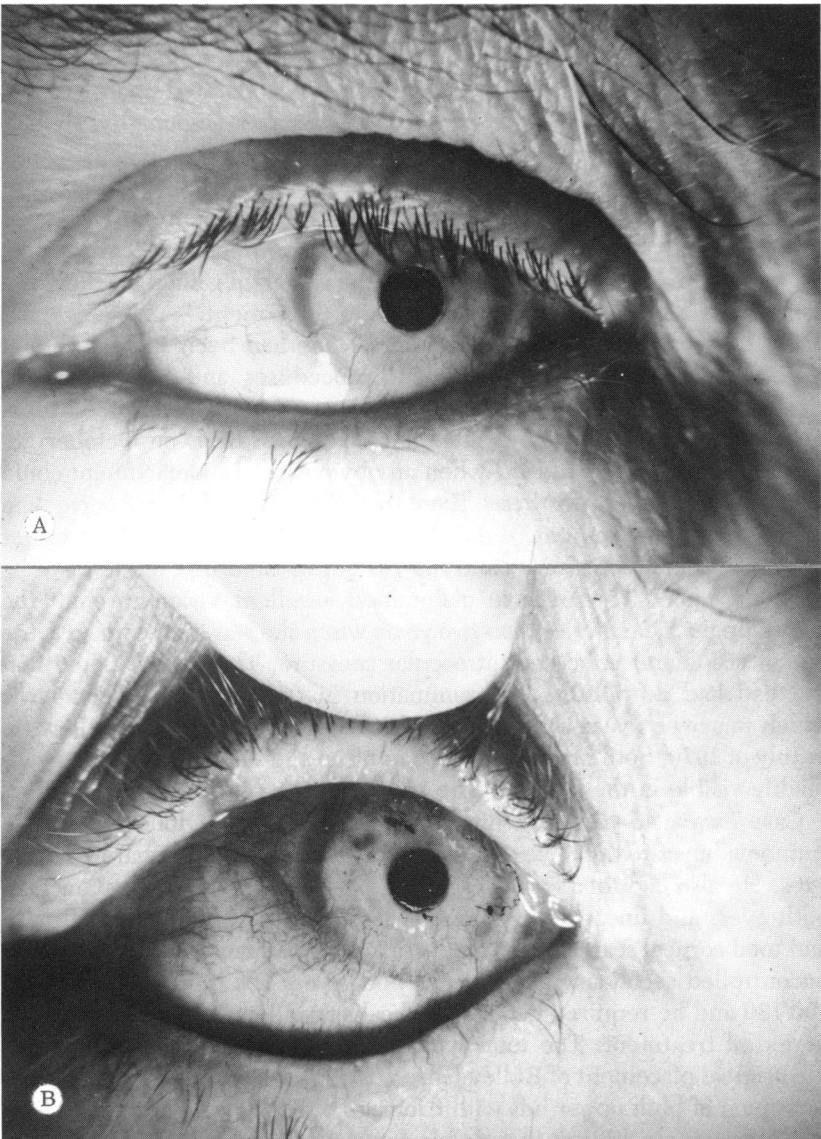


FIGURE 4

A: Case 1. The left eye of a 45 year old male in April of 1958 who had two previous keratoplastys on the left eye. Photograph taken six months postoperative. Vision 20/20. B: Case 1. Photograph taken 14 months postoperative. Vision reduced to light perception and projection after massive vitreous hemorrhage. Patient subsequently developed a posterior prosthetic membrane one year later and the implant was expelled by January 1971.

case, he had since been operated upon again by the newer* keratoplasty techniques (namely 10-0 synthetic suture) and has functional vision in his right eye (20/30 +4).

Case 5 was almost 80 years of age when he was operated upon. He was a far advanced diabetic with a Grade III to IV diabetic angiopathy. He had marked vascular difficulty in his legs, leading to gangrene. His ocular status, besides the retinal changes, included surgical aphakia with severe Fuchs' endothelial-epithelial dystrophy. A development of a massive intravitreal hemorrhage, even though he had subsequent clearing, was not unexpected. It should be noted that the vision he gained for the short period obtained was of great satisfaction to the patient.

Case 6 was a 71-year-old white female. She had been subjected to at least five previous anterior segment procedures and had secondary glaucoma in both eyes when first seen. Even so, she maintained functional vision in her right eye after her keratoprosthesis on October 28, 1966 until November 7, 1967 when an obvious retinal detachment could be seen through her prosthesis. Even though she had adequate correction of her retinal detachment, she did not regain the vision available to her prior to detachment surgery and the patient insisted that the left eye be operated upon. The left eye maintained excellent vision through the follow-up period of better than two years when she was seen with an acute loss of vision and increased intraocular pressure. The patient noted that she had had no ophthalmic examination in the period between visits which was over a year in duration. When she finally was lost to follow-up in July of 1970, both prostheses were in place and the fundus details were readily visible in the left eye. The right eye was phthisical.

Case 7 was a 45-year-old white male first seen in 1966, following severe ammonia burns to both eyes which had caused total symblepharon of both eyes. He also had total corneal scarring of both eyes, mature cataracts of both eyes, and uncontrolled secondary glaucoma of both eyes. He also had total corneal scarring of both eyes, mature cataracts of both eyes, and uncontrolled secondary glaucoma of both eyes. His blood pressure was 190/130 and he required general medical surveillance through his entire period of treatment. The total symblepharon had been controlled with the original placement of Ridley lenses. Even so, he developed cicatricial entropion of both upper lids with trichiasis of both upper and lower lids. It was extremely difficult to maintain tissue coverage over the keratoprosthesis. Donor cornea, sclera, fascia lata, and autologous fascia lata were

*Micro surgical techniques have been routinely utilized since 1956.

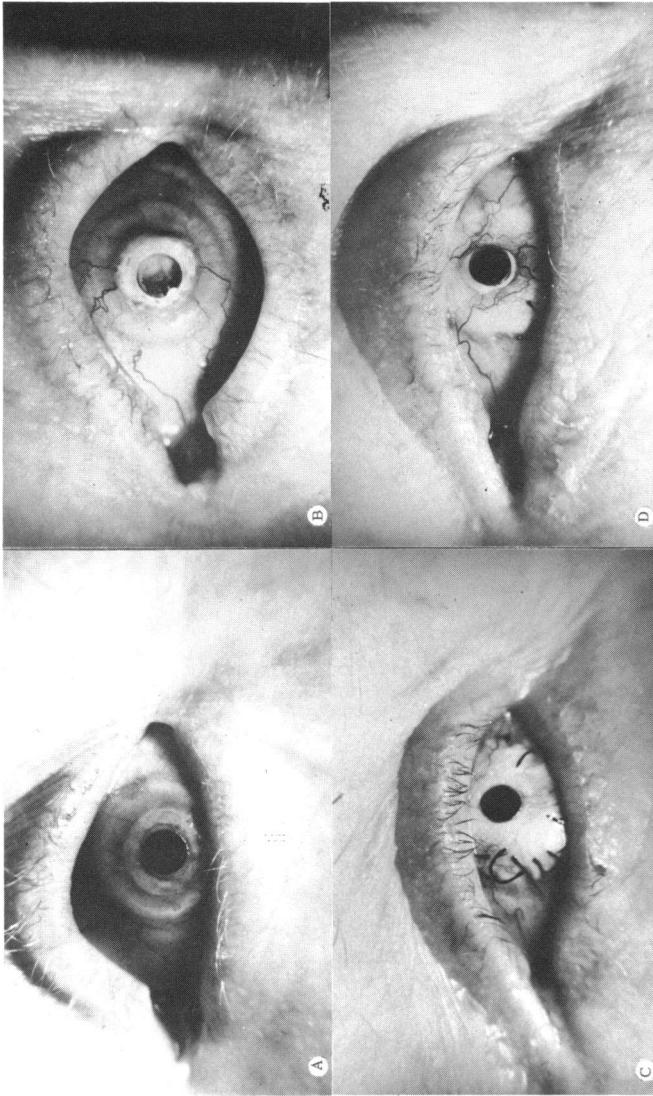


FIGURE 5

A: Case 5. A 79 year old white male diabetic in 1962. Vision right eye 7/200, left eye count fingers at two inches. Previous history of penetrating keratoplasty left eye with no improvement in vision. B: July 1966 three months postoperative. In August of 1966 patient developed an intravitreal hemorrhage left eye. The following May (1967) he had developed a retroprosthetic membrane. C: On July 26, 1967 a scleral transplant with replacement of keratoprosthesis (satellite type) was performed. Photograph approximately six weeks postoperative shows the implant in place with the overlying sclera still in place. D: Photograph taken in March of 1968. Subsequent of this, patient developed a posterior prosthetic membrane by August of 1969 and was subsequently lost to follow-up in 1970. At that time the patient was aged 86.

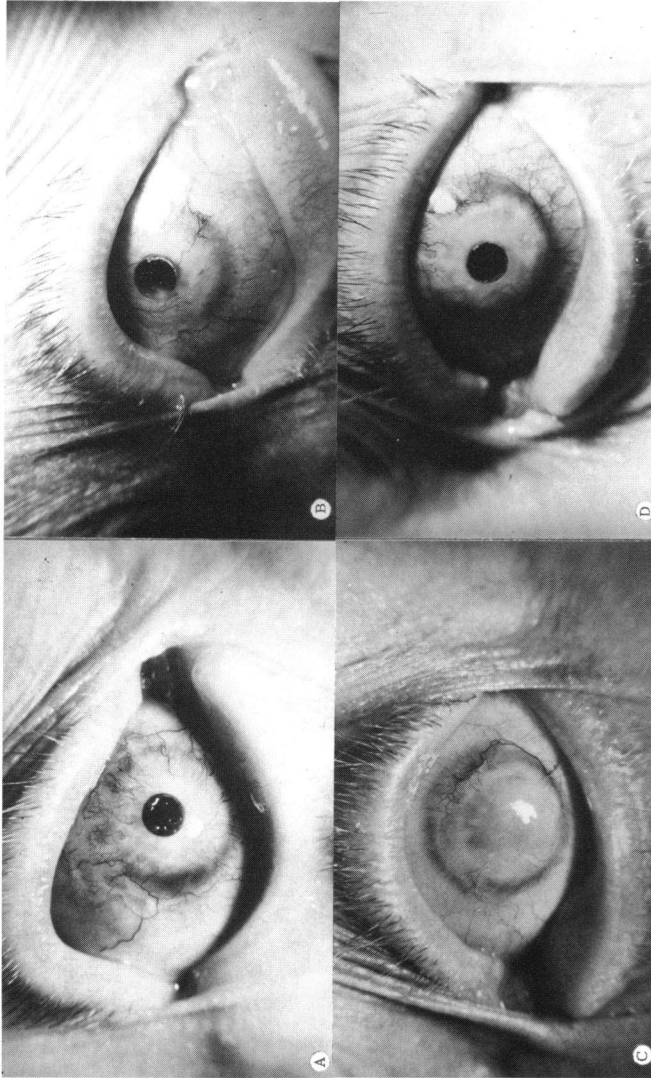


FIGURE 6

A: Case 6. A 63 year old white female in 1958 with an original diagnosis of keratoconus. Three months after keratoprosthesis implanted, right eye. B: By November of 1967 who was noted to have a retinal detachment in her right eye which was repaired. The photograph taken in February of 1968 shows the beginning of a retroprosthetic membrane in the right eye. At that time vision was reduced to light perception and projection. C: Left eye in November of 1967 prior to implantation of keratoprosthesis. D: Left eye taken in February of 1968 shows the prosthesis three months after implantation.

tried, plus a conjunctival graft from the right superior cul-de-sac in an attempt to maintain the tissue structure surrounding the keratoprosthesis. The patient maintained functional vision and was able to work as an executive in a training situation. He was able to read small print for two years until the keratoprosthesis was expelled. The expulsion was probably due to the multiple procedures performed on the eye over that period.

Eighteen of the remaining twenty-three patients had a notable fibrotic or cyclitic membrane of the anterior chamber on initial implantation of the keratoprosthetic device. This was, in fact, the reason for the design of the satellite type prosthesis.

Five cases which did not have a fibrotic or cyclitic membrane of the anterior chamber are cases number 2, 10, 11, 24 and 25. Case 2 was a 28-year-old white male who had been severely burned with metallic sodium. He had multiple procedures in an attempt to maintain his anterior ocular segment and cul-de-sacs. He also had cicatricial entropion of both upper lids, trichiasis of both lower lids, staphylococci infection of both eyes, and perforation of one globe secondary to infection.

Case 10 was a 70-year-old white female with a total lipid corneal dystrophy of both eyes. She had maintained her keratoprosthesis in her left eye from April 18, 1969 to date with light perception and projection, large objects, and color vision. The patient required a silicone contact lens and a conjunctival purse string in July 1973 for a periprosthetic necrosis and she maintained vision.

Case 11 was 68 years old when first seen in 1967 with total symblepharon of both eyes due to ocular pemphigus. His corneas were completely opaque. After his operation he could see his plate and had "getting around" vision for six months, at which time his keratoprosthesis was lost due to panophthalmitis. During this period the patient had been out of the city and had no ophthalmic treatment.

Case 24 was a 14-year-old white female first seen in 1961. A keratoprosthesis was performed because she had multiple procedures with repeated intraocular and extraocular infections and perforations of the globe. The eye was lost due to infection within five months after placement of the keratoprosthesis.

Case 25 was a 52-year-old white male, He was first seen in 1951 and had a history of lye burns in both eyes, previous corneal transplants both eyes, uncontrolled diabetes, and recurrent intra- and extraocular infection. Keratoprosthesis, when performed on January 3, 1967, was difficult to maintain because of cicatricial entropion of both eyes and recurrent secondary infections of both eyes. Although he only maintained vision for

a three or four month period, it was adequate for him to get around his home and surroundings. The loss of his prosthesis was undoubtedly related to his general systemic condition as well as his severe ocular changes created by the original trauma.

The remaining 18 patients all had light perception in their remaining eye. However, three of these patients (Case 9, 19, and 22) had a second eye. These three patients, who had a remaining eye before keratoprosthesis surgery was attempted, are important for several reasons. Two of these patients, Cases 9 and 19, had total ocular symblepharon secondary to ocular pemphigus.

Case 9 was a 77-year-old white female first seen in 1965. She claimed light perception in both eyes; her left eye had an atrophic disc, aphakia, severe Fuchs' dystrophy, and secondary glaucoma. Light perception could not be proven objectively with the left eye. However, with the right eye the patient had definite light perception. Even though she developed total symblepharon, she claimed — and was able to demonstrate — light perception in her right eye. This vision was maintained from May 26, 1966 when the keratoprosthesis surgery was performed until June 7, 1972 when she was last seen.

Case 19, a 53-year-old black female who was originally seen after multiple procedures secondary to bilateral lye burns, had total symblepharon. She maintained light perception in both eyes. Her first prosthesis surgery was performed on the right eye on January 14, 1969 and on the left eye on May 18, 1973. Both implants are in place. There is nearly total symblepharon of both cul-de-sacs.

Case 22 had an original diagnosis of congenital glaucoma. After multiple surgical procedures for this disease she had a keratoprosthesis operation performed on her light perception eye on July 12, 1966. This prosthesis was expulsed five months later but she has maintained light perception in her remaining left eye to date.

The remaining 15 patients had only one eye when first seen. Light perception was claimed, but not necessarily proven objectively in all patients.

Case 17, a white female who had been followed since 1952 had keratoprosthesis surgery performed on July 26, 1966. The keratoprosthesis was then replaced on April 24, 1973 with the satellite type. This patient has maintained light perception, projection, and color vision to date with a +22.00 diopter correction. She had improved from eccentric roving fixation which had been maintained throughout the entire period. This was the only patient who had evidence of squamous epithelial inclusion on placement of the satellite type implant. The previous surgical proce-

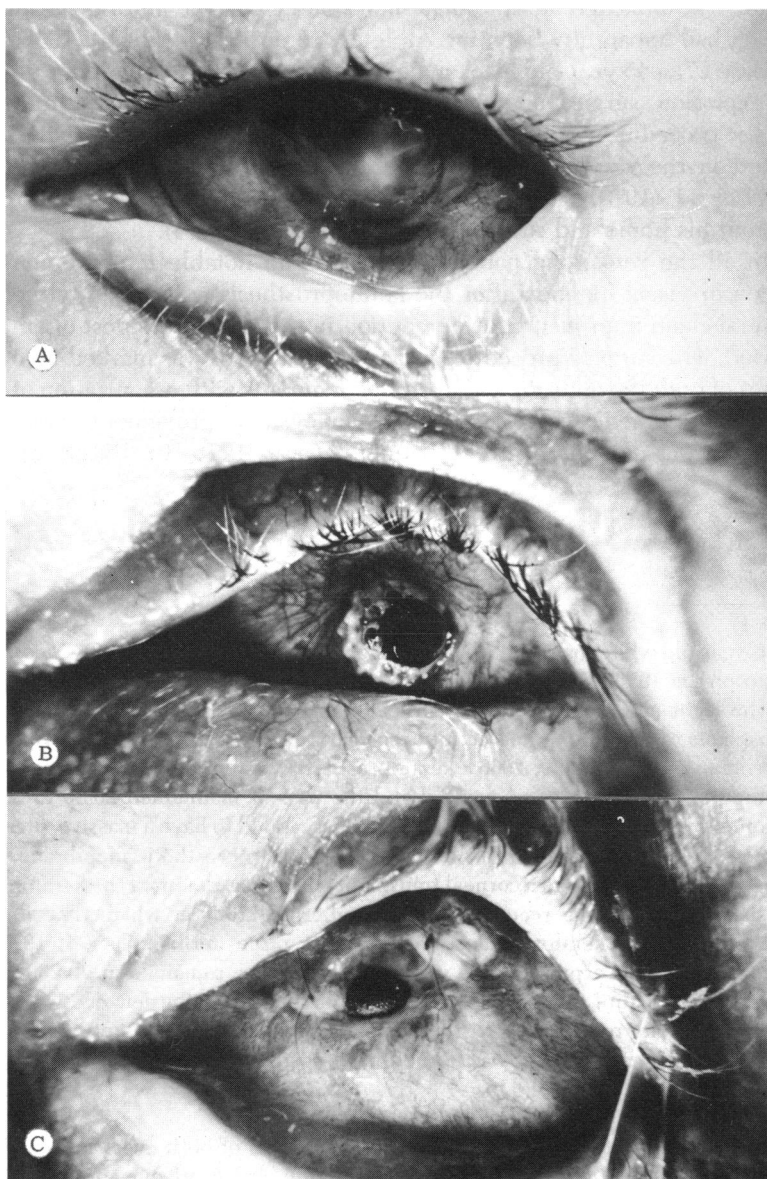


FIGURE 7

A: Case 7. Left eye in November of 1967 preoperative. **B:** The periprosthetic necrosis was repaired with a scleral overgraft and replacement of keratoprosthesis with a satellite type in June of 1970. **C:** Taken in December of 1970 prior to the development of a retroprosthetic membrane. Two months later the keratoprosthesis was expulsed.

dures had indicated an epithelial inclusion cyst of the anterior chamber which had apparently been incompletely removed on July 10, 1956.

Case 27, a 45 year-old black male who had multiple amputations due to an explosion, surgical anophthalmos of the left eye, a history of multiple plastic procedures, and glaucoma in the right eye. A recordable ERG was noted in the right eye and a keratoprosthesis was performed on December 11, 1973. He has maintained vision which allows him to get around his home and surroundings to date (April 1974).

In all the remaining patients there was no notable improvement in vision or visual function after the keratoprosthesis was placed, although several claim improved light perception in the immediate post operative period. The surgical procedure indicated that there was marked involvement of both the anterior and posterior segments with organization of the vitreous in practically all patients. Psychological improvement in over all function was notable in several patients. (Cases 4, 15, 16, 18, 20, 21 and 26).

CASE REPORTS

CASE 1

A 46-year-old white male had a clinical diagnosis of dominant Groenouw's corneal dystrophy in 1958. The patient had five anterior segment procedures performed on the right eye including three corneal transplants. He had had two corneal transplants to the left eye and an intracapsular cataract extraction with peripheral iridectomy. On March 29, 1966 a keratoprosthesis was placed in the left eye. The postoperative course was uneventful and the patient maintained 20/30 to 20/20 vision until August 16, 1966 at which time he was found to have a massive vitreous hemorrhage. Subsequent to this he developed a retroprosthetic membrane. On June 27, 1967 patient had a corneal transplant with replacement of the keratoprosthesis. The membrane recurred by September 30, 1969 at which time it was removed and the keratoprosthesis remained in place until January 4, 1971 at which time it was expulsed. The vision in the left eye remained at 20/200 from June 27, 1967 until September 30, 1969. Final vision in the left eye was light perception and projection. Histopathologic evaluation of the retroprosthetic membrane indicated that it was formed from posterior corneal elements.

CASE 2

A 28-year-old white male had metallic sodium burns of both eyes. He was first seen in December of 1965 with light perception and hand movements with a perforated globe on the left. He had a 9 mm penetrating graft performed on the left eye on December 8, 1965 and a 9 mm penetrating graft on the right eye on December 23, 1965. He was noted to have cicatricial entropion of both upper lids

and mature cataracts both eyes. On April 9, 1966 he had a keratoprosthesis inserted after lens extraction, left eye. On May 5, 1966 a reinforcement of the anterior chamber with donor cornea material was performed, and on June 7, 1966 he had a complete conjunctival flap, left eye. On July 26, 1966 he had a replacement of the corneal graft (10 mm) and the silicone button was replaced. On December 7, 1966 he had an 8 mm full thickness corneal transplant with a keratoprosthesis procedure performed on the right eye. The cornea was replaced with donor sclera on February 17, 1967. The keratoprosthesis was replaced and a retroprosthetic membrane was removed. On July 13, 1967 a 9 mm penetrating graft was performed on the right eye, after the right prosthesis had expelled. The corneal graft of July 13, 1967 perforated and was replaced on October 5, 1967 with a 5 mm full thickness graft. On December 29, 1967 the spastic entropion of the upper lids was corrected with a bilateral Hotz-Anagnostakis procedure. The patient then returned to his home and was lost to follow-up. He had light perception, left eye only.

CASE 3

A 17-year-old white female had a diagnosis of congenital glaucoma both eyes in 1925. The left eye was removed. When first seen on July 13, 1925 the patient had a corneal leucoma right eye, cataract right eye, and secondary glaucoma right eye. On September 9, 1925 a cataract extraction on the right eye was performed. The patient had a corneal transplant on February 20, 1948 which required reinforcement by conjunctival flap on March 2, 1948. Secondary glaucoma was controlled but the patient required a 6 mm penetrating graft on July 30, 1959 with removal of lens and fibrous pupillary membrane. On July 12, 1966 a keratoprosthesis operation was performed on the right eye. Postoperative course was uneventful until October 17, 1968, at which time patient had acute inflammation of the right eye which was controlled by antibiotic therapy. On November 12, 1968 a satellite type implant was inserted with removal of fibrous membrane and on July 15, 1969 a donor sclera overlay was placed on the right eye. This procedure was repeated on October 24, 1969. This implant was maintained until June 26, 1970 when the keratoprosthesis was revised and a silicone lens was placed over the prosthesis. This was maintained for two years to the end of follow-up with continuing development of phthisis bulbi.

CASE 4

A 45-year-old white male lost his right eye in a mine explosion during World War II. The left eye had light perception and temporal projection with organization of the anterior chamber. The tactile tension was normal. Keratoprosthesis surgery was performed on September 27, 1966. The postoperative course was uneventful except for some deposition of white sebaceous appearing material on the surface of the implant which was removed with a cotton tipped swab. Patient was lost to follow-up on December 27, 1966.

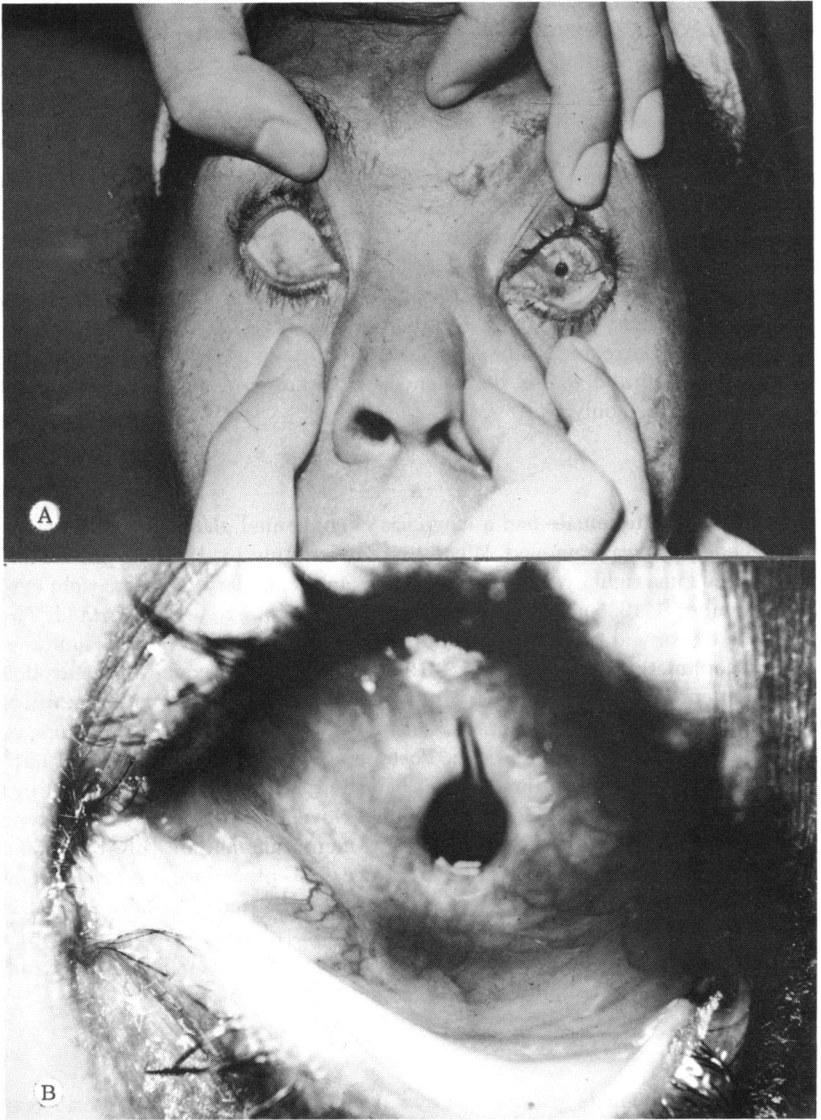


FIGURE 8

A: Patient with severe burns of both cul-de-sacs and corneas of both eyes. Restoration of cul-de-sacs had been performed using molded sclera lenses. Photograph shows the keratoprosthesis in the left eye several months duration. (Case 8). B: Close up of the left eye of this patient. The implant had been kept in place with approximately two reimplantations from the spring of 1966 to August of 1973.

CASE 5

A 79-year-old white male had far advanced ocular diabetic changes and peripheral vasculopathy in 1962. Vision in the right eye was 7/200, and vision in the left eye was counting fingers at two feet. Far advanced Fuchs' dystrophy was present in both eyes. On January 29, 1963 a 6 mm penetrating graft was performed on the left eye with no improvement in function. On April 13, 1966, a keratoprosthesis procedure was performed on the left eye. Postoperatively the patient had visible ophthalmoscopic details with a grade III to IV diabetic vasculopathy and he attained "getting around" vision. On August 10, 1966 he had a massive retinal hemorrhage into the vitreous with very slow resolution. On May 3, 1967 he had a definite posterior prosthetic membrane in the left eye. On July 26, 1967 a scleral transplant with replacement of the keratoprosthesis (satellite type) was performed. This was maintained until August 28, 1969 at which time there was reformation of a retroprosthetic membrane. The patient at that time was 86 years old. Histopathologic evaluation of the retroprosthetic membrane indicated it was essentially composed of posterior corneal elements.

CASE 6

A 63-year-old white female was seen in 1958 because of keratoconus of both eyes. She had had corneal transplants on the right eye in 1953 and 1955 with a cataract extraction on the right eye in 1957. She had corneal transplantation on the left eye in 1956 with an iris prolapse requiring repair. Vision on first examination was 10/200 right eye, and hand movements left eye. On July 29, 1961, an 8 mm penetrating graft was performed on the left eye, followed by an iridencleisis on August 8, 1961. On October 28, 1966 a keratoprosthesis was performed on the right eye. Immediate postoperative vision was 20/100 which was maintained until November 7, 1967 when the patient was observed to have a retinal detachment in the right eye. This was treated on November 20, 1967. A keratoprosthesis was performed on the left eye. The vision was 20/30+ through February 23, 1970 at which time the patient noted a loss of vision due to increased intraocular pressure left eye. Optic atrophy with a deep cup was found at that time. She was treated for a secondary glaucoma left eye and was lost to follow-up on July 7, 1970, with visible fundus details in the left eye; vision light perception with moving shadows. The right eye was phthisical but the prosthesis was in place, both eyes.

CASE 7

A 45-year-old white male suffered severe ammonia burns to both eyes in March of 1966. On first examination he was found to have nearly total symblepharon both eyes, increased intraocular pressure both eyes, and mature cataracts both eyes. Vision was reduced to less than 20/200 in the right eye and to counting fingers in the left eye. He had a marked corneal leucoma in both eyes. The medical evaluation revealed a blood pressure of 190/130. On March 23, 1966 an iridencleisis was performed on the right eye and on June 14, 1966 an intracapsular cataract extraction was performed on the left eye. The patient returned to work

but vision was not adequate and on January 23, 1967 a 6 mm full thickness graft was performed on the left eye. On February 17, 1967 a 10 mm full thickness graft and an intracapsular cataract extraction were performed on the right eye. He returned to a working situation but the corneal transplant had to be replaced on the right eye on July 28, 1968 at which time a pupillary membrane was removed. Two months later, the vision corrected to 20/40-, but this gradually failed due to a central corneal erosion found on November 20, 1968. On December 6, 1968 a keratoprosthesis with stored scleral overlay was performed on the left eye. Vision was 20/50 on April 3, 1969, but there was periprosthetic corneal necrosis. This was repaired with a scleral overlay. Vision returned to 20/40 on July 1, 1969. On November 28, 1969 a stored scleral overlay was again required for the left eye. Vision again was maintained until June 2, 1970 at which time a repeat scleral graft was required, and then a free conjunctival graft (right eye to left eye) on June 26, 1970. On September 4, 1970 a fascia lata autograft was performed on the left eye. By December 11, 1970 patient was noted to have a retroprosthetic membrane and by February 12, 1971 the button had expelled. He had functional vision in the left eye from December 1968 to December 1970.

CASE 8

A 43-year-old black female was seen in 1969 with a clinical diagnosis of lye burns of both eyes. She had a total symblepharon which had been corrected by lysis and placement of Ridley lenses, both eyes. She had a keratoprosthesis in the left eye 1966 and several corneal transplants had already been performed on the left eye. On April 22, 1969 a stored scleral graft was performed on the left eye and on May 2, 1969 a keratoprostheses procedure with stored scleral overlay was performed on the right eye. At that time an anterior segment fibrotic membrane was noted in the right eye. On May 16, 1969 the scleral overlay had necrosed and a stored fascia lata graft was performed on the right eye. This rapidly necrosed and on May 27, 1969 it was replaced with a scleral graft and the implant was replaced. The implant again required replacement on June 10, 1969 and on September 23, 1969 a repeat scleral graft with silicone contact lens overlay with replacement of keratoprosthesis with satellite type was done. On December 2, 1969 the sclera required replacement as well as re-implantation of keratoprosthesis. On December 12, 1969 the sclera was replaced with stored fascia lata to the right eye. By March 2, 1970 the keratoprosthesis had extruded from the left eye and was replaced on March 3, 1970 with stored fascia lata. The keratoprosthesis again extruded and in December 1970 required replacement. A superimposed silicone corneal lens was placed on both eyes. This had come out by August 24, 1971, and a new silicone lens was placed in the left eye. This was removed by January 19, 1972. By August 2, 1973 both prostheses were in place but there was apparent phthisis bulbi, right eye. The left eye maintained light perception, moving shadows, and color perception. Duration of the keratoprosthesis in the right eye was three years, eight months; left eye two years, eight months.

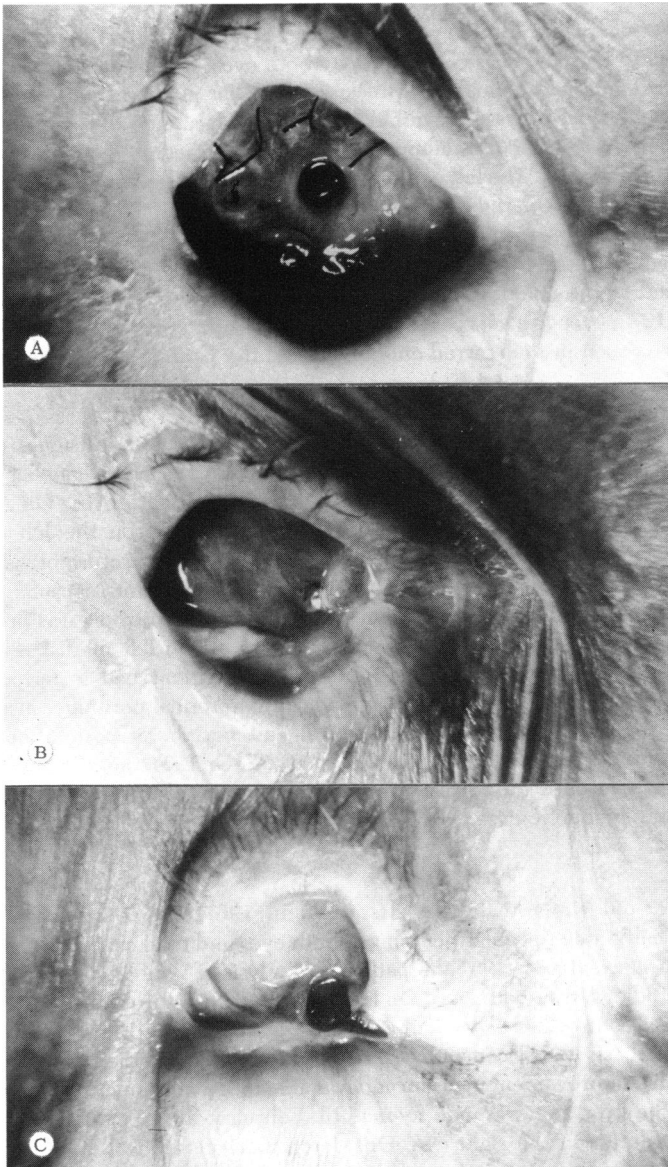


FIGURE 9

A: A 77 year old white female in 1965. Her first keratoprosthesis was performed in May of 1966. Patient at this time had light perception right eye, questionable light perception left eye. (Case 9). B: By September of 1966 the cul-de-sacs had closed in. This was repaired on a number of occasions. C: The eye after repair of the cul-de-sacs as it was seen in January of 1967.

CASE 9

A 77-year-old white female was first seen in 1965. She was aphakic and had glaucoma in both eyes, Fuchs' dystrophy both eyes, and ocular pemphigus both eyes. On January 18, 1966 a full thickness lamellar graft was performed on the right eye, as well as lysis of symblepharon with placement of scleral lens, both eyes. On May 27, 1966 a keratoprosthesis was performed on the right eye, which had light perception. The left eye had questionable light perception. A reinsertion of a Ridley lens on the right eye was done. On April 12, 1967 there was expulsion of the keratoprosthesis which was replaced on April 21, 1967. At least 14 attempts were made to reduce the symblepharon and enlarge the cul-de-sacs of the right eye including placement of a regular size silicone conformer. When last seen on June 7, 1972, over five years after replacement of keratoprosthesis, the prosthetic device was seen in the scarred cul-de-sac, and the patient had light perception.

CASE 10

A 70-year-old white female was examined in 1968. The initial diagnosis was far advanced corneal dystrophy both eyes. On December 20, 1968 a lamellar keratectomy with sodium versenate lavage was performed on both eyes. On April 18, 1969 an intracapsular cataract extraction was performed on the left eye and keratoprosthesis was implanted. The patient got immediate return of vision with light perception and projection. On April 29, 1969 an intracapsular cataract extraction was performed on the right eye. A large left exotropia was present. A tenotomy of the left lateral rectus and resection of the left medial rectus was performed on June 19, 1970. By July 31, 1973 patient had a periprosthetic necrosis left eye which was repaired with a circumferential peritomy, insertion of a silicone contact cover lens with central and peripheral perforation, and a conjunctival purse string. When last seen in March 1974 the vision was maintained left eye with the implant in place. Duration of the implant to date is approximately four years.

CASE 11

A 68-year-old white male was first seen in 1967. The diagnosis was total symblepharon due to ocular pemphigus both eyes and total corneal scarring both eyes. On December 5, 1967 the patient had a lysis of symblepharon with placement of Ridley lenses both eyes. On January 17, 1968 the procedure was repeated because of contraction of the cul-de-sacs. On August 13, 1968 a satellite type keratoprosthesis was placed with a stored corneal overlay on the right eye. Patient had notable improvement in vision and was able to see his dinner plate. However, he left the city and was not seen until February 29, 1969 when he had a panophthalmitis in the right eye. On March 2, 1969 removal of organized and purulent material was attempted with revision of the keratoprosthesis. There was marked organization of the vitreous. Vision went down to no light perception. By March 26, 1969 the eye was quiet. On January 8, 1970 the patient was lost to follow-up.

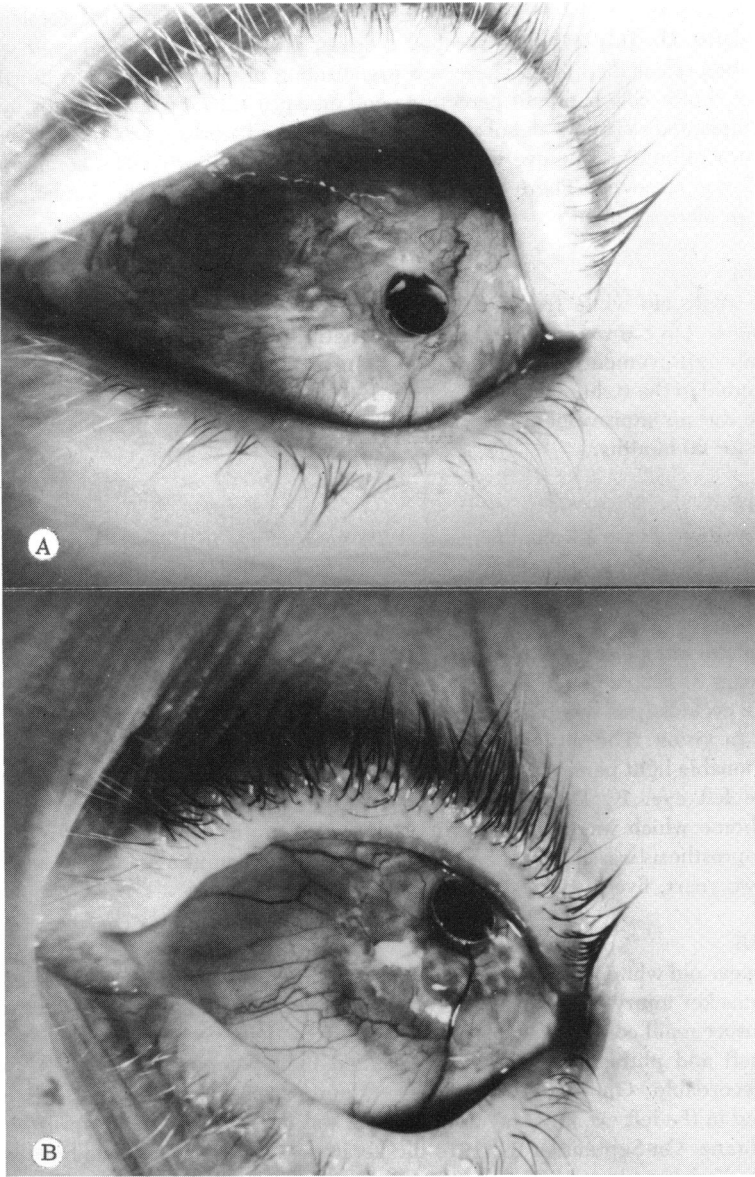


FIGURE 10

A: Case 10. A keratoprosthesis was performed on her left eye in June of 1969. As can be seen in the figure, the left eye turned up and out. She required a muscle procedure to bring the eye into position. B: The keratoprosthesis in place in June of 1970.

CASE 12

A six-month old black female was seen in 1952 with a diagnosis of retrolental fibroplasia. On July 24, 1964 she had a 6 mm full thickness corneal graft with extraction of calcified lens. There was organization of vitreous and questionable phthisis bulbi. She had light perception and on April 12, 1966 a keratoprosthesis was implanted. Vitreous detail was noted and marked scarring was seen through the corneal button. The eye was quiet until June 25, 1968 when the keratoprosthesis was removed. There was a postprosthetic membrane. The implant had been in place 26 months.

CASE 13

A six-weeks-old white female was seen in 1956 with a diagnosis of congenital glaucoma. On February 8, 1960 a 7 mm penetrating graft was performed. There was no improvement in function and on July 19, 1966 a keratoprosthesis was implanted in the right eye. On March 26, 1968 the keratoprosthesis was removed. There was no improvement in vision of this phthisical eye. The prosthesis was in place for 20 months.

CASE 14

The brother of case 13 was first seen at 2½ years of age in 1953 with congenital glaucoma both eyes. On January 30, 1953 he had an iridencleisis both eyes. On May 1, 1956 a penetrating corneal transplant was performed on the left eye with a iris prolapse by July 2, 1956. On January 7, 1959 an 8 mm penetrating corneal transplant was performed on the right eye with removal of calcified lens. On February 8, 1960 a penetrating graft was performed on the left eye. On July 24, 1962 a cyclodialysis was performed on the left eye. There had been no improvement in vision. The vision in the right eye was no light perception; left eye, questionable light perception. On July 19, 1966 a keratoprosthesis was implanted in the left eye. By December 19, 1967 there was a posterior postprosthetic membrane which was removed. He was followed until October 23, 1969. The keratoprosthesis was expelled by December 1968. The duration of the prosthesis was two years, five months.

CASE 15

A 54-year-old white male was seen in 1972. The right eye was anophthalmic from a firecracker injury and the left eye was perforated by a pen in the fourth grade. An unsuccessful corneal transplant was done on the left eye in 1970. The left eye was soft and phthisical. The patient claimed light perception. The ERG was non-recordable. On June 16, 1972 a keratoprosthesis (satellite type) was implanted in the left eye. By May 2, 1973 there was formation of the postprosthetic membrane. On September 29, 1973 the keratoprosthesis was in place but there was a discharge around the anterior segment. The patient was treated with Garamycin drops locally. He claimed subjective improvement in light perception postoperatively but this could not be proven. The duration of the implant was 15 months when he was lost to follow-up.

CASE 16

A 15-year-old white male was first seen in July 1969. The clinical diagnosis was sympathetic ophthalmia right eye, secondary to "B.B." injury left eye. The left eye had been removed. On September 15, 1969 a penetrating keratoplasty was performed on the left eye with removal of phthisical membrane and cataract. By July 8, 1970 the patient had a definite phthisical change in the left eye. However he claimed light perception. On July 14, 1970 a keratoprosthesis (satellite type) was implanted in the right eye. A retroprosthetic membrane had formed by August 21, 1970 which was removed. Two months later the patient claimed light perception. The eye was quiet and comfortable. The patient was lost to follow-up but apparently the prosthesis is in place to date almost four years later.

CASE 17

A six-week-old white female was seen in August 1952 with a clinical diagnosis of congenital cataracts and glaucoma both eyes. On August 8, 1952 a trephine was performed on the right eye and an iridectomy was performed on the left eye. On August 19, 1952 a conjunctival flap was placed on the right eye. The right eye developed phthisis bulbi. On May 24, 1955 a calcified lens was removed from the left eye with removal of post lenticular membrane. On July 10, 1956 removal of an epithelial cyst from the iris of the left eye was performed. On February 15, 1957 the patient had an iridencleisis of the left eye with freeing of adhesions and enlargement of the pupil. On November 7, 1958, a cyclodialysis of the left eye with separation of glial band was performed. There was no improvement in vision. On July 26, 1966 a keratoprosthesis was implanted. There was periprosthetic corneal necrosis noted postoperatively. On March 24, 1967 a stored scleral transplant with insertion of satellite type keratoprosthesis was performed with removal of postpupillary membrane. The pathologist's report indicated corneal scar, anterior synechia, and squamous epithelial inclusions which might be a residual of the July 10, 1956 procedure. She was noted to have eccentric fixation, definite light perception, and a recordable ERG in February 1973. On April 24, 1973 a satellite type keratoprosthesis was replaced and when last seen on December 27, 1973 she had a normal tension, clear media, and central fixation with color perception. Duration of the implant with two replacements was six years, five months.

CASE 18

A ten-week-old white male was seen in November 1950. The diagnosis was congenital glaucoma both eyes with buphthalmos. On November 15, 1950 a trephine operation with complete iridectomy was performed on both eyes. On January 5, 1951, the trephine operation was repeated on both eyes. On July 26, 1966 a keratoprosthesis was performed on the left eye. On December 16, 1966 an excision of an epithelial overgrowth of the prosthesis left eye was done. When last seen on April 18, 1974 the prosthesis was in place behind a reformation of epithelial overgrowth. The duration of the implant was six years, nine months.

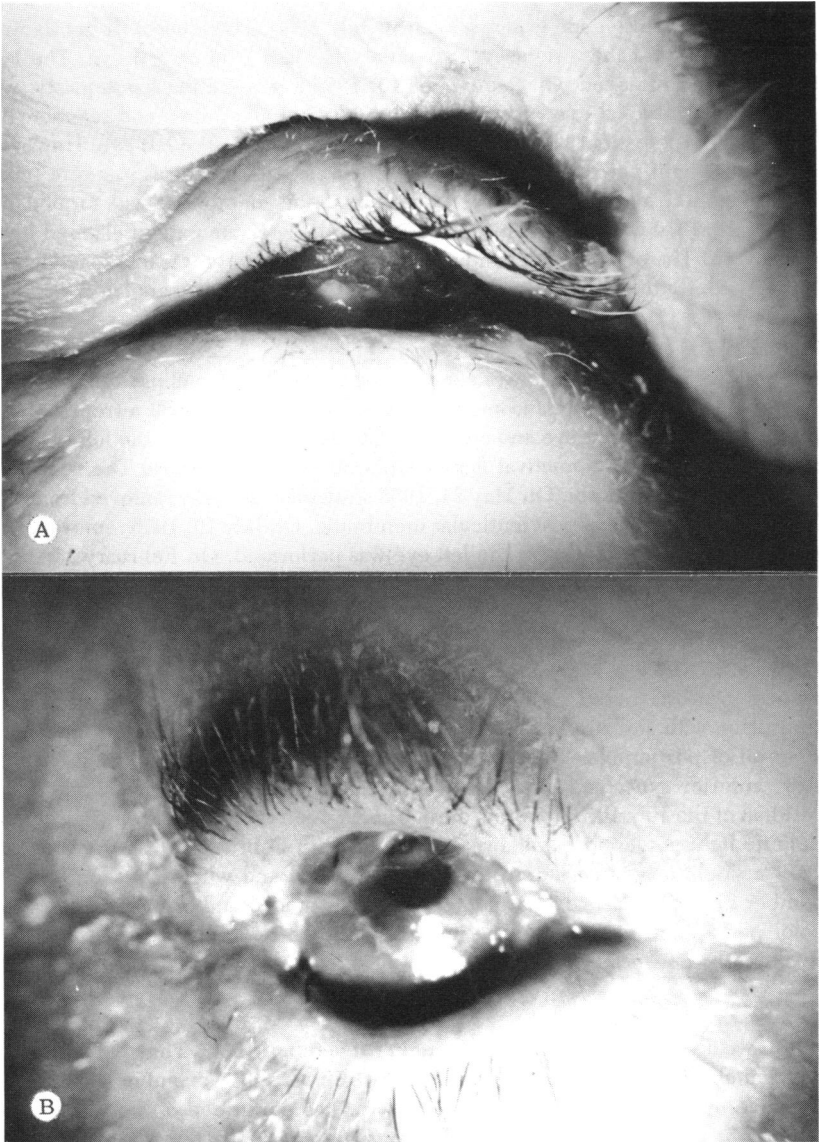


FIGURE 11

A: Case 11. The preoperative photograph of the left eye. B: The position of the keratopros-thesis with a super imposed stored corneal overlay.

CASE 19

A 53-year-old black female was seen in August 1968. The clinical diagnosis was lye burns, total symblepharon, and secondary ocular pemphigus both eyes. She had multiple previous ocular procedures for repair of cul-de-sacs, two keratoplastys both eyes, and cataract extractions, both eyes. On January 4, 1969 a satellite type keratoprosthesis was placed in the right eye. The development of pupillary membrane was noted on June 17, 1969, was removed and recurred again by May 12, 1970. On December 4, 1970 an 8.5 mm penetrating graft was performed on the left eye. On May 18, 1973 a keratoprosthesis was performed on the left eye and on July 31, 1973 the cul-de-sac was reformed with a full size lucite conformer. On October 30, 1973 lysis of adhesions both eyes and replacement silicone conformers was performed on both eyes and silicone anterior contact segments were placed on both eyes. On March 19, 1974 both keratoprostheses were in place and the silicone contact cover was over the left eye. The silicone conformers had been expulsed. The duration of the implant in the right eye was three years, three months; left eye ten months.

CASE 20

A 47-year-old white male was seen in 1961. The left eye had been removed in 1932. On June 8, 1962 an 8 mm penetrating corneal transplant was performed on the right eye with cataract extraction. Postoperative course was uneventful, but the eye appeared to be phthisical. On August 15, 1967 a keratoprosthesis was placed in the right eye. The implant was expulsed on January 10, 1968 secondary to infection of the anterior ocular segment. The duration of the implant was five months.

CASE 21

A 58-year-old white male was first seen in 1968. He had had cataract surgery both eyes and had a retinal detachment in the right eye. On September 18, 1958 a scleral buckling procedure was done on the right eye. On April 10, 1962 a total scleral buckle with silicone tubing was done. On December 4, 1962 a 7 mm lamellar corneal transplant was done on the left eye. On September 28, 1965 a 6 mm penetrating corneal graft was done on the left eye. An anterior chamber hyphema occurred on October 12, 1965, requiring irrigation and air injection. On January 3, 1969 the patient had a placement of a satellite type keratoprosthesis left eye with removal of fibrotic membrane anterior chamber. By May 21, 1969 the membrane had reformed and by August 20, 1969 the implant was extruded. The duration of the implant was seven months.

CASE 22

A 5½-year-old white female was first seen in 1958 with a diagnosis of congenital glaucoma (buphthalmos) both eyes. On July 14, 1959, a 7 mm penetrating graft was done on the left eye. On November 27, 1959, a 1.5 mm trephine was performed left eye. On June 23, 1961, a 8 mm penetrating graft was done on the left eye. On July 12, 1966 a small type keratoprosthesis was placed in the right eye

with removal of anterior chamber fibrotic membrane. On August 2, 1966 a conjunctival flap was placed. On September 2, 1966 a 6 mm full thickness graft was placed over the implant with replacement of conjunctival flap on September 13, 1966. On November 20, 1966 the implant was expulsed. The duration of the implant was five months.

CASE 23

A 3-year-old black female was first seen in 1963 with a diagnosis of bilateral uveitis and secondary cataracts both eyes. On June 30, 1964 a cataract extraction was performed on the left eye. On August 20, 1966 a discission was done on the left eye. In December 1966 the left eye became phthisical. On February 17, 1967 a full thickness corneal transplant with keratoprosthesis was placed in the right eye. On September 9, 1968 the eye was quiet, the prosthesis was in place, and the eye had light perception. The duration of the implant was 1 year, seven months.

CASE 24

A 14-year-old white female was seen in 1961 with diagnoses of Stevens-Johnson disease, total symblepharon both eyes, and corneal scarring both eyes. Vision in the right eye was 5/200 and in the left eye was light perception. On July 25, 1961 lysis of total symblepharon was done with molding and placement of Ridley lenses both eyes. Cul-de-sacs were completely reformed with some return of tearing in the right eye. On January 10, 1962 a lamellar keratotomy was performed on the left eye with replacement of Ridley lens. She returned to her home where her local ophthalmologist changed the Ridley lenses to small lenses. The left eye developed a central corneal ulcer with perforation. On February 21, 1962 a 7 mm penetrating keratoplasty was performed on the left eye. The graft was replaced on July 13, 1962 with an 11 mm full thickness penetrating keratoplasty. On September 2, 1962 the patient developed an endophthalmitis in the left eye, which resolved on chemotherapy. On June 11, 1964 she had an 8 mm full thickness keratoplasty on the left eye. On May 7, 1968 following a recurrent corneal perforation, a keratoprosthesis was placed in the left eye. Endophthalmitis recurred within five months and the eye was enucleated. The right eye has retained reading vision of 20/40. The duration of the implant was five months.

CASE 25

A 52-year-old white male was seen in 1961 with a clinical diagnosis of lye burns of both eyes, partial symblepharon both eyes, cicatricial entropion upper and lower lids both eyes, and severe diabetes. He had undergone corneal transplantation both eyes. On February 21, 1962 a 7 mm penetrating keratoplasty was performed on the left eye with removal of fibrous scar from the anterior chamber. On November 31, 1962 a corneal ulcer required antibiotic therapy and there was secondary clouding of the cornea. On March 22, 1963 a 6 mm penetrating keratoplasty was performed on the left eye. On January 31, 1967 a keratoprosthesis was performed on the left eye. Secondary infection was noted on February 18, 1967 with reformation of the posterior prosthetic membrane. By April 18,

1967 it was necessary to repair the cicatricial entropion of both upper lids with Hotz-Anagnostakis procedures both eyes. One week later a postprosthetic membrane was removed and although the patient had light perception there was definite organization of the vitreous and a fibrous membrane was noted. On July 14, 1967 the keratoprosthesis was removed due to secondary infection. The duration of the implant was six months.

CASE 26

An 18-month-old white male was seen in 1956 with a diagnosis of retrolental fibroplasia. On November 12, 1957 an intraocular membrane and the lens was removed from the left eye. On June 26, 1962, an intracapsular cataract extraction was performed on the right eye. On October 23, 1962 a pupillary membrane was removed from the right eye. On July 29, 1969 a discission was done on the left eye and on July 20, 1971. On June 22, 1973 a satellite type keratoprosthesis was placed with removal of organized vitreous. A silicone corneal cover lens was sewn over the keratoprosthesis with 10-0 ethilon sutures. The patient had retained his habit of rubbing his eyes and by December 4, 1973 a panophthalmitis required chemotherapy. The keratoprosthesis was expelled by January 6, 1974. It was replaced with little hope of survival. The patient was lost to follow-up. The duration of the implant was six months.

CASE 27

A 45-year-old black male with surgical anophthalmos left eye was seen in 1973. He had corneal scarring, secondary glaucoma, operative aphakia, and two prior penetrating keratoplastys on the right eye. The ERG was recordable in the right eye. On December 11, 1973 a keratoprosthesis (satellite type) was implanted. On April 19, 1974 the prosthesis was in place. The tactile tension was soft. Vision was light perception and moving shadows. The duration of the implant is four months to date.

CONCLUSIONS

A cast, medical grade, optical-silicone keratoprosthesis has been described. Its use in certain operative conditions has been noted. Certain conclusions may be considered.

1. Monkey. The procedure in the stump tail monkey was technically uncomplicated, however, the duration of the retention of the implant was not more than six months. In every instance the extrusion of the implant was caused by a retroprosthetic membrane. This membrane was formed from posterior corneal tissues which grew across the back of the implant and forced the implant out. Usually the chamber was not lost. There was no problem with infection.

2. Rabbit. The anterior chamber procedure was again technically uncomplicated. The laboratory conditions were such that maintenance of a clean cul-de-sac was very difficult. An implant in place for a year was considered adequate. The same procedure was utilized in the human.

3. Human. This is a small but carefully controlled series. Only a few of the 27 patients could be considered to have real potential for vision. These patients did well until some untoward circumstance took place — a vitreous hemorrhage, a retinal detachment, panophthalmitis, etc. Following such complications there was development of a retroprosthetic membrane. Besides the basic complications of a severely traumatized eye, the development of a retroprosthetic membrane and periprosthetic necrosis are the two prime complications following the implantation of a keratoprosthesis.

The possibility of faulty design must be considered. One must also consider the possibility of a chronically irritated anterior ocular segment. The fact that one patient (Case 1) could be operated upon twice with resultant functional vision to date, indicates that repeated keratoplasty with newer techniques should be considered.

Those patients which did attain some kind of visual function, for however short a period, required careful medical control. A number of them attained visual function satisfactory to their needs. It should be noted that those patients that had total symblepharon required constant supervision as to the maintenance of their cul-de-sacs. A large number of patients in this series had a cyclitic or fibrotic membrane in the anterior chamber. It would appear that the recurrence of this membrane is not prohibited but may be delayed by the particular prosthetic device presented.

With due consideration to all the problems relating to the patient with significant disease of the anterior ocular segment and cul-de-sac, as well as the constant medical and surgical supervision required, a properly designed and maintained keratoprosthesis device may be considered as a possible method of treatment.

REFERENCES

1. Baker, AR: "Some Remarks On Transplantation Of The Cornea And Allied Subjects." *Am J Ophthalmol* 10:1-10, 1889.

DISCUSSION

DR R. TOWNLEY PATON. Due to unforeseen circumstances I am sorry to miss the privilege of giving a formal discussion of Dr Ruedemann's paper on Keratoprosthesis. Although I have not read his paper I had some personal correspondence with him and saw some of the photographs demonstrating his technique.

He has entered into a field of eye surgery in which there does not appear to be any general agreement as to the best technique to be used. However, there is universal agreement that a keratoprosthesis is to be used in only those cases where a keratoplasty is not indicated and is not to be used as a primary procedure. Those who have been pioneers in this field have devised many interesting variations depending on the type of eye to be operated upon. A very excellent review of some of these techniques is given by Dr Dhanda and Dr Kalevar. I shall show you some pictures taken from their book on corneal surgery.

First let me show you the various methods used by Dr Stone. [slide] Keratoprosthesis designed by Stone. (A) Anterior and posterior projection implants. (B) (i) Anterior implant with insert in place (ii) Anterior implant with posterior trephine window. (iii) Anterior implant with through-and-through insert. (C) (i) Posterior implant with insert in place. (ii) Posterior implant and insert covered with a lamellar graft. (iii) Posterior implant with through-and-through insert.

Collar-button prosthesis of Dohlman [slide].

Cardona through-and-through prosthesis. (A) Measurements. (B) Skirt with fenestrations and pigment-embedded cylinder. [slide]

One of the most dramatic techniques is the Strampelli-Orteo keratoprosthesis in which a disc is taken from a tooth of the patient and an acrylic implant embedded in the center. The combined implant is then transplanted on to the recipient cornea. The theory being that the skirt of the implant is made of autogenous tissue and is, therefore, better tolerated by the host. Strampelli claims excellent results in highly vascularized corneas.

In surveying the literature there has been a steady improvement in the length of time that patients have maintained good vision, but eventually all implants are extruded. In some instances reoperation has been successful, but many eyes have eventually been lost.

It is hoped that Dr Ruedemann, as the results of his experiments and the development of a new type of implant, has further advanced our knowledge on the subject.

DR WILLIAM C. FRAYER. I would like to ask Dr Ruedemann about the expected refractive error in these patients. Secondly, do they have a significant visual field through the prosthesis.

DR ALBERT D. RUEDEMANN, JR. Thank you, Dr Frayer, for your kind assistance in reading Dr Paton's discussion.

In terms of the refractive power, each one of these models was made from a mold of the anterior segment of the eye of the animal or human involved. We used a standard anterior curve on the human and then put a power of about +12 in this, and the refractive errors were remarkably small. I can think in terms of two diopters a cylinder to 20/20, or J-1. The gentleman from General Motors had to wear a telescope-type thing to get J-1, but he did maintain his vision.

I want to make several points here. One is about the histopathology. I couldn't send Dr Paton the histopathology on the animals which I had in a box because I couldn't find the box, and I still haven't found the box. We have moved our laboratory three times, and I just couldn't tell him because I didn't have them.

The retroprosthetic membranes were obviously corneal in origin, and in the human cases where we have taken the retroprosthetic membrane out (and this is our biggest problem, this membrane and periprosthetic necrosis) the retroprosthetic membrane has always been made up of posterior corneal elements, and they literally push the implant out eventually. We never lose aqueous.

There is no question that there will be newer methods and newer materials for keratoprosthesis devices, but we must also remember that we have newer techniques for keratoplasty. I pointed out in case 1 that we went back to the original eye some ten years after keratoplasty (three times) with a cataract extraction and reoperated, the only variant in our technique being a 10-0 suture. One year postoperative he has 20/30 +3. So, we can't forget the keratoplasty.

Thank you very much.