

OCULAR MANIFESTATIONS OF HIV INFECTION

BY *Douglas A. Jabs, MD*

FOOTNOTES TO TITLE PAGE:

From the Ocular Immunology Service, The Wilmer Institute, Department of Ophthalmology, The Johns Hopkins University School of Medicine.

ABSTRACT

Objective: To evaluate the frequency of ocular complications and the clinical outcomes of these complications in patients with various stages of HIV infection.

Methods: Retrospective review of all HIV-infected patients seen in an AIDS ophthalmology clinic from November 1983 through December 31, 1992.

Results: Eleven-hundred sixty-three patients were seen for ophthalmologic evaluation. Of these, 781 had the acquired immune deficiency syndrome (AIDS), 226 had symptomatic HIV infection (AIDS-related complex [ARC]), and 156 had asymptomatic HIV infection. Non-infectious HIV retinopathy was the most common ocular complication, affecting 50% of the patients with AIDS, 34% of the patients with ARC, and 3% of the patients with asymptomatic HIV infection. Cytomegalovirus (CMV) retinitis was the most common opportunistic ocular infection, affecting 37% of the patients with AIDS. Other opportunistic ocular infections, including ocular toxoplasmosis, varicella zoster virus retinitis, and *Pneumocystis* choroidopathy were all much less common, each occurring in $\leq 1\%$ of the patients with AIDS. Treatment of CMV retinitis with either foscarnet or ganciclovir was successful in initially controlling the retinitis. However, relapse represented a significant problem and required frequent re-inductions. As a consequence of the retinal damage associated with relapse, loss of visual acuity occurred. The median time to a visual acuity of 20/200 or worse for all eyes with CMV retinitis was 13.4 months, and the median time to a visual acuity of 20/200 or worse in the better eye was 21.1 months. At last follow-up, 75% of the patients had a final visual acuity of 20/40 or better in at least one eye. Retinal detachments were a frequent ophthalmologic complication of CMV retinitis with a cumulative probability of a retinal detachment in at least one eye of 57% at 12 months after the diagnosis of CMV retinitis. Herpes zoster ophthalmicus developed in 3% of the overall series and was seen in all stages of HIV infec-

tion. Fifty-six percent of the cases of ocular toxoplasmosis had simultaneous toxoplasmic cerebritis. Ocular toxoplasmosis responded to standard anti-microbial therapy. Varicella zoster virus retinitis, when manifested by the acute retinal necrosis (ARN) syndrome, responded to intravenous acyclovir therapy. Conversely, in a limited number of patients with the progressive outer retinal necrosis syndrome, the disease responded poorly to intravenous acyclovir therapy, but appeared to respond to combination foscarnet and acyclovir therapy. Neuro-ophthalmic lesions were present in 6% of the patients with AIDS. The most common cause of a neuro-ophthalmic lesion was cryptococcal meningitis, and 25% of the patients with cryptococcal meningitis developed a neuro-ophthalmic complication.

Conclusions: Ocular manifestations are common in patients with AIDS. CMV retinitis represented a major vision-threatening problem in these patients. While available therapy was successful in initially controlling the retinitis, the phenomenon of relapse resulted in some degree of long-term visual loss. Preservation of the patient's visual acuity in at least one eye was generally successful. Other opportunistic ocular infections were substantially less common than CMV retinitis but require aggressive therapy.

INTRODUCTION

Since the original description of the acquired immunodeficiency syndrome (AIDS) as a new disease characterized by opportunistic infections and unusual neoplasms in young adults in 1981,^{1,2} AIDS has become a worldwide epidemic. In 1992, 47,095 new cases of AIDS were reported to the Centers for Disease Control and Prevention (CDC), for a total of 253,448 reported cases in the United States.³ While the rate of rise of new cases has slowed over time, the number of new cases each year still continues to increase, and in 1992, there were 3.5% more new cases than in 1991. It is estimated that at least 1,000,000 people in the United States are infected with the human immunodeficiency virus (HIV).⁴ Available data suggest that virtually all of these people will ultimately develop AIDS, with a median time from acquisition of HIV infection to AIDS of 11 years.⁵

The initial cases were largely confined to homosexual or bisexual men and intravenous drug users. Smaller numbers of cases were due to transmission of HIV infection through blood transfusions prior to screening of the blood supply for HIV and to transmission to hemophiliacs via intravenously administered clotting factors prior to the initiation of a screening system. While the largest number of cases remains among homosexual or bisexual men, an increasing number of cases are due to heterosexual transmission and among minority groups. Hence, the relative proportion of cases among homosexual or bisexual men continues to decrease.³

Since the original description of ocular changes in the fundi of patients with AIDS by Holland and associates⁶, it has become evident that the eyes

are involved in the majority of patients with AIDS. The most common ocular finding is a noninfectious occlusive microangiopathy known as "HIV retinopathy" (also called "AIDS retinopathy" or "noninfectious HIV retinopathy").⁷⁻¹⁶ HIV retinopathy is characterized primarily by cotton-wool spots but is also associated with intraretinal hemorrhages. Somewhat less frequent than HIV retinopathy, but visually more significant, are opportunistic ocular infections, particularly cytomegalovirus (CMV) retinitis.⁷⁻²¹ With the advent of the AIDS epidemic, CMV retinitis has gone from being a rare disease in the United States to arguably the most common intraocular infection. Other opportunistic ocular infections seen in patients with AIDS include retinitis caused by either the varicella zoster virus^{15,22-27} or *Toxoplasma gondii*^{15,28-31} and chorioidopathy caused by *Pneumocystis carinii*.³²⁻³⁷ Unusual neoplasms, such as lid or conjunctival involvement by Kaposi's sarcoma³⁸⁻⁴¹ and ocular or orbital involvement by high-grade lymphomas, may also occur.^{15,42,43} Finally, a variety of neuro-ophthalmic lesions have been described in patients with HIV infection.^{15,44-50}

While a variety of cell types may be infected by HIV, the immunologic hallmark of HIV infection is the selective loss of the CD4+ T cell. CD4 is a cell surface marker that identifies the helper/inducer subset of T cells. Helper T cells are responsible for delayed type hypersensitivity and augmentation of the immune response, including the induction of B cells to make antibody and the induction of resting cytotoxic T cells to activated cytotoxic T cells. AIDS represents only the last stage of HIV infection. Currently, the majority of patients infected with HIV are asymptomatic. Once the CD4+ T cell count has fallen sufficiently (generally, < 500 cells/ μ L) that the immune system shows some evidence of impairment, patients begin to develop symptoms, such as thrush. Early in the AIDS epidemic, patients with these symptoms but without fully developed AIDS were classified as having the AIDS-related complex (ARC). AIDS occurs when the immune system is sufficiently impaired that the patient develops opportunistic infections or unusual neoplasms (generally, CD4+ T cells < 200 cells/ μ L). The CDC has modified the definition of AIDS twice to accommodate an expanding knowledge base about HIV and AIDS. The initial surveillance case definition of AIDS was modified in 1987 to include information concerning HIV antibody testing⁵¹ and again in 1993 as a consequence of changes in the clinical presentation of the disease due in part to the successful use of primary prophylaxis for *Pneumocystis carinii* pneumonia, and due to the increased clinical use of CD4+ T cell counts.⁵²

In this thesis, we present the information concerning 1,163 patients with HIV infection seen in an AIDS ophthalmology clinic at an urban academic medical center over a period of 9 years.

PATIENTS AND METHODS

Study Population

The first patient in this series was seen in November 1983. In 1984, the Ocular Immunology Service began operation and subsequently established the AIDS Ophthalmology Clinic. Patients included in this study were seen between November 23, 1983, and December 31, 1992. The December 31, 1992, date was chosen to coincide with the change in the surveillance case definition of AIDS by the CDC.⁵²

Classification of HIV Infection

All patients were classified as having AIDS according to the 1987 CDC revised surveillance case definition of AIDS.⁵¹ Patients with evidence of HIV infection but without symptoms were classified as having asymptomatic HIV infection. Patients having some symptoms, such as thrush, fever, weight loss, or herpes zoster, were classified as having symptomatic HIV infection, and for the purposes of this study, were termed as having ARC. The requirement that an individual have at least two HIV-related symptoms in order to be classified as having ARC, which is used in some studies, was not used here. The term "ARC" used in this study is largely comparable to the current CDC class B (symptomatic HIV infection).⁵² Similarly, patients classified as having AIDS in this study are largely comparable to the current CDC class C (opportunistic infections or unusual neoplasms),⁵² and patients classified as having asymptomatic HIV infection are similar to the current CDC class A.⁵²

Diagnosis of Ocular Lesions

HIV retinopathy (Fig 1) was diagnosed when the patient presented with either cotton-wool spots or intraretinal hemorrhages. CMV retinitis (Fig 2) was diagnosed by the characteristic picture of a necrotizing retinitis with either edematous white borders or granular white borders and with or without hemorrhage.^{17,53} Ocular toxoplasmosis (Fig 3) was diagnosed on the basis of the characteristic clinical picture of a focal yellow-white necrotizing retinitis with fluffy borders and no or few scattered intraretinal hemorrhages.³⁰ Ocular toxoplasmosis was usually accompanied by an overlying vitritis, but the finding was not necessary for the diagnosis. Inactive lesions (toxoplasmic scars) consisted of focal atrophic choroid and retina with retinal pigment epithelial clumping. Presumed varicella zoster virus (VZV) retinitis (Fig 4) was diagnosed when a patient presented with a clinical picture resembling either the acute retinal necrosis (ARN) syndrome or progressive outer retinal necrosis syndrome. The ARN syndrome was diagnosed when a confluent, full-thickness, largely peripheral, yellow necrotizing retinitis with little or minimal hemorrhage was seen, with or without an overlying vitritis.^{27,54} The progressive outer retinal necrosis syndrome (Fig

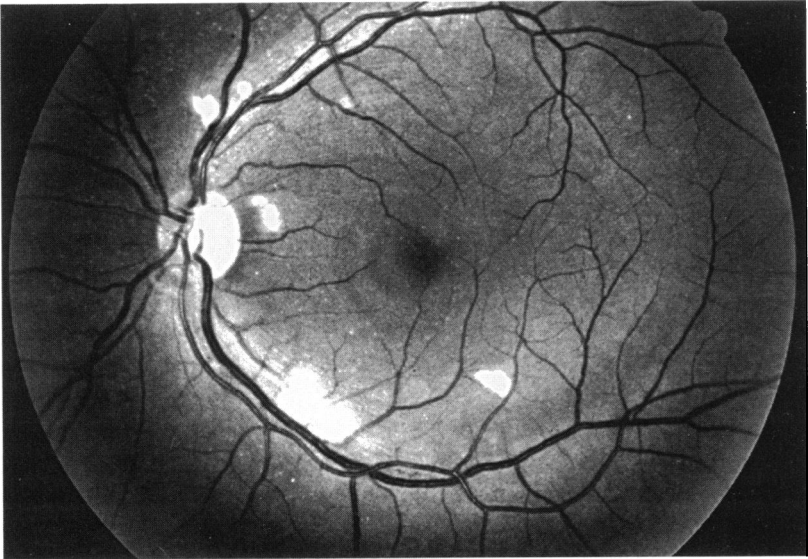
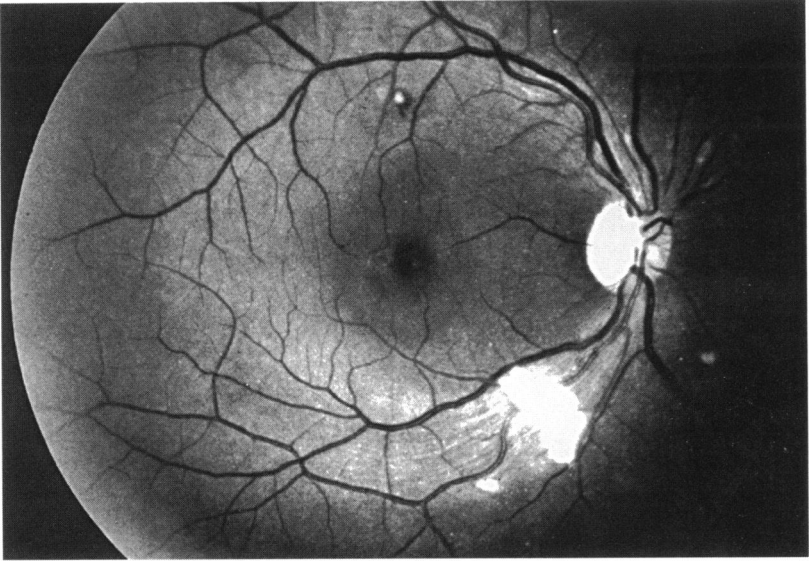
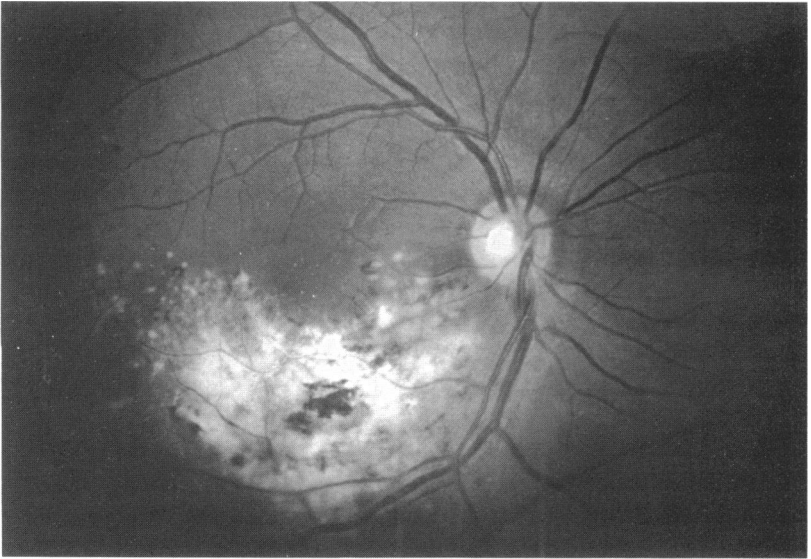
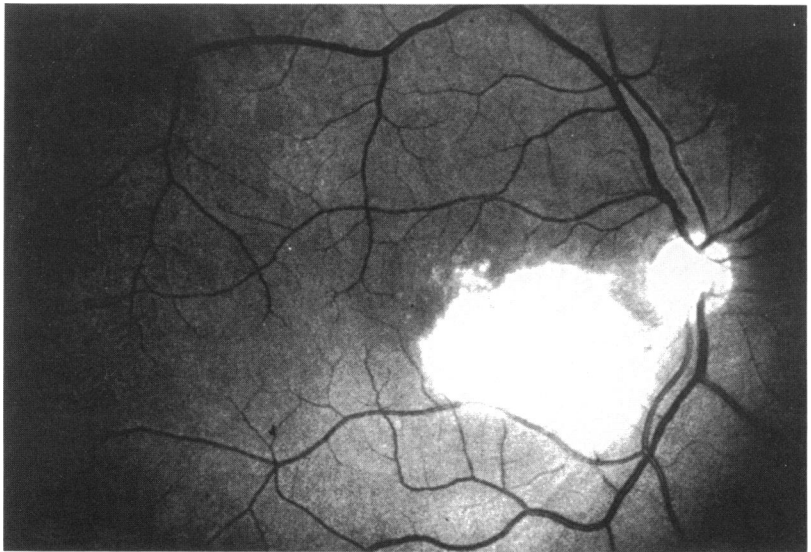


FIGURE 1

Cotton-wool spots in both right (A) and left (B) eyes of patient with AIDS and HIV retinopathy.

**FIGURE 2**

Cytomegalovirus retinitis in patient with AIDS.

**FIGURE 3**

Toxoplasmic retinitis in patient with AIDS. Diagnosis was subsequently confirmed at autopsy.

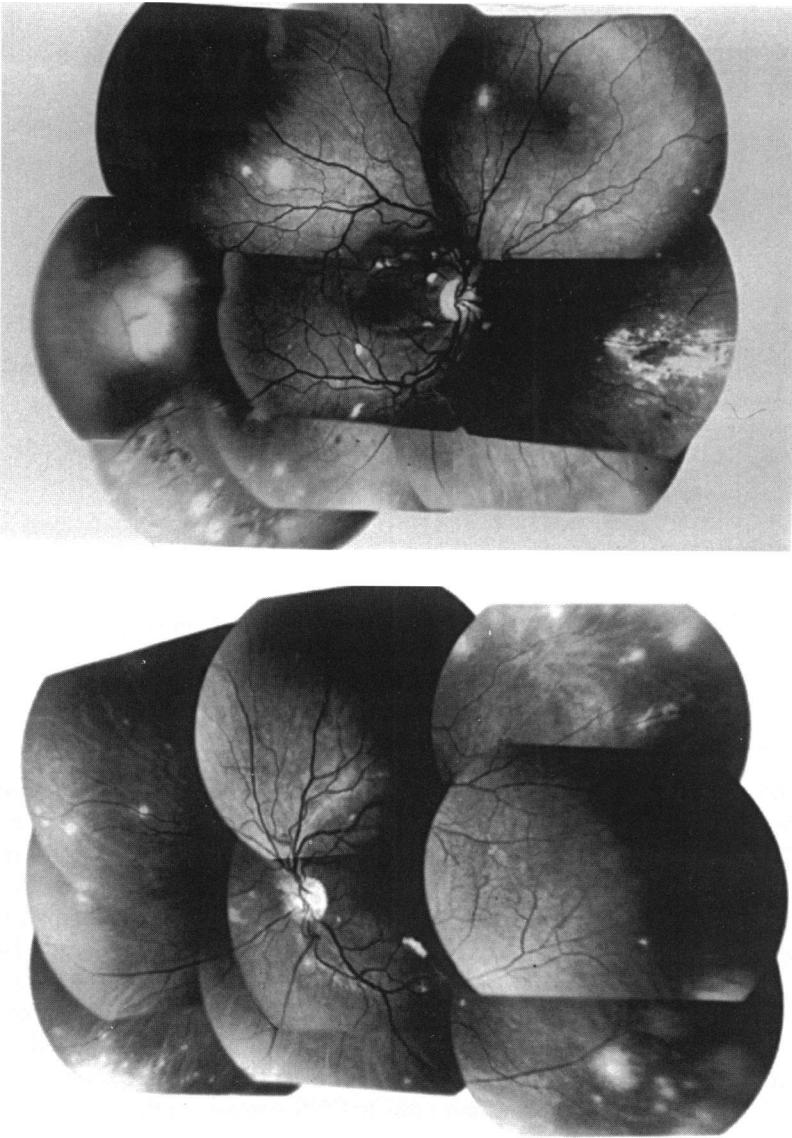


FIGURE 4

Right eye (A) and left eye (B) of patient with varicella zoster virus (VZV) retinitis and cytomegalovirus (CMV) retinitis. Early VZV retinitis is present in periphery of both eyes and has characteristic involvement of outer retina. CMV retinitis is present in nasal periphery of right eye and has characteristic full-thickness retinitis with hemorrhage. Patient also had concurrent herpes zoster ophthalmicus.

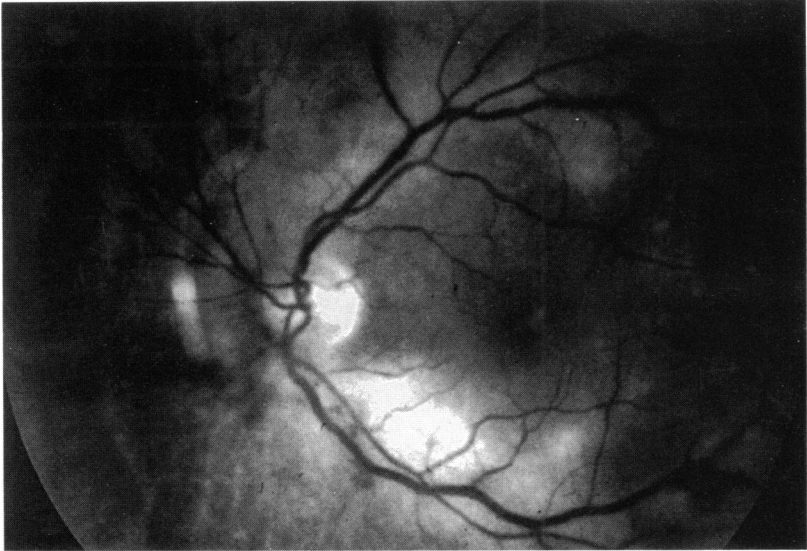


FIGURE 5

Early posterior pole involvement by varicella zoster retinitis in patient with AIDS and progressive outer retinal necrosis syndrome.

5) was diagnosed when a multifocal, rapidly progressive, outer retinal, yellow necrotizing retinitis with early posterior pole involvement was seen.²⁷ *Pneumocystis carinii* choroidopathy (Fig 6) was diagnosed by the characteristic clinical picture of a deep, yellowish-orange, multifocal choroidopathy.^{32,35} In cases where diagnostic uncertainty existed, the response to therapy generally confirmed the proper diagnosis. Syphilitic uveitis was diagnosed when a patient presented with evidence of intraocular inflammation, a positive fluorescent treponemal antibody absorption (FTA-ABS) test, and a response to antibiotic therapy (penicillin). Neuro-ophthalmic lesions included cranial nerve palsies, visual field deficits due to central nervous system (CNS) lesions, and optic nerve problems due to CNS disease. In this study, extension of CMV retinitis into the optic nerve was not classified as a neuro-ophthalmic lesion.

Characterization of CMV Retinitis

CMV lesions were characterized both by their location and by the extent of disease. The retina was divided into three zones as originally described by Holland and associates.⁵⁵ Zone 1 consisted of an area 3,000 μ from the center of the fovea and 1,500 μ from the edge of the optic disc. This area was judged to be approximately 2 disc diameters from the center of the

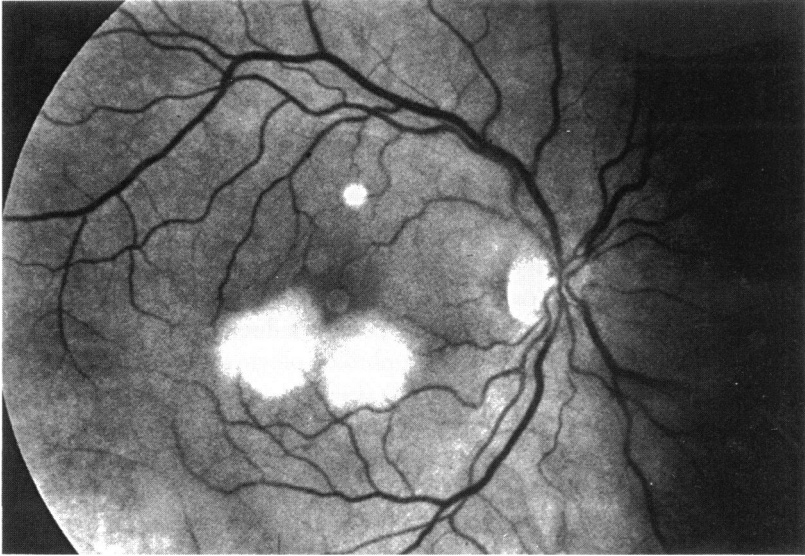


FIGURE 6

Pneumocystis carinii choroidopathy in patient with AIDS. Diagnosis was subsequently confirmed at autopsy.

fovea and 1 disc diameter from the edge of the optic disc, using the conventional estimate of the optic disc as being 1,500 μ in diameter, and corresponds to the posterior pole. Zone 2 extended from the edge of zone 1 approximately to the equator as defined by a circumference marked by the four vortex veins. Zone 3 extended anteriorly from the edge of zone 2 to the pars plana. Lesions were also characterized as to their size into four categories: (1) less than 10% of the retinal area in size, (2) 10% to 24%, (3) 25% to 49%, and (4) \geq 50% of the retinal area in size. The term "small peripheral lesion" was used for a lesion in zone 2 and/or zone 3 (ie, not involving zone 1) and less than 25% of the retinal area in size. While this term might be considered somewhat misleading because such lesions may be neither particularly peripheral nor particularly small, it has now come into widespread use for clinical trials concerning CMV retinitis.⁵⁶

Treatment of CMV Retinitis

CMV retinitis treatment was initiated with either ganciclovir or foscarnet, as determined by clinical judgment. The induction dose of ganciclovir (Cytovene) was 5 mg/kg given intravenously (IV) twice daily and adjusted for renal function, and the maintenance dose was 5 mg/kg IV given once daily. The foscarnet (Foscavir) induction dose was 60 mg/kg IV every 8

hours, and the maintenance dose was 90 mg/kg to 120 mg/kg once daily. Generally, the approach was to use 90 mg/kg once daily initially as the maintenance dose and to increase it to 120 mg/kg once daily after the first relapse. Foscarnet dosing was adjusted for renal function using previously published nomograms.⁵⁶ Only ganciclovir was available from 1984 until December 1988, while both foscarnet and ganciclovir were available after that date. Forty-five patients participated in the Studies of Ocular Complications of AIDS Foscarnet-Ganciclovir Cytomegalovirus Retinitis Trial, in which the treatment assignment was randomized between ganciclovir and foscarnet.⁵⁶⁻⁵⁸ The duration of induction therapy was 2 weeks, except for 13 patients treated prior to 1988, when a 3-week induction period was used.

Patients were generally seen for ophthalmologic evaluation 2 weeks after the initiation of therapy, 1 month after the initiation of therapy, and monthly thereafter. Patients who relapsed were again seen 2 weeks after the initiation of reinduction therapy, and 1 month after the initiation of reinduction therapy, and then resumed monthly ophthalmologic follow-up. All relapses were treated with 2 weeks of reinduction, followed by maintenance, generally with the same drug. Once both drugs were available, frequent relapses (two relapses within a 10-week period despite two consecutive induction and maintenance cycles) were treated by changing to the alternate drug. Changes in anti-CMV therapy also occurred for persistent or recurrent toxicity. Because of the duration of elevated creatinine levels in patients treated with foscarnet who had a creatinine level over 2.9 mg/dL, most patients with this toxicity were switched to ganciclovir, at least temporarily.

A remission was defined when the borders of the retinitis lesion were completely quiet to clinical examination and the size of the lesion was felt to have stabilized (nonenlarging). Relapse (breakthrough) of the retinitis was diagnosed when a previously quiet lesion (remission) developed newly active borders. Progression of the retinitis was diagnosed when there was a movement of the border of a lesion a minimum of 750- μ in either eye along at least a 750- μ front, or the development of a new lesion at least one-quarter disc area in size.⁵⁶ Because the development of newly active borders in a previously quiet eye indicates infection of new retina and, therefore, movement of the borders, the terms "relapse" and "progression" were generally synonymous. Prior to 1988, relapse was generally used without regard to a specific distance, while after January 1989, progression was generally used for treatment decisions.

Statistics

Groups of patients were compared using the chi-square test for independence for categorical variables and T tests for continuous variables. For comparisons among three groups, Kruskal-Wallis nonparametric analysis of variance was used. Kaplan-Meier life tables were computed and compared

by the log-rank test. For risk factor analyses, relative odds ratios and 95% confidence intervals were computed.⁵⁹

For the comparison among groups of risk factors, the hierarchical classification of risk group was used. For all analyses except central venous catheter complication, patients having both the risk factors of homosexuality and/or bisexuality and intravenous drug use were classified in the homosexual and/or bisexual group. Because any intravenous drug use was considered a potential risk factor for line complication, for this analysis patients with both risk factors were classified as being in the intravenous drug use group.

RESULTS

Demographics

From November 23, 1983, to December 31, 1992, 1,163 patients with HIV infection were seen. Of these, 781 (67%) had AIDS, 226 (19.5%) had ARC, and 156 (13.5%) had asymptomatic HIV infection. The greater number of patients with AIDS than with earlier stages of HIV infection reflects the referral bias of the clinic and the propensity for opportunistic ocular infections to occur at later stages of HIV disease.

The mean age of patients with AIDS was 37 years; with ARC, 38 years; and with asymptomatic HIV infection, 37 years (Table I). The age distributions were similar among the three groups, with the largest number of patients in the 20- to 39-year-old age-group. At least 90% of each group was in the 20- to 60-year-old bracket, and very few patients were present at either extreme of age. Fifty percent of the patients with AIDS were white; 49% were black, and 1% were Hispanic. Of the patients with ARC, 42% were white, 57% were black, and 1% were Hispanic or other race. Of the patients with asymptomatic HIV infection, 31% were white, 67% were black, and 2% were Hispanic. Of the patients with AIDS, 88% were men and 12% were women; of the patients with ARC, 84% were men and 16% were women; and of the patients with asymptomatic HIV infection, 73% were men and 27% were women. Among patients with AIDS, 62% were homosexual or bisexual men, and 21% had only a history of intravenous drug use. Among patients classified as having ARC, 48% were homosexual or bisexual men, and 28% had only a history of intravenous drug use. Among patients with asymptomatic HIV infection, 36% were homosexual or bisexual men, and 33% had only a history of intravenous drug use. The percent of patients having heterosexual transmission as a risk factor was 7% among those with AIDS, 13% among those with ARC, and 18% among those with asymptomatic HIV. These changes in race, sex, and risk group, were all statistically significant (Table II, $P \leq .001$).

TABLE I: DEMOGRAPHICS OF STUDY POPULATION

	AIDS	ARC	HIV
No. of patients	781	226	156
Age (yr)			
Mean	37	38	37
0 - 19	8 (1%)	4 (1.5%)	9 (6%)
20 - 39	494 (63%)	137 (60.5%)	94 (60%)
40 - 59	263 (34%)	77 (34%)	46 (30%)
60 - 79	13 (2%)	8 (4%)	7 (4%)
Race			
White	388 (50%)	94 (42%)	49 (31%)
Black	382 (49%)	129 (57%)	104 (67%)
Hispanic	11 (1%)	1 (<1%)	3 (2%)
Other	0 (0%)	2 (1%)	0 (0%)
Sex			
Male	685 (88%)	189 (84%)	114 (73%)
Female	96 (12%)	37 (16%)	42 (27%)
Risk group			
Homosexual/bisexual	487 (62%)	110 (48%)	56 (36%)
Homosexual/bisexual & IVDU	24 (3%)	6 (3%)	4 (3%)
IVDU	160 (21%)	63 (28%)	51 (33%)
Transfusion*	16 (2%)	6 (3%)	7 (4%)
Heterosexual	58 (7%)	30 (13%)	29 (18%)
Other risk/NIR	36 (5%)	11 (5%)	9 (6%)

AIDS, acquired immunodeficiency syndrome; ARC, AIDS-related complex; HIV, asymptomatic human immunodeficiency virus; IVDU = intravenous drug user; NIR, no identifiable risk factor.

*Transfusion class includes both blood transfusions and hemophiliacs.

Noninfectious HIV Retinopathy

Noninfectious HIV retinopathy was present in 50% of the patients with AIDS (Tables II and III). Forty-six percent of the patients had cotton-wool spots, and 10% had intraretinal hemorrhages. The frequency of HIV retinopathy was compared among the different stages of HIV infection (Table II). There was a significant trend for increasing frequency of HIV retinopathy as the disease stage progressed from asymptomatic HIV infection (3%) to ARC

TABLE II: HIV RETINOPATHY AND STAGE OF HIV INFECTION

	AIDS	ARC	HIV	P
No. of patients	754*	226	156	
Age (yr)				
< 40	65%	62%	66%	.69
≥ 40	35%	38%	34%	
Race				
White	50%	42%	31%	<.001
Nonwhite	50%	58%	69%	
Sex				
Male	88%	84%	73%	<.001
Female	12%	16%	27%	
Risk group				
Homosexual/bisexual	65%	51%	38%	<.001
Other risk groups	35%	49%	62%	
HIV retinopathy	51%	34%	3%	<.001

AIDS, acquired immunodeficiency syndrome; ARC, AIDS-related complex; HIV, asymptomatic human immunodeficiency virus;

*Thirty-seven patients with AIDS were seen previously at earlier stage of HIV infection and are included in analysis only once.

(34%) and AIDS (51%, $P \leq .001$). For this analysis, 37 patients with AIDS who were also seen when they had ARC or asymptomatic HIV infection were counted only once at the earlier stage of infection. Risk factors for HIV retinopathy, including age, race, sex, risk group, opportunistic infections, and neoplasms, were analyzed and are presented in Table IV. Only infection with *Mycobacterium avium* complex (MAC) was significantly associated with HIV retinopathy, with an odds ratio of 1.67 (95% confidence interval [CI] = 1.13 to 2.49). Hence, the increasing frequency of HIV retinopathy with the progressive stage of HIV infection appeared to be related directly to the progressing immune deficiency, rather than to a confounding variable due to the change in the demographics of the different stages of HIV infection.

Large-Vessel Retinal Vaso-occlusive Disease

Fourteen patients in the series developed large-vessel retinal vaso-occlusive disease, primarily central retinal vein occlusion. Twelve patients with

TABLE III: FREQUENCY OF OCULAR LESIONS IN PATIENTS WITH AIDS

LESION	NO.	%
HIV retinopathy	394	50
Cotton-wool spots	357	46
Intraretinal hemorrhages	74	10
Opportunistic ocular infections		
Cytomegalovirus retinitis	287	37
Ocular toxoplasmosis	9	1
Presumed varicella zoster retinitis	7	< 1
<i>Pneumocystis</i> choroidopathy	5	< 1
Kaposi's sarcoma		
Conjunctival	10	1
Cutaneous lid	13	2
Neuro-ophthalmic lesions	49	6

AIDS, acquired immunodeficiency syndrome; HIV, asymptomatic human immunodeficiency virus.

AIDS (1.5%) suffered such an occlusion, while one patient with ARC (0.4%) and one with asymptomatic HIV infection (0.6%) each suffered such an occlusion. The patient with ARC and the patient with asymptomatic HIV infection each had a branch retinal vein occlusion. Of the patients with AIDS, there were eight central retinal vein occlusions, two branch retinal vein occlusions, and two patients with arterial occlusive disease. The frequency of large-vessel disease was three times as great among patients with AIDS (1.5%) as among patients with earlier stages of HIV infection (0.5%), but the difference was only suggestive (Fisher's exact test, $P = .15$).

Cytomegalovirus Retinitis

Two hundred eighty-seven patients with AIDS (37%) developed CMV retinitis (Table III). The annual incidence of CMV retinitis from 1983 through 1992 is plotted as Fig 7.

Demographics of Patients With CMV Retinitis.

The demographic characteristics of the 287 patients with CMV retinitis are listed in Table V. Mean age was 38 years (range, 16 to 67). Fifty-six percent of patients were white, 42% were black, and 2% were Hispanic. Eighty-eight percent were male and 12% were female. Of the 210 patients (74%) who were in the homosexual or bisexual risk group, 10 patients also had a

TABLE IV: UNIVARIATE ANALYSIS OF RISK FACTORS FOR HIV RETINOPATHY

RISK FACTOR	ODDS RATIO	95% CONFIDENCE INTERVAL
Age (<40 yrs versus ≥40)	1.22	0.90 - 1.65
Race (white versus nonwhite)	0.78	0.59 - 1.03
Sex (male versus female)	1.12	0.73 - 1.72
Risk group (homosexual/bisexual versus other)	1.15	0.86 - 1.55
Opportunistic infections		
<i>Pneumocystis carinii</i> pneumonia	1.29	0.96 - 1.73
Cryptococcal meningitis	1.18	0.77 - 1.79
<i>Mycobacterium avium</i> complex	1.67	1.13 - 2.49
Cerebral toxoplasmosis	0.69	0.38 - 1.24
Esophageal candidiasis	1.30	0.74 - 2.29
Tumors		
Kaposi's sarcoma	0.98	0.64 - 1.50
Lymphoma	0.59	0.27 - 1.26

HIV, human immunodeficiency virus.

New Cases of CMV Retinitis By Year

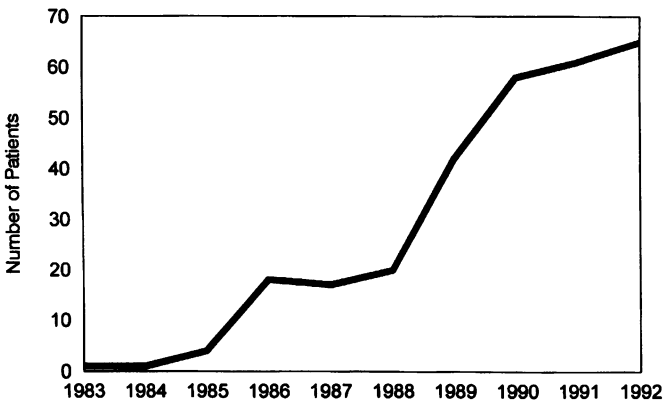


FIGURE 7

Number of new cases of cytomegalovirus retinitis per year at AIDS Ophthalmology Clinic, 1983 through 1992.

**TABLE V: BASELINE DEMOGRAPHIC CHARACTERISTICS
OF PATIENTS WITH CYTOMEGALOVIRUS RETINITIS**

CHARACTERISTIC	RESULT
No. of patients	287
Age (yr)	
Mean \pm SD	38 \pm 8
Range	16 - 67
Race	
White	56%
Black	42%
Hispanic	2%
Sex	
Male	88%
Female	12%
Risk group	
Homosexual/bisexual	74%
IVDU	14%
Other	12%
Time from Dx AIDS to Dx CMV (mo)	
Mean \pm SD	14 \pm 11
Range	0 - 81

AIDS, acquired immunodeficiency syndrome; CMV, cytomegalovirus; Dx, diagnosis; IVDU, intravenous drug use.

*Includes 10 patients with both homosexual/bisexual contact and IVDU as risk factors.

history of intravenous drug use. Intravenous drug use as the only risk factor for HIV infection was present in 14% of patients and 12% belonged to other risk groups. The mean time from the diagnosis of AIDS to the diagnosis of CMV retinitis was 14 months (range, 0 to 81). A histogram plotting the proportion of patients with CMV retinitis versus the time from the diagnosis of AIDS to the diagnosis of CMV retinitis is presented in Fig 8. Sixteen percent of the patients had CMV retinitis as their AIDS-defining opportunistic infection [or CMV present at the time of the initial diagnosis of AIDS]. These 47 patients represent 6% of all patients with AIDS in this series. Fifty-six percent of the patients had CMV retinitis diagnosed within 1 year

Time from AIDS to CMV Diagnosis

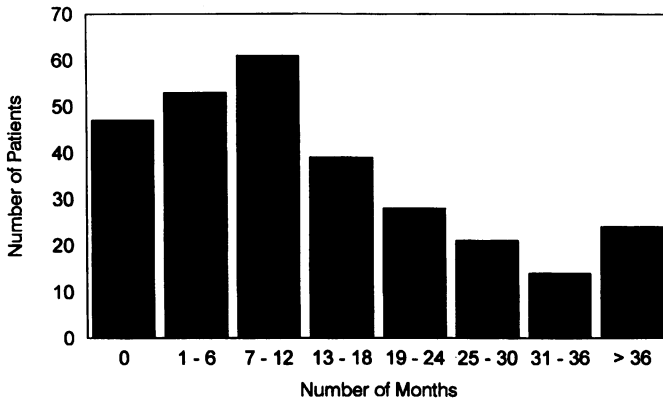


FIGURE 8

Interval between diagnosis of AIDS and diagnosis of cytomegalovirus retinitis.

of the diagnosis of AIDS. The longest interval between the diagnosis of AIDS and of CMV retinitis was 81 months.

Risk factors were analyzed among the entire AIDS cohort for the development of CMV retinitis. Univariate analysis revealed 5 risk factors significantly associated with CMV retinitis (Table VI): (1) white race, with an odds ratio of 1.57 (95% CI = 1.17 to 2.10); (2) homosexual or bisexual risk group, with an odds ratio of 1.75 (95% CI = 1.27 to 2.40); (3) MAC infection, with an odds ratio of 3.04 (95% CI = 2.04 to 4.53); (4) extraocular CMV disease, with an odds ratio of 3.40 (95% CI = 2.03 to 5.68); and (5) HIV retinopathy, with an odds ratio of 1.46 (95% CI = 1.09 to 1.96). In a multivariate analysis, white race was not significantly associated at the $P = .05$ level, and the odds ratio for race (white versus nonwhite) was 1.30, while the other 4 risk factors identified in the univariate analysis remained significantly associated.

Clinical Findings

Of the 287 patients with CMV retinitis, 148 (52%) had bilateral disease. Thus, a total of 435 eyes were involved. The characteristics of CMV retinitis at the time of diagnosis in the affected eyes are outlined in Table VII. Few eyes had only zone 1 involvement, and the majority of eyes had disease involving zones 1, 2, and/or 3. Indeed, 57% of affected eyes had some zone

TABLE VI: UNIVARIATE ANALYSIS OF RISK FACTORS
FOR CYTOMEGALOVIRUS RETINITIS

RISK FACTOR	ODDS RATIO	95% CONFIDENCE INTERVAL
Age (<40 yrs versus ≥40)	0.90	0.66 - 1.23
Race (white versus nonwhite)	1.57	1.17 - 2.10
Sex (male versus female)	1.13	0.72 - 1.76
Risk factor (homosexual/bisexual versus other)	1.75	1.27 - 2.40
Opportunistic infections		
<i>Pneumocystis carinii</i> pneumonia	1.08	0.79 - 1.46
Cryptococcal meningitis	0.67	0.42 - 1.06
<i>Mycobacterium avium</i> complex	3.04	2.04 - 4.53
Cerebral toxoplasmosis	0.56	0.28 - 1.09
Esophageal candidiasis	1.14	0.64 - 2.02
Extraocular CMV disease	3.40	2.03 - 5.68
Tumors		
Kaposi's sarcoma	1.00	0.64 - 1.55
Lymphoma	1.42	0.67 - 2.99
HIV retinopathy	1.46	1.09 - 1.96

CMV, cytomegalovirus; HIV, human immunodeficiency syndrome.

1 involvement, while 43% of eyes had disease without zone 1 involvement (ie, involving only zones 2 and/or 3). Thirty-four percent of eyes had lesions less than 10% of the retinal area in size; 38% had lesions between 10% and 24%, 15% had lesions 25% to 49%, and 13% had lesions greater than 50% of the retina in size. Eighty-six patients (30%) had "small peripheral lesions" (ie, involving zone 2 and/or 3 and less than 25% of the retina in size in the involved eyes) only at the time of initial diagnosis of CMV retinitis.

Selected baseline (ie, at time of diagnosis of CMV retinitis) characteristics of patients with "small peripheral" CMV retinitis lesions are listed in Table VIII. The only differences between those with "small peripheral" lesions and those with either "large or posterior" lesions were that a slightly greater percentage of patients with small peripheral lesions were white (67% versus 52%, $P = .03$), and a lower percentage of patients with small peripheral lesions had bilateral disease at the diagnosis of CMV retinitis (26% versus 45%, $P = .002$).

**TABLE VII: BASELINE CLINICAL CHARACTERISTICS
OF CYTOMEGALOVIRUS RETINITIS**

	NO.	%
<u>Patients (n = 287)</u>		
Bilaterality		
Bilateral	148	52
Unilateral	139	48
<u>Eyes with CMV retinitis (n = 435)</u>		
Location (n = 432)		
Zone 1 only	16	4
Zones 1 & 2 only	47	11
Zones 1, 2, & 3	182	42
Zone 2 only	8	2
Zones 2 & 3 only	153	35
Zone 3 only	26	6
Size (% of retinal area; n = 432)		
< 10%	148	34
10% - 24%	166	38
25% - 49%	64	15
≥ 50%	54	13

Laboratory Results

Information concerning CD4+ T cell counts was available on 105 patients at the time of diagnosis of CMV retinitis. The mean CD4+ T cell count was 23 cells/ μ L, the median 13 cells/ μ L, and the range 0 to 115 cells/ μ L. Although the range was broad, the distribution was skewed toward lower CD4+ T cell counts, with 89% of the patients having CD4+ T cell counts of 50 cells/ μ L or less, and 96% having CD4+ T cell counts of 100 cells/ μ L or less. Cultures of the blood and/or urine at the time of diagnosis of CMV retinitis were done on 128 patients. Blood cultures were positive in 88 (69%), and urine cultures were positive in 57 (44%). Thirty-four of these patients had both positive blood and positive urine cultures. Cultures of both were negative in 17 (13%). An additional 24 patients had evidence of CMV infection elsewhere, including isolation from the gastrointestinal tract, lung (on bronchoalveolar lavage), sputum, liver (on liver biopsy), throat, or bone marrow.

Response to Therapy

Two hundred forty-four patients were treated with either ganciclovir or foscarnet; 43 patients received no therapy. Of the 244 patients treated, 190

TABLE VIII: BASELINE CHARACTERISTICS OF PATIENTS WITH AND WITHOUT "SMALL PERIPHERAL" CYTOMEGALOVIRUS RETINITIS LESIONS

	"SMALL PERIPHERAL" LESIONS	OTHER LESIONS	<i>P</i>
No. of patients	86	200	
Age (yr)			
Mean \pm SD	39 \pm 8	37 \pm 8	.13
Range	22 - 67	16 - 64	
Race			
White	67%	52%	.03
Black	33%	46%	
Hispanic	0%	2%	
Sex			
Male	88%	88%	.93
Female	12%	12%	
Risk group			
Homosexual/bisexual	74%	72%	.17
IVDU	9%	16%	
Other	16%	11%	
Time from Dx AIDS to Dx CMV (mo)			
Mean \pm SD	16 \pm 14	14 \pm 14	.27
Range	0 - 50	0 - 81	
Bilateral CMV retinitis	26%	45%	.002
CD4+ count (cells/ μ L)			
No. of patients	33	72	
Median	14	12	.73
Mean \pm SD	17 \pm 16	26 \pm 32	
Range	0 - 60	0 - 115	

AIDS, acquired immunodeficiency syndrome; CMV, cytomegalovirus; Dx, diagnosis; IVDU, intravenous drug use.

(78%) were initially treated with ganciclovir and 54 (22%) with foscarnet. Since December 1988, when the first patient was treated with foscarnet, the relative numbers for initial treatment were 54 (27%) with foscarnet and 146 (73%) with ganciclovir. While 190 patients were started on ganciclovir and 54 patients on foscarnet, a total of 213 patients received ganciclovir therapy at some time during the course of their disease, and 87 patients received foscarnet. The baseline characteristics of the three initial treatment groups (ganciclovir as initial treatment, foscarnet as initial treatment, and no therapy) were similar (Table IX). In particular, there were no signifi-

TABLE IX: BASELINE CHARACTERISTICS OF PATIENTS WITH CYTOMEGALOVIRUS RETINITIS BY INITIAL TREATMENT

CHARACTERISTIC	INITIAL TREATMENT			P
	GANCICLOVIR	FOSCARNET	NONE	
No. of patients	190	54	43	
Age (yr)				
Mean \pm SD	38 \pm 8	38 \pm 8	39 \pm 10	.87
Range	16 - 64	22 - 57	23 - 67	
Race				
White	60%	52%	46%	.21
Black	39%	46%	49%	
Hispanic	1%	2%	5%	
Sex				
Male	88%	87%	88%	.96
Female	12%	13%	12%	
Risk group				
Homosexual/bisexual	75%	74%	65%	.61
IVDU	13%	17%	16%	
Other	12%	9%	19%	
Time from Dx AIDS to Dx CMV (mo)				
Mean \pm SD	16 \pm 15	12 \pm 12	12 \pm 13	.18
Range	0 - 81	0 - 41	0 - 51	
Bilateral CMV retinitis	39%	46%	28%	.18
Size CMV lesion*				
< 25%	68%	74%	60%	.36
\geq 25%	32%	26%	40%	
Zones CMV lesions*				
1, 2, & 3	50%	59%	51%	.63
1 or 1 & 2	14%	9%	19%	
2 and/or 3	35%	31%	30%	
CD4+ count (cells/ μ L)				
No. of patients	60	37	8	
Median	12	15	16	.91
Mean \pm SD	23 \pm 30	23 \pm 26	25 \pm 28	
Range	0 - 115	0 - 112	0 - 72	

AIDS, acquired immunodeficiency syndrome; CMV, cytomegalovirus; Dx, diagnosis; IVDU, intravenous drug use.

*Involvement in worse eye; for size, larger lesion; for zones, more posterior disease.

cant differences in the mean CD4+ T cell counts (ganciclovir, 23 cells/ μ L; foscarnet, 23 cells/ μ L; no treatment, 25 cells/ μ L).

The response to initial therapy was available for 241 patients, of which 188 were treated initially with ganciclovir and 53 with foscarnet. A remission was seen in 177 (73%), and the median time to remission was 39 days. The median time to remission was 32 days for patients initially treated with foscarnet and 42 days for those initially treated with ganciclovir (Fig 9, $P = .004$). Fifty-two percent of the treated patients suffered breakthrough during the period of observation. The median time to breakthrough after the initiation of therapy was 5.0 months (Fig 10). There was no difference between the times to breakthrough in those patients initially treated with foscarnet and those treated with ganciclovir (ganciclovir, 5.1 months; foscarnet, 4.7 months; $P = .47$).

Patients with CMV retinitis underwent reinduction at the time of breakthrough. The number of inductions needed by each patient for the 244 treated patients varied from 1 to 12. The mean number of inductions for the treated patients was 1.9, and there was a strong correlation between the number of inductions and survival (Table X, $P < .001$), in that longer survival was correlated with a greater number of inductions. The mean induction rate was 4.5 inductions per person per year.

Time to Remission by Initial Treatment

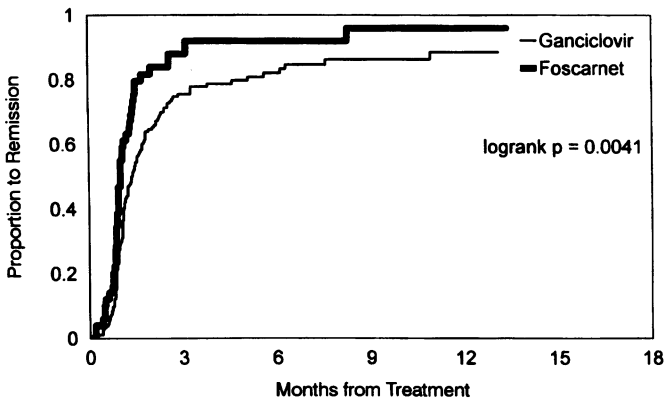


FIGURE 9

Kaplan-Meier analysis of time to "remission" of retinitis in patients with cytomegalovirus retinitis by initial treatment.

Time to Clinical Relapse

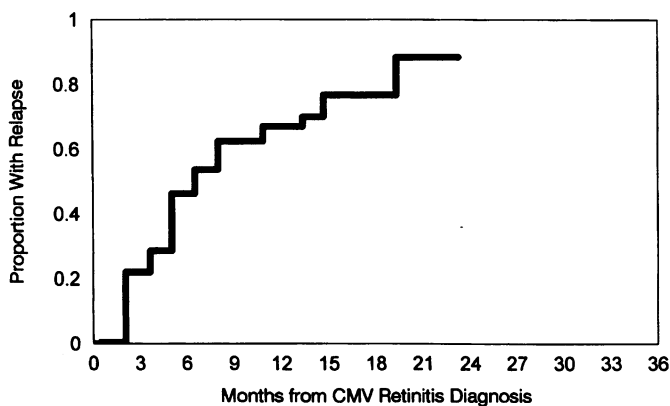


FIGURE 10

Kaplan-Meier analysis of time to clinical relapse progression of retinitis in patients with cytomegalovirus retinitis.

TABLE X: FOLLOW-UP AND NO. OF INDUCTIONS IN PATIENTS WITH CYTOMEGALOVIRUS RETINITIS

DURATION FOLLOW-UP (MO)	NO. (%) PATIENTS	MEAN NO. INDUCTIONS
0 - 3	48 (20)	1.1
4 - 6	60 (25)	1.4
7 - 9	49 (20)	1.7
10 - 12	32 (13)	2.3
> 12	55 (22)	3.1

Response of CMV Cultures to Treatment

A subset of 43 patients treated for CMV retinitis underwent routine cultures of blood and urine at scheduled time intervals after the diagnosis of CMV retinitis.⁵⁶ Treatment for CMV retinitis was successful in initially suppressing viral replication in the blood and urine (Table XI). While 70% of these 43 patients had either a positive blood or a positive urine culture at the time of diagnosis of CMV retinitis, only 5% had a positive blood or urine

TABLE XI: CULTURES FOR CYTOMEGALOVIRUS IN PATIENTS TREATED FOR CMV RETINITIS

	DIAGNOSIS	2 WK ^o	1 MO	3 MO	6 MO	1 YR
Foscarnet[†]						
Blood (n/N)‡	12/20	1/16	1/15	3/13	1/9	0/1
(%)	60	6	7	23	11	0
Urine (n/N)	11/20	0/15	2/15	2/13	2/9	0/1
(%)	55	0	13	15	22	0
Either (n/N)§	13/20	1/16	3/15	4/13	2/9	0/1
(%)	65	6	20	31	22	0
Ganciclovir[†]						
Blood (n/N)	12/23	1/21	0/21	2/18	3/13	2/4
(%)	52	5	0	11	23	50
Urine (n/N)	10/22	0/20	1/19	1/18	1/13	0/4
(%)	45	0	5	6	8	0
Either (n/N)	17/23	1/21	1/21	3/18	3/13	2/4
(%)	74	5	5	17	23	50
Total						
Blood (n/N)	24/43	2/37	1/36	5/31	4/22	2/5
(%)	56	5	3	16	18	40
Urine (n/N)	21/42	0/35	3/34	3/31	3/22	0/5
(%)	50	0	9	10	14	0
Either (n/N)	30/43	2/37	4/36	7/31	5/22	2/5
(%)	70	5	11	22	23	40

^o Time after diagnosis of CMV retinitis. [†] Initial treatment. [‡] n/N = number positive/number tested. [§] Either blood or urine culture positive.

culture 2 weeks after the initiation of therapy. Over time, there was a slow increase in the percentage of patients with either a positive blood or a positive urine culture. At 1 month after diagnosis of CMV retinitis, a positive culture from either source was detected in 11%, at 3 months in 22%, and at 6 months in 23%. Over time, the number of the patients available for follow-up cultures decreased owing to mortality. No differences could be detected in the rate of clearing of the blood or urine cultures for patients initially treated with foscarnet or initially treated with ganciclovir.

Visual Outcome

Initial visual acuities are outlined in Table XII. They are presented both for all eyes involved with CMV retinitis and as the visual acuity in the better eye

TABLE XII: VISUAL ACUITY IN PATIENTS WITH CYTOMEGALOVIRUS RETINITIS

	% EYES ^c		% PATIENTS ^a	
	INITIAL ^b	FINAL ^d	INITIAL	FINAL
No. ^e	403	425	267	280
Visual acuity				
20/40 or better	72	45	90	75
20/50 - 20/160	13	18	8	11
20/200 - 5/200	6	8	1	3
4/200 or worse	9	29	1	11

^aAll eyes involved with cytomegalovirus retinitis.

^bVision in better eye. ^cVisual acuity at time of diagnosis of CMV retinitis.

^dVisual acuity at last follow-up visit at which acuity was measured.

^eNumber of observations available, which differs from total number of involved eyes and patients with CMV retinitis owing to incomplete baseline data.

for each patient. The majority of eyes had good visual acuity at initial presentation, with 72% having 20/40 or better acuity. Only 9% of involved eyes had worse than 5/200 acuity at the time of diagnosis. When a better eye analysis was done in order to estimate the patient's function, 90% of patients had 20/40 or better acuity in at least one eye, and only 1% of patients had worse than 5/200 in both eyes at the time of diagnosis of CMV retinitis. Final visual acuities are also listed in Table XII, both for all involved eyes and for the better eye. Final visual acuity is the visual acuity determined at the time of the last follow-up at which a visual acuity could be measured. The final visual acuity was 20/40 or better in 45% of eyes, 20/50 to 20/160 in 18%, 20/200 to 5/200 in 8%, and worse than 5/200 in 29%. When patients were analyzed, 75% of the patients had a final visual acuity of 20/40 or better in at least one eye, and only 11% had a final visual acuity of 4/200 or worse. Kaplan-Meier analyses of the time to a visual acuity of 20/50 or worse and to 20/200 or worse for all involved eyes are shown in Figs 11 and 12, respectively. For all eyes with CMV retinitis, the median time to a visual acuity of 20/50 or worse was 7.7 months, and to a visual acuity of 20/200 or worse, 13.4 months. Kaplan-Meier analyses of the time to a visual acuity of 20/50 or worse for the better eye and to 20/200 or worse for the better eye are shown in Figs 13 and 14, respectively. The median time to a patient's decline in visual acuity to 20/50 was 16.0 months, and to an acuity of 20/200 or worse, 21.1 months.

Time to 20/50 or Worse All Involved Eyes (N=426)

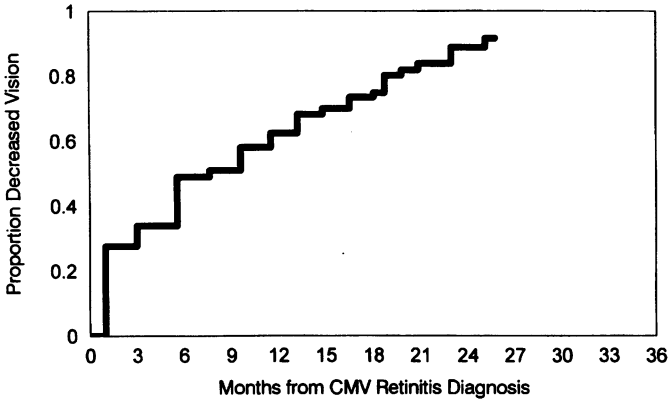


FIGURE 11

Kaplan-Meier analysis of time to visual acuity of 20/50 or worse for all eyes involved with cytomegalovirus retinitis.

Time to 20/200 or Worse All Involved Eyes (N=430)

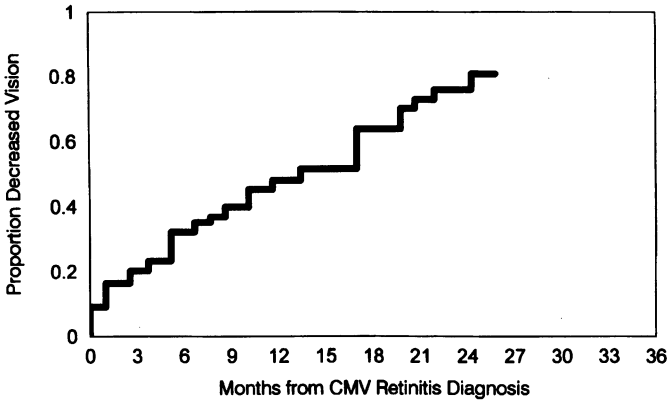


FIGURE 12

Kaplan-Meier analysis of time to visual acuity of 20/200 or worse for all eyes involved with cytomegalovirus retinitis.

Time to 20/50 or Worse

Better Eye (n=284)

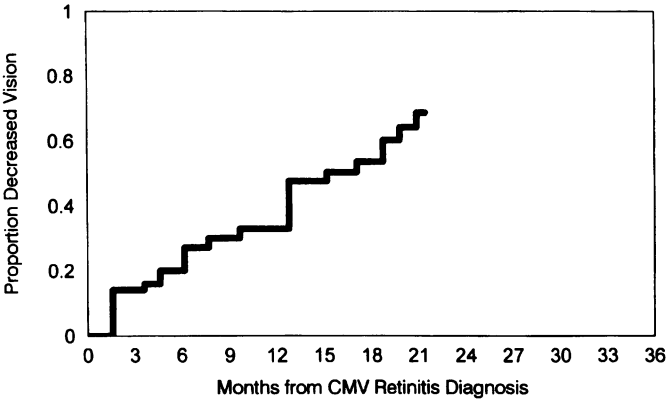


FIGURE 13

Kaplan-Meier analysis of time to visual acuity of 20/50 or worse for better eye in patients with cytomegalovirus retinitis.

Time to 20/200 or Worse

Better Eye (n=287)

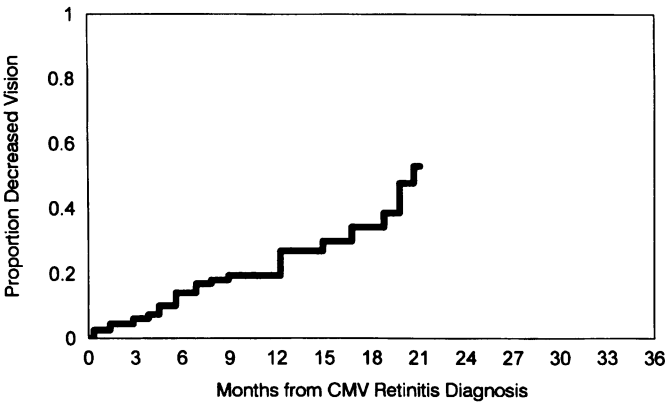


FIGURE 14

Kaplan-Meier analysis of time to visual acuity of 20/200 or worse for better eye in patients with cytomegalovirus retinitis.

Retinal Detachment

Eighty-one (28%) of the 287 patients developed a retinal detachment in at least one eye. The characteristics of patients at the time of diagnosis of CMV retinitis with a retinal detachment compared with patients without a detachment are shown in Table XIII. There were no significant differences in the baseline demographic characteristics. The median time from the diagnosis of CMV retinitis to a retinal detachment in either eye was 10.6 months, and the cumulative probability of a retinal detachment at 12 months after the diagnosis of CMV retinitis was 57% (Fig 15). Of the 81 patients with retinal detachments, 23 (28%) had bilateral detachments. Of the 81 patients with retinal detachments, 54 had bilateral CMV retinitis; and hence, 43% of patients with a retinal detachment and bilateral CMV retinitis developed a detachment in the second eye. Of the 435 eyes involved by CMV retinitis, 104 (24%) developed a retinal detachment.

TABLE XIII: BASELINE CHARACTERISTICS OF PATIENTS WITH CYTOMEGALOVIRUS RETINITIS WITH AND WITHOUT RETINAL DETACHMENTS

	PATIENTS WITH DETACHMENTS	PATIENTS WITHOUT DETACHMENTS	P
No.	81	206	
Age (yr)			
Mean \pm SD	38 \pm 8	38 \pm 8	.64
Range	16 - 64	22 - 67	
Race			
White	63%	54%	.23
Black	37%	44%	
Hispanic	0%	2%	
Sex			
Male	90%	87%	.52
Female	10%	13%	
Risk group			
Homosexual/bisexual	77%	72%	.46
IVDU	15%	14%	
Other	8%	14%	
Time from Dx AIDS to Dx CMV (mo)			
Mean \pm SD	16 \pm 17	14 \pm 12	.19
Range	0 - 81	0 - 59	
Bilateral CMV retinitis	46%	36%	.15
Size CMV lesion*			
< 25%	59%	72%	.03
\geq 25%	41%	28%	

TABLE XIII: CONTINUED BASELINE CHARACTERISTICS OF PATIENTS WITH CYTOMEGALOVIRUS RETINITIS WITH AND WITHOUT RETINAL DETACHMENTS

PATIENTS WITH DETACHMENTS	PATIENTS WITHOUT DETACHMENTS	<i>P</i>	
Zones CMV lesions*			
1, 2, & 3	59%	49%	.06
1 or 1 & 2	6%	17%	
2 and/or 3	35%	34%	
CD4+ count (cells/μL)			
No.	30	75	.66
Median	14	13	
Mean \pm SD	27 \pm 34	22 \pm 26	
Range	0 - 115	0 - 112	
Initial treatment			
Ganciclovir	83%	60%	.07
Foscarnet	15%	20%	
Eyes with CMV retinitis with and without detachments:			
No. eyes	104	331	
Size CMV lesion			
< 25%	60%	76%	.002
\geq 25%	40%	24%	
Zones CMV lesions			
1, 2, & 3	52%	39%	.012
1 or 1 & 2	7%	17%	
2 and/or 3	41%	44%	

AIDS, acquired immunodeficiency syndrome; CMV, cytomegalovirus; Dx, diagnosis; IVDU, intravenous drug use.

* Involvement in worse eye; for size, larger lesion; for zones, more posterior disease.

Complications of Therapy

Of the 213 patients treated with ganciclovir, an absolute neutrophil count less than 500 cells/ μ L occurred in 53 patients (25%), thrombocytopenia requiring discontinuation of ganciclovir occurred in three (1%), and one additional patient developed angioedema. Complications of therapy seen in the 87 patients treated with foscarnet included an elevation of the serum creatinine level to greater than 2.9 mg/dL in 18 (21%), genital ulcers in two (2%), infusion-related nausea in 7 (8%), and congestive heart failure from the fluid load accompanying foscarnet therapy in a patient with cardiomyopathy in one (1%).

Time to Retinal Detachment (N=287)

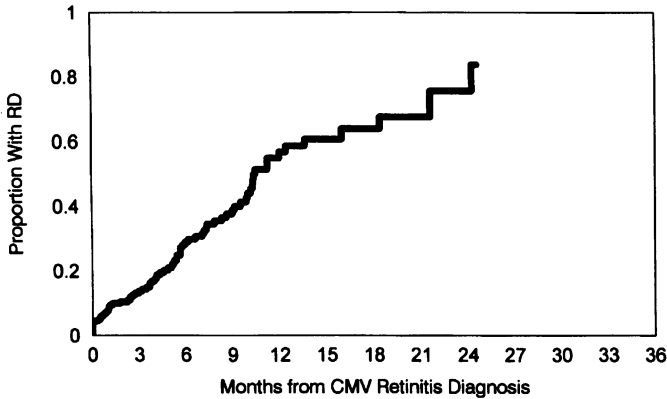


FIGURE 15

Kaplan-Meier analysis of time to retinal detachment (RD) in either eye after diagnosis of cytomegalovirus retinitis.

Of the 244 patients treated, 115 (47%) developed a complication related to a central venous catheter (CVC). Of these 115 patients with CVC-related complications, 91 (79%) suffered an episode of bacteremia or sepsis, 29 (25%) an infection of the catheter site, and 9 (8%) a thrombotic complication. The mean number of CVC-related complications for the 244 treated patients was one complication per patient. However, for the 115 patients who experienced a line complication, the mean number was two complications per patient. The maximum number of complications per patient was nine. The probability of a CVC-related complication was associated with the duration of follow-up. Of patients with 0 to 3 months' follow-up, only 19% developed a CVC-related complication, while among those patients with greater than 12 months' follow-up, 67% had at least one CVC-related complication (Table XIV, $P = .001$). Hence, CVC-related complications represented a major medical problem in patients treated for CMV retinitis with chronic intravenous therapy.

Comparisons of patients with and without CVC-related complications are presented in Table XV. There was a suggestion that the proportion of patients intravenous drug use risk group who had a CVC-related complication was higher than the proportion without a CVC complication (22% versus 14%, $P = .11$). There was a substantially greater proportion of patients

**TABLE XIV: CENTRAL VENOUS CATHETER-RELATED COMPLICATIONS
IN PATIENTS TREATED FOR CYTOMEGALOVIRUS RETINITIS**

DURATION FOLLOW-UP (MO)	NO. (%) PATIENTS	PROBABILITY OF AT LEAST ONE COMPLICATION
0 - 3	48 (20)	19%
4 - 6	60 (25)	40%
7 - 9	49 (20)	53%
10 - 12	32 (13)	59%
> 12	55 (22)	67%

with a line complication who had experienced an episode of neutropenia, defined as an absolute neutrophil count less than 500 cells/ μ L; 30% of the patients suffering a CVC-related complication had an episode of neutropenia, compared with only 15% of those without a complication ($P=.005$). The relative risk of a CVC-related complication for those patients who suffered an episode of neutropenia versus those who did not was 1.85 (95% CI = 1.42 to 2.42, $P = .00007$).

Survival

Median survival after diagnosis of CMV retinitis was 7.8 months (range, 0.7 to 33) (Fig 16). To determine if there was any change over time for survival, the 287 patients with CMV retinitis were stratified into two groups according to year of diagnosis of CMV retinitis. The first group consisted of 61 patients diagnosed between 1983 and 1988, and the second, 226 patients diagnosed between 1989 and 1992. There was a suggestion of improved survival after 1988 (Fig 17, $P = .15$), but the difference did not achieve conventional significance.

Other Ocular Infections

Herpes Zoster Ophthalmicus

Zoster ophthalmicus developed in 35 (3%) of the 1,163 patients seen. The frequency of zoster was similar among patients with AIDS, ARC, and asymptomatic HIV infection. The frequency of zoster ophthalmicus for patients with AIDS was 3%; for patients with ARC, 4%; and for patients with asymptomatic HIV infection, 3%. Ocular complications developed in 49% of the 35 patients with zoster ophthalmicus (Table XVI). The frequency of ocular complications was similar among the three groups: for patients with AIDS, 50%; for patients with ARC, 44%; and for patients with asymptomatic HIV, 50%. The most frequently noted complication in pa-

TABLE XV: CHARACTERISTICS OF PATIENTS WITH CMV RETINITIS WITH AND WITHOUT CENTRAL VENOUS CATHETER COMPLICATIONS

	PATIENTS WITH CVC COMPLICATION	PATIENTS WITHOUT CVC COMPLICATION	<i>P</i>
No.	115	129	
Age (yr)			
Mean \pm SD	37 \pm 8	38 \pm 8	.49
Range	22 - 64	16 - 60	
Race			
White	56%	59%	.57
Black	43%	39%	
Hispanic	1%	2%	
Sex			
Male	88%	88%	.90
Female	12%	12%	
Risk group			
Homosexual/bisexual	71%	70%	.11
IVDU	22%	14%	
Other	7%	16%	
Time from Dx AIDS to Dx CMV (mo)			
Mean \pm SD	16 \pm 13	14 \pm 15	.26
Range	0 - 59	0 - 81	
Bilateral CMV retinitis	36%	46%	.11
CD4+ count (cells/ μ L)			
No.	55	42	
Median	14	13	.50
Mean \pm SD	24 \pm 29	22 \pm 29	
Range	0 - 115	0 - 113	
Initial treatment			
Ganciclovir	77%	79%	
Foscarnet	23%	21%	
Ganciclovir treatment ever	90%	84%	.16
Neutropenia*	30%	15%	.005

AIDS, acquired immunodeficiency syndrome; CMV, cytomegalovirus; CVC, central venous catheter; Dx, diagnosis; IVDU, intravenous drug use.

*Any episode of an absolute neutrophil count less than 500 cells/ μ L.

Survival from Diagnosis of CMV Retinitis

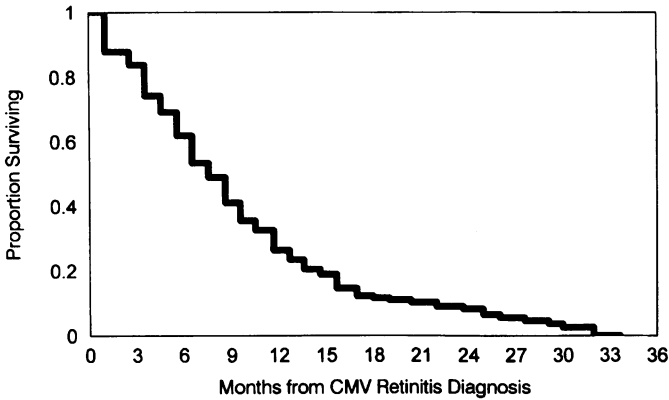


FIGURE 16

Kaplan-Meier analysis of survival after diagnosis of cytomegalovirus retinitis.

Survival after CMV Diagnosis By Year of CMV Diagnosis

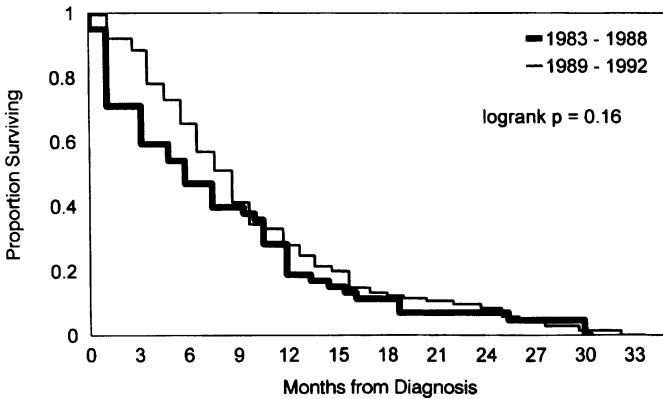


FIGURE 17

Kaplan-Meier analysis of survival after diagnosis of cytomegalovirus retinitis by year of cytomegalovirus retinitis diagnosis.

TABLE XVI: OCULAR COMPLICATIONS IN 35 HIV-INFECTED PATIENTS WITH ZOSTER OPHTHALMICUS

COMPLICATION	NO.	% PATIENTS
Any*	17	49%
Keratitis	9	26%
Uveitis	8	23%
Scleritis	2	6%
Sixth cranial nerve palsy	1	3%

* Number of complications exceeds number of patients. Three patients had more than one complication: keratouveitis in two patients and sclerouveitis in one.

tients with zoster ophthalmicus was keratitis, occurring in 26% of the 35 patients, followed by uveitis in 23%, scleritis in 6%, and a sixth cranial nerve palsy in one patient. There was no clear-cut increase in any specific complication with each of the three levels of HIV infection.

Varicella Zoster Virus Retinitis

Presumed VZV retinitis developed in seven of the 1,163 HIV-infected patients. VZV retinitis was equally frequent among patients with AIDS, ARC, and asymptomatic HIV infection. Three of the patients had the ARN syndrome variant, while four cases had the progressive outer retinal necrosis syndrome. Two cases of progressive outer retinal necrosis were seen in patients with AIDS, and two cases were seen in patients classified as having ARC according to the 1987 CDC case surveillance definition of AIDS.⁵¹ However, both of these patients had low CD4+ T cell counts (≤ 50 cells/ μ L) and would be classified as having AIDS using the 1993 CDC case surveillance definition of AIDS.⁵² CD4+ T cell counts were available for three of the patients with progressive outer retinal necrosis and were 4 cells/ μ L, 6 cells/ μ L, and 50 cells/ μ L. Cases of ARN were seen in patients with asymptomatic HIV and AIDS. Four of the cases of VZV retinitis had antecedent cutaneous zoster, including three cases of herpes zoster ophthalmicus and one case of thoracic dermatomal zoster. All of the cases of ARN responded to treatment with intravenous acyclovir at a dosage of 1,500 mg/M² per day (divided every 8 hours) with control of the retinitis. Neither of the two cases of progressive outer retinal necrosis treated with intravenous acyclovir had any response to treatment, while in the two cases of progres-

sive outer retinal necrosis treated with combination intravenous foscarnet and acyclovir, progression of retinitis was arrested.

Ocular Toxoplasmosis

Ocular toxoplasmosis was seen in nine patients, all of whom had AIDS. Hence, 1.1% of patients with AIDS developed ocular toxoplasmosis. Forty-eight patients (6.1% of the patients with AIDS) developed CNS infection with *T gondii*. There was a significant association between ocular toxoplasmosis and CNS toxoplasmosis. Five of the nine patients with ocular involvement (56%) had CNS involvement, and of the 48 patients with CNS involvement, only 12% developed ocular disease. The relative risk for development of CNS disease for patients with ocular involvement was 19.9 ($P < .0001$, Fisher's exact test). Three of the nine patients with ocular toxoplasmosis (33%) had concomitant cytomegalovirus retinitis. The frequency of coexistent CMV retinitis and ocular toxoplasmosis was similar to the frequency of CMV retinitis in the entire AIDS population (37%). Data on the prophylaxis being used for *P carinii* pneumonia was available on eight of the nine patients. Only one of these patients was taking trimethoprim-sulfamethoxazole (TMP-SMZ); five were receiving no prophylaxis, one was receiving aerosolized pentamidine, and one dapsone. In two of the nine cases, the initial diagnosis was CMV retinitis, but this was changed because of the lack of response to anti-CMV therapy. In both cases the active retinitis quieted on appropriate anti-*Toxoplasma* therapy, confirming the diagnosis of ocular toxoplasmosis. Therapy for toxoplasmic retinitis consisted of pyrimethamine and sulfadiazine in four cases; pyrimethamine and clindamycin in two cases; clindamycin only in one case; and pyrimethamine, sulfadiazine, and clindamycin in one case. No patients were treated with concomitant corticosteroids. One patient received no treatment because of the extensive retinal destruction seen at the time of initial presentation. Two patients died during initial therapy, and one patient did not return for follow-up. Of the six patients for whom follow-up evaluations were available, all six responded to initial therapy with control of the ocular lesions. Long-term follow-up was available on only two of the nine patients. One patient was maintained on pyrimethamine and clindamycin for long-term suppressive therapy. The second patient received no suppressive therapy initially, relapsed, and was then maintained on clindamycin without any further relapses for 9 months prior to his death.

Pneumocystis Choroidopathy

Five of the patients with AIDS (0.6%) developed presumed *P carinii* choroidopathy. The diagnosis was based on the clinical appearance in all five cases, and in one case autopsy confirmation was available. Four of the five patients had a previous episode of *P carinii* pneumonia. The one patient without antecedent *P carinii* pneumonia was the one patient with au-

topsy confirmation. None of the patients were receiving TMP-SMZ as prophylaxis for *P carinii* pneumonia at the time of *Pneumocystis* choroidopathy. Three patients were receiving aerosolized pentamidine, one was receiving dapsone, and one was not receiving prophylaxis.

Fungal Retinitis

Three patients, all of whom had AIDS, developed intraocular fungal infections. Two patients had presumed cryptococcal choroiditis,¹⁵ and one patient had *Candida* endophthalmitis. The one patient with *Candida* was an intravenous drug user. Both patients with presumed cryptococcal choroiditis had coexistent cryptococcal meningitis and a beneficial response to treatment with intravenous amphotericin.

Bacterial Infections

The most commonly encountered bacterial infection was ocular syphilis, seen in 14 patients. Of the 14 patients with ocular syphilis, three had AIDS, two had ARC, and nine had asymptomatic HIV infection. One patient was seen with syphilitic uveitis and optic neuropathy both when he had asymptomatic HIV infection and later when he had developed AIDS; for statistical analyses, he was classified in the asymptomatic HIV group. There was a significant difference in the frequency of ocular syphilis between patients with AIDS and those with earlier stages of HIV infection (relative risk = .12, Fisher's exact test, $P = .0006$). There was no difference in the risk of syphilitic uveitis among homosexual or bisexual men versus other risk groups (relative risk = .71, $P = .51$). Of the 14 patients with ocular syphilis, nine had syphilitic uveitis, four had optic nerve involvement, and one had both syphilitic uveitis and an optic neuropathy. All 10 cases of syphilitic uveitis (including the one with both uveitis and an optic neuropathy) were seen in patients with either asymptomatic HIV infection (eight cases) or ARC (two cases). Two patients with asymptomatic HIV infection developed optic nerve involvement (including the one with both uveitis and optic neuropathy), while the other three cases of optic nerve involvement were seen in patients with AIDS.

One case of presumed tuberculous choroiditis was seen in a patient with AIDS and pulmonary tuberculosis. One case of presumed bacterial orbital cellulitis was seen in a patient with AIDS and CMV retinitis. The orbital cellulitis resolved with antibiotic therapy. This patient had previous episodes of bacterial infections, including sepsis and subacute bacterial endocarditis related to intravenous drug use. Bacterial corneal ulcers were seen in four patients with AIDS and one patient with ARC. The bacterial pathogens present included a mixed infection with *Staphylococcus aureus* and *Moraxella* sp in one case, *Staphylococcus epidermidis* in one case, *S aureus* in one case, and *Pseudomonas aeruginosa* in one case. In the fifth case, no culture was obtained, but the patient was treated empirically with

antibiotics with resolution. All five patients had factors contributing to the development of corneal ulcers, including radiation therapy to the lids for Kaposi's sarcoma (one case), seizures (one case), stupor and exposure (one case), herpes simplex virus keratitis and exposure (one case), and trauma (one case).

Ophthalmic Neoplasms

Kaposi's Sarcoma

Ocular involvement by Kaposi's sarcoma was present in 16 of the 781 patients (2%). There were 10 cases of conjunctival involvement and 13 cases of cutaneous lid involvement. Seven patients had both cutaneous lid and conjunctival involvement. Overall, there were 100 patients with Kaposi's sarcoma. Hence, the frequency of ocular involvement among patients with Kaposi's sarcoma was 16%. Two of the patients had only ocular involvement, while the other 14 had both ocular disease and Kaposi's sarcoma elsewhere. Eleven of the 16 patients received no specific therapy for the ocular Kaposi's sarcoma. Three patients were treated with radiation therapy to the lids, one was followed while receiving etoposide for Kaposi's sarcoma, and one patient underwent surgical excision of a conjunctival lesion. One of the patients receiving radiation and the one patient undergoing surgical excision did not suffer a relapse. Relapses of the ophthalmic Kaposi's sarcoma occurred in one of the patients receiving radiation therapy and in the one patient receiving chemotherapy (after discontinuation of the chemotherapy). There was no follow-up on one of the patients receiving radiation treatment.

Lymphoma

No cases of ocular or orbital lymphoma were diagnosed in this clinical series.

Neuro-ophthalmic lesions

Neuro-ophthalmic lesions were present in 46 patients with AIDS (6%). The most common cause of a neuro-ophthalmic lesion was cryptococcal meningitis, accounting for 25 of the 46 patients (54%). Cryptococcal meningitis was present in 100 patients with AIDS; hence, 25% of the patients with cryptococcal meningitis had an ophthalmologic complication. The ocular complications of cryptococcal meningitis are listed in Table XVII. The most frequent complication was papilledema associated with elevated intracranial pressure. The patients with optic atrophy generally were seen somewhat later in the course of their cryptococcal meningitis, and whether the optic atrophy represented the consequences of papilledema or damage to the optic nerve from cryptococcal invasion could not be determined. Optic neuropathy was diagnosed when the patient lost vision and developed clinical evidence of optic nerve dysfunction (eg, optic atrophy) during follow-up

**TABLE XVII: OCULAR COMPLICATIONS IN 100 PATIENTS
WITH CRYPTOCOCCAL MENINGITIS**

COMPLICATION	NO. AND %*
Papilledema	9
Optic atrophy	6
Optic neuropathy	4
Cranial nerve palsy†	7
Third	2
Fourth	1
Fifth	1
Sixth	3
Seventh	1
Other	
Dysconjugate gaze	1
Cortical blindness	1
Choroidopathy	2

* Twenty-five patients had ocular complications; number of complications exceeds 25 owing to multiple complications in four patients.

† Multiple cranial nerve palsies in one patient.

despite successful treatment of the cryptococcal meningitis with antifungal agents. Cranial nerve palsies were seen in seven patients. The two patients with cryptococcal choroidopathy were described previously in the "Other Ocular Infections" section.

Other neuro-ophthalmic lesions in patients with AIDS included optic neuropathies (eight cases), cranial nerve palsies (five cases), visual field deficits (four cases), papilledema (two cases), and other abnormalities of ocular motility, such as a skew deviation (one case) and opsoclonus (one case). The causes of these other neuro-ophthalmic lesions included CNS mass lesions such as toxoplasmosis (four cases) and lymphoma (one case diagnosed and one case presumed); CNS infections, such as herpes simplex virus encephalitis and/or meningitis (two cases), VZV encephalitis (one case), progressive multifocal leukoencephalopathy (one case), and syphilis (four cases); herpes zoster ophthalmicus (one case); and ethambutol toxicity (one case). Two cases were attributed to HIV infection of the CNS, and in three cases, the etiology was unknown, although HIV infection was considered a potential cause.

Neuro-ophthalmic lesions were seen in six patients with asymptomatic HIV infection (3%) and two patients with ARC (1%). Of the patients with

asymptomatic HIV infection, one had papilledema due to malignant hypertension, two had an optic neuropathy due to syphilis, one had optic atrophy of unknown cause, one patient with idiopathic thrombocytopenic purpura had an optic neuropathy (possibly related to HIV), and one patient had optic neuritis. Of the patients with ARC, two had optic neuritis. In all three patients with optic neuritis, the etiology was undetermined. Neuro-ophthalmic lesions were significantly more common among patients with AIDS than among patients in earlier stages of HIV infection (relative risk = 2.8, $P = .008$).

DISCUSSION

In this thesis we document the experience of the AIDS Ophthalmology Clinic at an urban academic medical center from 1983 through December 31, 1992. The cut-off date of December 31, 1992, was chosen to coincide with the change in the CDC surveillance case definition for AIDS effective January 1, 1993.⁵² This change in definition, which now includes CD4+ T cell lymphopenia less than 200 cells/ μ L as an AIDS-defining diagnostic criterion, will alter certain epidemiologic inferences as to the frequency of events in patients with AIDS. For example, during 1993 approximately half of the patients diagnosed as having AIDS fulfilled the 1993 CDC surveillance case definition for the classification of AIDS but did not fulfill the 1987 CDC surveillance case definition (ie, they were diagnosed as having AIDS due to CD4+ T cell lymphopenia but did not have a category C indicator disease).⁶⁰ Given the relatively larger number of patients now diagnosed as having AIDS as a consequence of CD4+ T cell lymphopenia, it is anticipated that the reported frequency of ocular events may decrease in the future because of the larger denominator; however, the magnitude of this effect remains to be seen.

Our data must be interpreted cautiously because they are not a prospective epidemiologic evaluation of a cohort over time. Rather, they reflect a retrospective analysis of a large clinical experience. However, the 781 patients with AIDS are estimated to represent 78% of the patients with AIDS seen at our hospital and 24% of the patients with AIDS seen in our metropolitan area.⁶¹ As such, the data provide a fairly representative sample of what might be seen in patients with AIDS. The series is weighted toward patients with more severe immunodeficiency (AIDS) rather than toward earlier stages of HIV infection, reflecting the referral bias of patients more likely to have ocular findings. Indeed, the 382 patients with ARC or asymptomatic HIV infection are estimated to represent only 18% of the patients with the earlier stages of HIV infection seen at our hospital. However, since it has been the policy of our AIDS Ophthalmology Clinic to see all HIV-infected patients for any visual complaint, regardless of its nature, our data provide some information of what will be seen at all levels of HIV

infection.

Comparison of the three levels of HIV infection (AIDS, ARC, asymptomatic HIV) demonstrated the shifting demographics of the AIDS epidemic, seen both locally and nationally. Specifically, there was a progressive decline in the percentage of patients who were homosexual or bisexual men (62% of patients with AIDS versus 36% of patients with asymptomatic HIV) and a corresponding increase in the percentage of patients who either were intravenous drug users (21% to 33%) or acquired HIV through heterosexual transmission (7% to 18%).

The most common ocular finding in patients with HIV infection was the noninfectious HIV retinopathy. The frequency of HIV retinopathy was greatest among patients with AIDS and least among patients with the asymptomatic HIV infection. The change in demographic features among the three groups did not account for the difference in the frequency of HIV retinopathy. Only stage of HIV infection and coinfection with MAC infection were significantly associated with HIV retinopathy. The association of HIV retinopathy with MAC infection probably represents the association of each with lower CD4+ T cell counts. MAC infection is known to occur with increasing frequency at lower CD4+ T cell counts, particularly less than 100 cells/ μ L,⁶² and Kuppermann and associates²⁰ have reported that HIV retinopathy is also associated with lower CD4+ T cell counts.

The pathogenesis of HIV retinopathy is unknown, but three hypotheses have been forwarded: (1) immune complex deposition disease, (2) HIV infection of retinal vascular endothelium, and (3) hemorrhagic abnormalities. Circulating immune complexes have been detected in the sera of patients with AIDS and ARC,⁶³ and autopsy studies have demonstrated the presence of immunoglobulins occluding the retinal arteriolar lumina.¹² Patients with AIDS have B-cell abnormalities, including polyclonal B-cell activation and hypergammaglobulinemia.^{64,65} These abnormalities of B-cell function are similar to those seen in patients with autoimmune disorders, such as systemic lupus erythematosus, and it has been proposed that HIV retinopathy represents an immune complex deposition phenomenon similar to the microvasculopathy seen in the patients with autoimmune diseases.¹⁰

HIV infection has been detected in retinal vascular endothelial cells⁶⁶ and in the brain of patients with AIDS.⁶⁷⁻⁷⁰ Hence, it has been proposed that this microvasculopathy is due to a toxic effect of HIV on retinal endothelial cells, resulting in vascular occlusion. However, this hypothesis has been disputed, since some data suggest that the magnitude of HIV infection in the retinal vasculature is insufficient to account for the frequency of HIV retinopathy.⁷⁰ The third hypothesis is that HIV retinopathy represents an abnormality of blood flow (hemorrhology) produced by HIV infection. Vascular abnormalities similar to those seen in the retina can be detected in the conjunctiva,^{71,72} suggesting that there is a more widespread abnormality of blood flow. These vascular abnormalities have been correlated with abnor-

mal blood flow,⁷² suggesting that this is the primary cause of HIV retinopathy. However, these studies have not addressed the mechanism for abnormal blood flow in these patients. Hence, the pathogenesis remains uncertain.

Clinically, noninfectious HIV retinopathy is visually asymptomatic. Cases of macular ischemia¹² and macular edema⁷³ have been reported but are rare. Subtle deficits in color vision and contrast sensitivity have been reported in patients with AIDS and ARC,^{74,75} and optic nerve axonal loss has been reported in patients with AIDS.⁷⁶ It is unclear whether these findings represent damage from HIV infection to the retina and/or CNS or the cumulative damage to the retina as a result of microvascular infarcts from HIV retinopathy.^{74,76}

While most patients with HIV retinopathy are visually asymptomatic, a small number of patients developed large-vessel retinal vaso-occlusive disease. Large-vessel retinal disease occurred in approximately 1% of the 1,163 patients with HIV infection. The most frequent finding was venous occlusive disease (ie, branch retinal vein occlusion or central retinal vein occlusion). These patients often suffered severe visual loss. Although, to the best of our knowledge, there is no good epidemiologic study of the incidence of branch retinal vein and central retinal vein occlusion, the frequency in patients with HIV infection seems greater than what might be expected for an age-matched population. The pathogenesis of this large-vessel retinal vaso-occlusive disease is unknown. It is conceivable that the hypergammaglobulinemia seen in patients with HIV infection is sufficiently severe in a few patients that it can lead to venous occlusive disease. However, we have insufficient data on our patients with large-vessel retinal vaso-occlusive disease and on an appropriate control population to either confirm or refute this hypothesis.

Although HIV retinopathy was the most common finding seen in patients with HIV infection, it was the opportunistic ocular infections, particularly CMV retinitis, that represented the major threat to vision among patients with AIDS. The AIDS epidemic has brought with it an epidemic of CMV retinitis. The number of new cases diagnosed annually has increased from 1 in 1983 to 65 in 1992. At our institution, CMV retinitis is now the most frequent intraocular infection encountered. Unless a successful drug for primary prophylaxis of CMV disease is found, continued increase in the incidence of CMV disease is likely. In the Multicenter AIDS Cohort Study (MACS), it was reported that with the use of primary prophylaxis for *P carinii* pneumonia, the cumulative frequency of CMV disease increased from 25% to 45% in patients with AIDS.²¹ Eighty-five percent of all CMV disease among patients with AIDS is CMV retinitis.¹⁹ Our frequency of 37% probably reflects some referral bias of patients with visual symptoms. However, the assumption that all of the patients with AIDS at our hospital not seen by us did not have CMV retinitis (a conservative assumption) still gives an estimated frequency of 29% (ie, 29% of patients with AIDS will develop CMV

retinitis between the diagnosis of AIDS and death).

Risk factors were analyzed for the development of CMV retinitis. Factors significantly associated included risk group for acquisition of HIV, MAC infection, extraocular CMV disease, and HIV retinopathy. Seroprevalence studies of the general population have reported that latent infection (positive antibodies to CMV) is present in 50%, and studies of homosexual men have reported that latent infection is present in nearly 100%.^{77,78} With progressive immunodeficiency, CMV can reactivate and establish first an active infection (positive cultures) and then disease (tissue damage), presumably through hematogenous dissemination to target-organ tissues. The association of CMV retinitis with visceral CMV disease was not surprising, since autopsy studies early in the AIDS epidemic demonstrated that when patients had CMV retinitis, there was also CMV infection elsewhere in the body in nearly all patients.¹² The association with HIV retinopathy is somewhat more intriguing. It has been hypothesized that one of the reasons for the greater frequency of CMV retinitis among patients with HIV infection, compared with patients with other immunodeficiencies or immunosuppression, is the occurrence of HIV retinopathy. Specifically, HIV retinopathy damages the vascular endothelium and thus allows the entry of CMV into the retina from the bloodstream and the establishment of retinal CMV infection. However, the association of both CMV retinitis and HIV retinopathy with low CD4+ T cell counts suggests that the association may not be independent of the CD4+ T cell count. Further exploration of this issue in a large prospective cohort study may be necessary to distinguish between the two hypotheses. While MAC infection is associated with low CD4+ counts, and the incidence of MAC infection parallels that of CMV disease,⁶² *in vitro* studies have suggested that CMV infection enhances the growth of *M avium*.⁷⁹ Hence, it is possible that this association represents a pathogenic interaction.

Several series have reported that CMV retinitis is associated with low CD4+ T cell counts, and the mean count among patients with CMV retinitis is generally less than 50 cells/ μ L, in the range of 10 to 20 cells/ μ L.^{18,20,57,80} Two studies have reported that CMV retinitis was not seen in patients with greater than 50 cells/ μ L.^{18,20} While our series shows a clear-cut association with CD4+ T cell counts of less than 50 cells/ μ L, in that 89% of the patients had a count of that level or lower, CMV retinitis was not exclusively seen in patients with low CD4+ T cell counts. Indeed, one patient had CMV retinitis with a T cell count of 115 cells/ μ L. The highest reported CD4+ T cell count in a patient with CMV retinitis in the literature is 323 cells/ μ L.⁸⁰ Hence, patients can develop CMV retinitis with T cell counts greater than 100 cells/ μ L, but the frequency is very low. Previous epidemiologic studies have estimated the risk of CMV retinitis in patients with CD4+ T cell counts of less than 100 cells/ μ L at approximately 10% per year^{18,19} and in those with CD4+ T cell counts of less than 50 cells/ μ L at approximately 20% per year.¹⁸ The

study by Kuppermann and associates²⁰ suggested that approximately half of the patients with CMV retinitis were visually asymptomatic and undiagnosed. Therefore, routine evaluation of patients with CD4+ T cell counts of less than 100 cells/ μL , in particular those with less than 50 cells/ μL , for the development of CMV retinitis might be a reasonable approach.

Among patients with CMV retinitis in whom cultures were performed, blood cultures were positive in 69% and urine cultures were positive in 44%. Other studies⁸¹⁻⁸⁴ have reported the frequent occurrence of positive blood and/or urine cultures in patients with CMV retinitis. Palestine and coworkers⁸² reported that 62% of patients with CMV retinitis had a positive blood culture and 100% of patients with CMV retinitis had a positive urine culture. Salmon and associates⁸³ reported that 94% of patients with end-organ disease had a positive blood culture. Zurlo and colleagues⁸⁴ reported that 45% of patients with CMV end-organ disease had a positive blood culture and 100% of patients had a positive urine culture. CMV is thought to be hematogenously disseminated to the retina, and the high rate of positive blood cultures in patients with CMV retinitis supports this hypothesis. Indeed, in patients with AIDS, a positive blood culture for CMV is predictive of subsequent CMV end-organ disease. Salmon and associates⁸³ found a relative risk of developing CMV retinitis of 2.7 and Zurlo and colleagues⁸⁴ found a relative risk of 2.3 (positive versus negative CMV blood cultures). However, the predictive power in the study by Zurlo and associates⁸⁴ was low, suggesting limited clinical utility.

The evaluation of new anti-CMV agents is often conducted on patients with "small peripheral" lesions, namely, those lesions occupying less than 25% of the retinal area and limited to zone 2 and/or 3.^{82,85} These lesions are not thought to be immediately vision-threatening, and deferral of anti-CMV therapy for these patients for the 3 to 4 weeks usually necessary to observe progression is thought to be an acceptable risk. We evaluated our experience and compared patients with "small peripheral" lesions to those with lesions designated "large" ($\geq 25\%$ of the retina in size) or "posterior" (involving zone 1). "Small peripheral" lesions were present in 30% of the patients with CMV retinitis at the time of diagnosis of the retinitis. Hence, recruitment for clinical trials involving "small peripheral" lesions would be expected to be approximately one-third the rate for clinical trials involving all patients with CMV retinitis. Demographic characteristics and CD4+ counts were not different between the patient group with "small peripheral" lesions and that with "large" or "posterior" lesions. The only difference between the two groups in clinical presentation was the lower rate of bilateral disease at diagnosis among patients with small peripheral lesions (26% versus 45%). This finding is consistent with the idea that these patients have less extensive disease, as evidenced by the smaller lesion size.

We also evaluated the response to therapy seen among our patients. Since this study was not a randomized, controlled, clinical trial, but rather a

retrospective analysis of our clinical experience, data comparing the two drugs, ganciclovir and foscarnet, must be interpreted with great caution. Our overall clinical response rate of 73% is similar to that reported in other smaller studies.^{17,55,82,85-100} The median time to remission was 39 days. This fact is important because it indicates that evaluation prior to 4 weeks after initiation of therapy is unlikely to show completely quiescent borders. Instead, the evaluation of patients for quiet lesions should be at 4 to 6 weeks after initiation of therapy. Evaluation prior to that time should be to document an absence of progression and confirm the initial diagnosis.

One major problem with the treatment of CMV retinitis is that of relapse. It now appears that relapse will occur in nearly all patients treated for CMV retinitis, given enough time. As such, a key issue becomes the time to relapse.^{57,58,95} Studies employing different techniques of evaluation have found different times to relapse (first progression). Studies utilizing evaluation by a centralized fundus photograph reading center have demonstrated relatively short times to first progression.^{58,82,85} In the Foscarnet-Ganciclovir Cytomegalovirus Retinitis Trial,⁵⁸ the time to first progression as judged either by the clinician or by the time to first reinduction was substantially longer than that judged by the Fundus Photograph Reading Center. Indeed, the median time to first reinduction in this trial was 121 days (4 months).⁵⁸ Our estimate of the time to breakthrough is probably most comparable to the reported time to first reinduction in the Foscarnet-Ganciclovir Cytomegalovirus Retinitis Trial. Clinical trials generally enroll a more compliant patient population and obtain a more regular frequency of evaluation in order to assure precision of measurements. In the Foscarnet-Ganciclovir Cytomegalovirus Retinitis Trial, patients were followed every 2 weeks for 2 months, and monthly thereafter. Our clinical practice of evaluating patients at 2 weeks, 4 weeks, and monthly thereafter should have provided a similar frequency of follow-up. However, since there was some degree of variable follow-up in our series owing to the inclusion of patients who were either sicker or less compliant than those in a clinical trial, our estimate of the time to progression might be expected to be longer than that in a clinical trial. As such, these data provide an estimate of what might be seen in a consecutive case series, such as is often reported for pilot projects of new therapies.¹⁰¹⁻¹⁰⁶

The second problem with relapse is that once a patient has suffered breakthrough, he or she continues to relapse at an ever-increasing rate.⁵⁸ Treatment for CMV retinitis inhibits viral replication but does not eliminate the virus from the retina. Histologic studies of eyes treated for CMV retinitis have reported that viral DNA can be detected at the border of the lesion but that viral replication is ineffective.¹⁰⁷ This fact accounts for the prompt relapse of CMV retinitis when maintenance therapy is discontinued and for the fact that most relapses of treated patients occur at the border of the existing lesion.⁹³ In the Foscarnet-Ganciclovir Cytomegalovirus Retinitis Trial, the time to progression decreased with successive progressions.⁵⁰ Our

series estimated an average rate of 4.5 inductions per person per year, with the first reinduction occurring at 5 months after initiation of treatment, suggesting an increasing need for more frequent inductions as time progressed.

The declining ability of foscarnet and ganciclovir over time to control CMV disease is mirrored by the culture results seen in the subset of patients undergoing routine culturing. Although there was a prompt initial response to therapy with clearing of the cultures of blood and urine for CMV, over time the proportion of patients with positive cultures gradually increased. Resistance testing was unavailable, and so it was not possible to determine whether or not the CMV cultures seen were due to resistant virus. However, Drew and associates⁸¹ have reported that one third of patients with CMV retinitis treated with ganciclovir for 3 or more months with positive urine cultures for CMV will have virus resistant to ganciclovir. Hence, it is likely that some of these positive cultures were due to resistant virus. However, given the fact that relapse is universal, it is unlikely that resistance accounts for all episodes of relapse. More likely, the phenomenon of relapse is due to the failing immune system and/or the inability of intermittent intravenous administration to deliver sustained high intraocular levels of antiviral agents.

Given the fact that treatment does not eliminate the virus and that relapse occurs, the goals of treatment are to retard the progression of retinitis, preserve the maximum amount of functional retina, and preserve visual acuity. Even when anti-CMV drug therapy does not result in completely quiet disease, it will retard the progression rate of CMV retinitis.¹⁰⁸ Hence, one of the key issues in treatment of CMV retinitis is the long-term visual outcome. Our study provides data on the long-term visual outcome in a relatively large cohort of patients treated for CMV retinitis. Unfortunately, it appears that with current therapies, some degree of visual loss is common. While 72% of involved eyes presented with a baseline visual acuity of 20/40 or better, the median time to a decrease in visual acuity to 20/50 or worse for all involved eyes was 7.7 months, and the median time to a visual acuity of 20/200 or worse was 13.4 months. Hence, the current treatments are not entirely successful in preventing visual loss in the involved eyes.

However, the patient's ability to function is often determined by the visual acuity in the better eye. Although 52% of the patients had bilateral disease at the time of initial diagnosis of CMV retinitis, the ability to preserve the patient's visual function was relatively good. The median time to a decline in visual acuity to 20/50 or worse was 16 months and to visual acuity of 20/200 or worse was 21 months. Given the current life span of patients with CMV retinitis, a large number of patients are likely to preserve functional visual acuity in at least one eye.

In our series the median survival after diagnosis of CMV retinitis was 7.8 months. The survival in our series was similar to the median survival reported for patients with ganciclovir therapy in the Foscarnet-Ganciclovir

Cytomegalovirus Retinitis Trial.⁵⁷ While in this trial foscarnet was associated with a longer median survival, no difference in survival between patients initially treated with foscarnet versus ganciclovir could be detected in our series a result and similar to that seen by Harb and associates¹⁰⁹; however, neither their nor our series was a randomized, controlled, clinical trial. Polis and associates¹¹⁰ reported an increased survival of a cohort of patients with AIDS and CMV retinitis treated with foscarnet when compared with historical controls. Jacobson and coworkers⁹⁹ reported a longer survival with increasing maintenance doses of foscarnet in a study of different maintenance doses for the treatment of CMV retinitis in patients with AIDS. In the Foscarnet-Ganciclovir Cytomegalovirus Retinitis Trial,⁵⁷ the difference in mortality could not be accounted for simply by differential antiretroviral use. The most likely explanation appeared to be that foscarnet inhibits HIV replication, a phenomenon that has been described in vitro.¹¹¹⁻¹¹³ The effect of foscarnet on survival in our series might be detected by an increasing survival over time due to the increasing use of foscarnet in our clinic, and there is a suggestion of an increased survival after the introduction of foscarnet in 1989. However, the difference was only suggestive, and other factors affecting survival (eg, new antiretroviral treatments, *P carinii* pneumonia prophylaxis) may have produced this difference. Holland and colleagues¹¹⁴ reported an increasing survival over time for patients with CMV retinitis and suggested that treatment for CMV retinitis may have contributed to this phenomenon. Our epidemic of CMV retinitis began somewhat later than the one in Los Angeles, and ganciclovir became available in 1984, early in our experience. Hence, our data cannot be used to confirm or refute their hypothesis.

One of the major ophthalmologic complications of CMV retinitis is retinal detachment. Multiple series have reported that approximately 25% of patients with CMV retinitis will develop a retinal detachment.^{59,115-122} This figure, since it does not take into account the time factor, is an underestimate of the cumulative frequency of retinal detachment in patients with CMV retinitis. Jabs and associates¹¹⁶ estimated a 1-year cumulative probability of retinal detachment of 50%, and in the Foscarnet-Ganciclovir Cytomegalovirus Retinitis Trial, the rate of retinal detachment was .61 per person per year (ie, an estimated 61% cumulative probability at 1 year).⁵⁸ Our 1-year cumulative probability of a retinal detachment was 57%, a very similar estimate. While early in the AIDS epidemic it was suggested that the treatment of CMV retinitis might predispose to retinal detachment by inhibiting scar formation, it has subsequently become clear that the rate of retinal detachment in patients not treated for CMV retinitis is substantially higher than in those treated.¹¹⁶ Several series have reported that successful anatomic attachment of the retina can be accomplished with vitreoretinal surgery, employing vitrectomy and tamponade with silicone oil.¹¹⁵⁻¹²² While

visual acuity outcomes after retinal reattachment surgery in patients with CMV retinitis were poor early in the AIDS epidemic, more recent reports of the visual outcomes have suggested much improved results.^{121,122} One major influence on these improving visual acuity outcomes appears to be early repair of the detachment.¹²²

Given the high rate of retinal detachments, there has been speculation as to the possible use of prophylactic therapy, such as laser photocoagulation. To date, there has been no study of prophylactic laser photocoagulation, and Freeman and colleagues¹²¹ have reported the failure of delimiting laser. This failure may be due, in part, to progression of the CMV lesion beyond the area of laser treatment. Identification of a group at high risk for CMV retinitis related retinal detachments might allow for the design of clinical trials of prophylactic therapeutic strategies. In this regard, the analysis of the baseline characteristics of patients and/or eyes with CMV retinitis and retinal detachments showed that larger lesions and those involving zone 3 were associated with an increased risk of detachment. Ninety-three percent of the eyes with a detachment had zone 3 involvement at baseline. Also, those patients who suffered a retinal detachment had a greater frequency of CMV lesions involving 25% or more of the retinal area at baseline. Jabs and associates¹¹⁶ in a smaller series, detected an association of subsequent detachments with CMV lesions at the time of diagnosis of the retinitis greater than 50% of the retinal area in size. The current series suggests that lesions occupying 25% to 50% of the retina are also associated with a greater risk of detachment than are smaller lesions. Freeman and coworkers¹²³ reported a fivefold increase in detachment risk for CMV lesions occupying greater than 25% of the retina and a 24-fold increase in risk for lesions occupying greater than 50%, when compared with those CMV lesions occupying only 10%.

The side effects of treatment seen here were similar to those described in earlier series with ganciclovir and foscarnet.^{17,57,82,85-100} The criteria used for the definition of toxicity in this study (for ganciclovir, absolute neutrophil count < 500 cells/ μ L; for foscarnet, serum creatinine > 2.9 mg/dL) are those levels that necessitate interruption of therapy. While these toxicities are generally reversible, prolonged interruptions of therapy can lead to relapse, and in the case of foscarnet, patients usually change therapy to ganciclovir because the time to reverse foscarnet's renal toxicity is too long to withhold treatment. Ganciclovir-induced granulocytopenia can now be treated with filgrastim (G-CSF; Neupogen) or sargramostim (GM-CSF; Prokine, Leukine).

A more serious and more problematic complication of current therapy is related to the CVC. Such complications were most often bacteremia or sepsis. A smaller number were catheter-site infections, and only 8% were thrombotic complications. The mean number of CVC-related complica-

tions was one complication per patient. However, it appears that the longer the patient has a CVC, the greater the likelihood of a CVC-related complication. Since treatment of CVC-related infections requires use of intravenous antibiotics, often hospitalization, and sometimes replacement of the catheter, the problems associated with CVC-related infections represent a substantial cost. Treatments for CMV retinitis that can avoid the CVC, such as the ganciclovir intraocular device,^{105,106} might improve not only the quality of life but also the medical situation for patients with CMV retinitis. The only risk factor detected for the development of a CVC-related infection, besides duration of the catheter, was an episode of neutropenia.

Other ocular infections in patients with AIDS were substantially less common than was CMV retinitis. Herpes zoster ophthalmicus occurred at all stages of HIV infection. While the proportion of patients with herpes zoster ophthalmicus was similar among patients with AIDS, ARC, and asymptomatic HIV infection, caution must be used in interpreting these data. The percentage of the patients with AIDS seen at our hospital who were referred to the AIDS Ophthalmology Clinic was much greater than the percentage of patients with earlier stages of HIV infection who were referred. Hence, it is quite possible that herpes zoster ophthalmicus is indeed more common among patients with AIDS than among those with earlier stages of HIV infection, but that we did not detect this difference because of referral bias. Other series¹²⁴⁻¹²⁶ have also reported the occurrence of herpes zoster ophthalmicus in patients at various stages of HIV infection. Kestelyn and associates,¹²⁶ reported ocular involvement in 89% of patients with herpes zoster ophthalmicus in Rwanda. Apparently, this group was not treated with acyclovir. Acyclovir has been shown to markedly decrease the rate of ocular complications in patients with herpes zoster ophthalmicus.¹²⁷ In our series, acyclovir was used routinely for the treatment of herpes zoster ophthalmicus, but 49% of these patients developed at least one ocular complication. The proportions of patients with keratitis (26%), uveitis (23%), and scleritis (6%) in our series were similar to those reported by Cobo and colleagues,¹²⁷ for keratitis (25%), uveitis (19%), and scleritis (3%) in immunologically normal patients treated with oral acyclovir. Hence, patients with HIV infection may not be prone to any greater incidence of ocular complications from herpes zoster ophthalmicus. It is possible that the severity of ocular complications may be greater in HIV-infected patients, but our data set cannot address this issue.

Presumed varicella zoster virus retinitis was seen either as the ARN syndrome or the progressive outer retinal necrosis syndrome. The ARN syndrome was seen at any level of HIV infection, while progressive outer retinal necrosis was seen only in those patients with clinical AIDS or CD4+ T cell lymphopenia. In the three patients with the progressive outer retinal necrosis syndrome for whom CD4+ T cell counts were available, all had

CD4+ T cells ≤ 50 cells/ μ L. This result is consistent with the idea that the progressive outer retinal necrosis variant is a relatively late HIV-stage manifestation and a far more aggressive form of VZV retinitis. The two patients in this series with the progressive outer retinal necrosis syndrome treated with intravenous acyclovir had no response to the drug, including one patient in whom acyclovir was started within 24 hours of the documented onset of retinitis. The two patients with the progressive outer retinal necrosis syndrome treated with combination intravenous foscarnet and intravenous acyclovir had arrest of the retinitis, but the long-term visual results were compromised by the development of retinal detachments and/or optic atrophy. We now treat patients with the progressive outer retinal necrosis syndrome with intravenous acyclovir at a dosage of 1,500 mg/M² per day (in divided doses, every 8 hours) and intravenous foscarnet at a dosage of 90 mg/kg every 12 hours for 2 weeks, followed by lifetime maintenance therapy with oral acyclovir at a dosage of 800 mg 5 times per day and intravenous foscarnet at 120 mg/kg per day.

Ocular toxoplasmosis was the second most common intraocular infection diagnosed in patients with AIDS. Occasionally, it was initially misdiagnosed as CMV retinitis. The progressive nature of the infection despite therapy for CMV led to the correct diagnosis, and there was a subsequent response to appropriate treatment with anti-*Toxoplasma* medications. Infection of the CNS with toxoplasmosis is estimated to occur in 3% to 10% of patients with AIDS in the United States.^{125,129} Toxoplasmic cerebritis responds to treatment with conventional regimens, such as pyrimethamine and sulfadiazine or pyrimethamine and clindamycin.¹²⁵⁻¹³⁰ In our series, toxoplasmic retinitis was associated with toxoplasmic cerebritis. Fifty-five percent of the HIV-infected patients with ocular toxoplasmosis also had toxoplasmic cerebritis. Hence, in an HIV-infected patient presenting with ocular toxoplasmosis, evaluation for CNS toxoplasmosis would seem to be appropriate. However, since only 12% of those patients with CNS toxoplasmosis had ocular involvement, the routine evaluation of patients without ocular symptoms may be less rewarding.

The response of ocular toxoplasmosis to anti-*Toxoplasma* therapy was good, regardless of which antibiotic combination was used (pyrimethamine and sulfadiazine; pyrimethamine and clindamycin; clindamycin alone; or pyrimethamine, sulfadiazine, and clindamycin). All of the patients for whom follow-up data were available responded to treatment with anti-*Toxoplasma* medications, indicating the efficacy of these antibiotics in control of the ocular infection. Systemic corticosteroids were not used because of the concerns of increasing immunosuppression. Given the good responses observed, it would appear that systemic corticosteroids are not necessary for the treatment of ocular toxoplasmosis in HIV-infected individuals. However, long-term suppressive antibiotic therapy may be necessary.^{30,31} It has

been reported that low-dose TMP-SMZ prophylaxis for *P carinii* pneumonia is effective in preventing the development of toxoplasmic cerebritis.¹³¹ Indeed, only one of our nine patients with toxoplasmic retinitis was receiving TMP-SMZ prophylaxis for *P carinii* pneumonia, suggesting that TMP-SMZ may be prophylactic against ocular toxoplasmosis as well. With the increasing use of TMP-SMZ as prophylaxis for *P carinii* pneumonia, the incidence of toxoplasmic retinitis in patients with AIDS may decrease over time.

P carinii pneumonia was originally the most frequent opportunistic infection in patients with AIDS. Its occurrence was predictable and was associated with a CD4+ T cell count < 200 cells/ μ L.¹³² Because of the morbidity and mortality associated with *P carinii* pneumonia, primary prophylaxis for its prevention and secondary prophylaxis to prevent its recurrence have become established forms of therapy in patients with AIDS. Initially, aerosolized pentamidine was used because of its relatively low rate of systemic complications and its effectiveness in preventing the initial occurrence and the recurrence of this infection.¹³³⁻¹³⁵ Subsequently, it became evident that aerosolized pentamidine was associated with extrapulmonary pneumocystosis.¹³⁶ Aerosolized pentamidine permitted the extrapulmonary proliferation of organisms while inhibiting pulmonary disease. Subsequent randomized, controlled clinical trials have demonstrated the superiority of TMP-SMZ over aerosolized pentamidine as both the primary and secondary prophylaxis for *P carinii* pneumonia.^{137,138}

Pneumocystis choroidopathy is a form of extrapulmonary pneumocystosis, first described by Rao and associates.³² It has been associated with the use of aerosolized pentamidine as *P carinii* pneumonia prophylaxis.^{34,35} Three of our five patients with *Pneumocystis* choroidopathy received aerosolized pentamidine as *P carinii* pneumonia prophylaxis, while a fourth was receiving no such prophylaxis. The fifth patient was receiving dapsone, which is less effective than TMP-SMZ. With the demonstration that TMP-SMZ therapy is superior to aerosolized pentamidine as prophylaxis for *P carinii* pneumonia,^{137,138} it is possible that the incidence of *P carinii* choroidopathy will decline in the future.

Fungal retinitis was uncommon among patients with AIDS. Indeed, there was only one case of *Candida* retinitis (.1%), and that patient was using intravenous drugs. Since *Candida* retinitis can be seen in non-HIV-infected patients using intravenous drugs,¹³⁹ it is more likely that this single case of *Candida* retinitis was related to the patient's intravenous drug use rather than to HIV infection. The low frequency of *Candida* retinitis and invasive candidal disease in patients with HIV infection is surprising given the common occurrence of thrush and candidal esophagitis in this patient population. It is possible that while cellular immunity is necessary for the control of mucocutaneous candidal infections, the relatively intact mucous

membrane barrier and/or presence of granulocytes in patients with AIDS may prevent dissemination of the disease. Conversely, in patients receiving chemotherapy for malignant tumors, or undergoing bone marrow transplant, candidal endophthalmitis is more likely to occur.¹⁴⁰⁻¹⁴² Estimates of the frequency of candidal endophthalmitis and/or retinitis in patients undergoing bone marrow transplant are 2% to 4%,^{141,142} a 20-fold higher frequency. Patients undergoing bone marrow transplant have aplasia, an indwelling CVC, and frequent antibiotic usage, which are all risk factors for disseminated candidal infections.¹⁴⁰ Two cases of presumed cryptococcal choroiditis were detected in patients with cryptococcal meningitis.

The most frequently encountered bacterial infection in HIV-infected patients was ocular syphilis, affecting approximately 1% of the 1,163 HIV-infected patients. This infection was more common in patients with earlier stages of HIV infection (3%) than among patients with AIDS (.4%). This result may represent a decline in the degree of sexual activity among patients with later stages of HIV infection when compared with asymptomatic HIV infection. Ocular syphilis in patients with HIV infection was most often manifested by uveitis, less often by optic nerve disease. Other series have also reported optic neuritis, retinitis, and/or scleritis as ocular complications of syphilis.¹⁴³⁻¹⁴⁷ Syphilitic uveitis in patients with HIV infection is often associated with neurosyphilis.¹⁴⁶ Intravenous treatment regimens for neurosyphilis appear to be effective in the control of this syphilitic uveitis, but intramuscular penicillin G benzathine is associated with frequent relapses.¹⁴⁷

A marked increase in active tuberculosis has been detected among HIV-infected patients.¹⁴⁸⁻¹⁵⁶ PPD-positive HIV-infected patients are more likely to develop active tuberculosis than are PPD-positive HIV-negative patients.^{149,150} In addition, HIV infection has been associated with outbreaks of multiple-drug-resistant tuberculosis.¹⁵¹⁻¹⁵⁴ Multiple-drug-resistant tuberculosis in patients with HIV infection is associated with widely disseminated disease, poor treatment response, and a high mortality rate.¹⁵⁵ Tuberculous choroidopathy has been reported previously,^{157,158} but these have been isolated case reports. HIV-infected patients with tuberculosis are at increased risk for tuberculous meningitis,¹⁵⁶ suggesting that dissemination to the eye may similarly be increased in these patients. Only one case of tuberculous choroidopathy was detected in our series. However, since only 20 cases of tuberculosis were present in the entire group of patients with AIDS, the low frequency of tuberculous choroiditis in the overall series is not surprising. Given the increasing incidence of tuberculosis in the HIV-infected population, it is likely that additional cases of tuberculous choroiditis will be seen over time.

Other reported intraocular infections have included endogenous bacterial retinitis,¹⁵⁹ bilateral chorioretinitis due to *Histoplasma capsulatum*,¹⁶⁰

corneal ulcers,¹⁶¹⁻¹⁶³ and microsporidial keratoconjunctivitis.^{164,165} No cases of bacterial retinitis, histoplasmic chorioretinitis, or microsporidial keratoconjunctivitis were encountered in this series, suggesting that these ocular complications are relatively rare. Similarly, while HIV-associated uveitis responsive to zidovudine¹⁶⁶ has been previously reported, no case of HIV-uveitis was seen in our series. Bacterial corneal ulcers were seen. However, in contrast to the reports by Parrish and associates¹⁶² and Aristimuno and colleagues,¹⁶³ where the corneal ulcers were spontaneous, in all of the cases in our series there was a mechanical factor contributing to the development of the infectious keratitis.

The only ocular tumor detected in this patient population was involvement of the conjunctiva and/or lids by Kaposi's sarcoma. Cutaneous lid involvement was somewhat more common than conjunctival involvement. These tumors were generally slow-growing and often did not require any form of therapy. Intraocular invasion never occurred among patients with conjunctival disease. The indications for therapeutic intervention included cosmesis and decreased vision due to Kaposi's sarcoma in the lids resulting in edema and obstruction of the visual axis. Either surgical excision or radiation therapy appeared to be effective, results that have been reported in other series of ocular Kaposi's sarcoma in patients with AIDS.³⁸⁻⁴¹

Scattered case reports have appeared of orbital lymphoma and of intraocular lymphoma in patients with AIDS.^{15,42,43,167-169} High-grade lymphoma in a patients with HIV infection is an AIDS-defining indicator disease.^{51,52} No patients in our clinical series of 781 patients with AIDS developed either orbital or intraocular lymphoma, underscoring the rareness of these events.

A wide variety of neuro-ophthalmic lesions have been described in patients with AIDS.^{15,44-50,159,170} Most often these represent the complications of opportunistic infections, such as toxoplasmic cerebritis or cryptococcal meningitis.^{15,44,49,50,159,170} Subtle abnormalities of ocular motility have been described in patients with AIDS and have been attributed to HIV infection.⁴⁵⁻⁴⁷ Clinically evident neuro-ophthalmic lesions developed in 6% of the patients with AIDS in our series. The most common cause of neuro-ophthalmic lesions was cryptococcal meningitis.

In the United States, cryptococcal meningitis develops in 2% to 9% of patients with AIDS.¹⁷¹⁻¹⁷³ Initial treatment is generally with intravenous amphotericin B, followed by long-term suppressive therapy with fluconazole.^{174,175} Long-term maintenance therapy (secondary prophylaxis) is necessary owing to the frequent occurrence of relapse without chronic suppression.¹⁷⁵ Milder cases of meningitis may sometimes be treated initially with fluconazole.¹⁷⁴ Ocular complications have been reported to develop in up to 76% of patients with cryptococcal meningitis.^{15,176-180} In our series, 25% of the patients with cryptococcal meningitis developed some

neuro-ophthalmic complication. The most frequent problem was papilledema, closely followed by optic atrophy and/or optic neuropathy. The optic neuropathy was diagnosed when there was a progressive decline in visual acuity and clinical evidence of optic nerve dysfunction despite therapy for cryptococcal meningitis. Two possible mechanisms for the optic neuropathy have been proposed: a direct invasion of the optic nerve by cryptococcal organisms and an adhesive arachnoiditis.¹⁷⁷⁻¹⁸⁰ It has been suggested that intravenous amphotericin therapy may produce a toxic optic neuropathy in some patients with cryptococcal meningitis.¹⁷⁶ However, the tendency to use amphotericin in patients with more severe meningitis and fluconazole in those with less severe meningitis may give the impression that amphotericin is associated with a worse visual outcome when the true problem is the underlying severity of the disease. While amphotericin toxicity cannot be ruled out in all cases, histologic studies of patients with visual loss have shown invasion of the optic nerve by cryptococcal organisms.^{177,180}

CONCLUSION

Ocular problems are common among patients with HIV infection, particularly those with AIDS. While noninfectious HIV retinopathy is the most frequently encountered problem, the major threat to vision in patients with AIDS in the United States is CMV retinitis. Currently available therapy is effective in initially controlling the retinitis, but relapses represent a long-term problem. Furthermore, the declining effectiveness of treatment over time results in some degree of visual loss. While 75% of the patients in our study had a final visual acuity of 20/40 or better in at least one eye, improved control of the disease represents a goal for future investigations. Retinal detachments continue to be a significant problem, with an estimated 1-year cumulative probability of approximately 50% to 60%. Whether better control of the retinitis or a prophylactic strategy would decrease this rate remains to be determined in future clinical trials. Other ocular problems are less common but continue to represent therapeutic challenges. Ocular toxoplasmosis, syphilitic uveitis, and *Pneumocystis* choroidopathy all respond to standard therapy for the disease. Varicella zoster virus retinitis responds to acyclovir with earlier stages of HIV infection, but in later stages of HIV infection, the progressive outer retinal necrosis syndrome variant responds poorly. Combination therapy with intravenous foscarnet and acyclovir may be of benefit in controlling the infection. Neuro-ophthalmic lesions are a frequent complication of cryptococcal meningitis.

REFERENCES

1. Gottlieb MS, Schroff R, Schanker HM, et al: *Pneumocystis carinii* pneumonia and mucosal candidiasis in previously health homosexual men: Evidence of a new acquired cel-

- lular immunodeficiency. *N Engl J Med* 1981;305:1425-1431.
2. Masur H, Michelis MA, Greene JB, et al: An outbreak of community-acquired *Pneumocystis carinii* pneumonia: Initial manifestation of cellular immune dysfunction. *N Engl J Med* 1981;305:1431-1438.
 3. Centers for Disease Control and Prevention: Update: Acquired immunodeficiency syndrome — United States, 1992. *MMWR* 1993;42:547-551.
 4. Centers for Disease Control: HIV prevalence estimates and AIDS case projections for the United States: Report based upon a workshop. *MMWR* 1990;39(RR-16):1-31.
 5. Munoz A, Wang MC, Bass S, et al: Acquired immunodeficiency syndrome (AIDS)-free time after human immunodeficiency virus type 1 (HIV-1) seroconversion in homosexual men. *Am J Epidemiol* 1989;130:530-539.
 6. Holland GN, Gottlieb MS, Yee RD, et al: Ocular disorders associated with a new severe acquired cellular immunodeficiency syndrome. *Am J Ophthalmol* 1982;93:393-402.
 7. Holland GN, Pepose JS, Pettit TH, et al: Acquired immune deficiency syndrome: Ocular manifestations. *Ophthalmology* 1983;90:859-873.
 8. Schuman JS, Friedman AH: Retinal manifestations of the acquired immune deficiency syndrome (AIDS): Cytomegalovirus, *Candida albicans*, toxoplasmosis, and *Pneumocystis carinii*. *Trans Ophthalmol Soc UK* 1983;103:177-190.
 9. Freeman WR, Lerner CW, Mines JA, et al: A prospective study of the ophthalmologic findings in the acquired immune deficiency syndrome. *Am J Ophthalmol* 1984;97:133-142.
 10. Newsome DA, Green WR, Miller ED, et al: Microvascular aspects of acquired immune deficiency syndrome retinopathy. *Am J Ophthalmol* 1984;98:590-601.
 11. Palestine AG, Rodrigues MM, Macher AM, et al: Ophthalmic involvement in acquired immunodeficiency syndrome. *Ophthalmology* 1984;91:1092-1099.
 12. Pepose JS, Holland GN, Nestor MS, et al: Acquired immune deficiency syndrome. Pathogenic mechanisms of ocular disease. *Ophthalmology* 1985;92:472-484.
 13. Humphrey RC, Parkin JM, Marsh RJ: The ophthalmological features of AIDS and AIDS related disorders. *Trans Ophthalmol Soc UK* 1986;105:505-509.
 14. Schuman JS, Orellana J, Friedman AH, et al: Acquired immunodeficiency syndrome (AIDS). *Surv Ophthalmol* 1987;31:384-410.
 15. Jabs DA, Green WR, Fox R, et al: Ocular manifestations of acquired immune deficiency syndrome. *Ophthalmology* 1989;96:1092-1099.
 16. Freeman WR, Chen A, Henderly DE, et al: Prevalence and significance of acquired immunodeficiency syndrome-related retinal microvasculopathy. *Am J Ophthalmol* 1989;107:229-335.
 17. Jabs DA, Enger C, Bartlett JG: Cytomegalovirus retinitis and acquired immunodeficiency syndrome. *Arch Ophthalmol* 1989;107:75-80.
 18. Pertel P, Hirschtick R, Phair J, et al: Risk of developing cytomegalovirus retinitis in persons infected with the human immunodeficiency virus. *J Acquir Immune Defic Syndr* 1992;5:1069-1074.
 19. Gallant JE, Moore RD, Richman DD, et al: Incidence and natural history of cytomegalovirus disease in patients with advanced human immunodeficiency virus disease treated with zidovudine. *J Infect Dis* 1992;166:1223-1227.
 20. Kuppermann BD, Petty JG, Richman DD, et al: Correlation between CD4+ counts and prevalence of cytomegalovirus retinitis and human immunodeficiency virus-related non-infectious retinal vasculopathy in patients with acquired immunodeficiency syndrome. *Am J Ophthalmol* 1993;575-582.
 21. Hoover DR, Saah AJ, Bacellar H, et al: Clinical manifestations of AIDS in the era of pneumocystis prophylaxis. *N Engl J Med* 1993;329:1922-1926.
 22. Jabs DA, Schachat AP, Liss R, et al: Presumed varicella zoster retinitis in immunocompromised patients. *Retina* 1987;7:9-13.
 23. Forster DJ, Dugel PU, Frangieh GT, et al: Rapidly progressive outer retinal necrosis in the acquired immunodeficiency syndrome. *Am J Ophthalmol* 1990;110:341-348.
 24. Margolis TP, Lowder CY, Holland GN, et al: Varicella-zoster virus retinitis in patients with the acquired immunodeficiency syndrome. *Am J Ophthalmol* 1991;112:119-131.
 25. Johnston WH, Holland GN, Engstrom RE, et al: Recurrence of presumed varicella-zoster virus retinopathy in patients with acquired immunodeficiency syndrome. *Am J*

- Ophthalmol* 1993;116:42-50.
26. Sellitti TP, Huang AJ, Schiffman J, et al: Association of herpes zoster ophthalmicus with acquired immunodeficiency syndrome and acute retinal necrosis. *Am J Ophthalmol* 1993;116:297-301.
 27. Engstrom RE Jr, Holland GN, Margolis TP, et al: The progressive outer retinal necrosis syndrome: A variant of necrotizing herpetic retinopathy in patients with AIDS. *Ophthalmology* 1994;101:1488-1502.
 28. Parke DW, Font RL: Diffuse toxoplasmic retinochoroiditis in a patient with AIDS. *Arch Ophthalmol* 1986;104:571-575.
 29. Wiess A, Margo CE, Ledford DK, et al: Toxoplasmic retinochoroiditis as an initial manifestation of the acquired immune deficiency syndrome. *Am J Ophthalmol* 1987;103:248-249.
 30. Holland GN, Engstrom RE, Glasgow BJ, et al: Ocular toxoplasmosis in patients with the acquired immunodeficiency syndrome. *Am J Ophthalmol* 1988;106:653-667.
 31. Cochereau-Massin I, LeHoang P, Lautier-Frau M, et al: Ocular toxoplasmosis in human immunodeficiency virus-infected patients. *Am J Ophthalmol* 1992;114:130-135.
 32. Rao NA, Zimmerman PL, Boyer D, et al: A clinical, histopathologic, and electron microscopic study of *Pneumocystis carinii* choroiditis. *Am J Ophthalmol* 1989;107:218-228.
 33. Freeman WR, Gross JG, Labelle J, et al: *Pneumocystis carinii* choroidopathy: A new clinical entity. *Arch Ophthalmol* 1989;107:863-867.
 34. Dugel PU, Rao NA, Forster DJ, et al: *Pneumocystis carinii* choroiditis after long-term aerosolized pentamidine therapy. *Am J Ophthalmol* 1990;110:113-117.
 35. Shami MJ, Freeman W, Friedberg D, et al: A multicenter study of *Pneumocystis* choroidopathy. *Am J Ophthalmol* 1991;112:15-22.
 36. Morinelli EN, Dugel PU, Riffenburgh R, et al: Infectious multifocal choroiditis in patients with acquired immune deficiency syndrome. *Ophthalmology* 1993;100:1014-1021.
 37. Whitcup SM, Fenton RM, Pluda JM, et al: *Pneumocystis carinii* and *Mycobacterium avium-intracellulare* infection of the choroid. *Retina* 1992;12:331-335.
 38. Schuler JD, Holland GN, Miles SA, et al: Kaposi sarcoma of the conjunctiva and eyelids associated with the acquired immunodeficiency syndrome. *Arch Ophthalmol* 1989;107:858-862.
 39. Dugel PU, Gill PS, Frangieh GT, et al: Ocular adnexal Kaposi's sarcoma in acquired immunodeficiency syndrome. *Am J Ophthalmol* 1990;110:500-503.
 40. Ghabrial R, Quivey JM, Dunn JP, et al: Radiation therapy of acquired immunodeficiency syndrome-related Kaposi's sarcoma of the eyelids and conjunctiva. *Arch Ophthalmol* 1992;110:1423-1426.
 41. Dugel PU, Gill PS, Frangieh GT, et al: Treatment of ocular adnexal Kaposi's sarcoma in acquired immune deficiency syndrome. *Ophthalmology* 1992;99:1127-1132.
 42. Fujikawa LS, Schwartz LK, Rosenbaum EH: Acquired immune deficiency syndrome associated with Burkitt's lymphoma presenting with ocular findings. (Abstract) *Ophthalmology* 1983; 90 (suppl):50.
 43. Matzkin DC, Slamovits TL, Rosenbaum PS: Simultaneous intraocular and orbital non-Hodgkin lymphoma in the acquired immune deficiency syndrome. *Ophthalmology* 1994;101:850-855.
 44. McArthur J: Neurologic manifestations of AIDS. *Medicine* 1987; 66:407-437.
 45. Hamed LM, Schatz NJ, Galetta SL: Brainstem ocular motility defects in AIDS. *Am J Ophthalmol* 1988;106:437-442.
 46. Nguyen N, Rimmer S, Katz B: Slowed saccades in the acquired immunodeficiency syndrome. *Am J Ophthalmol* 1989;107:356-360.
 47. Currie J, Benson E, Ramsden B, et al: Eye movement abnormalities as a predictor of the acquired immunodeficiency syndrome dementia complex. *Arch Neurol* 1988;45:949-953.
 48. Slavin ML, Mallin JE, Jacob HS: Isolated homonymous hemianopsia in the acquired immunodeficiency syndrome. *Am J Ophthalmol* 1989;108:198-200.
 49. Winward KE, Hamed LM, Glaser JS: The spectrum of optic nerve disease in human immunodeficiency virus infection. *Am J Ophthalmol* 1989;107:373-380.
 50. Keane JR: Neuro-ophthalmologic signs of AIDS: 50 patients. *Neurology* 1991;41:841-845.

51. Centers for Disease Control: Revision of the CDC surveillance case definition for the acquired immune deficiency syndrome. *MMWR* 1987;36:1S-15S.
52. Centers for Disease Control and Prevention: 1993 Revised classification system for HIV infection and expanded surveillance case definition for AIDS among adolescents and adults. *MMWR* 1992;41(RR-17):1-18.
53. Bloom JN, Palestine AG: The diagnosis of cytomegalovirus retinitis. *Ann Intern Med* 1988;109:963-969.
54. Holland GN and the Executive Committee of the American Uveitis Society. Standard diagnostic criteria for the acute retinal necrosis syndrome. *Am J Ophthalmol* 1994;117:663-666.
55. Holland GN, Buhles WC, Mastre B, et al: A controlled retrospective study of ganciclovir treatment for cytomegalovirus retinopathy: Use of a standardized system for the assessment of disease outcome. *Arch Ophthalmol* 1989;107:1759-1766.
56. Studies of Ocular Complications of AIDS Research Group in collaboration with AIDS Clinical Trials Group: Studies of Ocular Complications of AIDS Foscarnet-Ganciclovir Cytomegalovirus Retinitis Trial: 1. Rationale, design, and methods. *Control Clin Trials* 1992;13:22-39.
57. Studies of Ocular Complications of AIDS Research Group in collaboration with AIDS Clinical Trials Group: Mortality in patients with the acquired immunodeficiency syndrome treated with either foscarnet or ganciclovir for cytomegalovirus retinitis. *N Engl J Med* 1992;326:213-220.
58. Studies of Ocular Complications of AIDS in collaboration with the AIDS Clinical Trials Group: Foscarnet-ganciclovir cytomegalovirus retinitis trial. 4. Visual outcomes. *Ophthalmology* 1994;101:1250-1261.
59. Cox DR, Oakes D: *Analysis of Survival Data*. London, Chapman & Hall, 1984.
60. Centers for Disease Control and Prevention: Update: Impact of the expanded AIDS surveillance case definition for adolescents and adults on case reporting — United States, 1993. *MMWR* 1994;43:160-170.
61. Centers for Disease Control and Prevention: *HIV/AIDS Surveillance Report*. February 1993:1-23.
62. Gallant JE, Moore RD, Chaisson RE: Prophylaxis for opportunistic infections in patients with HIV infection. *Ann Intern Med* 1994;120:932-944.
63. Gupta S, Licorish K: Circulating immune complexes in AIDS. *N Engl J Med* 1984;310:1530-1531.
64. Lane HC, Masur H, Edgar LC, et al: Abnormalities of B-cell activation and immunoregulation in patients with the acquired immunodeficiency syndrome. *N Engl J Med* 1983;309:453-458.
65. Schnittman SM, Lane HC, Higgins SE, et al: Direct polyclonal activation of human B lymphocytes by the acquired immune deficiency syndrome virus. *Science* 1986;233:1084-1086.
66. Pomerantz RJ, Kuritzkes R, Monte M, et al: Infection of the retina by human immunodeficiency virus type I. *N Engl J Med* 1987;317:1643-1647.
67. Shaw GM, Harper ME, Hahn BH, et al: HTLV-III infection in brains of children and adults with AIDS encephalopathy. *Science* 1985;227:177-182.
68. Ho DD, Rota TR, Schooley RT, et al: Isolation of HTLV-III from cerebrospinal fluid and neural tissues of patients with neurologic syndromes related to the acquired immunodeficiency syndrome. *N Engl J Med* 1985;313:1493-1497.
69. Koenig S, Gendelman HE, Orenstein JM, et al: Detection of AIDS virus in macrophages in brain tissue from AIDS patients with encephalopathy. *Science* 1986;233:1089-1093.
70. Faber DW, Wiley CA, Lynn GB, et al: Role of HIV and CMV in the pathogenesis of retinitis and retinal vasculopathy in AIDS patients. *Invest Ophthalmol Vis Sci* 1992;33:2345-2353.
71. Teich SA: Conjunctival vascular changes in AIDS and AIDS-related complex. *Am J Ophthalmol* 1987;103:332-333.
72. Engstrom RE, Holland GN, Hardy WD, et al: Hemorrhagic abnormalities in patients with human immunodeficiency virus infection and ophthalmic microvasculopathy. *Am J Ophthalmol* 1990;109:153-161.
73. Palestine AG, Frishberg B: Macular edema in acquired immunodeficiency syndrome-

- related microvasculopathy. *Am J Ophthalmol* 1991;111:770-771.
74. Quiceno JI, Capparelli E, Sadun AA: Visual dysfunction without retinitis in patients with acquired immunodeficiency syndrome. *Am J Ophthalmol* 1992;113:8-13.
 75. Geier SA, Hammel C, Bogner JR: HIV-related ocular microangiopathic syndrome and color contrast sensitivity. *Invest Ophthalmol Vis Sci* 1994;35:3011-3021.
 76. Tenhula WN, Xu Shizao, Madigan MC: Morphometric comparisons of optic nerve axon loss in acquired immunodeficiency syndrome. *Am J Ophthalmol* 1992;113:14-20.
 79. Svenson SB, Melles H, Hoffner SE, et al: Infection with HIV-1, cytomegalovirus, or treatment with lipopolysaccharide all induce enhancement of intracellular growth of *Mycobacterium avium* in human macrophages. Presented at XXXIII Interscience Conference on Antimicrobial Agents and Chemotherapy. (Abstract 488) New Orleans, 1993.
 77. Collier AC, Meyers JD, Corey L, et al: Cytomegalovirus infection in homosexual men. *Am J Med* 1987;82:593-601.
 78. Tange M, Klein EB, Kornfield H, et al: Cytomegalovirus isolation from healthy homosexual man. *JAMA* 1984;252:1908-1910.
 80. Hoehster H, Dieterich D, Bozzette S, et al: Toxicity of combined ganciclovir and zidovudine for cytomegalovirus disease associated with AIDS. *Ann Intern Med* 1990; 113:111-117.
 81. Drew WL, Miner RC, Busch DF: Prevalence of resistance in patients receiving ganciclovir for serious cytomegalovirus infection. *J Infect Dis* 1991;163:716-719.
 82. Palestine AG, Polis MA, DeSmet MD, et al: A randomized controlled trial of foscarnet in the treatment of cytomegalovirus retinitis in patients with AIDS. *Ann Intern Med* 1991;115:665-673.
 83. Salmon D, Lacassin F, Harzic M, et al: Predictive value of cytomegalovirus viraemia for the occurrence of CMV organ involvement in AIDS. *J Med Virol* 1990;32:160-163.
 84. Zurlo JJ, O'Neill D, Polis MA, et al: Lack of clinical utility of cytomegalovirus blood and urine cultures in patients with HIV infection. *Ann Intern Med* 1993;119:12-17.
 85. Spector SA, Weingeist T, Pollard RB, et al: A randomized, controlled study of intravenous ganciclovir therapy for cytomegalovirus peripheral retinitis in patients with AIDS. *J Infect Dis* 1993;168:557-563.
 86. Collaborative DHPG Treatment Study Group: Treatment of serious cytomegalovirus infections with 9-(1,3-dihydroxy-2-propoxymethyl) guanine in patients with AIDS and other immunodeficiencies. *N Engl J Med* 1986; 314:801-805.
 87. Holland GN, Sidikaro Y, Kreiger AE, et al: Treatment of cytomegalovirus retinopathy with ganciclovir. *Ophthalmology* 1987; 94:815-823.
 88. Jabs DA, Newman C, de Bustros S, et al: Treatment of cytomegalovirus retinitis with ganciclovir. *Ophthalmology* 1987; 94:824-830.
 89. Henderly DE, Freeman WR, Causey DM, et al: Cytomegalovirus retinitis and response to therapy with ganciclovir. *Ophthalmology* 1987; 94:425-434.
 90. Orellana J, Teich SA, Friedman AH, et al: Combined short- and long term therapy for the treatment of cytomegalovirus retinitis using ganciclovir (BW B759U). *Ophthalmology* 1987; 94:831-838.
 91. Laskin OL, Cederberg DM, Mills J, et al: Ganciclovir for the treatment and suppression of serious infections caused by cytomegalovirus. *Am J Med* 1987; 83:201.
 92. Jacobson MA, O'Donnell JJ, Porteous D, et al: Retinal and gastrointestinal disease due to cytomegalovirus in patients with the acquired immune deficiency syndrome: Prevalence, natural history, and response to ganciclovir therapy. *Q J Med* 1988;67:473-486.
 93. Jacobson MA, O'Donnell JJ, Brodie HR, et al: Randomized prospective trial of ganciclovir maintenance therapy for cytomegalovirus retinitis. *J Med Virol* 1988; 25:339-349.
 94. Buhles WC, Mastro BJ, Tinker AJ, et al: Ganciclovir treatment of life-or sight-threatening cytomegalovirus infection: Experience in 314 immunocompromised patients. *Rev Infect Dis* 1988;10:S495-S506.
 95. Gross JC, Bozzette SA, Mathews WC, et al: Longitudinal study of cytomegalovirus retinitis in acquired immune deficiency syndrome. *Ophthalmology* 1990; 97:681-686.
 96. Walmsley SL, Chew E, Read SE, et al: Treatment of cytomegalovirus retinitis with trisodium phosphonoformate hexahydrate (foscarnet). *J Infect Dis* 1988; 157:569-572.
 97. LaHoang P, Girard B, Robinet TM, et al: Foscarnet in the treatment of cytomegalovirus retinitis in acquired immune deficiency syndrome. *Ophthalmology* 1989; 96:864-865.

98. Jacobson MA, O'Donnell JJ, Mills J: Foscarnet treatment of cytomegalovirus retinitis in patients with the acquired immunodeficiency syndrome. *Antimicrob Agents Chemother* 1989;33:736-741.
99. Jacobson MA, Causey D, Polsky B, et al: A dose-ranging study of daily maintenance intravenous foscarnet therapy for cytomegalovirus retinitis in AIDS. *J Infect Dis* 1993;168:444-448.
100. Katlama C, Dohin E, Caumes E, et al: Foscarnet induction therapy for cytomegalovirus retinitis in AIDS: Comparison of twice-daily and three-times-daily regimens. *J Acquir Immune Defic Syndr* 1992; 5:S18-S24.
101. Ussery FM, Gibson SR, Conklin RH, et al: Intravitreal ganciclovir in the treatment of AIDS-associated cytomegalovirus retinitis. *Ophthalmology* 1988; 95:640-648.
102. Cantrill HL, Henry K, Melroe NH, et al: Treatment of cytomegalovirus retinitis with intravitreal ganciclovir. Long-term results. *Ophthalmology* 1989; 96:367-374.
103. Heinemann MH: Long-term intravitreal ganciclovir therapy for cytomegalovirus retinopathy. *Arch Ophthalmol* 1989; 107:1767-1772.
104. Cochereau-Massin I, LeHoang P, Lautier-Frau M, et al: Efficacy and tolerance of intravitreal ganciclovir in cytomegalovirus retinitis in acquired immune deficiency syndrome. *Ophthalmology* 1991;98:1348-1355.
105. Sanborn GE, Anand R, Torti RE, et al: Sustained-release ganciclovir therapy for treatment of cytomegalovirus retinitis: Use of an intravitreal device. *Arch Ophthalmol* 1992;110:188-195.
106. Anand R, Nightingale SD, Fish RH, et al: Control of cytomegalovirus retinitis using sustained release of intraocular ganciclovir. *Arch Ophthalmol* 1993;111:223-227.
107. Pepose JS, Newman C, Bach MC, et al: Pathologic features of cytomegalovirus retinopathy after treatment with the antiviral agent ganciclovir. *Ophthalmology* 1987; 94:414-424.
108. Holland GN, Shuler JD: Progression rates of cytomegalovirus retinopathy in ganciclovir-treated and untreated patients. *Arch Ophthalmol* 1992;110:1435-1442.
109. Harb GE, Bacchetti P, Jacobson MA: Survival of patients with AIDS and cytomegalovirus disease treated with ganciclovir or foscarnet. *AIDS* 1991;5:959-965.
110. Polis MA, DeSmet MD, Baird BF, et al: Increased survival of a cohort of patients with acquired immunodeficiency syndrome and cytomegalovirus retinitis who received sodium phosphonoformate (foscarnet). *Am J Med* 1993;94:175-180.
111. Eriksson BF, Schinazi RF: Combinations of 3'-azido-3'-deoxythymidine (zidovudine) and phosphonoformate (foscarnet) against human immunodeficiency virus type 1 and cytomegalovirus replication in vitro. *Antimicrob Agents Chemother* 1989;33:663-669.
112. Kong XB, Zhu ZY, Ruprecht RM, et al: Synergistic inhibition of human immunodeficiency virus type 1 replication in vitro by two-drug and three-drug combinations of 3'-azido-3'-deoxythymidine, phosphonoformate, and 2',3'-dideoxythymidine. *Antimicrob Agents Chemother* 1991;35:2003-2011.
113. Jacobson MA, van der Horst C, Causey DM, et al: In vivo additive antiretroviral effect of combined zidovudine and foscarnet therapy for human immunodeficiency virus infection (ACTG Protocol 053). *J Infect Dis* 1991;163:1219-1222.
114. Holland GN, Sison RF, Jatulis DE, et al: Survival of patients with acquired immune deficiency syndrome after development of cytomegalovirus retinopathy. *Ophthalmology* 1990; 97:204-211.
115. Freeman WR, Henderly DE, Wan WL, et al: Prevalence, pathophysiology, and treatment of rhegmatogenous retinal detachment in treated cytomegalovirus retinitis. *Am J Ophthalmol* 1987;103:527-536.
116. Jabs DA, Enger C, Haller J, et al: Retinal detachments in patients with cytomegalovirus retinitis. *Arch Ophthalmol* 1991;109:794-799.
117. Sidikaro Y, Silver L, Holland G, et al: Rhegmatogenous retinal detachments in patients with AIDS and necrotizing retinal infections. *Ophthalmology* 1991;98:129-135.
118. Orellana J, Teich SA, Lieberman RM, et al: Treatment of retinal detachments in patients with the acquired immune deficiency syndrome. *Ophthalmology* 1991;98:939-943.
119. Dugel PU, Liggett PE, Lee MB, et al: Repair of retinal detachment caused by cytomegalovirus retinitis in patients with the acquired immunodeficiency syndrome. *Am J Ophthalmol* 1991;112:235-242.
120. Regillo CD, Vander JF, Duker JS, et al: Repair of retinitis-related retinal detachments

- with silicone oil in patients with acquired immunodeficiency syndrome. *Am J Ophthalmol* 1992;113:21-27.
121. Freeman WR, Quiceno JJ, Crapotta JA, et al: Surgical repair of rhegmatogenous retinal detachment in immunosuppressed patients with cytomegalovirus retinitis. *Ophthalmology* 1992;99:466-474.
 122. Lim JJ, Enger C, Haller JA, et al: Improved visual results after surgical repair of cytomegalovirus-related retinal detachments. *Ophthalmology* 1994;101:264-269.
 123. Freeman WR, Friedberg DN, Berry C, et al: Risk factors for development of rhegmatogenous retinal detachment in patients with cytomegalovirus retinitis. *Am J Ophthalmol* 1993;116:713-720.
 124. Cole EL, Meisler DM, Calabrese LH, et al: Herpes zoster ophthalmicus and acquired immune deficiency syndrome. *Arch Ophthalmol* 1984; 102:1027-1029.
 125. Sandor EV, Millman A, Croxson S, et al: Herpes zoster ophthalmicus in patients at risk for the acquired immune deficiency syndrome (AIDS). *Am J Ophthalmol* 1986; 101:153-155.
 126. Kestelyn P, Stevens AM, Bakkers E, et al: Severe herpes zoster ophthalmicus in young African adults: A marker for HTLV-III seropositivity. *Br J Ophthalmol* 1987; 71:806-809.
 127. Cobo LM, Foulks GN, Liesegang T, et al: Oral acyclovir in the treatment of acute herpes zoster ophthalmicus. *Ophthalmology* 1986; 93:763-770.
 128. Porter SB, Sande MA: Toxoplasmosis of the central nervous system in the acquired immunodeficiency syndrome. *N Engl J Med* 1992;327:1643-1648.
 129. Luft BJ, Hafner R, Korzun AH, et al: Toxoplasmic encephalitis in patients with the acquired immunodeficiency syndrome. *N Engl J Med* 1993;329:995-1000.
 130. Dannemann B, McCutchan JA, Israelski D, et al: Treatment of toxoplasmic encephalitis in patients with AIDS. *Ann Intern Med* 1992;116:33-43.
 131. Carr A, Tindall B, Brew BJ, et al: Low-dose trimethoprim-sulfamethoxazole prophylaxis for toxoplasmic encephalitis in patients with AIDS. *Ann Intern Med* 1992;117:106-111.
 132. Phair J, Munoz A, Detels R, et al: The risk of *Pneumocystis carinii* pneumonia among men infected with human immunodeficiency virus type 1. *N Engl J Med* 1990;322:166-175.
 133. Leoung GS, Feigal DW Jr, Montgomery AB, et al: Aerosolized pentamidine for prophylaxis against *Pneumocystis carinii* pneumonia. *N Engl J Med* 1990;323:769-775.
 134. Hirschel B, Lazzarin A, Chopard P, et al: A controlled study of inhaled pentamidine for primary prevention of *Pneumocystis carinii* pneumonia. *N Engl J Med* 1991;324:1079-1083.
 135. Montaner JS, Lawson LM, Gervais A, et al: Aerosol pentamidine for secondary prophylaxis of AIDS-related *Pneumocystis carinii* pneumonia: A randomized, placebo-controlled study. *Ann Intern Med* 1991;114:948-953.
 136. Northfelt DW, Clement MJ, Safrin S: Extrapulmonary pneumocystosis: Clinical features in human immunodeficiency virus infection. *Medicine* 1990;69:392-398.
 137. Schneider MM, Hoepelman AI, Eeftinck Schattenkerk JK: A controlled trial of aerosolized pentamidine or trimethoprim sulfamethoxazole as primary prophylaxis against *Pneumocystis carinii* pneumonia in patients with human immunodeficiency virus infection. *N Engl J Med* 1992;327:1836-1841.
 138. Hardy WD, Feinberg J, Finkelstein DM, et al: A controlled trial of trimethoprim-sulfamethoxazole or aerosolized pentamidine for secondary prophylaxis of *Pneumocystis carinii* pneumonia in patients with the acquired immunodeficiency syndrome. *N Engl J Med* 1992;327:1842-1848.
 139. Elliott AJ: Endophthalmitis in systemic disease: A review of *Candida albicans* endophthalmitis. *Semin Ophthalmol* 1987;2:229-237.
 140. McDonnell PJ, McDonnell JM, Brown RH, et al: Ocular involvement in patients with fungal infections. *Ophthalmology* 1985;92:706-709.
 141. Hirst LW, Jabs DA, Tutschka PJ, et al: The eye in bone marrow transplantation: I. Clinical study. *Arch Ophthalmol* 1983;101:580-584.
 142. Coskuncan NM, Jabs DA, Dunn JP, et al: The eye in bone marrow transplantation: VI. Retinal complications. *Arch Ophthalmol* 1994;112:372-379.
 143. Stoumbos VD, Klein ML: Syphilitic retinitis in a patient with acquired immunodeficiency

- ciency syndrome-related complex. *Am J Ophthalmol* 1987;103:103-104.
144. Passo MS, Rosenbaum JT: Ocular syphilis in patients with human immunodeficiency virus infection. *Am J Ophthalmol* 1988;106:1-5.
 145. Carter JB, Hamill RJ, Matoba AY: Bilateral syphilitic optic neuritis in a patient with a positive test for HIV. *Arch Ophthalmol* 1987;105:1485-1486.
 146. Becerra LI, Ksiazek SM, Savino PJ, et al: Syphilitic uveitis in human immunodeficiency virus-infected and noninfected patients. *Ophthalmology* 1989;96:1727-1730.
 147. McLeish WM, Pulido JS, Holland S, et al: The ocular manifestations of syphilis in the human immunodeficiency virus type 1-infected host. *Ophthalmology* 1990;97:196-203.
 148. Barnes PF, Bloch AB, Davidson PT, et al: Tuberculosis in patients with human immunodeficiency virus infection. *N Engl J Med* 1991;324:1644-1650.
 149. Selwyn PA, Hartel D, Lewis VA, et al: A prospective study of the risk of tuberculosis among intravenous drug users with human immunodeficiency virus infection. *N Engl J Med* 1989;320:545-550.
 150. Cantwell MF, Snider DE Jr, Cauthen GM, et al: Epidemiology of tuberculosis in the United States, 1985 through 1992. *JAMA* 1994;272:535-539.
 151. Edlin BR, Tokars JI, Grieco MH, et al: An outbreak of multidrug-resistant tuberculosis among hospitalized patients with the acquired immunodeficiency syndrome. *N Engl J Med* 1992;326:1514-1521.
 152. Fischl MA, Uttamchandani RB, Daikos GL, et al: An outbreak of tuberculosis caused by multiple-drug-resistant tubercle bacilli among patients with HIV infection. *Ann Intern Med* 1992;117:177-183.
 153. Frieden TR, Sterling T, Pablos-Mendez A, et al: The emergence of drug-resistant tuberculosis in New York City. *N Engl J Med* 1993;328:521-526.
 154. Iseman MD: Treatment of multidrug-resistant tuberculosis. *N Engl J Med* 1993;329:784-791.
 155. Fischl MA, Daikos GL, Uttamchandani RB, et al: Clinical presentation and outcome of patients with HIV infection and tuberculosis caused by multiple-drug-resistant bacilli. *Ann Intern Med* 1992;117:184-190.
 156. Berenguer J, Moreno S, Laguna F, et al: Tuberculous meningitis in patients infected with the human immunodeficiency virus. *N Engl J Med* 1992;326:668-672.
 157. Croxatto JO, Mestre C, Puente S, et al: Nonreactive tuberculosis in a patient with acquired immune deficiency syndrome. *Am J Ophthalmol* 1986;105:659-660.
 158. Blodi BA, Johnson MW, McLeish WM, et al: Presumed choroidal tuberculosis in a human immunodeficiency virus infected host. *Am J Ophthalmol* 1989;108:605-607.
 159. Davis JL, Nussenblatt RB, Bachman DM, et al: Endogenous bacterial retinitis in AIDS. *Am J Ophthalmol* 1989; 107:613-623.
 160. Macher A, Rodrigues MM, Kaplan W, et al: Disseminated bilateral chorioretinitis due to *Histoplasma capsulatum* in a patient with the acquired immunodeficiency syndrome. *Ophthalmology* 1985; 92:1159-1164.
 161. Santos C, Parker J, Dawson C, et al: Bilateral fungal corneal ulcers in a patient with AIDS-related complex. *Am J Ophthalmol* 1986; 102:118-119.
 162. Parrish CM, O'Day DM, Hoyle TC: Spontaneous corneal ulcer as an ocular manifestation of AIDS. *Am J Ophthalmol* 1987;104:302-303.
 163. Aristimuno B, Nirankari VS, Hemady RK, et al: Spontaneous ulcerative keratitis in immunocompromised patients. *Am J Ophthalmol* 1993;115:202-208.
 164. Friedberg DN, Stenson SM, Orenstein JM, et al: Microsporidial keratoconjunctivitis in acquired immunodeficiency syndrome. *Arch Ophthalmol* 1990;108:504-508.
 165. Lowder CY, Meisler DM, McMahon JT, et al: Microsporidia infection of the cornea in a man seropositive for human immunodeficiency virus. *Am J Ophthalmol* 1990;109:242-244.
 166. Farrell PL, Heinemann MH, Roberts CW, et al: Response of human immunodeficiency virus-associated uveitis to zidovudine. *Am J Ophthalmol* 1988; 106:7-10.
 167. Park KL, Goins KM: Hodgkin's lymphoma of the orbit associated with acquired immunodeficiency syndrome. *Am J Ophthalmol* 1993;116:111-112.
 168. Antle CM, White VA, Horsman DE, et al: Large cell orbital lymphoma in a patient with acquired immune deficiency syndrome. Case report and review. *Ophthalmology* 1990;97:1494-1498.

169. Stanton CA, Sloan DB III, Slusher MM, et al: Acquired immunodeficiency syndrome-related primary intraocular lymphoma. *Arch Ophthalmol* 1992;110:1614-1617.
170. Mansour AM: Neuro-ophthalmic findings in acquired immunodeficiency syndrome. *J Clin Neuro Ophthalmol* 1990;10:167-174.
171. Kovacs JA, Kovacs AA, Polis M, et al: Cryptococcosis in the acquired immunodeficiency syndrome. *Ann Intern Med* 1985;103:533-538.
172. Zuger A, Louie E, Holzman RS, et al: Cryptococcal disease in patients with the acquired immunodeficiency syndrome. Diagnostic features and outcomes of treatment. *Ann Intern Med* 1986;104:234-240.
173. Chuck SL, Sande MA: Infections with *Cryptococcus neoformans* in the acquired immunodeficiency syndrome. *N Engl J Med* 1989;321:794-799.
174. Saag MS, Powderly WG, Cloud GA, et al: Comparison of amphotericin B with fluconazole in the treatment of acute AIDS-associated cryptococcal meningitis. *N Engl J Med* 1992;326:83-89.
175. Bozzette SA, Larsen RA, Chiu J, et al: A placebo-controlled trial of maintenance therapy with fluconazole after treatment of cryptococcal meningitis in the acquired immunodeficiency syndrome. *N Engl J Med* 1991;324:580-584.
176. Kestelyn P, Taelman H, Bogaerts J, et al: Ophthalmic manifestations of infections with *Cryptococcus neoformans* in patients with the acquired immunodeficiency syndrome. *Am J Ophthalmol* 1993;116:721-727.
177. Cohen DB, Glasgow BJ: Bilateral optic nerve cryptococcosis in sudden blindness in patients with acquired immune deficiency syndrome. *Ophthalmology* 1993;100:1689-1694.
178. Lipson BK, Freeman WR, Beniz J, et al: Optic neuropathy associated with cryptococcal arachnoiditis in AIDS patients. *Am J Med* 1989;107:523-527.
179. Okun E, Butler WT: Ophthalmologic complications of cryptococcal meningitis. *Arch Ophthalmol* 1964;71:52-57.
180. Kupfer C, McCrane E: A possible cause of decreased vision in cryptococcal meningitis. *Invest Ophthalmol* 1974;13:801-804.