

# FUNGAL KERATITIS AT THE UNIVERSITY OF MINNESOTA: 1971-1981\*

BY *Donald J. Doughman*, MD,  
*Nancy M. Leavenworth*, MD (BY INVITATION),  
*Robert C. Campbell*, MD (BY INVITATION) AND  
(BY INVITATION) *Richard L. Lindstrom*, MD

## INTRODUCTION

FUNGAL INFECTION OF THE CORNEA MUST BE CONSIDERED IN THE DIFFERENTIAL diagnosis of any corneal ulcer. Since this is a relatively rare condition, most publications have been either individual case reports or a large series reported from referral centers especially in the southern and western United States.<sup>1-5</sup> Epidemiologic data from these reports indicate that keratomycosis would most likely occur in an otherwise healthy male working or playing outdoors after corneal abrasion with plant material. Except for seven reported cases of keratomycosis from the state of Wisconsin by Chin et al in 1975,<sup>6</sup> there has been no series of mycotic keratitis reported from the north-central region of the United States, a region with a large population of agricultural workers. The purpose of this paper is to report a series of 19 culture proven cases of fungal keratitis treated at the University of Minnesota over a ten-year time period demonstrating this disease is a significant problem in the northern states, especially in the rural farm population.

## MATERIALS AND METHODS

The records of admissions at the University of Minnesota Hospital were reviewed from January 1, 1971 to January 1, 1981. Nineteen cases of culturally proven fungal keratitis were found (only culture proven cases

\*From the University of Minnesota, Department of Ophthalmology, Minneapolis, MN. This study was supported in part by the Lion's Club of Minnesota and Research to Prevent Blindness, Inc.

were included in this study). Specimens were obtained by scraping the corneal ulcers with a sandblasted tip of a Kimura platinum spatula. The material obtained was directly inoculated onto solid Sabouraud's media without cycloheximide containing 25 µg/ml gentamicin sulfate to inhibit bacterial growth. The specimens were incubated at 30 C. If no growth was present by four weeks the specimens were discarded and reported as no growth. The table summarizes the critical information with regard to the patient's age, sex, history of injury or previous eye disease, prior treatment, description of the ulcer on admission, organisms cultured, therapy and final results. Using a minimum of one-year follow-up time none were lost to follow-up.

#### RESULTS

Table I lists the organisms cultured in the 19 cases. The most common organisms in our series were *Aspergillus* and *Candida albicans*. All cases of *Aspergillus* infections occurred in relatively young (average age of 47) healthy males who were either struck in the eye with a grain or seed or noted a sudden foreign body sensation while engaged in a farming activity. The relationship of trauma to subsequent development of the corneal ulcer was clear in each of these cases. Five of the six patients with *Aspergillus* received topical or systemic corticosteroids prior to admission at the University of Minnesota Hospitals. All cases presented with a severe anterior chamber reaction and in some cases hypopyon. A descemetocoele or threatened perforation was present in many cases. All were treated with natamycin (Pimaricin). One patient, in spite of two penetrating keratoplasties, topical treatment with Pimaricin and flucytocine, amphotericin-B topically and systemically and miconazole topically and systemically, developed endophthalmitis and required enucleation. One patient received intravenous and topical amphotericin-B for clinically suspected endophthalmitis. The final visual result was hand motion due to a large central scar. Three patients had a final visual acuity of 20/50 or better.

All *C albicans* infections occurred in diseased eyes. One patient had recurrent corneal ulcers and a history of three penetrating keratoplasties. One had entropion of the lower lid abrading the cornea. A third had a history of Stevens-Johnson syndrome with severe ocular surface disease. The fourth patient had aphakic bullous keratopathy and received donor tissue infected with *Torulopsis glabrata* for penetrating keratoplasty and has been the subject of a previous report<sup>7</sup> (*Torulopsis glabrata* is now included in the genus *Candida*<sup>8</sup>). All patients received systemic and/or topical corticosteroids prior to the treatment of keratomycosis. The aver-

TABLE I

NO.	AGE	SEX	HISTORY OF INJURY OR DISEASE	PREVIOUS TREATMENT	CLINICAL DESCRIPTION	ORGANISM	THERAPY	FINAL VISUAL RESULTS
1	65	M	FB sensation while walking in tall grass	Neosporin* Cellulose gum Prednisolone	Central ulcer superficial infiltrate	<i>Alternaria</i>	Pimaricin Neosporin Gentamicin	20/60
2	53	M	Glioblastoma radiation chemotherapy, herpes zoster ophthalmicus	Dexamethasone	Stromal opacity satellite lesions, hypopyon, greenish discharge	<i>Alternaria</i>	Amphotericin-B Fluycytocine Bacitracin	Deceased
3	93	M	Epithelial defect	Gentamicin Treated elsewhere without history of medications	Perforated cornea central corneal defect prolapsed iris, leaking AC	<i>Alternaria</i>	Pimaricin Gentamicin	LP
4	64	M	Lagophthalmos Ectropion, exposure keratitis	Neodecadron† Amphotericin-B Neosporin	Central stromal opacity, Descemetocoele, granulomatous mass, satellite lesions, central ulcer	<i>Alternaria</i>	Pimaricin Neosporin Gentamicin	LP
5	48	M	Foreign body	Hospitalized × 2 for IV & topical antibiotics	Central corneal ulcer corneal edema hypopyon	<i>Fusarium</i>	Pimaricin Amphotericin-B Prednisone, PK	20/25

6	52	M	Foreign body while operating a combine	? antibiotic	Corneal edema elevation/ex-cavation 4+ cell & flare	<i>Fusarium</i>	Pimaricin Gentamicin Bacitracin	20/60
7	49	M	Picking corn	Idoxuridine Griseofulvin Vit. B <sub>12</sub> Chloramphenicol	Central ulcer with necrotic debris hypopyon marked cell & flare	<i>Fusarium</i>	Pimaricin, Nystatin Amphotericin-B (IV & topical) Prednisolone Gentamicin, PK	HM
8	28	M	Plant seed hull right eye	Neodecadron† Garamicin Na Sulfacetamide Amphotericin-B Tetracycline	Perforated corneal ulcer, Descemetocel edema 3+ flare & cell	<i>Aspergillus fumigatus</i>	Pimaricin Prednisolone debride-ment glueing	20/50
9	58	M	FB while combining beans	Neodecadron† Nystatin Amphotericin-B antibiotics	Central ulcer abscess with purulent drainage hypopyon	<i>Aspergillus fumigatus</i>	Amphotericin-B (IV & topical) Prednisone Gentamicin Methicillin	HM
10	45	M	FB sensation while shell-ing corn	Corticosteroids Idoxuridine Vidarabine debridement × 2	Central corneal ulcer, Descemetocel satellite lesions hypopyon	<i>Aspergillus fumigatus</i>	Pimaricin Dexamethasone, Prednisone Prednisone, PK iris biopsy	20/50
11	48	M	Struck in eye with kernel of corn		Stromal infiltrate edema & folds in Descemet's satellite lesions	<i>Aspergillus</i> (not <i>fumigatus</i> )	Prednisone 5% Cellulose gum	Enucleation

12	46	M	Struck in eye with cracked corn	Inflamase Gentamicin	Deep stromal ulcer fibrin net over pupil	<i>Aspergillus fumigatus</i>	Pimaricin 5-FC Amphotericin-B Indomethacin	20/20
13	54	M	Wheat seed in eye	"eye drops"?	Central corneal ulcer with infiltrate, plaque, rubeosis, hypopyon perforation	<i>Aspergillus flavus</i>	Pimaricin Miconazole 5-FC (topical & syst.) Amphotericin-B (IV & topical) Ketoconazole (oral) PK × 2, Dexamethasone AC tap, Prednisone enucleation	Enucleation
14	78	M	Recurrent ulcer, Hx 3 PK's	Gentamicin Inflamase	Inferior-central stromal infiltrate, Descemetocoele with sealed perforation	<i>Candida albicans</i>	Pimaricin Flucytocine corneal scraping & glueing	NLP
15	78	F	Entropion	Prednisone Na Sulfacetamide	Central corneal ulcer, corneal haze hypopyon, Descemetocoele, perforation	<i>Candida albicans</i>	Pimaricin Gentamicin Bactracin Neosporin* Methicillin Lincomycin IV	CF-3'
16	51	F	Stevens-Johnson syndrome, PK × 2, corneal perf. in other eye 4 yrs ago	Gentamicin Cellulose gum Prednisolone	Stromal thinning & necrosis, corneal perforation, iris prolapse	<i>Candida albicans</i>	Cellulose gum Prednisolone	HM

17	59	M	Infected donor cornea for Bullous keratopathy 2° to birth injury	Topical corticosteroids	Whitish endothelial plaques, hypopyon, abscesses at graft host junction	<i>Candida albicans</i>	Amphotericin-B topically, systemically & intracamerally, Pimaricin Flucytocine, corticosteroids Miconazole, exchange PK, AC tap	LP
18	76	F	AODM × 9 yrs infected donor cornea for aphakic bullous keratopathy	Prednisone oral Dexamethasone Prednisolone topically	White fluffy ball of cells on endothelium at graft host junction	<i>Candida albicans</i> ( <i>Torulopsis glabrata</i> )	Flucytocine Dexamethasone Amphotericin-B (IV & topical) AC tap, iris biopsy vitreous aspiration Prednisone	Deceased
19	56		Radiation keratitis	Neo-cortef‡	White ulcerations posterior syn-echiae, Descemetocoele hypopyon	<i>Candida albicans</i>	Pimaricin, Nystatin Flucytocine Amphotericin-B corticosteroids PK, ICCE, anterior vitrectomy	CF 3-4'

\*Polymixin B-Bacitracin-Neomycin (Neosporin).

†Neomycin Sulphate-dexamethasone (Neodecadron).

‡Neomycin Sulphate-hydrocortisone acetate (Neo-cortef).

age age of these patients was 66 and the final visual results of these patients ranged from no light perception to finger counting at three feet.

Of the four patients with *Alternaria* infections, only one was a farmer with no previous history of ocular systemic disease. One patient had a history of glioblastoma treated with chemotherapy and radiation as well as herpes zoster ophthalmicus. The third patient had entropion and exposure keratitis and the fourth was a 93-year-old man with a two-year history of epithelial defect, corneal melting and perforation. The three patients with *Fusarium* infections resembled those with *Aspergillus* in that they were relatively young men without systemic or ocular disease and developed a corneal ulcer after foreign body injuries that occurred during farming activities.

With the exceptions of the infected donor grafts (patients 17 and 18; Table I) there was no typical clinical picture that could differentiate any of the organisms from each other. Figure 1 shows the seasonal variation in the occurrence of fungal keratitis in Minnesota and demonstrates a peak in October that corresponds with the harvesting season in the Midwest.

#### DISCUSSION

Fungal keratitis has been increasingly reported in the literature since the early 1960s.<sup>9</sup> Large series of patients have been reported from

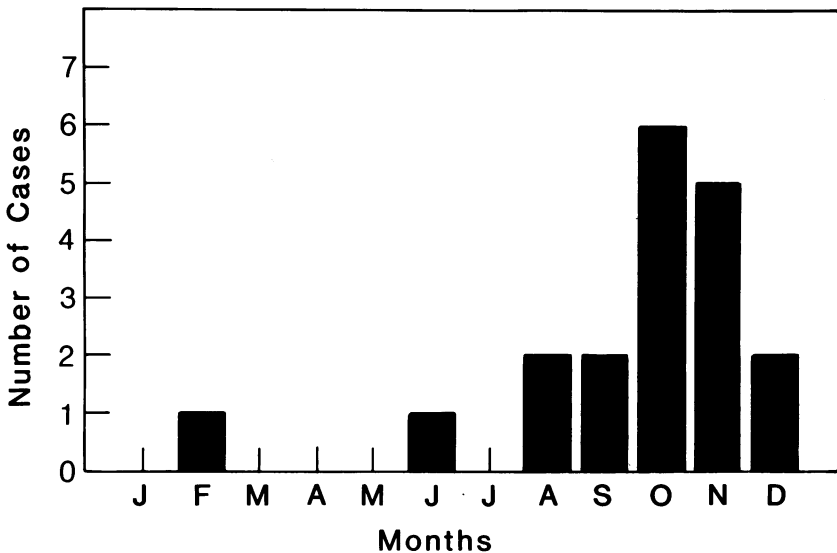


FIGURE 1  
Seasonal incidence of fungal keratitis in Minnesota.

Miami<sup>2,10,11</sup>; Gainesville<sup>1,4</sup>; San Francisco<sup>3</sup>; and New York City.<sup>5</sup> Chin et al reported seven cases over a two-year period of time seen in Wisconsin.<sup>6</sup> Our report of 19 cases over a ten-year period is the largest reported series of corneal diseases in the upper midwest area of the United States.

The predominant genus was *Fusarium* in the Florida series and *Candida* from New York City, San Francisco, and Milwaukee. In our series, *Aspergillus* and *Candida* were the most prevalent. Leber<sup>12</sup> first reported *Aspergillus* disease as an etiologic agent in hypopyon keratitis in 1879 in a farmer who had been injured with an oat shaft while thrashing. More cases of *Aspergillus* were reported over the next 30 years which Leber called *Aspergillus glaucus*. This was considered to be an occupational disease of farmers at that time. Since this was long before their introduction, corticosteroids could not be implicated. Thygeson and Okumoto<sup>3</sup> state that in rural areas, keratomycosis occurs after inoculation of fungi following corneal trauma. Our experience with both *Aspergillus* and *Fusarium* infections support this concept. All nine of these infections occurred in farmers as a result of being struck in the eye with a piece of grain or noting a foreign body while working. Presumably, these fungi are present on most cereal, vegetable, and citrus plants. *Fusarium* is the most common etiologic agent in the Miami series<sup>2,7,9</sup> presumably due to the vast numbers of citrus crops and citrus workers exposed in that area. *Aspergillus* sources include soil, farm homes, stables, barns, grain dust, and decaying vegetation. In Minnesota one-third of the state's total population is engaged in farming or related activities which explains the high incidence of these organisms causing fungal keratitis in the farming population especially during the harvest season.

*Alternaria* is a member of the class Deuteromycetes (fungi imperfecti) and of the family Dematiaceae. It does not possess the property of dimorphism lacking a yeast form.<sup>13</sup> It is commonly associated with plant material. In many laboratories this fungus is considered to be a nonpathogenic contaminant and its presence in culture may have been overlooked in the past. In addition, the use of inhibitors in the medium may prevent its growth.

*Alternaria* accounted for 21% of the organisms in this series and is the largest percentage reported to date in any published series. Isolated case reports of *Alternaria* keratomycosis have appeared in the literature.<sup>14,15</sup> Chin et al<sup>6</sup> reported one case of *Alternaria* species in their series of seven (14%) from Wisconsin. Sandhu and Randhawa<sup>16</sup> reported seven cases of *Alternaria* species from 140 corneal ulcers (5%) that occurred over a one-year period in Amrisar, India. In their study, as well as ours, the incidence of keratomycosis peaked in October. In addition, the incidence



of *Alternaria* species cultured from the atmosphere and Amrisar peaked in October. Amrisar is at 30 degrees, 38 minutes north latitude and in a cool climate relative to the rest of India. Minnesota is approximately 45 degrees north and has a cool climate during the fall months. In Sandhu and Randhawa's paper,<sup>16</sup> *Alternaria* is found in normal conjunctival sacs. Although we did not culture the atmosphere or normal conjunctiva, similar environmental conditions especially during the harvest season makes its presence likely in Minnesota.

*Candida* species was associated with diseased eyes in this series as has been reported in others.<sup>3,6,17</sup> The number of *C albicans* cases equaled *Aspergillus* as causing the largest number of corneal ulcers seen in our series. This was similar to that seen by Chin et al in Wisconsin.<sup>6</sup> Two of the *Candida* infections occurred following penetrating keratoplasty with infected donor tissue. This is a complication of organ culture donor storage utilized at the University of Minnesota and introduces a unique epidemiologic factor in mycotic eye disease. Both eyes were saved, one with topical and systemic antifungal therapy and the other with similar antimycotic treatment plus repeat corneal transplant and intracameral amphotericin-B. These cases point out the biohazard of media storage of donor tissue and increased incidence of this disease can be expected due to increasing use of such eye banking methods.

The results of therapy for mycotic keratitis show that although anti-fungal medications such as amphotericin-B and Pimaricin have greatly improved the prognosis of these infections, 70% ended up with less than 20/200 vision and two patients had to have an enucleation, figures similar to that noted by other authors.<sup>18</sup> This demonstrates the serious nature of this infection and the fact that more specific and effective antifungal therapy is still needed as recently discussed by Jones in his Jackson Memorial lecture.<sup>19</sup>

Although not specifically studied in this series, it is our impression that fewer cases of fungal keratitis are being referred to the University of Minnesota Hospital. Although this could be due to a lower incidence of the disease, a more likely explanation is the easy availability of 5% Pimaricin solution. Since most smaller hospitals do not have the equipment or personnel to do sophisticated mycology, I suspect that Pimaricin is being used in a shot gun approach to any corneal ulcer being treated by the general ophthalmologists. While this may be successful in the short run, we have only to look at the history of antibiotics to anticipate that in time organisms will become resistant to Pimaricin. Although new antifungal agents have been and are continuing to be developed for topical use, the

indiscriminate use of a valuable drug such as 5% Pimaricin is to be discouraged or it will become another penicillin-G.

#### CONCLUSIONS

Nineteen cases of culture proven fungal keratitis treated at the University of Minnesota over a ten-year period are reported. *Aspergillus* and *C albicans* represented the largest number of organisms cultured. Four cases of *Alternaria* species were cultured, the largest percentage in any series reported to date. Although Pimaricin was an effective mode of topical therapy in many of these patients, 70% were left legally blind and one eye had to be enucleated indicating that this disease is a serious ocular infection in the north-central region of the United States.

#### ACKNOWLEDGMENT

Fungal cultures were performed by the mycology laboratory at the University of Minnesota.

#### REFERENCES

1. Kaufman HE, Wood RM: Mycotic keratitis. *Am J Ophthalmol* 59:993, 1965.
2. Jones DB, Sexton RR, Rebell G: Mycotic keratitis in South Florida: A review of thirty-eight cases. *Trans Ophthalmol Soc UK* 89:781, 1969.
3. Thygeson P, Okumoto M: Keratomycosis: A preventable disease. *Trans Am Acad Ophthalmol Otolaryngol* 78:433, 1974.
4. Polack FM, Newark E, Kaufman HE: Keratomycosis. *Arch Ophthalmol* 85:410, 1971.
5. DeVoe AG: Keratomycosis. *Am J Ophthalmol* 71:406, 1971.
6. Chin GN, Hyndiuk RA, Kwasny GP, et al: Keratomycosis in Wisconsin. *Am J Ophthalmol* 79:121-125, 1975.
7. Larsen PA, Lindstrom RL, Doughman DJ: *Torulopsis glabrata* endophthalmitis after keratoplasty with an organ cultured cornea. *Arch Ophthalmol* 96:1019-1022, 1978.
8. Yarrow D, Meyers SA: Proposal for amendment of the diagnosis of the genus *Candida* Berkhout nom. cons. *Int J Systematic Bacteriol* 28:611-615, 1900.
9. Gingrich WD: Keratomycosis. *JAMA* 179:602, 1962.
10. Jones DB, Forster RK, Rebell G: *Fusarium soluni* keratitis treated with natamycin (Pimaricin). *Arch Ophthalmol* 88:147-154, 1972.
11. Forster RK, Rebell G: The diagnosis and management of keratomycoses. *Arch Ophthalmol* 93:975-978, 1975.
12. Leber T: Keratomycosis *Aspergillina* als Ursache von Hypopyonkeratitis. *Albrecht Von Graefes Arch Klin Exp Ophthalmol* 25:285-301, 1879.
13. Beneke ES: *Medical Mycology Laboratory Manual*. Minneapolis, Burgen Publishing Company, 1968, p 16.
14. Azar P, Aquavella JV, Smith RS: Keratomycosis due to an *Alternaria* species. *Am J Ophthalmol* 79:881-883, 1975.
15. Oesterle CS, Kronenberg HA, Peyman GA: Endophthalmitis caused by *Erwinia* species. *Arch Ophthalmol* 95:824-825, 1977.

16. Sandhu PK, Randhawa IS: Studies on the air-borne fungal spores in Amistar: their role in keratomycosis. *Mycopathologia* 68:47-52, 1972.
17. Jones DB: Fungal keratitis. *Clinical Ophthalmology*, Hagerstown, Harper & Row Publishing Co, 1978, vol 4, p 2.
18. Forster BK, Rebell G: The diagnosis and management of keratomycosis. II. Medical and Surgical Management. *Arch Ophthalmol* 93:1134-1136, 1975.
19. Jones BR: Principles in the management of oculomycosis. *Am J Ophthalmol* 79:719-751, 1975.

### DISCUSSION

DR ROBERT A. HYNDIUK. I thank Doctor Doughman and his colleagues for a fine paper and presentation. I have not previously seen or heard this paper, but have been asked to comment. Some know I have been in the Snow Belt in Milwaukee for the last 12 years and, as Doctor Doughman mentioned, reported on our experience with fungal keratitis in the North Country—Wisconsin—a few years ago.

Doctor Doughman has reported on the largest recent series of cases of fungal keratitis in the North Country. He has reviewed the important points and I would like to re-emphasize three concepts in dealing with patients with possible fungal keratitis. First, when should fungal keratitis be suspected? Most clinicians will automatically think of fungal keratitis when a patient comes in with a badly infected cornea and he has a history of corticosteroid use or a history of trauma. How many of us, however, in a busy practice may forget to think about fungal keratitis when we deal with a corneal ulcer and there is no history of corticosteroid use and no history of trauma? *Candida* infection is commonly superimposed on corneas that are already diseased—especially in patients with atopic disease and eczema, either with previous corneal disease or occasionally in corneas of atopic patients without previously significant corneal disease. These patients are particularly prone to *Candida* infections, herpes simplex infections, and other infections. They seem to have a problem with cell-mediated immunity—probably similar to a form-fruste Wiskott-Aldrich syndrome. In fact, many have *Candida* inhabiting mucus membranes, and in skin testing they are unresponsive to *Candida*. Increased suspicion of possible fungal infection in these atopic patients will be rewarding.

Secondly, special fungus media is not always necessary to grow *Candida*. If there is a problem, for instance in your office, with obtaining Sabouraud's media, blood agar left at room temperature will grow *Candida* and many other fungi. Bacterial overgrowth is sometimes a problem, however, when non-fungal media are used to grow fungi.

Thirdly, Doctor Doughman has already mentioned that one should be more aggressive surgically in some of these patients and I would like to re-emphasize that. We all have to remind ourselves that drugs like amphotericin-B, natamycin (Pimaricin), and the polyene antifungals are really very large molecules that penetrate the cornea relatively poorly, even in corneas with severe necrotizing

disease. If there is deep corneal infiltrative disease, some of these patients will not respond to *medical* therapy and penetrating keratoplasty may be necessary.

We recently had some interest in investigating what cryotherapy does in *Candida* keratitis. Our preliminary work shows that *Candida* strains isolated from human corneal infections are killed *in vitro* by freeze-thaw damage. Cryotherapy of *Candida* keratitis in animals deserves investigation, since occasionally patients with deep peripheral corneal infiltrative disease could be possible candidates when medical treatment has failed.

I thank Doctor Doughman and his colleagues for adding to our information on fungal keratitis in the North Country.

DR DANIEL M. TAYLOR. I would like to congratulate Doctor Doughman. Fortunately, we do not see a great deal of fungal keratitis in the northeast. However, when we do see this condition it has certainly proven to be treatment resistant and at times quite devastating. Our disappointment with medical therapy has caused us to adopt a rather aggressive approach. When we see true fungal keratitis proven by appropriate slides and cultures, we do not hesitate to proceed with either a deep lamellar full thickness keratoplasty or a full thickness penetrating keratoplasty. With either form of keratoplasty, the pathologic area is quickly eliminated and there is a dramatic reduction in inflammatory activity. We have not encountered a high incidence of peripheral anterior synechia and secondary glaucoma. I specifically mention this point, as there are many who believe that keratoplasty should be avoided at all costs when an eye is acutely inflamed. When performing an elective keratoplasty one would, of course, wait until all signs of ocular inflammation subside before proceeding. When one performs a therapeutic or reconstructive keratoplasty for treatment resistant corneal ulceration, the keratoplasty, itself, is curative and the inflammation will quickly subside. Our experience with natamycin and other fungicides has been frustrating, and we, therefore, urge an aggressive surgical approach before perforation and endophthalmitis develop.

DR FRANK M. POLACK. In 1971 we studied 33 cases of fungal keratitis (*Arch Ophthalmol* 85:410, 1971) and in 22 eyes we did penetrating keratoplasties when the infection did not respond within a few days to antifungal agents. The results were good in small lesions but usually bad in acutely inflamed eyes with large ulcers. Almost 50% of the grafts opacified and glaucoma occurred frequently. Our best surgical results were after deep keratectomies and conjunctival flaps. Today we should try antifungals for at least one week before we take any surgical approach. I also would like to remind you that the therapeutic approach is different in cases of fungus due to *Candida* or *Monilla* as compared to pathogens with collagenolytic activity such as *Fusarium* or *Cephalosporium*.

DR W. BANKS ANDERSON, JR. I have a question for Doctor Doughman. Does he feel that a sterile cornea loaded with hyphae interferes with healing?

DR RICHARD W. DARRELL. I would like to ask Doctor Doughman how often he has found the initial corneal scraping to be negative for fungus, even though subsequent scrapings and culture have established the correct diagnosis. I recall a case in which two scrapings taken several days apart were negative for fungus but the third scraping was positive. It is very important to try to make the diagnosis of fungus corneal ulcer by corneal scraping, repeated if needed, rather than to wait for the results of culture.

DR DONALD J. DOUGHMAN. I would like to thank all the discussants for their kind words. As to the questions; Doctor Anderson, I am not sure what you meant by your question. Many times corneal diagnostic scraping after short treatment intervals are sterile. Yet, when we do penetrating keratoplasty, hyphae will be found in the corneal button. Doctor Polack has previously reported the importance of not accepting a negative scraping. He advised doing a corneal biopsy that could be cultured to make the diagnosis. In fact, two of our cases in which the cultures were negative had positive cultures in the corneal button. However, I have concerns about penetrating keratoplasty in this disease in the very inflamed eye. The iris may swell causing synechia to the wound resulting in severe and often times irreversible glaucoma. On the other hand, penetrating keratoplasty may be necessary, especially if medical therapy is failing.