

OPHTHALMOLOGIC SURVEY OF
ATOMIC BOMB SURVIVORS
IN JAPAN, 1949

BY *David G. Cogan*, M.D.
S. Forrest Martin, M.D.
Samuel J. Kimura, M.D.
AND *H. Ikui*, M.D.

PURPOSE

THE OPHTHALMOLOGIC STUDY which this communication proposes to report is part of a long-term project conducted by the Atomic Bomb Casualty Commission (ABCC) to investigate the medical and biological effects of the atomic bombing in Japan.

The request for an ophthalmic survey was apparently initiated by the Committee on Ophthalmology of the National Research Council with the implied intent of determining what, if any, delayed injury to the eyes had resulted from the atomic bombing. The undertaking was prompted in considerable measure by the recent discovery of cataracts in cyclotron workers who had been chronically exposed to forms of radiant energy (neutrons and gamma rays) similar to those which were given off by the atomic bomb.

The assumed task of the study group was threefold: (1) to determine qualitatively, by history and examination, whether or not ocular lesions, other than traumatic, resulted from the atomic bombing; (2) to ascertain what the approximate frequency of these lesions was in a sample group of the surviving population who had been near the hypocenter at the time of the explosion; and (3) to note any incidental findings that might be considered of significance or interest in a routine examination of the eyes of a Japanese population.

BACKGROUND AND PREVIOUS PERTINENT LITERATURE

The atomic bombs were dropped over Hiroshima on August 6, 1945, and over Nagasaki on August 9, 1945. On August 28, 1945, a plan was drawn up for the study of atomic bomb casualties. A mission from the Manhattan Project was assigned to the determination of the residual radioactivity in the bombed cities. Considerable assistance was obtained from the Japanese Government groups who had already made preliminary observations, and at the suggestion of the Supreme Commander there was appointed a "Joint Commission for the Investigation of the Effects of the Atomic Bomb in Japan." The report of this commission, summarized in part in the article of Liebow, Warren, and De Coursey (1), provides the most comprehensive survey of the terrain, the physical characteristics of the land, and the medical and biological effects on the population, including many illustrations and eye-witness accounts.

A résumé of the Joint Commission's report is beyond the scope of this survey, but it is noteworthy that the casualties were divided into mechanical injuries, thermal injuries, and injuries from ionizing radiations. Mechanical injuries were those resulting from falling timbers and flying debris; injuries with glass particles from shattered window panes were especially frequent. Such injuries were sustained at distances of at least 4,000 meters from the hypocenter and were due to the blast of the bomb. Thermal injuries were caused either by radiant heat, in which case the heat was intense but lasted for only a fraction of a second, or by flame burns. The effects of radiant heat were evident in the form of burns up to 4,000 meters from the hypocenter, but rarely did they result in second-degree burns at a distance greater than 3,000 meters. Being of short duration they produced characteristically a "profile" type of burn with protection of structures not in a rectilinear projection from the bomb. They also produced relatively more superficial charring and less deep penetration in comparison with flame burns. They further produced curious configurations according to the clothing which was being worn at the time; thus burns often showed patterns when the overlying clothing had been of varying thickness, and when clothing was of a light and dark design, the

burns, selectively under the dark portions, often reproduced the design on the skin with remarkable fidelity. The flame burns resulted either from the spontaneous ignition of the clothing by the radiant heat or from the general conflagration that followed the bombing. Most of the early deaths, that is, those occurring within the first ten days, were due to mechanical or thermal injuries.

The injuries from ionizing radiations were theoretically attributable to any or all of the following forms of energy: visible rays, ultraviolet rays, gamma rays and neutrons; the only significant source was direct radiation from the bomb at the time of the explosion. It is thought that induced radiation on the ground or deposition of fission products was insufficient to have had a harmful effect. It is not clear what effect the visible and ultraviolet radiations had on the body as a whole, but reference will be made to possible ocular effects subsequently. Most of the radiation effects were due to neutrons and gamma rays, and what the varying effect was of each is probably of academic interest only. Although the proportion of neutron to gamma rays is known to decrease as a function of distance from the bomb, information on the absolute amounts of energy of each is not publicly available.

It is commonly stated that the spectrum of electromagnetic radiations resulting from the bomb had the same general distribution as that of the sun. The peak effects of the radiation became evident at ten days to two weeks after the bombing and were manifest by epilation, purpura, and drop in white blood count. A host of other symptoms were also frequent (diarrhea, anorexia, fever, and so on), probably attributable to radiation but hard to separate from the results of the unsanitary conditions following the bombing.

The effect of shielding was, of course, of prime importance in determining the type of lesion; no doubt it was responsible in large measure for the diversity of lesions produced. Those who were in the open at the time of the explosion were exposed to radiant heat and ionizing radiation; those who were protected by wooden buildings were not exposed to radiant heat but were exposed to ionizing radiations; while those who were in concrete buildings were relatively protected from both.

The ocular effects of the atomic bombings have already been the

subject of numerous publications.¹ The first report was apparently that to the Section of Preventive Medicine of the West Kyushu Military District by Matsuoka (2), ophthalmologist of the Japanese Army rescue squad sent to Hiroshima on August 9, 1945. Of 492 patients within two kilometers of the hypocenter, 453 had conjunctivitis, 3 had burns of the eyelashes, and one had infiltration of the cornea. No lesion of the eye was found attributable to the direct effect of the blast. Case reports of atomic bomb effects on the eye followed by Hata (3) on perforation of the eye with glass and separation of the retina by contusion; by Shoji (4) on cataracts occurring within a few weeks after the explosion and presumably due to the direct effect of the blast; by Ikui (5, 6) on ectropion of the lid from burns of the face and on concussion cataract; and by Oyama and Sasaki (7) on burns of the cornea and retina. A brief report on the acute effects of the Hiroshima eye casualties was also given by Yoshimoto (8) and Shoji (4).

The first ocular study of any considerable series was made by Tamura, Ikui, Nakano, Hiwatashi, and Oshio (9), on patients from the Nagasaki area who were within two kilometers of the hypocenter at the time of the explosion. The acute effects noted were: (1) thermal burns of the eyelids which were remarkable in leaving a minimum of scarring; (2) keratoconjunctivitis lasting only a few days and presumed to be due to ultraviolet radiation; (3) iridodialysis, luxation of the lens, hemorrhages in the retina and vitreous, and separation of the retina, all resulting from the direct effect of the blast; and (4) injuries by foreign bodies of which glass splinters predominated. Effects coming on 10-14 days after the bombing were noted in patients with radiation sickness and consisted of hemorrhages in the lids, conjunctiva, and retina, and occasionally infiltration and necrosis of the cornea. The retinopathy, consisting of exudates as well as hemorrhages, was especially noteworthy as it was found in 22 of 115 patients on whom ophthalmoscopic examination was done.

These same authors made a patho-histologic study (10) of 48 eyeballs removed from 29 persons who had died 20 to 40 days after the atomic bombing of Nagasaki. Most of them died of bacteremia

¹ For the sources of reference in the Japanese literature, we are indebted to Dr. Ikui.

complicating radiation sickness. Colonies of bacteria were frequently found in the retinal vessels and occasionally free in the retina. The retinal hemorrhages were not remarkable, and it was noteworthy that there was no evidence of disease in the retinal vessels. The white spots which had been seen clinically had their histologic counterpart in cytoïd bodies (associated with hemorrhages), collections of white blood cells, colonies of bacteria, and albuminous material. Separation of the retina of slight degree was occasionally found, mainly in the posterior segment but also adjacent to the ora serrata. The choroid was frequently infiltrated with monocytes, plasma cells, and lymphocytes, and contained bacterial colonies in the vessels and free in the tissue. The colonies were sometimes, but not always, associated with cellular reaction. Necrosis of the cornea and adjacent conjunctiva was present in one case. Vacuoles in the equatorial region of the lens were found in six cases, and the nuclei of the equatorial cells which lay beneath the capsule were degenerated in two cases with evidence of swelling and disintegration of a thin layer beneath the anterior and posterior capsules.

While the foregoing study has not been published, six of the specimens from this study were subsequently reported by Schlaegel (11) with the additional observation that there was slight thickening of the posterior capsules. An analogous pathohistologic study was made by Miura (12), but this report was not available to us. A further pathohistologic study has been made by Helenor Wilder (13).

The only instance of burn of the retina to have been reported is that of Oyama and Sasaki.² Their patient was searching the sky at the time of the flash, looking for the airplane. She had no immediate visual symptoms, but 30 minutes later developed severe pain in the eyes, photophobia, and swelling of lids. She was hospitalized for one month but was not seen by an ophthalmologist at that time. The acute symptoms had subsided at the end of the month, and on examination she was found to have symmetrical opacification of the lower half of both corneas and a central scotoma of both eyes, most dense in a ring shape corresponding to the six to

² See (7), p. 5, note 4.

eight degree isopters. The fundi at first showed a grayish white zone, one-third the size of the disc, on the temporal side of each macula, and obliteration of the normal paramacular ring reflex. The fundi subsequently cleared up, but the scotomata were permanent.

Benkwith (14) described in detail an instance of retinal hemorrhage with radiation disease, and Hirose (15) found retinal hemorrhages in 62 of 164 patients with presumed radiation sickness. Tanaka (16) reported a staphyloma of the cornea resulting from an ocular injury caused by the atomic bomb and suggested that its pathogenesis was similar to the keloid formation elsewhere in the patient's body. The retinopathy associated with radiation sickness has been described also by Flick (17), with the additional observation that the changes were reversible.

Up to the time of the present writing no delayed cataracts have been reported in the literature, but one of the patients described in the present manuscript is being currently reported at the Kyushu Ophthalmological Society meeting (September 23, 1949) by Hirose (18), and two additional cases of radiation cataract in the present report have been recognized by and called to our attention by Ikui.

PATIENTS

The patients were divided into the following classifications:

Group I: Survey Cases. (a) The 1,000 patients making up this group were drawn at random from a list in the census files of persons within 2,000 meters of the hypocenter and in the "open" at the time of the atomic bomb explosion. The age distribution of this group and the distribution as a function of distance from the hypocenter are presented in Figs. 1 and 2. (b) A supplementary survey was made of all available persons listed at the present time in the ABCC census files as being within 1,000 meters of the hypocenter (exclusive of the 14 patients included in the previous group). This amounted to 231 persons. The distribution as a function of age and distance from the hypocenter is presented in Figs. 3 and 4.

Group II: Non-survey Cases. The patients making up this group were reached by means other than the random sampling of the survey group. Some were reached through local ophthalmologists,

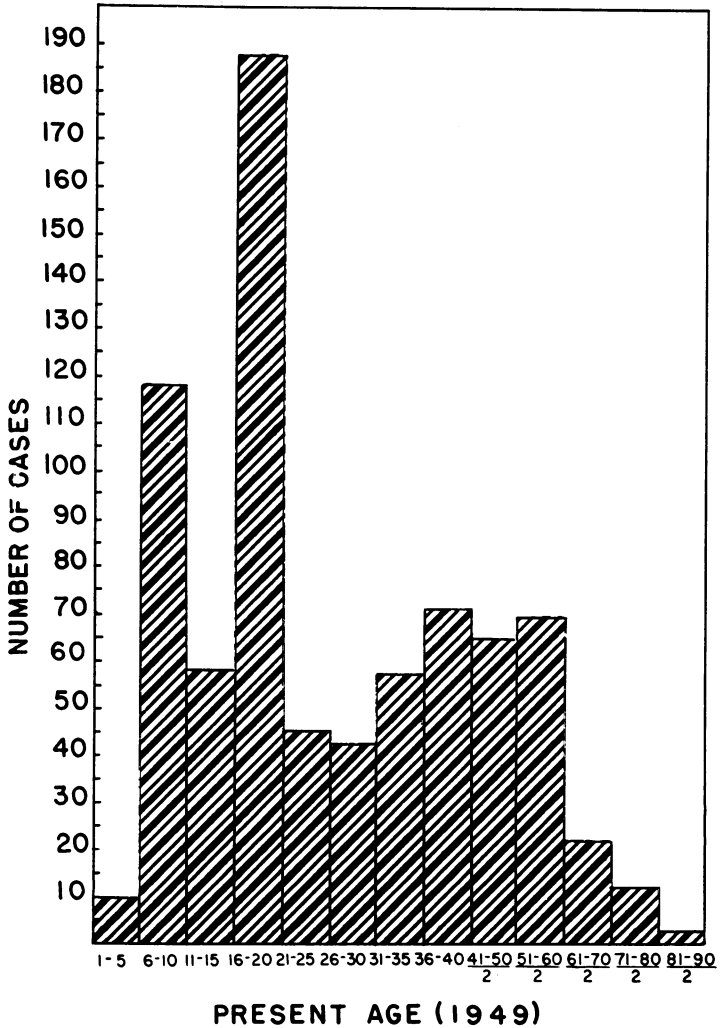


FIGURE 1. DISTRIBUTION BY AGE, 2,000-METER SURVEY

some through referrals and from other ABCC clinics, some others through newspaper publicity, and some were called in. From this group were separated those who were thought to have ophthalmologic lesions attributable to the atomic bomb.

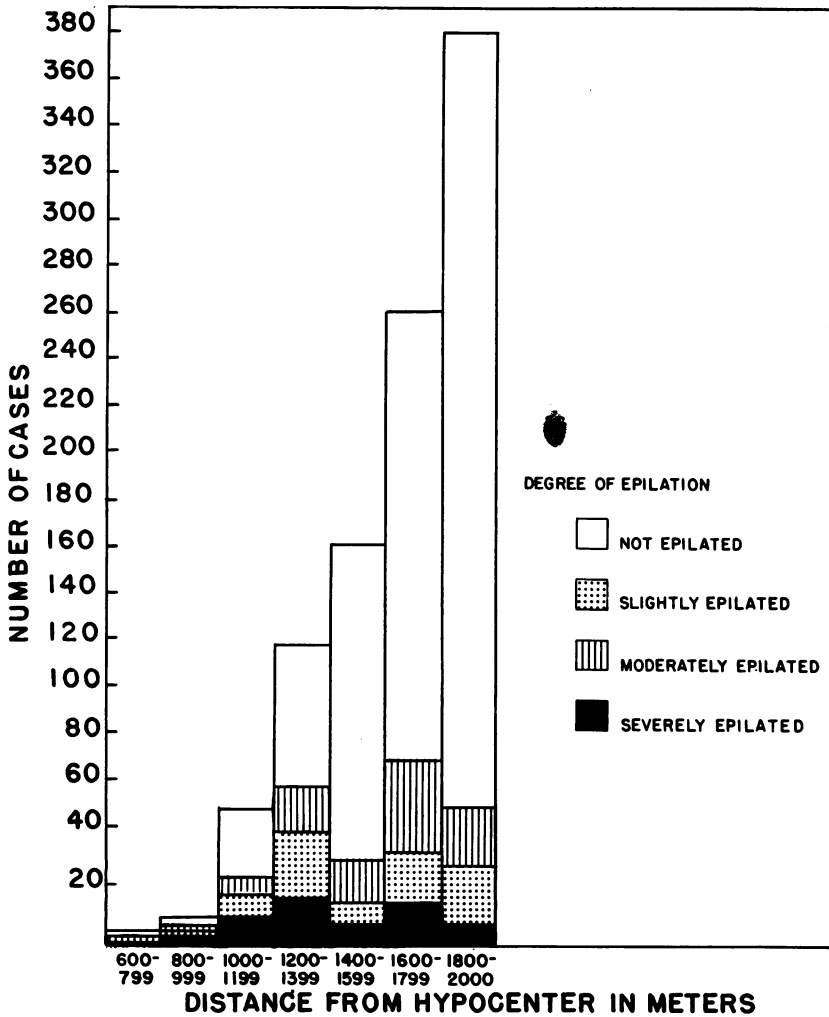


FIGURE 2. EPILATION, 2,000-METER SURVEY

RESULTS

GROUP I (a)

Survey of 1,000 patients within 2,000 meters of hypocenter (including fourteen within 1,000 meters).

A. Subjective Visual Phenomena

Practically everyone was aware of a bright flash of light, likened by many to a magnesium photoflash, followed, according to most observers,

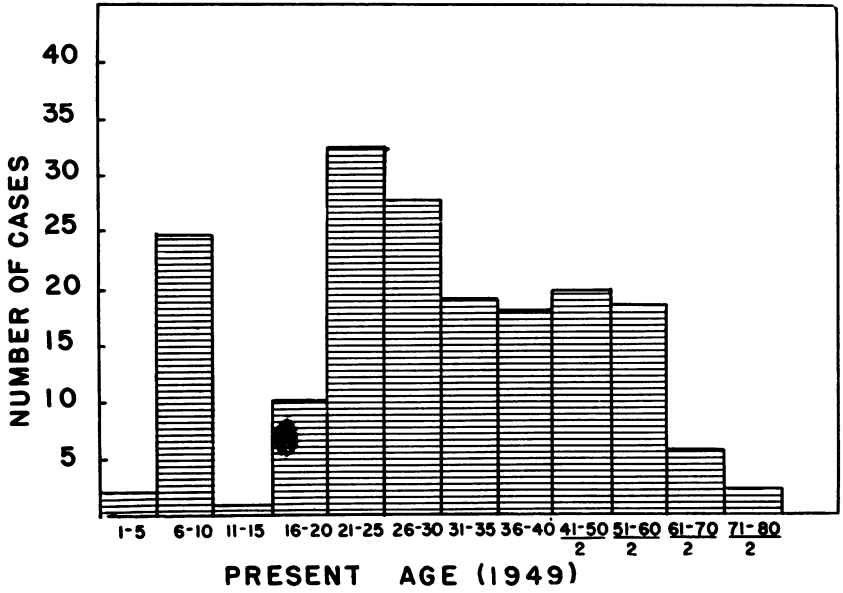


FIGURE 3. DISTRIBUTION BY AGE, 1,000-METER SURVEY

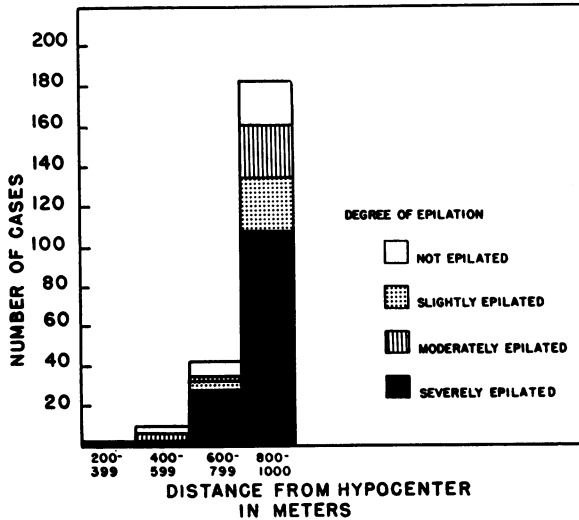


FIGURE 4. EPILATION, 1,000-METER SURVEY

by a period of darkness lasting several minutes. The darkness was described variously as "black cloud," "smoky vision," or "yellow light." A few did not recall seeing the flash but were aware of the subsequent darkness. Despite the darkness, most believed their vision was normal at the time and none gave a description of seeing visual patterns such as might be expected with after-images. It seems likely, therefore, that the darkness described after the explosion was due to atmospheric conditions rather than to a disturbance in the visual apparatus.

Many patients stated that they were blind for some time after the explosion, but in most instances this was due either to swelling of the lids from burns with consequent closure of the eyes, or to keratitis and not to any neuroretinal lesion. However, one patient became temporarily blind in association with headache, followed by loss of consciousness ten days after the atomic bomb. The findings in this patient are now entirely normal. Another patient who developed gradual loss of vision, beginning one month after the atomic bomb and progressing to the present, showed advanced optic atrophy. The lesion is presumed to be intracranial and not related to the atomic bomb. One other patient developed difficulty in vision three days after the atomic bomb in association with amnesia and confusion. Three patients in whom the present examination of the eyes revealed no abnormality gave a history of partial loss of vision in both eyes occurring about one month after the atomic bomb and lasting two to four weeks. There was no marked radiation sickness in any of these three, and in only one was there severe epilation and burns.

No patients in the survey group developed permanent central scotomata, although several were allegedly looking in the direction of the bomb at the time of the explosion.

B. Keratoconjunctivitis

The number of patients who gave a history of bilateral keratoconjunctivitis, within a few days or a few weeks after the atomic bombing and not obviously caused by trauma or burns, was 56. Of these, 42 gave a history of keratitis (as photophobia, foreign-body sensation, lacrimation, or redness) coming on within the first day and lasting for several hours or several days. These patients were 1,200 to 2,000 meters from the hypocenter. In none were there permanent sequelae. Discounting a few who believed they had symptoms for as long as a month, the cause of this early and temporary keratitis was presumably the ultraviolet radiation, for a similar history of keratitis is known to result from exposure to other sources of ultraviolet radiation. This is in keeping with the observation of some of the Japanese ophthalmologists who treated such persons within the first few days after the bombing. Presumably there were many more with keratoconjunctivitis from ultraviolet radiation

but in whom the ocular symptoms were masked by the thermal injuries.

A history of delayed keratitis was obtained in fourteen cases, symptoms coming on within the first week in eight patients, within the first month in four, and after several months in two. The symptoms lasted from several days to several months. The distances of the three patients from the hypocenter were between 1,100 and 2,000 meters. In none were there permanent sequelae. How much these cases represent a delayed keratitis due to radiation and how much to other causes cannot be stated with any conviction.

While 56 patients thus gave a history of some sort of keratitis following the atomic bomb as far out as the periphery of the zone studied, it is surprising that there were not sufficiently severe exposures to produce permanent corneal opacities, in view of the severe burns of the face that so many received. Thus, approximately one-quarter of those in the series gave a history of burn of the face with loss of skin and often burn of eyebrows and eyelashes, and yet had normal corneas at the present examination. None had permanent corneal opacities attributable to ultraviolet or infra-red radiation. The reason for this sparing of the eyes is not apparent. The blink reflex would certainly not have been rapid enough. One factor may have been the naturally narrow palpebral fissure in the Japanese with the protective overhanging of the upper lid. It is also conceivable that some measure of protection against the long infra-red rays may have been afforded to the eye, in comparison with the skin, by the fluid film that covers the eye.

It is also noteworthy that no case was found showing evidence of xerosis of the cornea or conjunctiva such as is occasionally found following severe x-ray or gamma ray exposure.

C. Lens Changes

Abnormalities of the lenses were noted in 81 persons, in none of whom were the findings considered to be due to radiation. In four additional persons there were abnormalities of the posterior capsule or adjacent cortex which, while thought not to result from radiation, were considered to show morphologic changes that suggested the radiation type. In none of the persons in the 1,000-2,000 meter survey series was an unquestionable case of radiation cataract found.

Of the 81 persons with lenticular abnormalities, 38 had senile cataracts of the predominantly cortical type, and 12 of the predominantly nuclear type; 18 had isolated opacities in the embryonic nucleus or outlining the Y sutures; 8 had coronary cataracts; 5 had one or more bluish, lacelike opacities situated on, or in the embryonic nucleus; 3 had lamellar cataracts; one had a unilateral posterior polar cataract in association with high myopia; one had a unilateral collar button cata-

ract in association with an old lesion of the cornea; one had congenital cataracts with microphthalmia; and one had a congenital white membrane on the anterior capsule.

The characteristic changes that make up radiation cataracts will be discussed subsequently. The fact that none occurred in this series suggests that the frequency at present is less than one in a thousand. It is entirely possible, however, that some of this same group will develop cataracts in the future, as it is well known that the latent period for radiation cataracts may be a decade or longer.

The absence of exfoliation of the lens capsule may also be noteworthy in view of the large amount of infra-red radiations to which the eyes of some of the patients must have been exposed.

D. Neuroretinal Lesions

No lesions were found in the fundus which were thought to have been directly related to the atomic bomb. Two persons, of 75 years and 60 years respectively, had degeneration of the central retina, but neither person had been looking at the sky at the time of the explosion and only one of them had symptoms of radiation sickness and epilation. They were thought to have senile macular degeneration. A third patient with normal visual acuity had some mottling of the central portions of the fundus. One patient gave a history of intermittent amblyopia beginning before the atomic bomb explosion, but the objective findings were normal.

One patient had a unilateral hole of the macula in association with high myopia, and three patients had evidence of an old chorioretinitis. Only eight patients had hypertensive and arteriosclerotic changes in the retinal vessels, and in all of these the changes were mild; none had a vascular retinopathy. Two had a bilateral optic atrophy, due in one case to methyl alcohol poisoning³ and of undetermined cause in the other but presumably associated with an intracranial lesion. One patient had a unilateral optic atrophy and aberrant regeneration of the third nerve following a perforating injury of the cheek. One patient had a vertical and horizontal nystagmus following cerebral concussion. These last two cases were the only ones attributable to the atomic bomb.

E. Miscellaneous Ocular Findings

While of doubtful significance in reference to the atomic bomb, the following abnormalities were noted in the survey patients and are included here merely for the sake of completeness.

Trichiasis unassociated with entropion: 14 cases. Thirteen of these

³ This patient stated that when the atomic bomb struck Hiroshima he felt the end of the world was at hand and consequently decided to make his exodus in as pleasant a frame of mind as possible. Hence he took a large amount of alcohol.

patients were children, and the trichiasis was associated with considerable epiblepharon in all cases. The lashes of the inner aspects of the lower lids were usually the ones responsible and therefore caused contact with the cornea when the eye was adducted. Only in two of the patients was there also involvement of the lashes of the upper lids. In three patients there was considerable keratitis epithelialis and some pannus formation in the lower inner angle of the cornea, but it was noteworthy that the trichiasis had caused surprisingly little subjective disturbance.

Ptosis (unilateral): 1 case.

Dacryocystitis: 2 cases.

Trachoma (quiescent and active): 13 cases. As the palpebral conjunctiva was not examined in all patients, it is probable that many more had trachoma than is here indicated.

Pterygium: 12 cases.

Inflamed pingueculum: 3 cases.

Keratitis (inactive), type unspecified: 16 cases. Herpetic: 1 case; phlyctenular: 1 case; traumatic: 3 cases; interstitial: 4 cases; epithelialis: 2 cases; ophthalmia neonatorum: 1 case.

Miscellaneous corneal abnormalities: one case each of white ring of cornea, senile marginal thinning, microcornea, and crocodile shagreen to posterior surface of cornea.

Argyll Robertson pupils: 1 case.

Albinism: 1 case.

Persistent hyaloid remnant: 1 case.

Asteroid hyalitis: 2 cases.

Phthisis bulbi: 1 case.

Myopia: No record of the presence or absence of myopia was kept for the entire survey group, but in a sample of 155 cases unilateral myopia was found once, bilateral myopia of 1.00 to 3.00 diopters was found in 7 (4.5 percent) and of 3-14 diopters in 4 (2.5 percent). Thus the incidence of myopia greater than one diopter was found for this small group to be of the order of 7 percent.

F. Non-ocular Findings

Observation was made on patients of the survey series as to burns of the face, epilation, and radiation sickness. Some burn of the face occurred in 394 patients, with loss of the skin of face in 256. Burns of the lids occurred in a considerable, although undetermined, number of these patients. Yet the residual scarring of the lids and of the face was surprisingly slight. Ectropion of the lids was found in four patients only. Practically all of the burns were of the flash type and presumably had shown considerable charring without deep penetration.

Epilation, for our purposes, means loss of head hair, eyebrows or eye-

lashes and may have been an immediate occurrence resulting from heat or a delayed occurrence (usually 10 to 18 days) resulting from the ionizing radiations. It may, of course, be both immediate and delayed owing to the conjoint effect of thermal and ionizing radiations, but in this case the delayed effect would be obscured by the immediate burns. Immediate burns of the head with loss of scalp hair, eyebrows, or eyelashes were noted in approximately 200 patients. In many, only the eyebrows and eyelashes were burned. Delayed epilation of the scalp hair was recorded as partial in 160 cases and practically complete in 65 cases (Fig. 2). Delayed epilation of the eyebrows occurred in 22 cases and of the cilia in 16 cases. The duration of the epilation in the cases in which it was complete varied from several weeks to six months. No correlation was found between the duration of the epilation and the distance of the patient from the hypocenter.

While the entity of radiation sickness is well defined, it is not easy to separate some of its manifestations from infections not necessarily associated with radiation. Thus anorexia, malaise, nausea, vomiting, diarrhea, fever, and even petechiae which, along with reduction in the white blood cell count, make up the entity of radiation sickness may result from such unsanitary conditions as prevailed following the atomic bombing and are not necessarily due to the radiation. Without, therefore, knowledge of the white blood cell count during the critical few weeks following the bombing, it seems futile to attempt any evaluation at this late date of the presence or severity of the radiation sickness. Suffice it to say that approximately one-half of the surveyed persons gave a history of fever and gastrointestinal disturbances and approximately one-tenth gave a history of petechiae at some time during the first few weeks following the bombing.

GROUP I (b)

Survey of 231 patients within 1,000 meters of the hypocenter, comprising the total available number of persons listed at present in the ABCC census files as having been in this area at the time of the explosion (exclusive of the fourteen included in the previous group).

A. Subjective Visual Phenomena

Of the patients in whom the objective findings were normal, 25 stated that they had impaired vision at, or within a few weeks following, the time of the explosion, but in only two cases was this thought to be significant in respect to the atomic bomb. The complaints of the others were thought to be due to presbyopia, myopia, senile cataracts, or senile macular degeneration, having no causal connection with the atomic bomb. Of the two patients who were thought to have had visual

complaints attributable to the atomic bomb, one had had poor vision with "black clouds" before the eyes, and one complained of "red vision." In both instances, the visual difficulty had come on approximately three weeks after the bombing in association with radiation sickness (fever, pharyngitis, and petechiae) and the complaints of both are presumed to have been caused by retinal and vitreous hemorrhages.

B. Keratoconjunctivitis

Five patients stated they had symptoms of bilateral keratitis (photophobia, lacrimation, foreign-body sensation) coming on within the first day after the explosion, and lasting two or three days. These were presumably due to ultraviolet radiation. In one other patient with similar symptoms the condition lasted three weeks, but inasmuch as this patient also had extensive burns of the face it was possibly a thermal injury rather than abiotic. Six patients also gave a history of keratitis coming on 3 to 4 weeks after the explosion and lasting for several days (in one patient) or one or more months (in the other patients). All of these patients had symptoms of radiation sickness, and the cause of the keratitis was presumably the ionizing radiations.

C. Lenses

Abnormalities of the lenses were noted in 20 patients of this series. Eight had senile cortical cataracts. Seven had congenital opacities situated in the lens nucleus; one had an anterior polar opacity; one had several vacuoles in the anterior cortex; and five had posterior capsular cataracts which were believed to have been caused by radiation from the atomic bomb. These latter will be discussed subsequently, together with the cases of radiation cataract in Group II.

Five additional patients showed changes in the posterior capsules suggestive of the radiation type, but the changes were not sufficiently definite at the time to justify the diagnosis of radiation cataract. One patient had minimal posterior cortical opacities in the axial region of both eyes, with two vacuoles beneath the anterior capsule of the right eye. This patient had had no radiation sickness but did have complete epilation of scalp hair beginning, allegedly, three months after the atomic bomb and lasting three months. It seems altogether likely that this is an instance of incipient radiation cataract. Another patient showed a faint axial opacity in the right eye over a 1 mm. zone with two scintillating reflections (possibly vacuoles) just in front of the posterior capsule of the right eye. The anterior capsule was normal. The left eye, which apparently had an injury or ulcer of the cornea, showed an opacity of the lower nasal quadrant of the cornea and a posterior synechia, but the lens was clear. The patient had had no radiation sickness but had been almost completely epilated for four months. This is also thought to be a possible instance of early radiation

cataract but, if true, the unilaterality of the posterior capsular opacity is surprising. Three patients showed either haziness and irregular reflexes from the posterior capsule or a few subcapsular vacuoles that were thought to be borderline abnormalities. These patients will be examined again at a later date.

D. Neuroretinal Lesions

Two patients in this group had bilateral macular degeneration and one had unilateral macular degeneration. One other patient had a unilateral coloboma of the choroid; one patient had retinitis pigmentosa; one patient had optic atrophy of undetermined origin; and three patients had mild hypertensive and arteriosclerotic changes in the retinal arteries.

E. Miscellaneous Ocular Findings

Four patients in this group were noted to have shown trachoma and one patient had had a perforating injury of the eyeball.

F. Non-ocular Findings

Burns of the face which were sufficiently severe to result in loss of skin occurred in only ten patients of this series. In the two-kilometer survey group the incidence of comparable burns was more than five times as great, a difference which is undoubtedly explained by the fact that almost all of the survivors within the one-kilometer range had some form of shielding from the thermal effects of the bomb.

On the other hand, the percentage in the one-kilometer group who were epilated was much greater than in the two kilometer group (see Fig. 4). Sixty percent were recorded as completely epilated in the one-kilometer group, but only slightly more than 4 percent for the two-kilometer group. The duration of the epilation in those in whom it was said to have been complete was less than one month in 8; from one to two months in 25; from two to five months in 49; from five months to one year in 18; and, allegedly, longer than one year in 12. The duration was not known in 9.

The difficulty in evaluating radiation sickness has already been discussed. Of the 231 patients in this series, 205 gave a history of delayed malaise, gastrointestinal symptoms, or pharyngitis, which might be interpreted as radiation sickness. One hundred and nineteen gave a history of petechiae coming on within the first few weeks after the explosion.

GROUP II

This was made up of persons who were reached through local ophthalmologists, through newspaper publicity, or through hearsay. It is, therefore, a highly selected group, and the incidence of

disease in this series gives no indication of the frequency in the population at large. In only a small number was there thought to be any causal connection with the atomic bomb.

The cases seen who gave no history or findings suggestive of association with the atomic bomb are listed according to diagnosis as follows:

Normal: 101.

Lids and lacrimal apparatus: Dacryocystostenosis: 1; ectropion (upper lid): 1; trichiasis (epiblepharon): 4; trichiasis (trachoma): 1; chalazion: 1; trachoma (active): 3; vernal conjunctivitis (lids): 3.

Extraocular muscles: Nystagmus: 2; strabismus: 3; chronic progressive ophthalmoplegia externa: 2.

Conjunctiva and cornea: Catarrhal conjunctivitis: 3; vernal conjunctivitis (bulbar): 1; rupture, Descemet's membrane (birth): 1; interstitial keratitis: 5; phlyctenular keratoconjunctivitis: 1; leucoma: 1; sclerokeratitis: 1.

Lens: Senile cataract: 4; diabetic cataract: 1; coronary cataract: 1; nuclear sclerosis: 1; secondary cataract: 1; congenital cataract: 1; exfoliation of lens capsule: 1.

Retina and optic nerve: Central serous retinopathy: 1; macular degeneration: 1; separated retina: 2; retinitis proliferans (Eales' disease): 1; retinitis pigmentosa: 3; retinitis punctata albescens: 1; optic atrophy (probably methyl alcohol): 2.

Uvea: Iritis: 3; uveitis: 1; Harada's disease: 1.

Eye as a whole: Ametropia: 16; chronic glaucoma: 2; phthisis bulbi: 1; congenital microphthalmos: 2.

The patients in the non-survey group who were believed to have had lesions resulting from the atomic bomb are discussed in the following paragraphs, arranged according to the headings used in the description of the survey cases. It should be borne in mind that the evidence that the lesions in this group were in fact due to the atomic bomb depended on time relationships and morphologic characteristics, rather than on comparative statistics.

A. Subjective Visual Disturbance

The only patient falling into this category in the non-survey series was a 30-year-old man who was on the sixth floor inside a concrete building 450 meters from the hypocenter at the time of the explosion. Except for a mild burn of the ear, he had no symptoms until approxi-

mately three weeks after the explosion, when he became blind. At the same time he developed profound epilation and radiation sickness (including petechiae). His vision gradually returned two months later. At the time of the present examination, vision was 20/30 O.U. and the only objective findings were the presence of flocculent opacities in the lens having a lamellar distribution similar to that seen with congenital cataracts.

The cause of blindness in this patient is not evident, but it was obviously part of the radiation syndrome. The present cataracts are considered unrelated to the rest of the condition since similar changes are seen not infrequently in Japanese persons, and there were no changes in the posterior capsule such as occur with radiation cataracts.

B. Keratoconjunctivitis

While several patients in the non-survey group gave a history of a transient keratitis following the atomic bombing, only one showed residual opacities of the cornea thought to be attributable to it. This patient, previously reported by Oyama and Sasaki,⁴ was a 23-year-old girl who was 2,000 meters from the hypocenter gazing into the sky at the time of the explosion. She was knocked down by the blast but does not remember any visual disturbance until 30 minutes later when her lids became swollen from burns of her face and she could not see. For several days she had pain in the eyeballs, and the photophobia was severe. She was hospitalized for a month and the photophobia disappeared, but she was not examined by an ophthalmologist. She had no epilation, diarrhea, or fever. When examined two months after the bombing, she was found to have symmetrical opacities of the lower halves of both corneas. The distribution of the opacities was likened to a mountain with a rounded, sharply demarcated upper edge extending into the pupillary area and a less well-defined lower edge. The pupils were round, and the lenses were clear. The retina and visual fields showed abnormalities to be described subsequently. The patient was examined by us four years after the bombing and showed superficial and deep opacities in the lower portions of both corneas. They could just be seen grossly as patchy opacities but were conspicuous by slit-lamp examination. In other respects the eyes were normal.

C. Lens Changes

Ten cases of cataracts thought to be caused by ionizing radiation were seen. Five were patients in the 1,000-meter survey series. Two, including one in the survey group, were referred to us by Dr. Ikui and one by Dr. K. Hirose.⁵ Two other patients were seen by us because of

⁴ See (7), p. 5, note 4.

⁵ This case was reported at the Kyushu Ophthalmological Society meeting at Kumamoto, Sept. 23, 1949.

their complaints of failing vision (one was an employee of the ABCC!), and the tenth person, who had no visual complaint, was called in because she was known to have been with one of the other nine at the time of the explosion.

Nine of the patients were exposed at Hiroshima and one at Nagasaki. All were said to have had normal visual acuity prior to, and for some time after, the bombing. Seven were males and three were females. The ages at the time of the exposure were 13 to 55 years. All were within 550 to 950 meters of the hypocenter at the time of the explosion. Three were standing together in the forward part of a street car. Four were in wooden houses roofed with tile. One was crouching behind a wooden building; one was walking in the street, shielded by the plastered wall of a building; and one is not known to have had any shielding. Two had thermal burns of the profile type (that is, from radiant heat); all had epilation of the head after a latent period of one to four weeks, with complete baldness lasting three to five months. Six had vomiting on the day of the explosion, and eight had symptoms one to three weeks after the explosion consisting of fever and malaise; five had vomiting and diarrhea and five had petechiae. One developed a sloughing lesion of the buccal mucosa and another a localized necrosis of the cheek with perforation. Whether these were caused by radiation sickness or by the unsanitary conditions prevailing at the time could not be determined. One of the three female patients had had amenorrhea since the explosion and the other two began their menses at ages 17 and 19 which was approximately three years after the explosion.

The only ocular complaint of the patients was failing vision. The onset of subjective visual symptoms was said to have been as early as one month after the bombing in one patient, but the patient was in an apprehensive mental state at the time and it is by no means certain that this initial complaint was due to incipient cataracts. The latent period of visual symptoms in seven other patients was 6 months, in one patient; $2\frac{1}{4}$ years, in one; and $2\frac{1}{2}$ years, in five. Three patients had had no ocular complaints. The failure of vision was said to have been either gradual or step-wise and fluctuant in the seven patients, one of these patients having thought some improvement followed each loss.

The cataracts consisted of opacities in the axial zone of the posterior lenticular capsules over an area of 2 to 4 mm., with occasional punctate dots farther toward the periphery. The findings were approximately symmetrical in the two eyes. The central opaque discs had jagged but nevertheless relatively sharp edges. In the five patients in whom the changes were most marked, the peripheral portions of the opaque discs were denser than the central portions, forming doughnut-shaped opacities when examined with the ophthalmoscope. With the slit-lamp biomicroscope the opacities were of a lacelike texture having a few poly-

chromatic crystals and a few vacuoles. The opacities were confined to the posterior capsules with no apparent extension into the underlying cortex, but the vacuoles were situated just in front of the capsules. In the two most advanced cases there was a distinct separation of the opacity centrally into two laminae from front to back with a relatively clear interval between them. Toward the periphery of this central disc the two laminae fused to form a denser ring corresponding to the doughnut-shaped opacity seen with the ophthalmoscope. In the less advanced cases which did not show the doughnut configuration, the central portion showed an opacification of the whole thickness of the posterior capsule similar to the peripheral portion of the disc in the more advanced cases. Thus it appears that progression of these cataracts is accompanied by a separation of the central opacity into two layers, separated by a clear interval, and an extension of the unsplit opacity toward the periphery. The anterior capsule also showed a few punctate dots in seven of the patients and an occasional vacuole in three. The lens cortex and nucleus, however, was entirely clear in all cases.

The cataracts are considered to be similar to those which have previously been associated with exposure to x-rays and gamma rays (19). What part neutrons played in their pathogenesis is not evident. The patients were in a zone where neutrons and gamma rays were present, although information on the amounts of each is not publicly available. Most persons in this zone died either from thermal or mechanical injuries or from radiation sickness. That these persons survived and developed cataracts may have been due simply to biologic variations; but it cannot be reasonably denied that, while the cataracts were the result of exposure of the head region, the absence of lethal radiation disease may be explained by a shielding of much of the rest of the body. Five of the patients had very little, if any, radiation sickness, and it is not impossible that the symptoms in the others may not have been caused by radiation. Yet all of them had profound epilation of the head, which was undoubtedly a radiation effect. It is possible that the three standing in the front of the street car were protected in the lower halves of their bodies by the metallic baseboard below the car windows and by the shielding from other persons.

Aside from the foregoing cases with outright posterior capsular cataracts, several border-line cases were seen that were thought not to represent radiation cataracts but in which final judgment will be postponed until further examination, six months or one year hence. These cases represented an unusual amount of marking of the posterior capsules and none showed opacification that was visible by ophthalmoscopic examination.

Aside from these cases which are thought to be normal variants, a few patients were seen with abnormalities in the posterior capsule that

were nevertheless not attributed to radiation. One patient was a 17-year-old diabetic boy who had been 2,000 meters from the hypocenter at the time of the explosion and had had no burns, epilation, or radiation sickness. Examination at the present time showed diffuse opacification of the posterior capsule and anterior capsule in the axial regions and extensive bluish-white opacities in the anterior and posterior cortex of both lenses. The presumptive diagnosis was diabetic cataracts.

The normal posterior capsule may be likened to a layer of glass immersed in water and having a varying amount of etching of its surface. The etching is usually most evident in the axial or periaxial region and can be seen by focal illumination as dots and threadlike lines. Often they are arranged like the tracks made by wind-blown beach grass on the otherwise smooth sand. They are most evident on the posterior surface of the capsule and presumably represent remnants of the hyaloid system. By transillumination, the posterior capsule often shows optical irregularities in the axial and periaxial regions similar to the "warts" on the posterior surface of the cornea.

D. Neuroretinal Abnormalities

Approximately ten persons gave a history of having been gazing at the sky at the time of the explosion, some at the airplane and at least one at the parachute carrying the bomb, but only one person showed any possible evidence of retinal or nervous system damage. This patient (7), the same one who was previously referred to with keratitis, was a 23-year-old girl who had been 2,000 meters from the hypocenter and was gazing skyward but does not know whether or not it was in the direction of the bomb. At first there were no visual disturbances. When examined two months after the bombing there was a grayish-white opacity one-third the size of the disc just temporal to each fovea. By campimetry a central scotoma was found, most dense in a ring-shaped area occupying the 6 to 8 degree isopters. It was symmetrical in the two eyes. The visual acuity, which was known to have been normal before the bombing, was correctible to O.D. 0.6 (20/50) and O.S. 0.9 (20/30). Examination four years after the bombing showed similar bilateral ring-shaped scotomata, but no abnormalities were found in the fundus.

This patient is presumed to have had an infra-red burn of the retina and was the only patient seen on whom such a diagnosis was made.

One other patient in the non-survey series had retinitis proliferans in one eye. The patient is said to have lost her vision in this eye immediately after the atomic bomb, presumably from a vitreous hemorrhage, although there was no known trauma.

E. Miscellaneous Ocular Findings

Perforation of the globe, frequently with loss of the eye, or phthisis

bulbi, was seen in 21 patients, in four of whom it was bilateral. In practically all cases the injury was caused by glass and in many cases it was accompanied by multiple scars of the lids and face. For some reason which is not apparent, these scars often had a distinct blue color. That it was glass rather than any inherent characteristic of the scar formation that caused this discoloration is suggested by the fact that burn scars and surgical scars in the Japanese show no similar pigmentation. The possibility that the discoloration was simply due to dirt that had been carried into the wounds could not be excluded, but its uniformity and the absence of granular texture made this possibility unlikely.

Iridodialysis resulting from the bomb was seen in one patient and is presumed to have occurred from a blow with some blunt object rather than from the blast.

Two persons who had had evidence of brain injury at the time of the bomb had complicating eye signs, one with bilateral sixth nerve paralysis and one with optic atrophy.

Pupillary areflexia was found in one eye of a patient who had been blind for several days after the explosion. She is presumed to have had an intraocular hemorrhage at the time.

GENERAL OBSERVATIONS ON JAPANESE EYES

Since, to our knowledge, no comparable examination has been reported on a large number of normal Caucasian eyes, the following observation may have little comparative significance. The data is, therefore, not presented statistically, but rather as our impression of certain differences between Japanese eyes (presumably applicable to all Orientals) and Caucasian eyes.

Trichiasis in association with epiblepharon is so frequent in Japanese children that it may be considered a normal variant. The responsible lashes are usually those in the inner portion of the lower lid and produce keratitis and occasionally pannus in the lower nasal quadrant of both corneas. It is not accompanied by scarring of the lids or by entropion. The subjective disturbances caused by the trichiasis are variable, but it was noteworthy that there was no case in which these symptoms were as marked as might be expected, and often there were no symptoms at all. In view of the fact that the condition was found almost exclusively in children, it is presumed that it becomes outgrown.

Staphylococcal and rosacea keratitis was conspicuous by its rarity in comparison with our experiences in the United States. Acne of

the face also appeared much less common. Trachoma, on the other hand, was frequent, being present in 5 percent to 10 percent of the patients examined. Pterygia and conspicuous pinguecula were perhaps somewhat more frequent than in at least some parts of the United States (Northeast) and it appeared that the pinguecula were situated closer to the limbus than is the case with Caucasian eyes, often actually overriding the cornea. One case of incipient pterygium in a heavily pigmented eye is perhaps especially noteworthy because of its possible significance in the pathogenesis of pterygia in general. Just in advance of the spearhead of the pterygium was a 1 mm. zone of flat pigmented epithelium suggesting that epithelium had grown over from the limbus in advance of the pterygium.

Vernal conjunctivitis of both bulbar and palpebral type appeared more common than in a comparable group in the United States.

Evidence of arteriosclerotic or hypertensive vascular disease was rare, but Eales' disease in young persons was relatively frequent. Only two instances of primary glaucoma were seen, and by inquiry among ophthalmologists this seems to be relatively infrequent in Japan.

Probably occurring in Caucasian eyes also, but being less evident, is the depigmentation of the pigment epithelium of the fundus with age and with high myopia. This leads regularly in the seventh decade to an exaggeration of the tessellated appearance of the fundus.

SUMMARY AND CONCLUSION

Previous reports of ocular lesions resulting from the atomic bomb have been concerned chiefly with traumatic injuries and retinal complications of radiation sickness. The present study was undertaken with the prime motive of determining what, if any, delayed injuries to the eyes had resulted from the atomic bombing.

Accordingly, 1,000 persons who were listed as having been in the "open" and within two kilometers of the hypocenter at the time of the explosion were selected at random from the census files of the Atomic Bomb Casualty Commission for study. In addition, 231 others, comprising the total available number of surviving persons listed at present in the census files as having been within one kilo-

meter of the hypocenter, were examined, as were several hundred others who were contacted through newspaper publicity, referrals from local ophthalmologists, or through hearsay.

The survey resulted in bringing in persons having, or having had, a variety of ocular conditions. Those connected with the atomic bomb included the following diagnoses: multiple injuries of eyes and eyelids; keratoconjunctivitis from ultraviolet and ionizing radiations; thermal burn of the cornea and of the retina; retinitis proliferans; and radiation cataracts. The cataracts were the only delayed manifestations of ocular injury from the atomic bomb.

Ten cases of radiation cataract were found. They all occurred in persons who were within one kilometer of the hypocenter and who were either in the "open" or protected by a wood or plaster wall. All had a delayed and entire loss of scalp hair, but did not necessarily have radiation sickness. The ages at the time of exposure were between 13 and 55. Three were females and seven were males.

The lens changes consisted predominantly of granular opacification of the posterior capsules in the axial zone. The mildest cases showed simply an asterisk-shaped central opacity, not more than 1 mm. in diameter, having several subcapsular vacuoles. The more marked cases showed, with the ophthalmoscope, a discoid opacity of the posterior capsule, having a characteristic doughnut shape with a relatively more translucent zone in the central 3-4 mm. region. With the slit-lamp biomicroscope the opacity was seen to be made up of granules forming a lacelike pattern and containing many scintillating highlights and occasional polychromatic reflections. In the more marked cases the opacities appeared to be split from front to back with a relatively clear lamina between the opaque layers. This clear lamina, which had a thickness equal to or several times that of the posterior capsule, was generally seen in the region corresponding to the translucent portion of the doughnut. In the early cases, before the lamination occurs, the greatest opacification of the capsule is to be found axially, but as the splitting takes place the greatest opacity extends progressively toward the periphery, forming the characteristic doughnut-shaped reflex. Whereas the posterior opaque lamina coincides with the posterior surface of the lens, the anterior lamina may bulge for-

ward, but it is nevertheless sharply demarcated from the underlying cortex. It does not show the extension into the cortex which is seen with the usual cataracta complicata and posterior polar cataracts. Vacuoles situated just beneath the posterior capsules are frequently found even in the mildest cases.

With the more advanced changes, fine opacities are also to be found in the anterior capsule and in the anterior subcapsular zone. Here they are often accompanied by vacuoles.

The latent period for the subjective disturbances resulting from the cataracts is about two years. The progress is slow and sometimes step-wise. Objective findings may antedate the subjective findings. The frequency of radiation cataracts is at present of the order of $2\frac{1}{2}$ percent of survivors within the one kilometer zone, but since the latent period may be many years, it is obvious that the frequency may increase considerably in the years to come.

The occurrence of radiation cataracts is thought to be significant not only on account of their ocular implications but more especially because they are the first delayed effects of the atomic bomb to have been demonstrated in the body as a whole.

REFERENCES

1. Liebow, A. E., Warren, S., and De Coursey, E.: Pathology of atomic bomb casualties, *Am. J. Path.*, 25: 853, 1949.
2. Matsuoka, H.: unpublished.
3. Hata, B.: Injuries to eyes by atomic bomb, *Nippon Rinsho* 3, Nos. 11-12, 1945.
4. Shoji, Y.: Injuries of eyes by air attacks, *Ganka Rinsho Iho*, 40: 1, 1946.
5. Ikui, H.: A case of ectropion of lid after burns of the face by atomic bomb, *Ganka Rinsho Iho*, 40 (2): 21, 1946.
6. Ikui, H.: A case of contusion cataract by blast of atomic bomb, *Ganka Rinsho Iho*, 40: 21, 1946.
7. Oyama, A. and Sasaki, T.: A case of burn of the cornea and retina by atomic bomb, *Ganka Rinsho Iho*, 40: 177, 1946.
8. Yoshimoto, R.: Ocular injuries from air attacks (abstract), *Ganka Rinsho Iho*, 41: 15, 1947.
9. Tamura, S., Ikui, H., Nakano, K., Hiwatashi, R., and Oshio, S.: Ocular lesions from the atomic bomb, *Ganka Rinsho Iho*, 40: 99, 1946.
10. Tamura, S., Ikui, H., Nakano, K., Hiwatashi, R., and Oshio, S.: unpublished.
11. Schlaegel, T. F.: Ocular histopathology of some Nagasaki atomic bomb casualties, *Am. J. Ophth.*, 30: 127, 1947.
12. Miura, H.: Pathohistologic examination of eyes of atomic bomb disease, *Acta Soc. oph. jap.*, 51, Nos. 5-6, 1946.
13. Wilder, H.: Appendix to Pathology Section, Joint Commission Report (unpublished).

14. Benkwith, K. B.: Retinal hemorrhages as seen in atomic bomb casualty, *Am. J. Ophth.*, 29: 799, 1946.
15. Hirose, K.: Changes in ocular fundus with atomic bomb disease (abstract), *Ganka Rinsho Iho*, 42: 26, 1948.
16. Tanaka, Y.: Staphyloma corneae, especially keloid-like thickening of the cornea by the atom bomb, *Niigata Igakkai Zasshi*, Vol. 61, no. 6, 1947.
17. Flick, J. J.: Ocular lesions following the atomic bombing of Hiroshima and Nagasaki, *Am. J. Ophth.*, 31: 137, 1948.
18. Hirose, K.: A case of cataract probably caused by the atomic bomb. Abstract to be published in *Ganka Rinsho Iho*, Vol. 44 (1950).
19. Rohrschneider, W.: Untersuchungen über die Morphologie und Entstehung der Röntgenstrahlenkatrakt beim Menschen, *Arch. f. Augenh.*, 106: 221, 1932.