

CHANGES IN THE EYE AND ORBIT FOLLOWING CAROTID LIGATION

BY *Kenneth C. Swan*, M.D., AND (BY INVITATION)

John Raaf, M.D.*

STRIKING OCULAR AND ORBITAL CHANGES result from development of a communication between the carotid artery and cavernous sinus. These changes, their pathogenesis and course, have been the basis for many publications. For example, Sugar and Meyer (1) reviewed nearly 800 reported cases. An appreciable number of these cases were treated by ligation of one or more carotid vessels but the possibility that ocular changes might follow this treatment apparently has received little attention. This ligation affects a transition from increased venous pressure in the orbit and eye to a state of markedly reduced arterial pressure. Such a marked alteration in vascular pressure might be expected to induce profound ocular and orbital changes; therefore, a comparison of pre-operative and postoperative findings in patients with carotid-cavernous sinus communications might be of physiologic as well as of clinical significance.

In recent years we have observed eight patients who had developed communications between the cavernous sinus and the carotid arteries following trauma to the head. The most consistent symptoms were diplopia or confusion of vision and a pounding sensation in the head. Temporal displacement of the globe in the orbit and a unilateral pulsating exophthalmos varying from three to eight millimeters were noted. Gross pulsation of the eyeball was not present but some forward movement of the globe with each systole could be readily seen in the mirrors of the Hertel exoph-

* From the Departments of Ophthalmology and Surgery, University of Oregon Medical School.

thalmometer. Varying degrees of limitation of rotations of the globe were present, but tests of concomitance made on an ophthalmograph indicated that this was due to mechanical obstruction from orbital engorgement rather than to paresis or paralysis of individual muscles. The exophthalmos was invariably associated with marked engorgement of the conjunctival vessels and some edema of the orbital tissues.

Auscultation of the affected side of the head revealed a metallic sounding bruit in all patients. It is commonly stated that this bruit is heard most plainly when the stethoscope is placed on the temple; however, in our cases it could be heard most clearly when the bell of the instrument was placed over the closed lids.

Sugar and Meyer (1) stressed the fact that glaucoma may develop in an appreciable number of patients with carotid-cavernous sinus communication. Repeated tension determinations were possible in six of our patients. In one patient whose symptoms were of short duration, there was no detectable difference in tension of the two eyes. In three an increase in the ocular tension varying from 7 mm. to 20 mm. Schiötz was found on the affected side. In the fifth patient diagnosis of glaucoma seemed justified by an ocular tension of 32-36 mm. Schiötz in the eye on the affected side as compared to an ocular tension of only 15-17 mm. Schiötz in the opposite eye. There was some bedewing of the cornea, partial mydriasis, and a diminished pupillary light reflex. The tension in this eye was reduced to within normal limits by the administration of pilocarpine but remained higher than in the opposite eye. In the sixth patient, the communication had been of many years duration. On the affected side, ocular tension was 60 mm. Schiötz, and the eye was blind.

It was possible to study the fundus of five of our patients under high magnification with a binocular ophthalmoscope. Definite papilledema was noted in only one patient. In the remaining patients there was increased capillarity of the optic disk. The capillary network in the macular region was much more prominent than in the opposite eye. Also the retinal veins on the affected side were considerably engorged, and the pulsations with systole were conspicuously lessened. In one case there were two small striate

hemorrhages observed along the course of one of the larger veins. Corrected visual acuity and fields were normal in all patients.

Spontaneous closures of carotid-cavernous sinus communications occur but are rare. In most cases the annoying bruit and diplopia persist. The patients may gradually lose vision in the affected eye and in some instances the second eye may be involved through extension of the arterial pulsation to the opposite cavernous sinus. For these reasons surgical therapy seems justified in persistent cases and was undertaken in six of our patients.

One of us (J.R.) has developed a technique of exposing the carotid vessels in the neck under local anesthesia and determining the patient's tolerance to carotid closure by clamping the common carotid artery for 30 to 45 minutes with a rubbershod forceps (2). If the patient tolerates this obstruction the common and external arteries are ligated on the affected side. The external carotid is ligated; otherwise, reversal of flow through this vessel might feed blood into the internal carotid and reduce the effectiveness of ligating the common carotid. This double ligation was performed in five of our patients without immediate loss of vision or neurologic symptoms other than transitory numbness on one side of the body. In the sixth patient only the internal carotid was ligated.

All six patients were immediately relieved of the pounding sensation in the head. Some regression of the exophthalmos became apparent within 48 to 72 hours, but in three patients some exophthalmos and dilatation of vessels have persisted.

In five patients postoperative studies of ocular tension were possible. Hypotony developed within the first hours after the operation. Twenty-four hours after ligation ocular tension varied from 10-13 mm. Schiötz as compared to 16-22 mm. Schiötz on the unoperated side. This hypotony lasted from three to six weeks in four patients but was still present after six months in the fifth case. In this patient, dilatation of the iris vessels became apparent at six weeks. Six months postoperatively these vessels were dilated and an increased protein was evident in the aqueous. Gonioscopy revealed no definite synechia but the details of the meshwork were obscured inferiorly.

Studies with the binocular ophthalmoscope were possible post-

operatively in five patients. In all, the diameters of the retinal arterial vessels were reduced 25-50 percent as compared to the opposite eye. Many terminal arterial elements which had been readily visible preoperatively seemed to have disappeared. Also there was marked diminution of the pulsation in the large vessels around the nerve head. In contrast to the marked contraction of the arterial tree, dilatation of the veins persisted, although it was less marked than before surgery.

In three patients, a striking retinopathy developed in addition to the marked changes in the retinal vessels. Cotton-wool patches became apparent in the macular region and around the nerve head about 80-90 hours after carotid ligation. These increased in number and size and were most conspicuous eight to ten days post-operatively. The cotton-wool patches were associated with edema of the macula and some cyanosis of the fundus (see Fig 1). These three patients noted the onset of blurred vision beginning two to

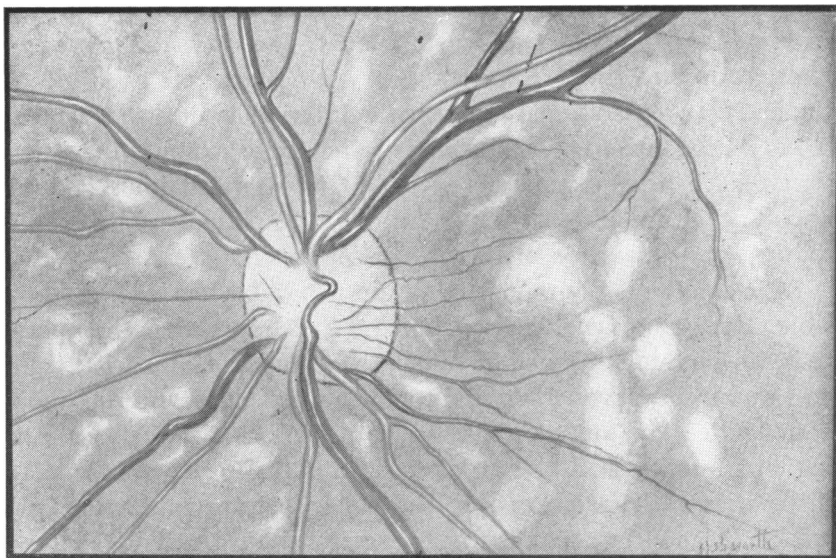


FIGURE 1. EDEMA AND CYANOSIS OF RETINA, VENOUS CONGESTION, DIMINISHED ARTERIAL PULSATION, CONTRACTED ARTERIAL TREE, AND COTTON-WOOL PATCHES DEVELOPING AFTER UNILATERAL LIGATION OF THE COMMON AND EXTERNAL CAROTID ARTERIES

five days postoperatively. Corrected visual acuity was reduced to 20/100 to 20/200 at the height of the retinopathy.

In two of the three patients, the striking retinopathy began to clear three to four weeks after surgery. The cotton-wool patches gradually faded, leaving focal areas of capillary dilatation and aneurysm formation. The latter vascular changes were visible only under the high magnification of the binocular ophthalmoscope. The edema gradually cleared and visual acuity returned to normal three to four months after surgery. Cyanosis of the retina disappeared but the contracted arterial tree remained. In both of these patients, ocular tension returned to normal, but in one a faint subcapsular lens opacity became apparent six months after operation. It progressed slowly over a period of another six months. In the third patient with retinopathy the cotton-wool patches cleared, but macular edema was still present six months after operation and visual acuity improved to only 20/50. This was the patient who had the persistent hypotony and developed changes in the iris and anterior chamber.

DISCUSSION

The symptoms and signs of the carotid-cavernous sinus communication can be attributed to increased pressure and transmission of the arterial pulsation directly into the orbital and ocular veins. As noted by Sugar and Meyer (1), it is quite remarkable that increased intraocular pressure has received so little attention, particularly as it has been established both by clinical observation and from experimental ligation that venous obstruction leads to increased ocular tension. A frank glaucoma was present in only two of our patients, but we did not have the opportunity to observe any of the other patients for more than a few months after the onset of symptoms. If the venous obstruction is partial, the rise in ocular tension may not occur for weeks or months. Glaucoma may be a major factor in the blindness that gradually seems to develop in many of these patients if the condition is untreated. Increased intraocular pressure may also account for the relative infrequency of the gross papilledema in these cases. It was present in only one of our patients.

Of the more than 800 reported cases of carotid-cavernous sinus communication only five or six have had simultaneous ligation of the common and external carotid vessels as was performed in our patients; however, it is unlikely that the retinopathy and hypotony that we have described are peculiar to this procedure. These changes might be expected to follow any marked drop in the arterial pressure in the eye and orbit. It is understandable that the retinopathy and hypotony might be overlooked or given little attention because care of these patients generally is conducted by neurosurgeons independently of ophthalmologists. Furthermore, the retinopathy does not seem to become conspicuous until several days after the surgery.

The ocular effects of carotid ligation have been studied considerably less than those of venous obstruction, but it has commonly been stated that the intraocular pressure bears no direct relationship to pressure in the ophthalmic artery. Barany (3) has ligated the carotid vessels in the rabbit and has observed a decrease in ocular tension. This decrease lasted only a few days and then gradually returned to normal in spite of a persistently lower arterial pressure in the eye. From this observation he concluded that ultrafiltration does not play an appreciable role in formation of the aqueous. The ocular hypotony which developed in our patients persisted for at least a month in all patients and in one patient it was still marked after six months.

Our tension studies could not be compared directly with those of Barany because in our patients there was the additional factor of markedly increased venous pressure at the time of carotid ligation; however, they do confirm his observation that a dramatic drop in pressure in the ophthalmic artery is accompanied by ocular hypotony, but the ocular tension slowly may return to the level of the opposite eye despite the permanently lowered arterial pressure. That this compensation did not occur in one of our patients indicates that there may be a minimal level of arterial pressure below which normal ocular hydrodynamics cannot be maintained.

Pathogenesis of the retinopathy is of considerable interest. The predominant lesion was the cotton-wool patch. In these cases at

least, lesions do not form suddenly with exudation of fluid; rather they seem to evolve over a period of three to six days. In one of our patients it was possible to observe development and regression of several cotton-wool patches. They began as focal areas of retinal pallor and an unevenness of the surface reflections. The involved area gradually acquired the characteristic fluffy cotton-wool appearance over a period of three to five days. The gray-white patches gradually cleared over a period of weeks, leaving areas of capillary dilatation and aneurysm formation. These were readily visible only under the high magnification of the binocular ophthalmoscope. Friedenwald (4) described similar capillary changes in the microscopic sections made parallel to the retinal surface. The evolution and course of the cotton-wool area in our patients following carotid ligation, therefore, support his contention that they are infarcts from reduced blood flow. Also the fact that these lesions did not acquire their characteristic fluffy appearance for several days would seem to support Christensen's (5) contention that they represent a "fibrinoid" type of degeneration of the ground and cement substance rather than a simple collection of edema fluid. The latter might be expected to collect within a few hours.

There are many other aspects of our cases which merit discussion. For example, there is much that could be learned by pre-operative and postoperative studies of alterations in ocular tension induced by pressure on the globe. In this report we have hoped to stimulate interest not only in this condition but to call attention to the opportunity which it provides for studying the influence of marked alterations in the vascular pressure on the function of the eye.

SUMMARY

The ocular and orbital findings in eight patients with carotid-cavernous sinus communications are briefly reviewed. In addition to the well-known sign of pulsating exophthalmos and ophthalmoplegia, elevated ocular tension was found in five out of six patients in whom tension determinations were made. In one patient a subacute glaucoma was present, and in another patient with long-

standing untreated communication a blind glaucomatous eye was found on the affected side. It is suggested that glaucoma may be an important factor contributing to blindness in untreated cases. Also it seems that the apparent ophthalmoplegia in these patients may be due simply to orbital engorgement.

Five of our patients were treated by simultaneous ligation of both external and common carotid arteries on the affected side. All were relieved of their major symptoms of diplopia and bruit. The exophthalmos was improved in all but did not completely subside in three. Postoperatively, there was hypotony and diminished volume and pulsation of the retinal arterial tree. In three patients a striking retinopathy developed several days postoperatively. This was characterized by a slight cyanosis of the retina, macular edema, and multiple cotton-wool patches. This retinopathy gradually cleared in two of the patients leaving only focal areas of capillary dilatation and aneurysm formation; but hypotony, retinal edema, and hemorrhages have persisted for six months in the third patient. These changes are discussed in relation to the vascular physiology of the eye and pathogenesis of cotton-wool patches.

REFERENCES

1. Sugar, H. S., and Meyer, S. J.: Pulsating exophthalmos, *Arch. Ophthalm.*, 23: 1288, 1940.
2. Raaf, J., and Swan, K. C.: Traumatic carotid cavernous sinus aneurysm, *Am. J. Surg.*, 80: 816, 1950.
3. Barany, E.: Influence of local arterial blood pressure on aqueous humor and intraocular pressure, *Acta Ophthalm.*, 24: 337, 1946.
4. Friedenwald, J. S.: A new approach to severe problems of retinal vascular disease, *Tr. Am. Acad. Ophthalm.*, 53: 73, 1948.
5. Christensen, L.: Ocular pathology in collagen diseases, *Tr. Am. Acad. Ophthalm.* Not yet published.

DISCUSSION

DR. FRANCIS HEED ADLER. Dr. Swan's and Dr. Raaf's communication gives us further evidence that in human beings, as in rabbits, the formation of aqueous humor, and therefore the maintenance of intraocular pressure, is mediated by mechanisms which are much more complex than simple filtration, presumably a mechanism such as Dr. Friedenwald has postulated. The next thing of importance to me in the paper is the fact that a retinopathy developed in these patients similar in most respects to what we ordinarily associate with hypertensive disease.

Dr. Swan stated the arteries were very much narrowed, and I would like to ask him whether, in the illustration that we saw, the narrowing was focal as well as general. It looked to me as if some of the vessels showed focal constriction, but the arteries were all narrowed, and in addition to that hemorrhages and cotton-wool patches were seen. This suggests the development of a hypertensive retinopathy in this condition and that the mechanism for producing the retinopathy is anoxia. We have two bits of evidence which point that way: the first is that the hypertensive state alone does not produce a retinopathy; we have cases of coarctation of the aorta in which the blood pressure in the arterial tree is elevated, and here no retinopathy occurs, and here with the lowered pressure and narrowed arteries a retinopathy occurs. It is a matter of blood flow, which when sufficiently impeded, dilates the capillaries. These then leak protein and we have hemorrhages and exudates.

DR. ARTHUR J. BEDELL. Some statements made by the authors need further elucidation. One refers to the retinopathy.

In the photograph of the left eye of a patient with spontaneous pulsating exophthalmos on the right side, there is no evidence of retinopathy. In the right eye a glaucomatous cup is seen through the hazy lens. At no time were there any cotton-wool spots.

The next case is a traumatic pulsating exophthalmos involving the right side. There was marked exophthalmos, pulsation, and bruit. Looking at the photograph of the left fundus you can readily see the distribution of the vessels and the very slight papillary and peripapillary edema. In the right fundus the edema is more marked, causing a loss of definition of the disk outline but no cotton-wool spots.

The photograph of the last case shows the extreme proptosis of the right eye after ligation of the common carotid. There is immense dilatation of the blood vessels on both sides of the face, particularly in the temporal regions, and yet even with this extensive and prolonged change no cotton-wool spots ever developed.

I have not seen a retinopathy in pulsating exophthalmos and trust the authors will speak more about its frequency.

DR. FRANK B. WALSH. In these cases of Dr. Swan's and Dr. Raaf's, the matter of retinopathy seems to be of particular interest. It is also interesting that the surgical technique is different from that which has been employed in a fair number of cases I have seen in which only the internal carotid artery is tied off. By going over Dandy's work and some previous experimental investigations, it has been shown that the anastomotic supply to the ophthalmic artery through the branches of the external carotid is tremendous. In the cases I have observed a retinopathy immediately after the operation was not a characteristic

feature. Because of the suddenness of the onset of this retinopathy, I believe, as I think Dr. Swan and Dr. Adler both believe, that it reflects some type of obstructive mechanism to the blood supply of the retina.

DR. KENNETH C. SWAN. I sincerely appreciate the discussion and the different points of view brought out.

Dr. Adler has called attention to the similarity of this retinopathy to that observed in hypertension. There is one striking difference. In hypertension we do not see a marked decrease in pulse pressure, whereas diminished pulsation of the retinal arterial tree is marked in the fundus following carotid ligation. I agree with Dr. Adler that diminished blood flow may be the common factor causing cotton-wool lesions in the two conditions.

In answering Dr. Bedell, I want to emphasize that the retinopathy occurred in only three of the five patients in whom the double ligation was made. Also, the retinopathy may be transitory, coming on a few days after the operation, and disappearing after a few weeks in two of the three patients; therefore, it could be easily overlooked.

I was particularly pleased to have Dr. Walsh express an opinion. We have not had the opportunity to study a control series in which only the common carotid or the internal carotid were tied, so that we cannot draw conclusions as to whether the double ligation may be responsible for the striking retinopathy and hypotension which we observed. There is a possibility that they may not occur when only the common or internal carotid vessels are ligated.