

have given these patients amino acids and attempted to run protein tests on them afterward, without being able to come to any conclusions. The diet must be given in large amounts, almost to the point of distraction of the patient; unless you have a very good patient it is difficult to make them adhere to any of these high protein diets, because they resent them and don't like the taste of them, so it has been a very difficult problem to maintain this experiment on any sort of good scientific basis. I am sure we can select certain types of lens changes and routinely send them to the laboratory and expect to find from them certain specific proteins that apparently are off their base. Much more work will have to be done, but at least this is a start, and I hope others will take the next step.

---

## DIFFUSE MALIGNANT MELANOMA OF THE IRIS. REPORT OF TWO CASES

SHALER RICHARDSON, M.D.

Jacksonville, Florida

A survey of the literature offers convincing evidence of the rarity of primary malignant melanoma of the iris. The number of recorded cases is estimated by Duke-Elder<sup>1</sup> at 150 and by Doherty<sup>2</sup> at about 175. It is generally stated that of malignant melanomas in the uveal tract, 85% occur in the choroid, 9% in the ciliary body and 6% in the iris. McKee<sup>3</sup> observed that this ratio is somewhat proportional to the amount of uveal pigment present.

Usually circumscribed, this lesion of the iris may be diffuse, and it may also be pigmented or unpigmented. Although the descriptive literature is often not explicit enough to make differentiation between the circumscribed and the diffuse types clear, the diffuse tumor appears to be extremely rare. Recently, Wilder<sup>4a</sup> stated that there are 7 instances of diffuse malignant melanoma of the iris in the files of the Army Institute of Pathology. In presenting 1 case in 1923, Li<sup>5</sup> was able to collect only 5 cases in the literature. Doherty<sup>2</sup> in 1939 included in his complete bibliography (1919-1937) but 5

additional cases, designated as ring sarcoma of the iris. Among the 263 cases of uveal sarcoma in Martin-Jones' recent comprehensive study,<sup>6</sup> there was 1 case of ring sarcoma. Two cases that came under my care within a period of 13 months are reported here.

#### NOMENCLATURE

Malignant melanoma of the iris is variously referred to in the literature as sarcoma, melanosarcoma and ring sarcoma. Malignant melanoma is, however, to be preferred. In the view of some authors, melanoma carries with it the connotation of malignancy, and nevus is applied to the nonmalignant pigmented tumor. Nevertheless, in ophthalmology there is need for the more exact definition of benign or malignant melanoma, for in the eye are present mesodermal melanoblasts, from which arise both benign and malignant tumors.<sup>7</sup> When not circumscribed, the malignant melanoma of the iris is appropriately described as diffuse or infiltrating. First differentiated by Fuchs,<sup>8</sup> this type came to be described as flat sarcoma, and in 1898 Ewetzky<sup>9</sup> suggested the term ring sarcoma, which seems to have the preference in the literature.

#### AGE AND SEX INCIDENCE

Most authorities are agreed that malignant melanoma of the uveal tract is more prone to develop in persons in the sixth decade. It has been noted, however, that in the iris this tumor occurs on the average some 10 years earlier than those in the ciliary body and choroid, at approximately 40 instead of 50 years. This conclusion is borne out in my cases. Wilder<sup>4b</sup> mentioned a series of 137 malignant melanomas of the iris in which 51 or 37% were from patients under 40 years of age, confirming Duke-Elder's statement that the average age of occurrence for tumors of the iris is lower than for the remainder of the uveal tract.<sup>1</sup>

Martin-Jones<sup>6</sup> concluded that this neoplasm of the iris occurs with greater frequency in women. Three of the 4 cases

in his recent series, including the 1 case of ring sarcoma, were in women, and he cited Pflüger's 23 cases with 15 in women and Treacher Collins' 18 cases with 10 in women. Five cases of ring sarcoma cited by Li<sup>5</sup> were in women, although his 1 case was not, nor was Bruner's case.<sup>10</sup> In 1 of my 2 cases the patient was a woman.

#### ETIOLOGY

The method of origin of the malignant melanoma remains a matter of controversy. Opinions vary as to whether it arises from endothelium, epithelium or chromatophores. In contradistinction to the epiblastic theory of Verhoeff,<sup>11</sup> there is the more recent neuroectodermal theory advanced by Masson<sup>12</sup> and supported by the later researches of Theobald.<sup>13</sup>

The role of injury in the etiology of this tumor is problematical, as is that of prolonged inflammation. It is, however, well known that benign melanomas of the iris undergo malignant changes and should rightly be regarded with suspicion. Martin-Jones<sup>6</sup> concluded that abnormal ocular pigmentation is an etiologic factor in some cases of sarcoma of the uveal tract, the evidence being more in favor of abnormal masses of pigmentation in the iris becoming malignant than those of the choroid.

Reese<sup>7</sup> concluded that a melanoma of the uvea may be malignant at one site and benign at one or several other sites, thus representing multiple origins of the tumor. Noting that the iris is a common site for the benign feature, he regarded this lesion of the iris as a diagnostic aid when observed clinically. He commented that the ring nature of a melanoma may be accounted for in part by multiple diffuse origins as well as implantation growths which logically occur around the filtration angle, where disseminated tumor cells in the anterior chamber would tend to gather. Too, he was of the opinion that an important difference between a localized malignant melanoma of the uvea with benign melanomas elsewhere and a diffuse and ring type of melanoma lies in a

malignant effect of the cancerigenic agent at one site and a benign effect elsewhere in the one case, and a diffuse, multiple malignant effect in the other cases.

#### PATHOLOGY

The cell types on which the classification of Callender<sup>14</sup> is based include spindle cell with subtypes A and B, fascicular, epithelioid, mixed and necrotic. From their study of 500 cases of malignant melanoma of the choroid and ciliary body, Callender, Wilder and Ash<sup>15</sup> concluded that the pure spindle cell types, particularly subtype A, are of a relatively low degree of malignancy, that an increased degree of malignancy is associated with the presence of epithelioid cells, and that a low degree of malignancy is usually associated with a heavy fiber content. Wilder<sup>16</sup> explained the observation that melanomas of the iris behave less malignantly than do those of the choroid on the ground that they are readily visible and consequently recognized earlier.

Whether the tumor starts at the root of the iris or in the region of the ligamentum pectinatum, these structures as a rule become rapidly involved. An increase in size denotes the extension in a definite pigmented nevus. If, however, the growth originates in the deeper layers of the iris near its root, it may spread beneath the stroma, causing discolorations varying from light yellow to dark brown. This type of growth tends to metastasize into the fibers of the ligamentum pectinatum and the canal of Schlemm, with resulting increased tension. Metastasis around the angle of the anterior chamber produces the diffuse or ring type of tumor.<sup>2</sup>

In its evolution the diffuse tumor is distinguished from the circumscribed variety by its slow growth with long preservation of vision and lack of objective signs, its diffuse infiltration of the uveal tract and the extent of its metastatic spread. Duke-Elder<sup>1</sup> estimated the length of the history from 7 months to 10 years and regarded it as the most conspicuous feature. In this connection it is of interest that in Bruner's

case,<sup>10</sup> the patient "had always noticed a little colored spot on the inner half of the iris." In Li's case,<sup>5</sup> there was a history of trauma 2 years previously. Of the cases collected by Li,<sup>5</sup> in Solomon's case,<sup>16</sup> the patient had observed for 20 years a speck on the iris gradually increasing in size; in Hanke's case,<sup>17</sup> the growth evidently antedated the failing vision of 9 months' duration by a considerable period; in Alt's case,<sup>18</sup> the patient had observed a spot on the iris for several years; in Levan's case,<sup>19</sup> a pigmented nevus was observed for several years with increase in size and several pigmented spots not noted previously appearing 1 year before removal of the eye; and in Pindikowski's case,<sup>20</sup> the patient had noticed the tumor for some time. In my cases, 1 patient thought that the affected eye had been discolored for several months, and the other patient had been aware of a dark brown spot on the iris of the involved left eye for many years with gradual change in color of the iris to dark brown over an indefinite period of years, the iris of the right eye being blue.

#### DIAGNOSIS

It may be impossible at first to distinguish between benign and malignant melanomas unless microscopic examination is made possible by iridectomy. The benign lesion characteristically attains a certain size and remains so, nor does it project much above the plane of the iris. Too, vascularization is uncommon in the innocent tumor. Beginning malignancy manifests itself clinically by an increase in size, varying discolorations in the same growth, an increased blood supply, an elliptical pupil and development of abnormal tension.<sup>2</sup>

Martin-Jones<sup>6</sup> observed that malignant melanoma of the iris may give rise in some cases to no subjective symptoms, being discovered only on routine examination; in other cases, the patient may seek advice because of a small brown or blackish spot on the iris, present as long as he could remember or since birth, and believed to be increasing in size. Extension of the growth over the pupillary margin may interfere with

vision, as may intra-ocular tension if the tumor grows sufficiently. Analysis of the pathologic reports in my cases would seem to indicate that the glaucoma was secondary to the infiltration of pigment and tumor cells into the filtration angle.

The position on the iris is a consideration of some importance in diagnosis. In the order of frequency, the lower half, the upper half, the inner segments and the outer segments are affected.

In differential diagnosis, inflammatory granulomas, especially tubercle and syphilis, are to be considered, as are secondary tumors and cysts. The flat diffuse lesion is sometimes mistaken for iridocyclitis. When the secondary glaucoma manifests itself, it is difficult to be sure that this condition is not primary.

#### PROGNOSIS

Despite the relatively slower progress of malignant melanoma in the iris, the prognosis is uncertain at best. There appears to be no time limit of safety. Even enucleation at an early stage does not preclude metastases, and after extra-ocular extension, fatalities rapidly increase. Infiltrating growths are more dangerous than the discrete variety.

Considering this tumor in the uveal tract as a whole, Martin-Jones<sup>6</sup> concluded that the case is quickly and invariably fatal if melanogen is present in the urine. It was not present in either of my cases. This author further observed that 27% of patients die within 3 years after operation, 36% within 5 years and 56% within 10 years; that the mixed cell type of growth is the most malignant; that the presence of malignant cells in the emissaria of the globe is not necessarily of bad prognostic import, in 58% of such cases survival reaching 5 years; that the prognosis in cases of extra-ocular extension is comparatively bad, 70% of patients dying from the disease within 5 years; and that in younger patients the prospect of survival from the disease is better than in those more advanced in years.

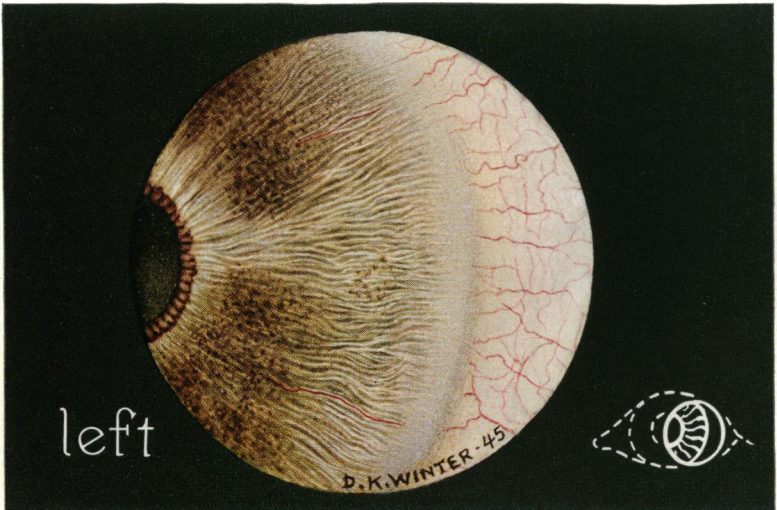
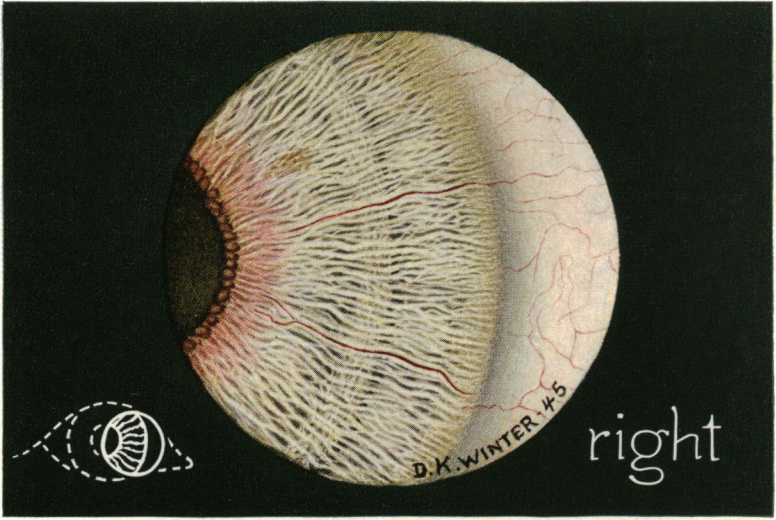


Fig. 1.—(Case 1).—Drawings of quadrants of iris. Right, the unaffected eye. Left, the affected eye.

The spindle cell type of lesion with a delicate nuclear structure gives the best and the round cell epithelioid and the mixed cell types the poorest prognosis. Also, the less dense the intercellular reticulum the graver the prognosis, according to Duke-Elder.<sup>1</sup> Their work on the prognostic significance of reticulin, or argyrophil, fibers led Callender and Wilder<sup>21, 22</sup> to conclude that there is an apparent connection between the reticulin content of the growth and the prognosis. Callender, Wilder and Ash<sup>15</sup> mentioned an apparent increased lethality with increased pigment content, but withheld a definite conclusion.

#### TREATMENT

Once the diagnosis of diffuse malignant melanoma of the iris is established, enucleation without delay is the treatment of choice. This extreme measure is the only procedure that offers relative safety. It would appear that exenteration does not increase the chance of survival in cases of extra-ocular extension.

There is apparently no evidence to justify radiation as a primary method of treatment. Some authors think it may have value as a postoperative measure.

#### CASE REPORTS

CASE 1.—Dr. A. J. O., a dentist aged 40, was examined on June 9, 1945. He complained of photophobia of 6 months' duration and a slight blurring of vision of the left eye of 7 days' duration. He stated that he had had no previous ocular trouble other than an astigmatism, for which glasses were worn, but he thought the left eye had been discolored for several months.

The vision in the right eye was 20/15, and in the left eye it was 20/20. The right eye was normal in all respects; the iris was light brown in color and without freckles (Fig. 1R). In the left eye, mild ciliary injection, sensitivity to light and mild edema of the corneal epithelium were present. The aqueous contained a few cellular elements, and with biomicroscopy the aqueous beam was hazy. The pupil was slightly dilated ovally, but reacted to light in its upper half. The iris was densely pigmented, its color being dark brown,



but in its upper segment a few islands showed no pigmentary changes (Fig. 1L). Below, there were 3 pigmented nodules rising slightly above the surface of the iris. Biomicroscopy showed dense pigmentation of the iris extending into the filtration angle. On the posterior surface of the cornea there were deposits of pigment. No new blood vessels were noted. Intra-ocular tension was for the right eye 19 and for the left eye 50 (Schiötz).

A 2½% solution of neosynephrine was instilled twice. The pupil dilated slightly above, but in the lower segment of the iris where pigmentation was heaviest, there was no dilation. The use of neosynephrine for dilation of the pupil was deemed necessary in order to examine the posterior chamber. The ocular fundus was normal; there was no cupping of the optic disk. The fields of vision were within normal limits.

The patient was told that in my opinion a malignant melanoma of the iris was present and that enucleation was imperative. Consultation was advised, and he was referred to Dr. A. B. Reese, who, in confirming the diagnosis, wrote me on July 27 as follows:

I agree most assuredly with you that Dr. O. has a malignant melanoma of the iris of the left eye. I do not feel there is any doubt at all about this. This melanoma is a flat, diffuse type which gives early glaucoma and is sometimes mistaken, particularly in the early stages, for iridocyclitis. I have seen 2 such instances, in which the eyes were operated on for secondary glaucoma. With the gonioscope I noted the angle over the lower 180° occluded by the tumor tissue.

The patient then returned to me. On August 2 the eye was enucleated, and a vitallium sphere was implanted in Tenon's capsule. The pathologic report made by Dr. J. A. C. Wadsworth of the College of Physicians and Surgeons, Columbia University, follows:

*Microscopic:* The sections are from an adult globe in which there is a heavily pigmented tumor of the iris and ciliary body which in its growth has involved the filtration angle (Fig. 2).

Near the base of the iris below is a loosely packed, heavily pigmented tumor mass which has spread diffusely throughout the iris and into the ciliary body. The tumor cells with their heavy pigment content can be seen clogging the meshwork of the angle and Schlemm's canal. On the posterior surface of the cornea near the angle below, a thin layer of tumor cells can be seen extending

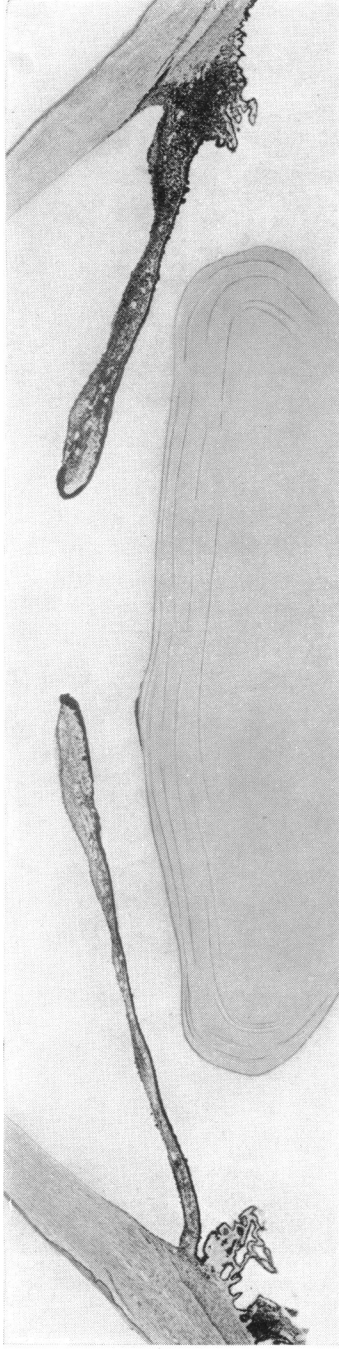


Fig. 2.—(Case 1).—Photomicrograph showing diffuse infiltration of the iris with tumor cells, extension to the ciliary body and involvement of the filtration angle.

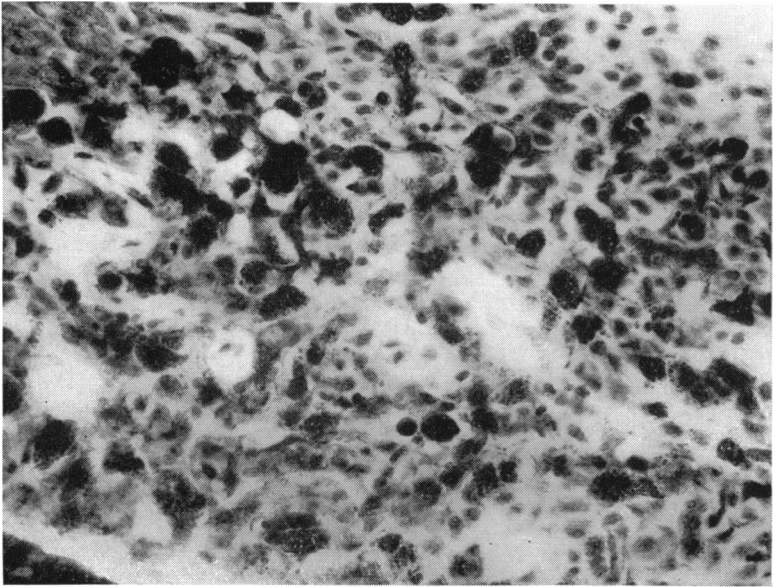


Fig. 3.—(Case 1).—Photomicrograph showing infiltration of the iris with heavily pigmented tumor cells; X 800.

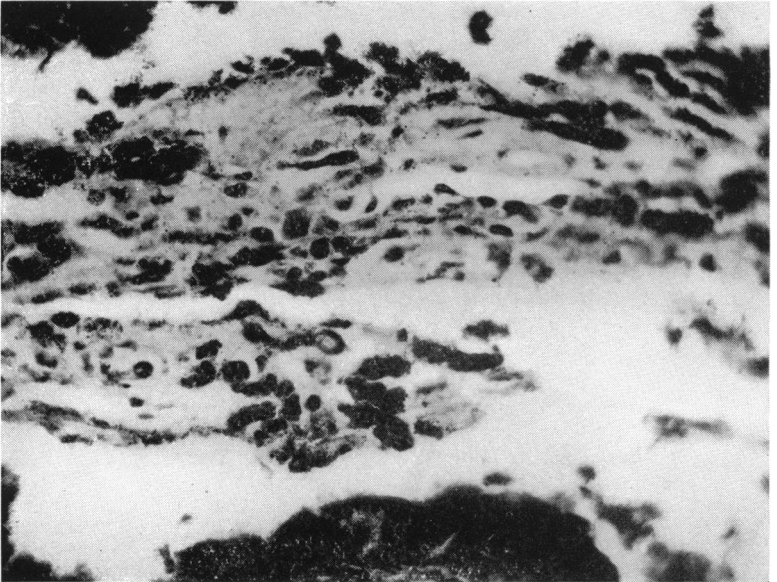


Fig. 4.—(Case 2).—Photomicrograph showing section of the iris removed by iridectomy for diagnostic purposes; X 800.

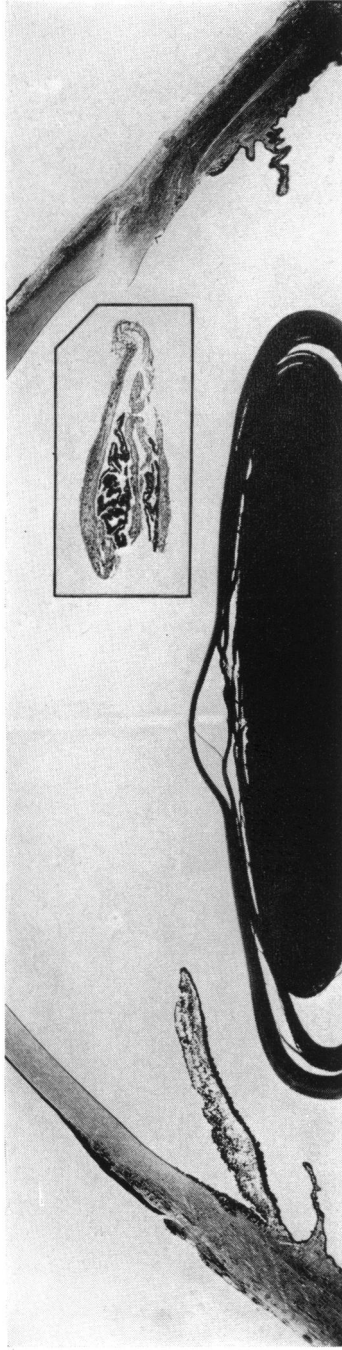


Fig. 5.—(Case 2).—Photomicrograph showing diffuse infiltration of the iris with tumor cells. Insert shows section of the iris removed for diagnostic purposes prior to enucleation of the eye.

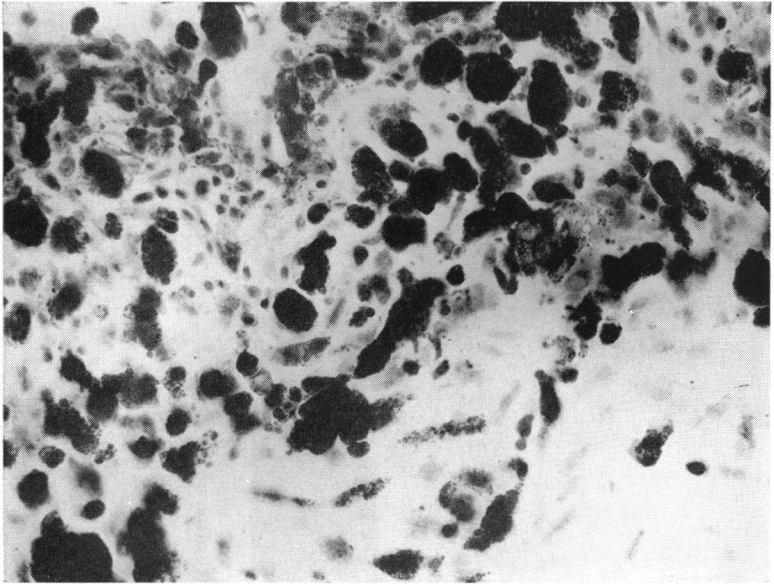


Fig. 6.—(Case 2).—Photomicrograph showing infiltration of the iris with tumor cells; X 800.

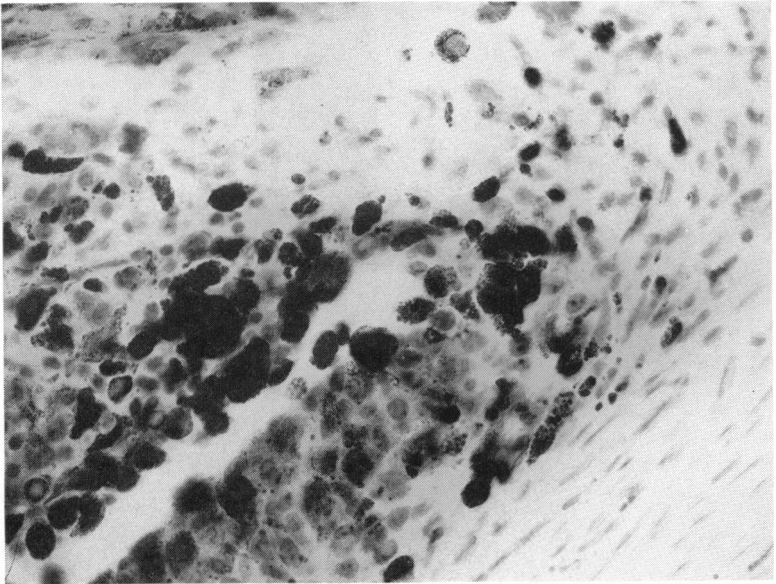


Fig. 7.—(Case 2).—Photomicrograph showing section of the iris at the filtration angle.

axialward. Many of these cells contain pigment. Also, scattered irregularly over the entire posterior surface of the cornea are numerous individual implants of tumor cells. Below, the iris is almost completely infiltrated with tumor cells, and those in the stroma of the iris contain no pigment or are very scanty in pigment. The contraction of this infiltrative growth has created a well-marked ectropion uveae. The tumor extends back from the base of the iris to the base of the ciliary body. In the region of the main mass of the tumor pigmented cells can be seen coursing along the perivascular spaces into the sclera, but no tumor can be seen outside the confines of the globe in the sections examined.

The majority of the tumor cells are large, oval and epithelioid in type, and filled with round pigment granules (Fig. 3). Occasionally one sees the branching typical of the chromatoblastic type of cell. The numerous implants along the cornea and throughout the iris and into the meshwork of the angle indicate the extreme friability of the tumor, and a marked tendency of the tumor cells to desquamate and disseminate which is typical of the chromatogenic type.

Sections stained with the Wilder method show a moderate amount of reticulum. Sufficient reticulum is present in the tumor to be placed in 2-c according to the Wilder classifications.

In the ciliary body opposite the site of the tumor there are areas of proliferation of the pigment epithelium with an associated proliferation of nonpigmented epithelium.

The retina shows peripheral cystic degeneration, and scattered throughout the retina are numerous small cystic areas. These areas are seen in the ganglion cell layer and external plexiform layer. There is also wrinkling of the internal limiting membrane of the retina.

The choroid is normal except for occasional drusen of the lamina vitrea.

There is moderate cupping of the optic nerve.

*Diagnoses:* Tumor of iris: melanoma—malignant (disseminating type). Tumor of ciliary body: melanoma—malignant (disseminating type). Glaucoma: secondary to tumor. Ciliary body: hyperplasia of ciliary epithelium.

Recovery was uneventful. When the patient was examined on May 1, 1947, 22 months after enucleation of the eye, there was no evidence of recurrence or metastasis.

CASE 2.—Mrs. W. L. P., a housewife aged 39, was referred to me in consultation by Dr. R. L. McDaniel on May 5, 1944, with the tentative diagnosis of malignant melanoma of the iris of the left eye. She stated that this eye had been red and had ached for 3 days, but there was no history of previous trouble with the eyes. Over an indefinite period of years she had observed the iris of the left eye become dark brown and she had also noticed a dark brown spot on it for many years. The iris of the right eye was blue, with no deposits of pigment.

On examination, the conjunctiva of the left eye was mildly hyperemic, and there was congestion of the ciliary vessels. Intra-ocular tension was for the right eye 19 and for the left eye 40 (Schiotz). The iris of the left eye was uniformly colored a chocolate brown and had the appearance of having had brown pigment spread on its surface. Its normal markings were effaced by the deposits of pigment, and it seemed thicker than usual. The pupil did not react to light; it was slightly dilated, and in the pupillary circle ectropion uveae was observed. Biomicroscopy showed a slight edema of the corneal epithelium. The aqueous beam was hazy, and within the aqueous fine pigment granules were noted. The filtration angle was covered with pigment over its entire circumference. Fine deposits of pigment were observed on the posterior surface of the cornea and on the anterior capsule of the lens. A 2½% solution of neo-synephrine was instilled, but the pupil did not dilate. The ocular fundus was normal except for a pathologic cupping of the nerve head.

The right eye was normal in all respects. The vision in this eye was 20/15, and in the left eye it was 20/20. The field of vision of the left eye was contracted concentrically to 20° for form.

It was difficult to identify this condition positively as a melanoma of the iris. Uveitis could not be ruled out clinically, nor could glaucoma. A diagnostic iridectomy was therefore performed on May 5. The pathologic diagnosis was malignant melanoma, and the eye was immediately enucleated (Fig. 4).

The following pathologic report of the enucleated eye was made by Col. J. E. Ash, Director of the Army Medical Museum:

*Gross:* The specimen consists of a firm, rather large eye measuring 26 by 24 by 25.5 mm. There is a scar at the limbus over a coloboma of the iris. The pupil is widely dilated, revealing only a narrow margin of the iris. The eye is opened in the vertical plane. There is a fold at the macula. The optic disk is cupped.

*Microscopic:* The iris is absent beneath a partially closed scar of a perforating wound of the cornea near the limbus (Fig. 5). On the opposite side generally round or polygonal cells, although occasional spindle forms are seen, infiltrate the iris and vascular layer of the ciliary body (Fig. 6). On both sides they line the filtration angle, clog the spaces of Fontana and appear around the canal of Schlemm (Fig. 7). The tumor cells are, on the whole, rather heavily pigmented, but the round, very deeply pigmented cells which cling to the filtration angle and the anterior surface of the iris are probably chromatophores. In the iris the tumor cells are concentrated anteriorly although, in some areas, they penetrate to the dilatator muscle. A Wilder reticulum stain demonstrates an argyrophil fiber content of about 50%. Subuveal hemorrhage detaches the ciliary body and all but the posterior choroid. The lamina cribrosa appears somewhat depressed.

*Diagnosis:* Diffuse malignant melanoma of the iris, mixed cell type, with invasion of the ciliary body; secondary glaucoma; iridectomy; subchoroidal hemorrhage.

The patient was recently examined 3 years after removal of the eye. There was no indication of recurrence or metastasis.

#### DISCUSSION

In both cases the filtration angle was blocked with pigment and tumor cells, there was secondary glaucoma, deposits of pigment were present on the posterior surface of the cornea, and the anterior chamber was normal in depth. Also, vision was within normal limits in both cases. In Case 1 the pupil dilated only partially and in Case 2 not at all.

Reticulum stain by the Wilder method demonstrated reticulum content of more than 50% in Case 1 and about 50% in Case 2. The lesion was of the epithelioid type in Case 1 and of the mixed cell type in Case 2.

It is noteworthy that in Case 2 a pigmented spot or freckle on the iris of the affected eye was observed by the patient for some years prior to the development of the tumor.



## SUMMARY

Diffuse malignant melanoma of the iris occurs rarely. The salient features of this unusual lesion are presented.

Two cases of malignant melanoma of the diffuse type primary in the iris are reported.

## BIBLIOGRAPHY

1. Duke-Elder, W. S.: *Textbook of Ophthalmology*, 3:2477-2518, St. Louis, C. V. Mosby Company, 1941.
2. Doherty, W. B.: *Am.J.Ophth.*, 22:239-249, March, 1939.
3. McKee, S. H.: *Arch.Ophth.*, 28:197-204, August, 1942.
4. Wilder, H. C.: (a) Personal Communication; (b) *Intra-Ocular Tumors in Soldiers, World War II*, *Mil. Surgeon*, 99:459-490, November, 1946.
5. Li, T. M.: *Am.J.Ophth.*, 6:545-556, July, 1923.
6. Martin-Jones, J. D.: *Brit.J.Ophth.*, Monograph Supplement XI, 1946.
7. Reese, A. B.: *Am.J.Ophth.*, 27:217-226, March, 1944.
8. Fuchs, E.: *Das Sarcom des Uvealtractus*, Wien, W. Braumüller, 1882.
9. Ewetzky: *Arch.f.Ophth.*, 45 (3):563, 1898; cited by Duke-Elder.<sup>1</sup>
10. Bruner, A. B.: *Arch.Ophth.*, 53:162-165, March, 1924.
11. Verhoeff, F. H.: *Arch.Ophth.*, 33:241, 1904; cited by Duke-Elder.<sup>1</sup>
12. Masson, P.: *Ann.Surg.*, 93:218-222, January, 1931.
13. Theobald, G. D.: *Arch.Ophth.*, 18:971-997, 1937.
14. Callender, G. R.: *Tr. Am. Acad. Ophth. & Otol.*, 36:131-142, 1931.
15. Callender, G. R., Wilder, H. C., and Ash, J. E.: *Am.J.Ophth.*, 25:926-967, May-June, 1942.
16. Vose Solomon: *Tr.Ophth.Soc.U. Kingdom*, 20:257, 1882; cited by Li.<sup>5</sup>
17. Hanke: *Graefe's Arch.f.Ophth.*, 47:463, 1898; cited by Li.<sup>5</sup>
18. Alt, A.: *Am.J.Ophth.*, 28, No. 6, June, 1911; cited by Li.<sup>5</sup>
19. Levan, L.: *Klin.Monatsbl.f.Augenh.*, 493, October-November, 1915; cited by Li.<sup>5</sup>
20. Pindikowski: *Klin.Monatsbl.f.Augenh.*, 53:516, 1915; cited by Li.<sup>5</sup>
21. Callender, G. R., and Wilder, H. C.: *Am.J.Cancer*, 25:251-258, October, 1935.
22. Wilder, H. C., and Callender, G. R.: *Am.J.Ophth.*, 22:851-855, August, 1939.

## DISCUSSION

DR. BRUCE FRALICK, Ann Arbor, Mich.: The rarity of diffuse malignant melanoma of the iris makes it unlikely that many of us will have the opportunity of seeing such a case in our years of practice. Dr. Richardson has indeed been fortunate to have seen and studied two such cases. He has reviewed the literature and presented the salient features of this condition so completely that it leaves little of importance to discuss.

A search of the records at the University Hospital and at my office has failed to reveal that a diagnosis of diffuse malignant melanoma of the iris had been made in either location. Several instances of circumscribed malignant melanoma of the iris were found, and these and a critical analysis of Dr. Richardson's cases

will form the basis of this discussion, since both the diffuse and circumscribed lesions have many features in common.

Since we do not have definite knowledge of the etiology of malignant melanoma, it seems to me that the most important consideration, at present, is the early diagnosis and treatment.

It is well known that malignant melanomas do not necessarily wait until they have attained considerable size before metastasizing. In fact, metastasis may occur from a tumor of very small proportions. The longer a malignant process is present in the eye or other tissues, the greater the opportunity of spread. The development of glaucoma, in a case of malignant melanoma of the iris, signifies an advanced stage of the disease, and that metastasis is more likely than not to have already occurred. The mere fact that glaucoma is present denotes that neither the patient nor physician has been very astute in his observations. Only too frequently, as in one of Dr. Richardson's cases, the patient is not aware of an abnormality until the advanced stage, signified by the presence of glaucoma.

Some features which might aid in the differential diagnosis of benign from malignant melanoma of the iris is the marked tendency for the malignant lesion to prevent complete dilatation of the pupil at the site of the infiltrative process. The malignant lesion is usually more elevated over the surface of the iris than is the benign. This elevation prevents gonioscopic examination of the angle when the process is near the iris base.

When a biopsy of the iris is to be taken for diagnosis, we should have an area which is most elevated and least dilatatable. I have come to the conclusion that we are not justified in relying on frozen sections at time of biopsy to direct us in our decision as to the malignancy of the specimen removed. Frozen sections are of such poor quality for accurate diagnosis that neither the pathologist nor the surgeon should be required to pass judgment as to whether the eye should be enucleated without control sections produced in the usual manner.

Pathologic examination of eyes containing malignant melanoma of the iris suggests the conclusion that often it should be possible to make a positive diagnosis by evacuating the aqueous through an anterior chamber puncture and spinning the aqueous down. Because of the friable character of this malignancy and its tendency to produce implantation growths in the anterior and posterior chambers, as pointed out by Reese, we would expect the simple procedure of cytologic examination of the centrifuged aqueous

would occasionally be of value. The few times that this diagnostic aid has been used by us in circumscribed malignant melanoma it has been without value.

DR. ALGERNON B. REESE, New York City: I think it is well that Dr. Richardson has reminded us of this rare type of melanoma which is frequently not recognized in its early stages. The lesion causes early glaucoma which, as stated by the essayist, is sometimes attributed to iridocyclitis. There seem to be three factors which lead to the diffuse character of these lesions.

1. Desquamation and dissemination of the tumor cells. The cells composing some melanomas show poor cohesion and therefore are quite friable. When this type of melanoma is present in the choroid this feature is not appreciable because the tumor is restrained within the confines of the lamina vitrea and the subretinal space, but when present in the ciliary body and iris, desquamated cancer cells are disseminated throughout the aqueous and deposited at various sites. Should the cells come to rest at a site where adequate nutrition is available they remain viable and may even produce secondary tumor nodules. I think Dr. Richardson's first case illustrates this very well.

2. Extension around the major arterial circle. Tumors of the iris may involve the anterior portion of the ciliary body and, therefore, come in contact with the major arterial circle through and around which they may spread because there is good nutrition and because the perivascular space is the line of least resistance.

3. Diffuse nature of the tumor and multiple origin. Neurogenic tumors are characterized by diffuse growth and multiple sites of origin. These tumors arise from the Schwann cell and a characteristic feature of this type of tumor is its appearance at numerous sites. That feature is well illustrated in neurofibromatosis in which condition we see multiple lesions all over the skin but with major manifestations at one particular site. In a like manner a neurogenic melanoma of the iris may manifest itself.

DR. E. C. ELLETT, Memphis, Tennessee: I wish to report a case which seemed to present a problem in diagnosis.

J. L., aged 23, seen in December, 1943, reported that he had had a dark spot on the iris of the left eye for several years. He had photographs taken in 1934, which I did not see, which he said showed the dark spot. He also said that it had been noticed fifteen years before by a doctor who removed a foreign body from his cornea. He had recently been a patient in an Army hospital when

the trouble was diagnosed sarcoma and enucleation advised. The right eye was normal with 6/6 vision.

The left eye saw 6/6, and presented a dark tumor of the iris, about 4 by 2 mm. There was also a small pterygium, tension 18 (Schiötz). The pupil was active except opposite the growth. There was a small prolongation of the growth down, and this, as well as the main body of the growth, seemed to fill the angle of the anterior chamber and touch the cornea. The growth did not infiltrate the iris, but was of a much darker color and could be described as "set in" the iris, which surrounded and was distinct from it, like a stone is set in a piece of jewelry.

The patient was seen again in May, 1944, and in September and October, 1945. There was no change in the eye at all and he was advised that the condition was not progressive and not malignant and to let it alone.

DR. ARTHUR J. BEDELL, Albany, N. Y.: In demonstrating several kodachrome photographs, I wish to show some of the iris lesions simulating malignant growths and also call attention to the value of infra-red photographs.

The first case is a cyst of the iris with rust-colored surrounding ring. The next a dense, brown, circumscribed mass in the lower portion of the iris, the third a much rougher, darker, well-delimited 4 mm. pigmentation, and the fourth, a sector-shaped depigmentation extending to a heavily pigmented, elevated pupillary margin. All of these cases have remained unchanged for years.

Two others present more diffuse browning with surface elevation.

A proved case of iris sarcoma is exhibited with the convex, elevated surface projecting into the anterior chamber.

The infra-red photograph compared with the ordinary black and white graphically demonstrates how a seemingly small grayness of a portion of the iris is by the infra picture found to be a large, thick iris tumor. Operation confirmed the diagnosis.

I was happy to hear Dr. Richardson's paper. It makes us more alert and better able to recognize both the malignant and non-malignant lesions.

DR. WENDELL L. HUGHES, Hempstead, N. Y.: I recently had an opportunity of seeing a case similar to Dr. Richardson's, and it was seen in consultation by Dr. Reese. The patient came with an acute congestive glaucoma, and the usual mistake was made. I did an iridectomy for the glaucoma, not recognizing the underlying tumor. Four months later the patient returned; the glaucoma was under good control, but she returned with a small nodule appearing in the

anterior chamber angle. Either it had been missed before, or it had just appeared. I hope it was the latter.

This shows the normal eye, and on the other side you will notice the difference in the color between those eyes, and the next slide shows the color of this iris, with the diffuse infiltration of the iris all around, and down here this small nodule that made us very suspicious of the advancing nature of the disease.

This shows the pathologic specimen; the iris infiltration does not show up, but there is a rather large infiltration in the ciliary body which Dr. Reese felt was a diffuse malignant melanoma of the iris and the ciliary body.

DR. SHALER RICHARDSON, closing: I desire to thank those who have discussed the paper. I also wish to thank Dr. McDaniel, with whom I saw the patient in Case 2 in consultation, for the privilege of reporting the case in this paper. Over a period of years I have collected 5 cases of circumscribed malignant melanoma of the iris, but I purposely did not include them in this report for I wanted to accentuate the difference between the diffuse malignant melanoma and the circumscribed type.

---

## THE CLINICAL COURSE OF THE EYE COMPLICATIONS OF ARACHNODACTYLIA

RALPH I. LLOYD, M.D.

Brooklyn, N. Y.

It is the general idea that the lens dislocations and rigid irides seen in arachnodactylia are nonprogressive congenital defects. Observation of 18 cases over periods of 5 to 14 years and some 25 others for shorter periods convinces me that many are true abiotrophies. While some patients complain only of reduced acuity, many show progressing lens dislocations and uveal degeneration ending in detachment of the retina. Our knowledge is far from complete and only 1 eye has been examined in the laboratory. This article is offered to attract other case and laboratory reports.

The disease is a dominant heredity in many families and recessive in others. A parent with normal eyes and some of the skeletal defects may transmit the disease in complete