

SIGNIFICANCE OF BRIGHT PLAQUES IN THE RETINAL ARTERIOLES

BY *Robert W. Hollenhorst, M.D.**

AMONG 235 PATIENTS¹ WHO HAD OCCLUSIVE DISEASE within the carotid arterial system and 93 patients with clinical symptoms and signs of involvement of the vertebral-basilar arterial system, 31 (9.4 percent) had from a single plaque to several dozen bright plaques that were orange, yellow, or copper in color and situated at various bifurcations of some of the retinal arterioles. A total of 35 such patients had carotid endarterectomy. Seven (20 percent) of these 35 surgical patients had such plaques; in five of the seven, the retinal plaques appeared during the operation, whereas they appeared 6 weeks afterward in another, and they remained unchanged postoperatively in the seventh patient. In two instances, the plaques occluded tiny peripheral retinal arterioles, with infarction in portions of the retina.

These plaques were observed in 27 (11 percent) of the 235 patients who had signs and symptoms of involvement of the carotid arterial system (cases 1-20 and 25-31 in Tables 1 and 2), and in four (4 percent) of the 93 patients who had evidence of involvement of the vertebral-basilar arterial system (cases 21-24 in Table 1). Two of the four patients in the latter group had simultaneous signs and symptoms of occlusive disease in the carotid arterial system.

Among twelve of these 31 patients, various changes in position of the plaques occurred; some of them disappeared (cases 2, 5, 13, 17, 25, 31), some new ones appeared (cases 2, 5, 17, 25-28, 30, 31), some moved to other locations within the retina (cases 12, 17, 20, 25), and some appeared as showers of plaques (cases 25, 28, 31).

These plaques had a characteristically bright orange-yellow color. They reflected the light of the ophthalmoscope often in a heliographic fashion and tended to lodge simultaneously at several bifurcations of the same arteriole as though they were fragments of a larger plaque.

*From the Section of Ophthalmology, Mayo Clinic and Mayo Foundation, Rochester, Minnesota.

TABLE 1. RETINAL PLAQUES WITH CAROTID OR VERTEBRAL-BASILAR ARTERIAL OCCLUSIVE DISEASE

Case	Age	Symptoms and signs*	Ophthalmodynamometry, mm. Hg†			Plaques in retinal arterioles
			R	L	L	
1	55	Transient L(H); no ocular symptoms	72/30	112/42	2 R	June, 1956 = 1 R Nov., 1956 = 2 R Sept., 1958 = no plaques, attacks stopped Many both eyes
2	62	Transient altitudinal anopsia R; 1 convulsion; bruit both carotids	85/30	85/35		
3	60	Transient aphasia and R(H)	35	10	1 R	July = 1 L; anticoag. relieved attacks. Oct. = previous plaque gone; new plaques each eye 1 L central artery
4	62	LAF and attacks R(H); bruit L carotid	120/42	65/32		
5	74	Aphasia, R(H)	70	60		
6	66	Aphasia, RHH, LAF, R(H); bruit R carotid	80/18	100/32		
7	66	Aphasia, R(H), coma, LAF	80/38	80/32		In all branches L 1 L
8	63	Convulsions 4 years; attacks R(H); stenosis L int. carotid by angiogram	55	55		
9	48	RAF and L hemianesthesia	32	35	Several R	3 L
10	52	Aphasia, RHH, RH; angiogram = patent carotid and occluded middle cerebral	50	50		
11	64	LHH, L(H)	42	42	2 R	Many R; moved distally under observation
12	59	RAF, L(H)	65	65		
13	65	Aphasia, RHH	70	70	1 L; gone 2 days later	1 R
14	53	Paresthesia L hand; RAF; bruit both carotids	35/10	90/48		
15	64	No symptoms; bruit both carotids; iliac-artery occlusion	48/10	90/20	1 R	
16	74	No symptoms; bruit both carotids	70/38	110/62	2 L	Many L (see text); some appeared, moved and dis- appeared
17	52	LAF 1 day; angina pectoris 3 yr.	60	60		
18	67	Syncopal attacks; no ocular symptoms	95/48	65/28	9 R	Several L with occluded retinal arterioles; 1 R
19	70	LAF	90/40 120/45	90/40 80/30		
20	64	Amaurosis R; attacks of coma and L(H); cardiac valvular disease	95/32	105/30		Embolus occlusion R; 2 plaques that moved
21	55	R(H), ataxia	110/62	120/62	2 R	
22	64	Vertigo, ataxia, L(H)	70	70	1 L	2 L
23	59	Vertigo, L(H); bruit both carotids; generalized atherosclerosis	60/28	130/60		
24	64	Congruous LHH; L(H)	50	60	1 R	

* L = left; R = right; (H) = hemiparesis; AF = amaurosis fugax; HH = homonymous hemianopsia; H = hemiplegia.

† When only one measurement is given, it is the diastolic pressure.

TABLE 2. RETINAL PLAQUES IN PATIENTS HAVING CAROTID ENDARTERECTOMY

Case	Age	Symptoms and signs*	Preoperative ophthalmodynamometry, mm. Hg†		Carotid angiography	Carotid endarterectomy	Postoperative ophthalmodynamometry, mm. Hg†		Postoperative retinal findings
			R	L			R	L	
25	46	"Spells" of R temporal-lobe type; no ocular signs	40	60	Occlusion R. int.	R int. (unsuccessful)	60/40	100/70	15 plaques appeared and 2 arterioles occluded R; L eye normal; moving plaques observed
26	50	RH, RAF; bruit both carotids	50	70	Stenosis both int.	Bilateral	110/45	110/45	1 plaque appeared R
27	65	R(H); bruit both carotids	50	50	Stenosis L int.	L int.	50	60	1 plaque L and 2 branch artery occlusions R
28	58	Attack of coma	52	72	Occlusion R int., innominate and R vertebral	R common	130/65	130/65	appeared Many nonoccluding plaques appeared both eyes
29	51	LH; 5 plaques L, none R	70/35	70/35	Occlusion R int.	R int. (unsuccessful)	50	60	Same as preop.
30	63	L(H)	20	20	Stenosis R int.	R int.	98/38	110/40	1 plaque appeared R
31	59	L(H), LHH; bruit both carotids	28	60	Stenosis both int.	R int.	50	50	6 weeks postop. sudden onset LHH and LH, and numerous plaques R (later gone)

*Same abbreviations as in Table 1.

†When only one measurement is given, it is the diastolic pressure.

Only occasionally did they occlude the involved arterioles. The plaques occasionally occluded branches of the central retinal artery in a number of patients who had no signs or symptoms of cardiovascular disease.

It is probable that these bright plaques are embolic crystals of cholesterol arising from ulcerating atherosclerotic lesions situated on the cardiac valves or in the endothelium of the aorta or carotid arteries. Their nature has not been ascertained, as none of the eyes involved have been examined pathologically. Attempts to photograph the plaques by polarized or ultraviolet light to show their possible crystalline nature have not been successful. It is even possible that the plaques may be liquid in nature, for compression of the eye sometimes causes an ameboid bulging of part of the plaque into the neighboring arteriole, and many plaques move from one bifurcation to the next and finally disappear. From the following observations, it appears that some of these plaques are definitely crystals: (1) they often reflect the light brightly in only one direction, and if the ophthalmoscopic light is turned at a different angle or if the eye is compressed, the bright yellow reflection may diminish or disappear; (2) when the segment of artery in which the plaque rests is made to pulsate by compressing the globe, the bright reflection may flash on and off with each pulsation; (3) occlusion of an arteriole by even large plaques is infrequent; (4) pieces may break off from proximal plaques and may lodge successively at smaller, more distal bifurcations and finally may disappear entirely from the retinal circulation.

Some patients (cases 17 and 20) had bright orange plaques at various bifurcations in the superior or inferior temporal arterioles, but the only actual occluding plaque was a creamy-white irregular body situated at a bifurcation and protruding into the occluded arteriole. One may conjecture that such a creamy body is a piece of fibrin, a clump of platelets, or some other solid material, perhaps surrounding the cholesterol crystal. These creamy plaques usually but not always remain *in situ*, but the orange-yellow plaques may be dislodged by sudden pressure on the globe and may move to more distal bifurcations.

These bright plaques were seen mostly in elderly patients, in whom a degree of atherosclerosis is to be expected. All the patients who were subjected to angiography or endarterectomy had demonstrable intimal atherosclerosis; all the others in this study had signs and symptoms of occlusive ophthalmic, carotid, or vertebral-basilar arterial disease. Of the 31 patients, 27 (87 percent) were men. The 235 patients

who had occlusive disease of the carotid arterial system included 182 (77 percent) men. Among the 93 patients who had occlusive disease of the vertebral-basilar arterial system, 65 (70 percent) were men.

No plaques were seen in the retinas of 21 other patients who had experienced occlusion of the retinal arterioles, the central retinal artery, or the ophthalmic artery in the group who had evidence of occlusive disease in the carotid arterial system, or in two such patients among those who had occlusive disease in the vertebral-basilar arterial system. There were 65 other patients with amaurosis fugax who similarly were free of these plaques. Such plaques may have been overlooked, for many of the arterial occlusions had occurred months or weeks before the patients came to the Mayo Clinic. However, it is probable that other mechanisms, such as thrombosis, spasm, or hypotension, may have been responsible in the majority of patients in whom plaques were not seen.

The location of the plaques in the total of 29 patients who had involvement of the carotid arterial system is of considerable interest and importance. Among the 16 such patients who had significantly unequal retinal arterial pressures, the plaques were in the eye with the lower pressure in nine patients, on the side with the higher pressure in four patients, and on both sides in three patients. In the 13 patients with equal retinal arterial pressures, the plaques appeared in the eye on the side of the symptomatic carotid artery in 11 instances and on both sides in two. The nine patients who had plaques on the side of higher pressure or on both sides often had a bruit over the carotid artery or had symptoms arising from the carotid arterial system on the side of the retinal plaque. Therefore, one could postulate an atherosclerotic source of the retinal arterial plaques.

REPORT OF REPRESENTATIVE CASES

My colleagues and I have seen many elderly patients who had such bright plaques, both with and without arterial occlusion, but who had no signs or symptoms of occlusive cerebrovascular disease. The following two cases are illustrative.

CASE 17

A 52-year-old laborer with a 3-year history of angina pectoris noted transient loss of the upper field of vision of the right eye at 10 A.M., November 11, 1959. Two hours later, his ophthalmologist noted complete loss of vision, with fragmentation of the blood stream in the retinal arterioles and venules of the left eye. The vision and the retinal circulation returned

to normal 10 minutes later. After he ingested 50 mg. of nicotinic acid, the vision of this eye blacked out again for 20 minutes. That afternoon, after his vision recovered, he came 200 miles by airliner to the Mayo Clinic; he did not experience any visual difficulty in flight.

Examination showed 20/20 vision in each eye. The right eye was normal. Inside the central artery of the left eye was a yellow-white plaque that appeared to be either an atheroma or an embolus. All the arterioles apparently were normal. Below the optic disc was a faint patch of edema and a white streak in a tiny arteriole. Bright orange emboli were present at various bifurcations of the retinal arterioles; one was noted at the second branching of the inferior temporal arteriole, one along the upper macular arteriole, and one below the fovea. The brachial blood pressure was 135 mm. of mercury systolic and 105 mm. diastolic. The retinal diastolic pressure was 60 mm. in each eye.

Administration of heparin, warfarin (coumadin), sodium, and oxygen with 5 percent carbon dioxide was begun immediately. Vision was tested every 2 hours during the night. By the next morning (November 12), most of the retinal edema had absorbed but six coppery emboli now were

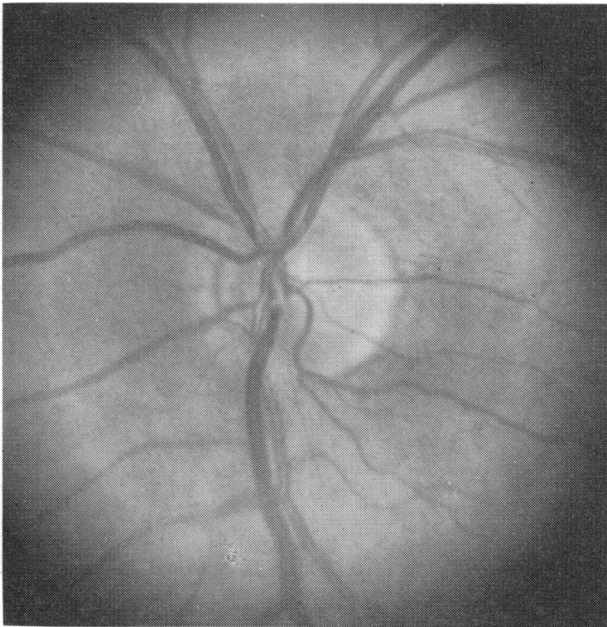


FIGURE 1. CASE 17, LEFT RETINA ON NOVEMBER 16, 1959, SHOWING SLIGHT EDEMA OF LOWER MARGIN OF OPTIC DISC.

Cholesterol emboli were present in the inferior temporal arteriole below the disc and at its second bifurcation; yellow-white material was present in the central artery.

scattered along the inferior temporal arteriole and its macular branches. That day he had several brief attacks of amaurosis fugax and several more during the night of November 13 (these latter were the last such episodes to occur during the ensuing 10 months). By November 14, all except three of the plaques had disappeared.

On the morning of November 16, several more coppery emboli were observed in the following locations: two major bifurcations of the inferior

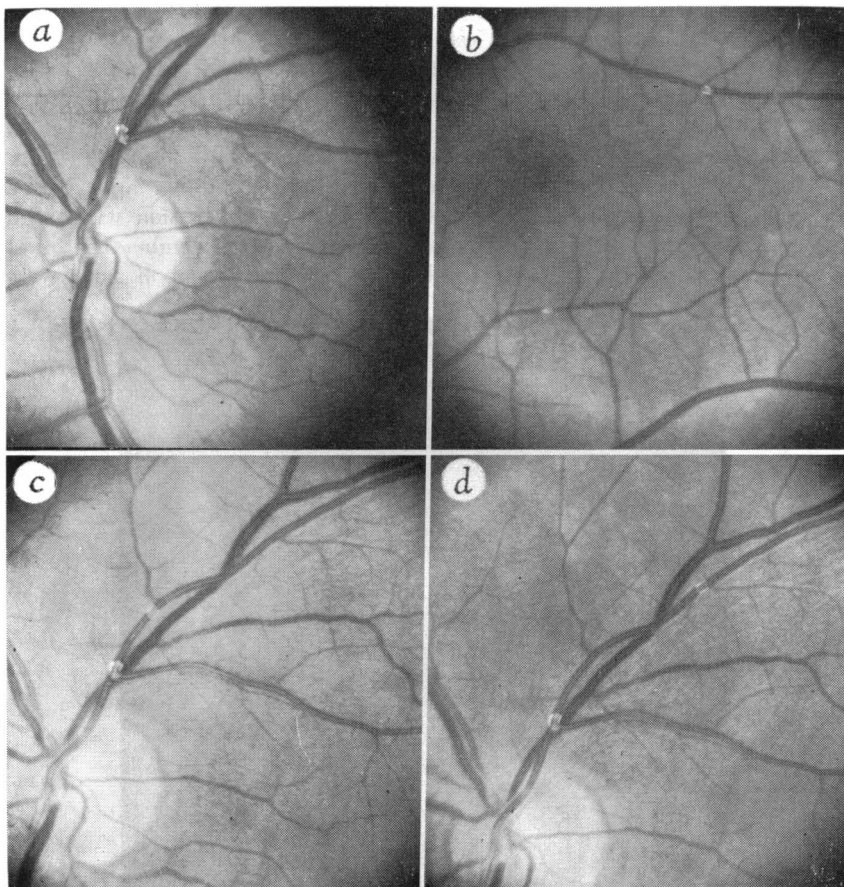


FIGURE 2. CASE 17.

A and B. Left retina on November 20, 1959. A fresh orange plaque is seen at the first fork above the optic disc; two emboli are noted in the superior macular arteriole and one in the inferior macular arteriole. C. Left retina on November 23. Note the additional plaque at the second fork of the superior temporal arteriole. D. Left retina on November 25. The second plaque has moved to the third fork of the superior temporal arteriole.

temporal arteriole, a tiny arteriole below the fovea, the inferior macular arteriole, the superior macular arteriole, an upper peripheral arteriole, and an area of fresh ischemic edema situated infero-temporal to the macula. These caused no visual symptoms (Figure 1).

During the night of November 20, a fresh, large, bright-orange plaque appeared in the ascending arteriole above the disc but did not impair the circulation. This plaque could not be moved by compressing the eye. Other plaques were present in the inferior macular arteriole and in the superior macular arteriole. Those previously seen in the inferior temporal arteriole and in a superior peripheral arteriole were gone (Figures 2a and 2b).

Between November 20 and 27, several pieces broke away from the large plaque above the optic disc and lodged successively at more distal bifurcations (Figures 2c and 2d) until they disappeared by November 27. The patient was advised to continue coumadin therapy for 3 weeks. At his dismissal, the retinal arterial diastolic pressure was 50 mm. in each eye.

He returned in January, 1960. The plaque above the optic disc had faded somewhat (Figure 3), but three emboli were visible in the superior temporal arteriole. Vision was normal.

He returned in August, 1960, because of several attacks of amaurosis

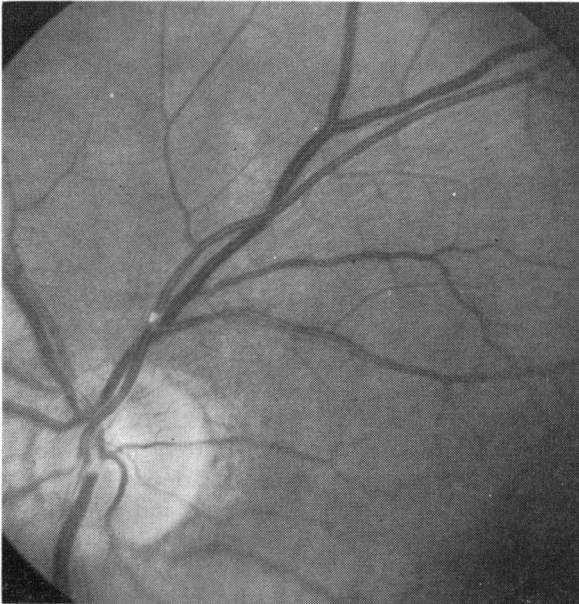


FIGURE 3. CASE 17, LEFT RETINA ON JANUARY 18, 1960.

Note the fading of the plaque in the superior temporal arteriole. Three plaques in this arteriole are not shown.

fugax in the left eye one week previously; these had ceased when he resumed anticoagulant treatment. Examination showed only one plaque far out along the superior temporal arteriole. The ophthalmodynamometric readings had changed to 95/48 in the right eye and 65/28 in the left eye; it was presumed that the decreased pressure on the left indicated occlusive involvement in either the ophthalmic or the internal carotid artery. As additional symptoms had not appeared and bruits were not heard over the carotid arteries, further diagnostic tests were deferred. He has remained asymptomatic since August, 1960.

CASE 19

A 70-year-old farmer had noted intermittent attacks of amaurosis fugax in the left eye for several months; about one month before he came to the clinic, the recurrent visual defect had become permanent.

Examination disclosed a small plaque in the inferior nasal arteriole of the right eye, but vision was normal. The visual field of the left eye showed a dense arcuate defect. Nearly a dozen bright embolic plaques were seen in various arterioles. One creamy plaque plugged the superior macular arteriole at its departure from the superior temporal arteriole above the optic disc; it had caused infarction of the retina. Several bright orange plaques were lodged in arterioles within the edematous zone. Non-obstructing plaques were seen in the branches of the superior temporal arteriole and in the terminal branches of the inferior macular arteriole (Figure 4).

The only physical findings of note were an aortic systolic murmur and lower retinal arterial pressures on the left side, the ophthalmodynamometric readings being 120/45 on the right and 80/30 on the left.

A majority of the patients who had these plaques gave definite evidence of associated atheromatosis in the aortic arch or its branches, as illustrated by the following case.

CASE 18

A 67-year-old retired businessman came to the clinic in December, 1959, because of frequent "faint spells" beginning in September, 1959. He had not had any visual symptoms. His heartbeat was irregular and the fingers of both hands tingled during an attack. During auscultation over the right carotid artery, he experienced a typical attack. His right eye contained a bright orange plaque in the central retinal artery in the optic disc, others at five bifurcations of the superior temporal artery (Figure 5), one at the first bifurcation of the superior nasal arteriole and two along the inferior temporal arteriole. Lesions were not seen in the left retina. The ophthalmodynamometric readings were 90/40 in each eye and were identical whether the patient stood or lay supine. Under treatment with bishydroxycoumarin (dicumarol), his "faint spells" immediately ceased and have not recurred.

The next case illustrates the appearance of bright plaques after

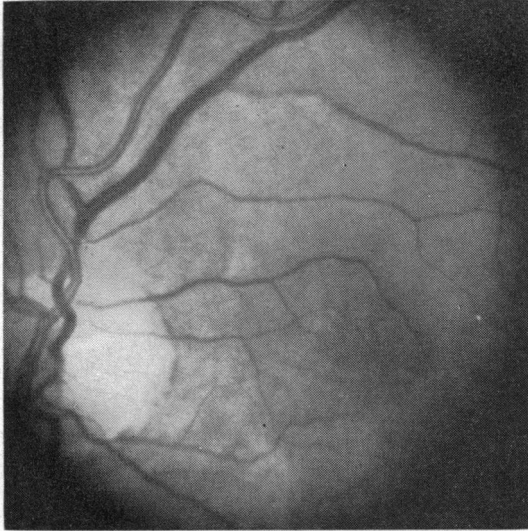


FIGURE 4. CASE 19, LEFT RETINA.

This patient had embolic occlusion of the superior macular arteriole and retinal infarction by a creamy plug at the exit of the superior macular arteriole. One of a dozen bright orange plaques is seen above the macula in a terminal branch of the superior macular arteriole.

carotid endarterectomy. The phenomena described probably result from cholesterol crystals dislodged from the site of an eroded atheroma in the carotid artery.

CASE 31

A 59-year-old businessman came to the clinic in June, 1959, because of several attacks of left hemiparesis during the previous year. Ophthalmoscopic examination gave normal findings. The retinal diastolic pressure was 28 mm. in the right eye and 60 mm. in the left. Bruits were heard over both carotid arteries in the neck. Angiography revealed severe stenosis of the first part of the right internal carotid artery and mild stenosis of the left.

After right carotid endarterectomy, the retinal arterial pressures became equalized on the two sides, and the fundi remained normal. Six weeks later, he sustained sudden infarction of the right cerebrum, with left hemiparesis and left homonymous hemianopsia. A dozen or more bright plaques were seen in various arteriolar bifurcations of the right eye, but they did not occlude any of the vessels. The retinal arterial pressure was 96/50 in each eye. No plaques were present in the left retina.

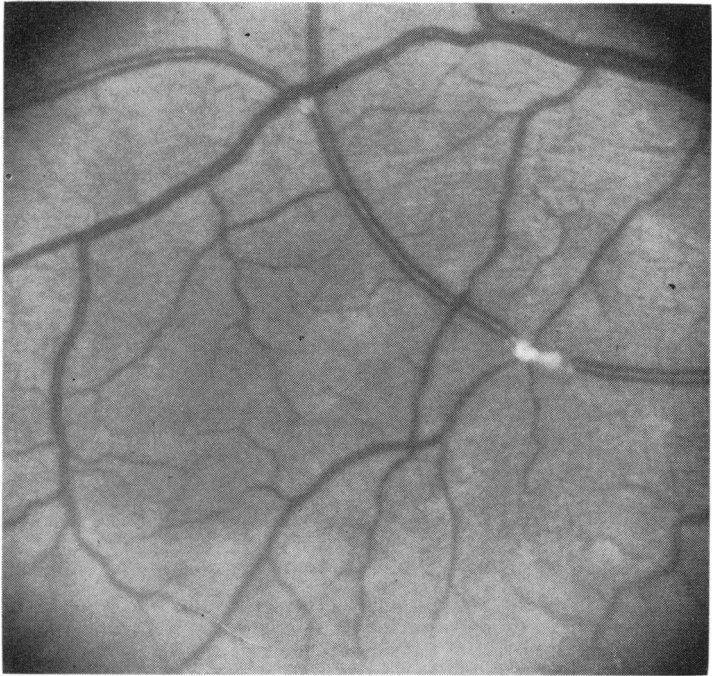


FIGURE 5. CASE 18, RIGHT RETINA.

Showing two non-obstructing orange plaques in superior temporal arteriole.

Examination nine months later disclosed that all the plaques had disappeared from the retina of the right eye; however, a similar bright non-occluding plaque had appeared in the inferior temporal arteriole of the left eye.

COMMENT

That the concept of cholesterol embolism in the retina is a tenable one may be inferred from other publications on this subject. Panum,² in 1862, was apparently the first to report embolization of atheromatous material. The embolus he described occluded a coronary artery and caused the death of the patient. Flory³ found cholesterol emboli in all organs in 12 percent of 57 patients who had advanced ulcerative atherosclerosis. Handler⁴ stated that intracerebral arterial embolization with encephalomalacia was common. Three of five patients in whom the cerebral vessels were examined showed this phenomenon. He

described the illumination of frozen sections with polarized light to identify the crystals. Ophthalmoscopy was done in two of his 20 patients, but orange plaques in the arterioles were not mentioned. Sayre and Campbell⁵ demonstrated cholesterol emboli in the kidneys, brain, heart, and extremities of a patient who had extensive atheromatous deposits in the aorta and its branches (Figure 6). Schornagel⁶ stated that emboli were relatively common after operations involving arteries with pronounced atheromatous changes. Otken⁷ reported embolic cholesterol crystals in human beings and was able to produce cholesterol emboli in animals.

It is difficult to understand why so few reports have appeared on the occurrence of these phenomena in the retinal arterioles. They undoubtedly have been observed clinically more frequently than the literature would indicate. One limiting factor is the absence of patho-

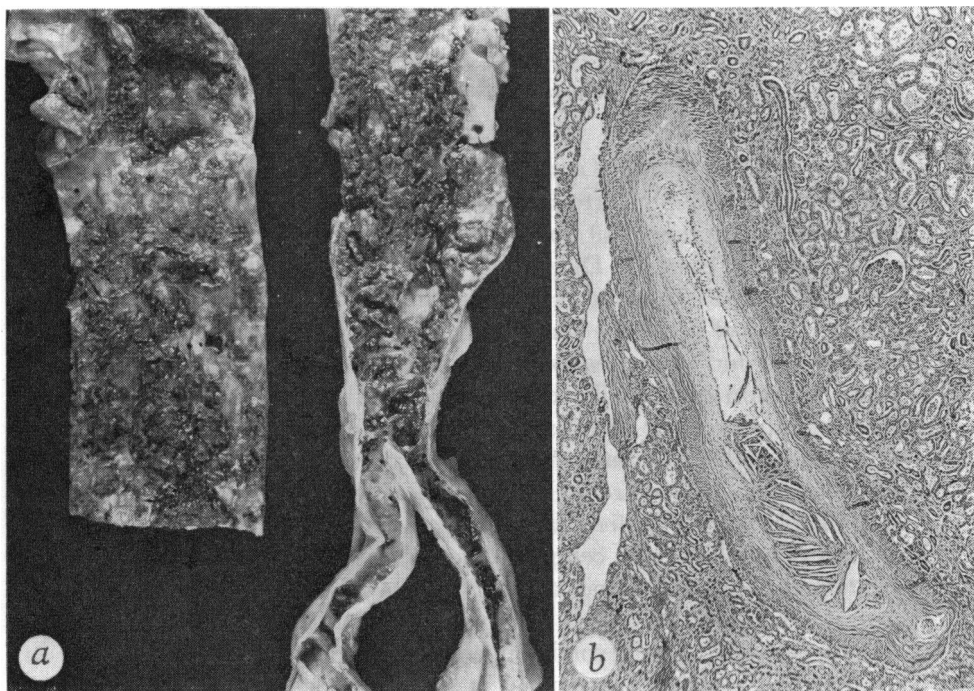


FIGURE 6.

A. Aorta with extensive atherosclerosis, erosion and deposition of blood and cholesterol. B. Intralobular renal artery in same case sectioned longitudinally. At one end, the lumen is occluded by amorphous material containing biconvex clefts formed by cholesterol deposits (hematoxylin and eosin; $\times 30$). (This figure is reproduced by courtesy of the publisher and the authors from Sayre and Campbell.)

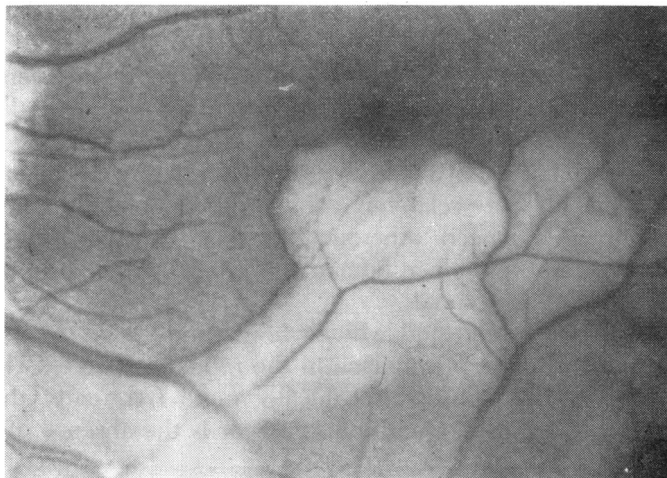


FIGURE 7. LEFT RETINA, SHOWING CALCIFIC (?) EMBOLUS WITH INFARCTION OF INFERO-TEMPORAL PORTION OF RETINA.

logic verification. Fisher^{8,9} and Duke-Elder¹⁰ cited references to more than 200 cases of retinal arterial occlusion. Only a few of these articles contained descriptions that appear to be similar to the findings in my cases. Neither Fisher nor Duke-Elder mentioned these bright plaques. Gowers,¹¹ in 1875, reported that he saw minute granular masses in the central artery of a patient who had occlusion of the central artery of the left eye and right hemiplegia caused by thrombosis of the left internal carotid and middle cerebral arteries; these masses were more likely clumps of static blood seen poorly by indirect ophthalmoscopy with candlelight. Minton¹² reported a clinical study of 54 cases of occlusion of the central retinal artery without mentioning intraluminal crystals. Elschmig's¹³ patient had atheromatous occlusion of the internal carotid, ophthalmic, and central retinal arteries, but emboli were not mentioned. Michel¹⁴ found at necropsy a yellow thrombus in the central artery of one of his patients. Butler's¹⁵ third patient had a "bright embolus" just beyond the first fork of the inferior temporal arteriole of the retina; it remained *in situ* for three weeks.

Another type of embolus I have seen in three patients is an irregular, extremely white body unaccompanied by orange-yellow plaques. All three of these patients had calcific lesions in the cardiac valves demonstrable roentgenographically. The nature of these plaques has not been proved. They may be pieces of calcium cast into the general

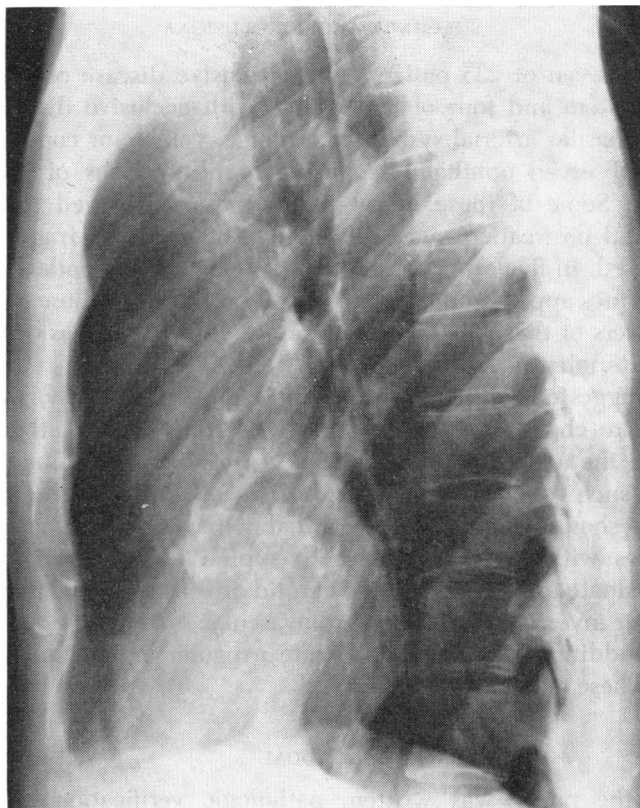


FIGURE 8. LATERAL VIEW OF THORAX, SHOWING EXTENSIVE CALCIFICATION OF MITRAL AND AORTIC VALVES.

circulation and lodged in the retinal arterioles. Galinowsky¹⁶ reported the pathologic verification of calcium embolization in the central artery of the retina in one case, and Coats¹⁷ recorded two such cases. Wagener and Gipner¹⁸ suggested this diagnosis in one of their patients observed clinically. A report of such a case follows.

A 37-year-old man came to the clinic in March, 1952, because of sudden loss of the upper part of the visual field of the left eye, two days before. A shiny white crystalline piece of material was lodged at one of the bifurcations of the inferior temporal arteriole of the left eye (Figure 7). The retina in the distribution of the involved vessel was infarcted. The patient had rheumatic valvulitis with aortic stenosis and insufficiency. Roentgenographic studies showed extensive calcification of the mitral and aortic valves (Figure 8).

SUMMARY AND CONCLUSIONS

Twenty-seven of 235 patients with occlusive disease of the carotid arterial system and four of 93 patients with occlusive disease of the vertebral-basilar arterial system had orange, yellow, or copper-colored plaques observed ophthalmoscopically at bifurcations of the retinal arterioles. Some of these bright plaques were observed to move to more distal bifurcations, and some broke into smaller fragments and disappeared. In five of 35 patients undergoing carotid endarterectomy, these plaques appeared during the operation. Three of these 35 patients had showers of these plaques. Only rarely did the plaques occlude the retinal arterioles.

It is suggested, although not confirmed pathologically, that these plaques are cholesterol crystals dislodged from eroded atheromatous lesions in the aorta or the innominate, carotid or ophthalmic arteries.

When such lesions are seen in the retinal arterioles, the examiner routinely should compare the ophthalmodynamometric readings on both sides with the patient in both supine and standing positions, should palpate and auscultate the carotid arteries, and should refer the patient for investigation of the cardiovascular system.

Three additional patients had white irregular emboli in the retinal vessels. These may be calcific emboli.

ADDENDUM

Since the paper was written, pathologic verification of calcium embolization to the central retinal artery has been obtained.

REFERENCES

1. Hollenhorst, R. W., Neuro-ophthalmologic Aspects of Occlusive Carotid and Vertebral-Basilar Artery Disease. Transactions, Third Princeton Conference on Cerebrovascular Disease. (In press.)
2. Panum, P. L., Experimentelle Beiträge zur Lehre von der Embolie, Arch. path. Anat., 25:308-38; 433-530, 1862.
3. Flory, C. M., Arterial occlusions produced by emboli from eroded aortic atheromatous plaques, Am. J. Path., 21:549-65 (May), 1945.
4. Handler, F. P., Clinical and pathological significance of atheromatous embolization, with emphasis on an etiology of renal hypertension, Am. J. Med., 20:366-73 (March), 1956.
5. Sayre, G. P., and Campbell, D. C., Multiple peripheral emboli in atherosclerosis of the aorta, Arch. Int. Med., 103:799-806 (May), 1959.
6. Schornagel, H. E., Embolie van cholesterolkristallen bij atherosclerose. Nederl. tijdschr. v. geneesk., 102:1741-3 (Sept. 6), 1958.
7. Otken, L. B., Jr., Experimental production of atheromatous embolization, Arch. Path., 68:685-9 (Dec.), 1959.
8. Fisher, C. M., Transient monocular blindness associated with hemiplegia, Arch. Ophth., 47:167-203 (Feb.), 1952.

9. Fisher, C. M., Observations of the fundus oculi in transient monocular blindness, *Neurology*, 9:333-47 (May), 1959.
10. Duke-Elder, W. S., Obstruction of the retinal arteries, in *Textbook of Ophthalmology: Diseases of the Inner Eye*. St. Louis, C. V. Mosby Company, 1940, III, pp. 2561-77.
11. Gowers, W. R., On a case of simultaneous embolism of central retinal and middle cerebral arteries, *Lancet.*, 2:794-6 (Dec. 4), 1875.
12. Minton, Joseph, A clinical study of fifty-four cases of occlusion of the central artery of the retina and its branches, *Proc. Roy. Soc. Med.*, 30:285-300, 1936.
13. Elschnig, Anton, Ueber die Embolie der Arteria centralis retinae, *Arch. Augenh.*, 24:65-146, 1892.
14. V. Michel, J., Ueber Erkrankungen des Gefässsystems der Arteria und Vena centralis retinae mit besonderer Berücksichtigung der pathologisch-anatomischen Veränderungen, *Ztschr. f. Augenh.*, 2:1-34, 1899.
15. Butler, T. H., Three cases of embolism of a retinal artery, *Brit. J. Ophth.*, 11:559-63 (Nov.), 1927.
16. Galinowsky, Zinaida, Ueber Endarteriitis der Arteria centralis retinae mit Concrementbildung, *Arch. Augenh.*, 43:183-99, 1901.
17. Coats, George, Obstruction of the central artery of the retina, *Roy. London Ophth. Hosp. Rep.* 16:262-306 (Oct.), 1905.
18. Wägener, H. P., and Gipner, J. F., Arterial spasm in production of occlusion of branches of central artery of the retina, *Am. J. Ophth.*, 10:650-7 (Sept.), 1927.

DISCUSSION

DR. BANKS ANDERSON. Ophthalmologists, neurologists, internists, and vascular surgeons interested in the maintenance of adequate circulation to the eye and brain will find this paper a most valuable contribution to our understanding of phenomena developing in the presence of carotid and vertebral-basilar arterial insufficiency. Specific diagnostic evidence of circulatory embarrassment occurring in 10 percent of individuals having carotid insufficiency, and in 5 percent having vertebral-basilar insufficiency, must be given serious consideration in evaluating patients suspected of having this disease. The lesions described are of diagnostic value and, coupled with ophthalmodynamometric studies, they have proven, according to the author, of particular value in localizing the site of greatest obstruction. Indeed, to some extent the appearance, fragmentation, migration, and disappearance of these plaques may be utilized as a guide in anticoagulant therapy. Here we have another example of the expanding role of the ophthalmologist in the treatment of systemic disease.

The author has differentiated the bright yellow plaque with the heliographic reflection, a graphically descriptive term which the discussor has not previously encountered, from the less reflective, larger, creamy plaque to which he attaches a different interpretation.

First, considering the bright, coppery, highly reflective, and sharply outlined plaque, it is indeed strange that more attention and inquiry has not been directed to the pathogenesis and significance of these lesions, at times quite conspicuous at the bifurcations of the retinal arterioles. In two instances the discussor has observed these plaques in individuals both of whom shortly thereafter developed optic atrophy in the eye in which the

plaque was observed, with hemiplegia on the opposite side. Since the plaques were observed prior to the carotid occlusion, the discussor had considered them to be lesions within the arteriolar wall. Subintimal atheromatous plaques are not theoretically found in smaller arterioles; nevertheless, the appearance of these lesions at bifurcations usually without appreciable obstruction to vascular flow, but with definite focal enlargement in the caliber of the vessel, with increasing density of the vessel wall, and with increase in the outside diameter as sometimes occurs, has seemed to implicate the arteriolar wall rather than the lumen as the source of a reflective lesion developing *in situ*. The observations of the author and the description of these plaques appearing rapidly in the eyes of five of thirty-five patients having undergone endarterectomy, their dislocation, fragmentation, and migration would indicate that they are more probably embolic in character. One troublesome detail in such an interpretation is an acceptable theory as to why the arteriole is not occluded. Another puzzle involves an explanation as to why the arteriole is bulbous at the site of the lesion and why the plaque sometimes seems to sheathe or saddle the vessel.

While the important point is the determination of the nature of the bright plaque, whether embolic or thrombotic, it is of interest also to speculate upon the composition of these lesions. The author has identified them as cholesterol crystals. He has stated that in some cases the plaques may be liquid in nature, since compression of the globe produces on "ameboid bulging into the neighboring arteriole . . ." In ophthalmology the term "cholesterol crystals" is used very uncritically. Almost any highly reflective substance interposed in the path of the ophthalmoscopic beam, such as, for example, the polychrome lustre of a central diabetic retinopathy or the kaleidoscopic reflex which is reflected from certain changes in the lens and cornea, is frequently so designated. Even accepting the concept of liquid crystals, there is little real proof of the constitution of these substances which have the common property of giving back a brilliant yellow reflection. Moreover, the color reflected is in large part due to the wave length of the light by which they are seen. As an instance, emboli of metallic mercury appear yellow in the light of the latest Zeiss camera which has a far higher Kelvin rating than the usual electric ophthalmoscope. In one instance the discussor had the opportunity of opening an eyeball having a creamy plaque and a presumable septic embolus to find that in daylight the yellow spot could not be identified as such but only by reference to surrounding vessels. Furthermore, the discussor has examined the fundi of a college athlete who suddenly became febrile and unconscious three days after a fracture of the femur. The retinal arterioles were filled with these bright yellow spots which were undoubtedly fat emboli. A yellow plaque has been observed in the artery of a young girl with rheumatic fever. If embolic, it must originate on a heart valve and presumably contain calcium. Similarly when an embolus occurs in subacute bacterial endocarditis, the endarteriolar obstruction may have all the characteristics of the plaques described in this paper

until the overlying edema, associated with the infarct, partially obscures the lesion, producing the soft creamy appearance. However, these are relatively minor areas of disagreement. Of whatever composition, these plaques are most probably embolic. The discussor does not consider the glittering coppery appearance characteristic of cholesterol. Perhaps the plaque may become creamy when total obstruction occurs, this being a quantitative rather than a qualitative differentiation.

Of particular importance is the localizing value of these emboli. When correlated with retinal artery pressures, the plaques were found to appear twice as frequently on the side with the low pressure. When pressures were equal, the plaques appeared more than twice as frequently on the side of symptomatic insufficiency. Ophthalmodynamometry within itself is, in the hands of most of us, far from an exact science. The addition of these additional "indicators" will be a great value in enhancing this diagnostic procedure.

An additional feature of this presentation is the possible therapeutic application. From the material presented, as well as from the discussor's limited experience, when retinal arteriolar plaques are observed, it would seem appropriate to consider immediate anticoagulant therapy, particularly where there is additional evidence of circulatory embarrassment in the ophthalmodynamometric examination.

We would like to inquire of the essayist then—

(1) Does he consider the yellow plaques always embolic in nature, or does he think that they may represent at times thrombotic phenomena related to the subintimal deposits of cholesterol found in larger arteries?

(2) How does the author explain the bulbous enlargement of the vessel at the involved bifurcation?

(3) Strictly as a concept in hydrodynamics, would not a particle so small as not to obstruct either branch of a bifurcating canal system select one or the other branch for total obstruction, particularly if ameboid in character?

(4) Under what conditions in the presence of the plaques would he consider anticoagulant therapy, how long, and at what percentage would he maintain the prothrombin level?

(5) Under what circumstances would he consider lowering the intra-ocular pressure by retrobulbar injection, massage, carbonic anhydrase inhibitors, or hypertonic solutions?

I have been intensely interested in the diagnostic and therapeutic possibilities indicated in this paper. Dr. Hollenhorst is to be commended in having made a very real contribution to the understanding of vascular disease involving the eye and brain.

DR. LESLIE C. DREWS. W.D.K., a near neighbor of mine, was seen at his home on February 15, 1954. Right eye vision had suddenly gone out 15 minutes before and had recovered after 12 minutes with a field loss to 20–30 degrees from fixation below, both subjectively and on confrontation.

Ophthalmoscopic examination showed a porcelain-like, yellow-white glistening embolus in the superior temporal artery, 4 disc diameters from the disc (#1) astride the first large bifurcation. The artery distal to this was fairly well filled. There was no edema of the retina. Deep massage of the right eye was done four or five times for 2 to 3 minutes each, after which the embolus shifted so that it pointed into the superior branch but still remained essentially in the bifurcation. Two other similar but much smaller emboli were noted in the lower branches of the descending branch of the superior temporal artery, one astride a bifurcation 1 disc diameter temporal to the fovea. Three hours later this embolus could not be found in any of the arteries past this point. The embolus at #1 position nearly plugged the blood vessel. It was quite irregular and rough so that varying depths of blood layers could be seen coursing over it in a most spectacular display.

Two days later, on February 13, visual fields were normal with 2/330 white and 2/330 red. Six gleaming emboli were found, all in the branches of the superior temporal artery of the right eye, but also one was found in an artery one disc diameter to the temporal side of the fovea of the left eye. General examination was advised. On February 17 only two emboli could be found, both in the right eye. On February 19 and 22 there was no change. The patient went to the Mayo Clinic for general examination.

On March 10 the patient returned to my neighborhood. Examination showed a plaque in the #2 position on the diagram astride a bifurcation, plus the remains of the first plaque at the #1 position.

On March 19 Dr. Rucker reported "a small plaque *on* the superior temporal artery of the right eye, which represents a minimal sclerosis of retinal arterioles."

On March 21 the vision of the right eye suddenly was lost again. After five minutes, when I saw him, the vision of the right eye was 3/100, the left eye 8/8. Ophthalmoscopic examination showed moderate spasm of all the retinal arteries of the right eye, with a fairly large embolus in the retinal artery one disc diameter below the disc in the position of #4 on the diagram.

At this time the patient noted a grey cloud in the upper temporal field O.D., but the visual field seemed normal to confrontation. Deep massage was done for 1 to 2 minutes, with a sudden return of vision to 8/8. Ophthalmoscopic examination 30 minutes later, with the pupil well-dilated under euphthalmine, showed four plaques in the infratemporal artery, all at bifurcations, and six other gleaming, tiny points in this artery but not located at bifurcations, and much smaller than the plaques which were astride the bifurcations. Nicotinic acid 150–250 mgm. b.d. was ordered. The new emboli all gradually absorbed or were lost during the next two weeks, and no more have been observed since then.

On April 9 there was marked blurring of the right eye in the upper field. The inferior branch of the artery on the disc seemed absent for about $\frac{1}{2}$ disc diameters, as indicated on the diagram. After a half hour the vessel opened

up and the blurring stopped. However, on the following day a severe attack with a complete loss of the upper field occurred, with essentially the same finding except that perhaps a little more of the vessel seemed to be constricted. As the patient was being watched the vessel opened up and vision returned. There was a similar attack on April 29.

Repeated examinations up to June, 1957, have all been entirely negative and the visual fields have remained perfectly normal. The patient noted no visual trouble since his last attack on April 29, 1954, up to one year ago.

I would suggest that if you have a case like this you could use observations on the flow of blood over a large plug as an accurate method of measuring the effect of vasodilators.

DR. WENDELL L. HUGHES. I would like to show one slide and ask Dr. Hollenhorst if any of his cases have gone on to a later formation of this type of plaque in the wall. This is a type that we see once in a while. This woman, a doctor, was observed first in 1948. She had a segmental defect in her field, corresponding to the area supplied by this blood vessel. There was no pulsation in the affected vessel, a branch of the central artery of the retina, and there was edema with exudates in the periphery where there was evident closure of the arterial circulation. This plaque entirely disappeared in about a year. Up to the present time (and I saw her about a year ago) there seems to be no further development of it. She did develop a general arterial disease with hypertension but is carrying along fairly well at the present time.

DR. GEORGE N. WISE. First, I would like to ask Dr. Hughes about his case. Did I understand you to say, Dr. Hughes, that there was a sector field defect corresponding to that retinal region between the arterial lesion and the periphery?

DR. HUGHES. There was a defect in the field corresponding with that.

DR. WISE. With a sector field defect, I do not understand why there would not be regional pallor of the optic disc?

It has been my experience that most of these yellow plaques are adventitial in origin. I had much the same idea as Dr. Anderson and have seldom seen such a plaque actually obstruct an arteriole. Embolic plaques, in my experience, are fuzzy white rather than yellowish-white. I do not think that what one sees is actually the embolus, but rather the area of reaction about it. As Dr. Anderson pointed out, the white fuzzy lesion extends well beyond the actual vessel wall and therefore would have to represent more than the embolus itself.

The yellowish bright plaques at bifurcations under discussion today often show a clear zone between the end of the plaque and the border of the blood column, thus indicating an adventitial position. This is best seen with the slit lamp and contact lens. When the plaque is sufficiently dense and encompasses or lies directly on top of the artery, it does appear to block

the artery, but field examination will usually reveal that the artery is patent. Those plaques lying a little offside will commonly leave a thin trace of visible red blood cell column passing by the side.

DR. FREDERICK H. VERHOEFF. I really don't know a thing about this subject, but I can't resist the temptation to discuss it from a theoretical standpoint.

The question is as to the origin of the plaque. I don't think it could be thrombotic, because a thrombus is, of course, coagulated blood and there is no reason why there should be crystals in that. However, it could be endarteritic. You can have endarteritis of a vessel, and as a result of this you can have cholestrin crystals deposited in it. If that was so, you would expect it to be particularly frequent in marked sclerosis of retinal vessels, and I haven't heard anyone say that. I think it is certainly not true.

I think the embolic theory is the best one. The fact that these plaques are so large could be explained in this way: a few cholestrin crystals do not completely obstruct the vessel, but make a place for other cholestrin crystals to accumulate. If they are in the blood at a particular time, and one or two do collect in a vessel, they will cause an obstruction and cause others to collect and finally a large collection could result. This explanation overcomes Dr. Hollenhorst's objection to the embolic theory that the plaques are too large to be embolic.

I have discussed this matter without knowing a damned thing about it. [Laughter]

DR. HOLLENHORST. Dr. Verhoeff, I think you have settled it, at least to my satisfaction. [Laughter]

First of all, I would like to thank Dr. Anderson, Dr. Drews, Dr. Hughes, Dr. Wise, and Dr. Verhoeff for their comments. In answer to Dr. Wise's statement that these plaques probably are in the adventitia, I cannot believe this concept is tenable, in view of the pictures you have seen. I have actually seen these little plaques move along in the vessel from one bifurcation to the next. I doubt that a lesion in the adventitia could do that. I am convinced that most, if not all, of the plaques are of embolic origin.

I think Dr. Wise has answered Dr. Anderson's question as to why these plaques seem larger than the vessel. Actually, they are larger than the blood column but not wider than the arteriole. The arteriole itself is probably considerably wider than the blood column that we see with the ophthalmoscope; these plaques may actually extend into an invisible part of the arteriole, that is, the part of the arteriole that is filled with the thin peripheral stream of blood rather than the thick central portion visible to the ophthalmoscope.

On at least one occasion I have seen the phenomenon Dr. Drews described, that is, a thin column of blood going around one of these lesions; in fact, the blood that went around the plaque seemed to be outside the vessel wall. Obviously the moving blood must have been in the part of the lumen of the vessel which was not visible to the ophthalmoscope.

Dr. Anderson asks under what conditions, in the presence of the plaques, would I consider anticoagulant therapy. I would not consider it at all in these patients unless there is some other evidence of occlusive involvement of the vascular system, and I think the only way one can find out about that is to carry out a complete and thorough general examination.

I hope someone will find a case of this type to study pathologically and settle the question of the nature of these plaques.

These observations tend to implicate recurrent embolic phenomena in the production of amaurosis fugax and other manifestations of carotid and vertebral-basilar arterial insufficiency. Whether this is true or not, I think only time will tell. When I encounter these plaques I make it a practice in my office to measure the ophthalmic artery pressures and to listen over the carotid arteries with a stethoscope before referring the patient for study.